



# WAR SURGERY

**WORKING WITH LIMITED RESOURCES  
IN ARMED CONFLICT  
AND OTHER SITUATIONS OF VIOLENCE**

**VOLUME 2**

**C. Giannou  
M. Baldan  
Å. Molde**



**ICRC**



**ICRC**

International Committee of the Red Cross  
19, avenue de la Paix  
1202 Geneva, Switzerland  
T +41 22 734 60 01 F +41 22 733 20 57  
E-mail: [shop@icrc.org](mailto:shop@icrc.org) [www.icrc.org](http://www.icrc.org)  
© ICRC, March 2013

Cover photos: M. Baldan / ICRC; Michael Zumstein / Agence VU; E. Erichsen / Aira Hospital, Ethiopia

# WAR SURGERY

**WORKING WITH LIMITED RESOURCES  
IN ARMED CONFLICT  
AND OTHER SITUATIONS OF VIOLENCE**

**VOLUME 2**

**C. Giannou  
M. Baldan  
Å. Molde**



**ICRC**



## PREFACE

It is with great pleasure that I welcome the completion of Volume 2 of *War Surgery: Working with Limited Resources in Armed Conflict and Other Situations of Violence*. As did Volume 1, this second volume has benefited from numerous remarkable professional collaborations and scientific contributions under the joint authorship and review of Drs Christos Giannou, Marco Baldan and Åsa Molde. I feel certain that it will provide a new point of reference for health professionals engaged in providing lifesaving services in often hazardous environments.

Most fortuitously, the publication of Volume 2 coincides with the 150th anniversary of the founding of the International Committee of the Red Cross. The historical importance of this anniversary for professionals engaged in war surgery cannot be overstated. In 1863, a group of Swiss citizens created the International Committee of Geneva for the Relief of Wounded Soldiers, which heralded the dawn of a new consciousness regarding the fate of the wounded left incapacitated on the battlefield. The history of the ICRC and the Red Cross/Red Crescent Movement is intimately interwoven with the development of war surgery, both as a professional discipline and as an ethos in times of armed conflict.

The ICRC's future will be shaped by its commitment to continuous learning and to the enhancement of the professionalism of humanitarian action. This new manual bears testimony to the dedication of Red Cross and Red Crescent surgeons in articulating and sharing their experiences to prepare a new generation of professionals equipped and empowered to be the future standard-bearers for war surgery.

Since the publication of *Surgery for the Victims of War* in 1985, the ICRC has accomplished a great deal – although much remains to be done – in defining the appropriate treatment protocols for the management of the war wounded when working in resource-poor settings: a continuous exercise of updating and expanding relevant and appropriate knowledge to help save lives and alleviate suffering in spite of the prevailing and often dire conditions.

Consequently, this manual is first and foremost accountable to the people and communities it seeks to serve. In addition, in the pursuit of protecting and assisting the victims of armed conflict and other situations of violence, the ICRC insists on the safeguarding of medical neutrality and accessibility of medical care to those in need as a fundamental message of the International Movement of the Red Cross and Red Crescent and of all humanitarian work. Indeed, to use the words of the Health Care in Danger campaign: "It's a matter of life and death".



Peter Maurer

President  
International Committee of the Red Cross



# TABLE OF CONTENTS

INTRODUCTION TO VOLUME 2	11	
<b>Part A</b>	<b>BLAST PHENOMENA</b>	<b>17</b>
A.1	Short history of the weapons of war and armed conflict	19
A.2	Munition composition	20
A.3	Open-air bomb explosion	20
A.4	Effects due to the environment	21
A.5	Specific explosive devices	22
<b>Chapter 19</b>	<b>EXPLOSIONS AND PRIMARY BLAST INJURIES</b>	<b>25</b>
19.1	Introduction	27
19.2	The single bombing incident	27
19.3	Epidemiology	29
19.4	Pathogenesis and pathophysiology	32
19.5	Clinical presentations and management	34
19.6	The ear and ruptured tympanum	36
19.7	Blast lung	36
19.8	Arterial air embolism	39
19.9	Visceral injury	39
19.10	Eye and maxillo-facial injuries	40
19.11	Other injuries	40
19.12	Removal of unexploded ordnance	40
<b>Chapter 20</b>	<b>INJURIES DUE TO ANTI-TANK MINES</b>	<b>43</b>
20.1	Introduction	45
20.2	Epidemiology	45
20.3	ATM effects on an armoured vehicle	46
20.4	Clinical presentations	47

<b>Chapter 21</b>	<b>INJURIES DUE TO ANTI-PERSONNEL MINES</b>	<b>51</b>
21.1	Introduction: the humanitarian challenge	53
21.2	Mechanism of injury	54
21.3	Clinico-pathological patterns of injury	55
21.4	Epidemiology	57
21.5	Blast mine injury: pathogenesis and clinical implications	60
21.6	Clinical presentation and management	64
21.7	Surgical management of pattern 1 traumatic amputations	66
21.8	Special features of mine-blast injury to the foot	68
21.9	Special features of mine-blast injury to the hand: pattern 3	69
21.10	Surgical management of pattern 2 injuries	69
21.11	Physical and psychological rehabilitation	70
21.12	Conclusion: the humanitarian challenge	70
	Annex 21. A Humanitarian repercussions of landmines	71
<b>Part B</b>	<b>LIMBS</b>	<b>75</b>
B.1	Introduction	77
B.2	Wound ballistics	78
B.3	Epidemiology	78
B.4	Emergency room care	80
B.5	Surgical decision-making	82
B.6	Patient preparation	85
B.7	Surgical treatment	86
B.8	Topical negative pressure and vacuum dressing	90
B.9	Crush injury of the limbs: rhabdomyolysis	90
B.10	Compartment syndrome and fasciotomy	91
B.11	Reconstructive surgery of the limbs	96
	Annex B.1 Pneumatic tourniquet	97
	Annex B.2 Crush injury	98
<b>Chapter 22</b>	<b>INJURIES TO BONES AND JOINTS</b>	<b>103</b>
22.1	Introduction	105
22.2	Wound ballistics	105
22.3	Epidemiology	109
22.4	Management of war wounds with fractures	112
22.5	Methods of bone immobilization: surgical decision-making	114
22.6	Wounds involving joints	121
22.7	Hand and foot injuries	123
22.8	Problematic cases	125
22.9	Bone infection	127
22.10	Bone grafting	131
	Annex 22. A Plaster-of-Paris	133
	Annex 22. B Traction	145
	Annex 22. C External fixation	156
	Annex 22. D ICRC chronic osteomyelitis study	163
	Annex 22. E Bone grafting	166
<b>Chapter 23</b>	<b>AMPUTATIONS AND DISARTICULATIONS</b>	<b>171</b>
23.1	Introduction	173
23.2	Epidemiology	174
23.3	Surgical decision-making	175
23.4	Classical surgical procedure: initial operation	177
23.5	Delayed primary closure	180
23.6	Myoplastic amputations	181
23.7	Guillotine amputation	188
23.8	Specific amputations and disarticulations	189
23.9	Post-operative care	195
23.10	Patient rehabilitation	195
23.11	Complications and stump revision	197



<b>Chapter 24</b>	<b>VASCULAR INJURIES</b>	<b>201</b>
24.1	Introduction	203
24.2	Wound ballistics and types of arterial injury	203
24.3	Epidemiology	205
24.4	Emergency room care	208
24.5	Diagnosis and surgical decision-making	209
24.6	Surgical management	210
24.7	Post-operative care	217
24.8	Damage control and temporary shunt	217
24.9	Complex limb injuries: concomitant arterial lesion and fracture	219
24.10	Specific arteries	219
24.11	Venous injury	220
24.12	Arterio-venous fistula and pseudoaneurysm	221
24.13	Complications	223
<b>Chapter 25</b>	<b>INJURY TO PERIPHERAL NERVES</b>	<b>225</b>
25.1	Introduction	227
25.2	Wound ballistics	227
25.3	Pathophysiology	227
25.4	Epidemiology	228
25.5	Clinical picture	229
25.6	Surgical management	230
25.7	Surgical technique of nerve suture	233
25.8	Post-operative care	235
25.9	Post-trauma sequelae	236
<b>Part C</b>	<b>HEAD, FACE, AND NECK</b>	<b>239</b>
C.1	The general surgeon and the head, face and neck	242
<b>Chapter 26</b>	<b>CRANIO-CEREBRAL INJURIES</b>	<b>245</b>
26.1	Introduction	247
26.2	Mechanisms of injury and wound ballistics	248
26.3	Epidemiology	250
26.4	Pathophysiology	253
26.5	Clinical examination	254
26.6	Emergency room management	256
26.7	Decision to operate	257
26.8	Operating theatre	258
26.9	Cranio-cerebral debridement: "burr-hole" wound	260
26.10	Tangential wounds	263
26.11	Other penetrating wounds	266
26.12	Trepanation	268
26.13	Difficult situations	268
26.14	Post-operative and conservative management	272
26.15	Increased intracranial pressure	274
26.16	Cerebrospinal fluid fistula	275
26.17	Infection	275
26.18	Primary blast neurotrauma	276
26.19	Post-trauma rehabilitation	277
Annex 26. A	Trepanation	278

<b>Chapter 27</b>	<b>MAXILLO-FACIAL INJURIES</b>	<b>283</b>
27.1	Introduction	285
27.2	Wound ballistics	286
27.3	Epidemiology	287
27.4	Clinical examination and emergency room care	288
27.5	Decision to operate	290
27.6	Haemostasis and debridement	292
27.7	Mandibular fractures	295
27.8	Midface fractures	301
27.9	Skin closure	304
27.10	Post-operative management	305
27.11	Complications	306
<b>Chapter 28</b>	<b>INJURIES TO THE EAR</b>	<b>309</b>
28.1	Epidemiology and mechanism of wounding	311
28.2	External ear	311
28.3	Middle ear	312
28.4	Inner ear	313
<b>Chapter 29</b>	<b>INJURIES TO THE EYE</b>	<b>315</b>
29.1	Introduction	317
29.2	Wounding mechanisms and ballistics	318
29.3	Epidemiology	319
29.4	First aid and emergency care	320
29.5	Clinical picture and examination	320
29.6	Primary management	323
29.7	Assessment of injury and decision to operate	323
29.8	Anaesthesia	324
29.9	Minor procedures	325
29.10	Intermediate injuries	327
29.11	Excision of the eye	329
29.12	Retrobulbar haemorrhage	331
29.13	Treatment of complications	332
29.14	Burns of the eyelids and eye	333
	Annex 29. A Complete ocular examination	334
<b>Chapter 30</b>	<b>INJURIES TO THE NECK</b>	<b>337</b>
30.1	Introduction	339
30.2	Surgical anatomy	339
30.3	Wound ballistics	341
30.4	Epidemiology	341
30.5	Clinical presentations and emergency room care	343
30.6	Decision to operate	347
30.7	Patient preparation	347
30.8	Surgical management of vascular injuries	348
30.9	Surgical management of laryngo-tracheal injuries	352
30.10	Surgical management of pharyngo-oesophageal injuries	354
30.11	Post-operative care	355
30.12	Tracheostomy	356
<b>Part D</b>	<b>TORSO</b>	<b>359</b>
D.1	Introduction	361
D.2	Epidemiology	361
D.3	Thoraco-abdominal wounds	362
D.4	Injuries to the diaphragm	364
D.5	Transaxial injuries	365
D.6	Junctional trauma	365
D.7	The general surgeon and the chest: the psychological partition	366

<b>Chapter 31</b>	<b>THORACIC INJURIES</b>	<b>369</b>
31.1	Introduction	371
31.2	Wound ballistics	371
31.3	Epidemiology	373
31.4	Clinical presentation	376
31.5	Emergency room management	380
31.6	Intercostal chest tube drainage	381
31.7	Thoracotomy	385
31.8	Exploration of the chest cavity	390
31.9	Wounds of the chest wall	391
31.10	Injuries of the lung	391
31.11	Great vessels, heart and pericardium	395
31.12	Oesophageal injuries	398
31.13	Other injuries	399
31.14	Thoracic damage control	400
31.15	Post-operative care after thoracotomy	400
31.16	Retained haemothorax	401
31.17	Empyema	402
Annex 31. A	Intercostal nerve block	405
Annex 31. B	Intercostal chest tube	406
Annex 31. C	Thoracic incisions	412
<b>Chapter 32</b>	<b>INJURIES TO THE ABDOMEN</b>	<b>419</b>
32.1	Introduction	421
32.2	Wound ballistics	421
32.3	Epidemiology	425
32.4	Clinical presentations	432
32.5	Emergency room management	434
32.6	Decision to operate	436
32.7	Preparation of the patient and anaesthesia	437
32.8	General plan of surgery	438
32.9	Damage control: abbreviated laparotomy	442
32.10	“Frontline laparotomy” and late-presenting patients	445
32.11	Midline great vessels	446
32.12	Liver and biliary tract	450
32.13	Pancreas, duodenum and spleen	458
32.14	Stomach	465
32.15	Small bowel	466
32.16	Colon	468
32.17	Pelvis	474
32.18	Abdominal drains	478
32.19	Post-operative care	479
32.20	Post-operative complications	480
Annex 32. A	Abdominal compartment syndrome	482
<b>Chapter 33</b>	<b>UROGENITAL TRACT INJURIES</b>	<b>485</b>
33.1	Introduction	487
33.2	Wound ballistics	487
33.3	Epidemiology	487
33.4	Examination and diagnosis	488
33.5	Kidneys	488
33.6	Ureters	494
33.7	Urinary bladder	500
33.8	Prostate and posterior urethra	501
33.9	Male external genitalia and anterior urethra	503
33.10	Female genitalia and urethra	506
33.11	Post-operative care	507

<b>Chapter 34</b>	<b>AUTOTRANSFUSION</b>	<b>509</b>
34.1	Rationale of autotransfusion	511
34.2	Methodology of autotransfusion	512
34.3	Pathophysiological changes	513
34.4	Indications	514
34.5	Practical autotransfusion methods	515
34.6	Complications and risks	519
<b>Chapter 35</b>	<b>WAR WOUNDS IN PREGNANT WOMEN</b>	<b>523</b>
35.1	Introduction	525
35.2	Wound ballistics	525
35.3	Epidemiology and international humanitarian law	525
35.4	Clinical picture and emergency room care of the mother	527
35.5	Examination of the foetus	529
35.6	Surgical decision-making	530
35.7	Surgery of the abdomen	531
35.8	Post-operative care	532
<b>Part E</b>	<b>SPINE</b>	<b>535</b>
<b>Chapter 36</b>	<b>INJURIES OF THE VERTEBRAL COLUMN AND SPINAL CORD</b>	<b>541</b>
36.1	Wound ballistics	543
36.2	Epidemiology	544
36.3	Pathophysiology	545
36.4	Clinical picture and examination	546
36.5	Emergency room management	550
36.6	Surgical decision-making	552
36.7	Organization of further management	553
36.8	Skin care	554
36.9	Care of the bladder	555
36.10	Nutrition and care of the bowels	558
36.11	Physiotherapy and mobilization	558
36.12	Complications	560
Annex 36. A	Hospital nursing care	563
<b>Part F</b>	<b>HOSPITAL MANAGEMENT AND PATIENT CARE</b>	<b>571</b>
F.1	Hospital management	573
F.2	Post-operative care	574
F.3	Critical care in low-income countries	578
F.4	Improvisation	580
F.5	Final remarks	582
Annex F. 1	Ballistics	583
Annex F. 2	Red Cross Wound Score and classification system	586
Annex F. 3	ICRC antibiotic protocol	588
<b>ACRONYMS</b>		<b>591</b>
<b>SELECTED BIBLIOGRAPHY</b>		<b>595</b>





## INTRODUCTION TO VOLUME 2

Volume 1 of this manual has been well received by its target audience: surgeons of the Red Cross/Red Crescent Movement and other humanitarian agencies, and civilian and military colleagues working in austere, constrained and at times hostile environments. While Volume 1 dealt with general themes and topics, the challenge of Volume 2 lies in applying the same logic to the management of actual wounds in specific organ systems.

Different socio-economic and tactical contexts call for different “surgeries” for the victims of war as described in Sections 1.3 and 6.5 in Volume 1. No one model of organization of surgical care can meet the demands and constraints of very different contexts. The context may be military or civilian and involve a wealthy industrialized society, an emerging economy, or a low-income country. The constraints are related to security; efficiency of pre-hospital care and patient evacuation; the supply of medicines and consumables and the repair and maintenance of equipment; and of course the availability of human resources, both in terms of numbers and technical competency. All too often, while facing a barrage of war casualties, hospital staff find themselves working in conditions bereft of the resources necessary to provide optimal patient care. It is under these circumstances that the application of appropriate clinical techniques and protocols employing appropriate technology come to the fore in fulfilling their lifesaving potentials given the constraints – material and human.

Inevitably, the techniques described are not those of the latest developments as performed by specialists working in an academic setting. Many are a throwback to what was expected of a general surgeon one or two generations ago. That such techniques are still scientifically valid today is a tribute to our predecessors and they still form the basis of good surgical practice in many countries where, even in peacetime, resources are limited and working circumstances precarious.

As mentioned, this manual is geared to the needs of the trained general surgeon working more or less in isolation in a rural hospital where referral of patients to more sophisticated facilities – far away in an inaccessible major city – is impractical or impossible. It also recognizes the great variety of technical competency and professional experience of its readers. This is why, for example, the operative details of both chest tube drainage and a thoracotomy are described.

The surgical management of the various organ systems of the body is subdivided into surgical subspecialties, such as neurosurgery, maxillo-facial surgery, ophthalmology and otorhinolaryngology, chest and vascular surgery, and orthopaedics. The general surgeon will usually have only a passing knowledge of the procedures required to deal with trauma affecting these different organ systems. Nonetheless, a great deal can be done by applying simple and basic techniques well within the competency of the general surgeon. The operations described are those that have proved successful in the experience of ICRC surgeons and other colleagues working in similar conditions.

More sophisticated procedures, particularly of reconstructive surgery, do indeed require the expertise of the specialist, and are not dealt with in this book.

We hope that well-trained specialist surgeons working in resource-poor settings will also find this ICRC experience useful and relevant, since the constraints of limited resources mean that the surgeon must accept that he cannot fully utilize his capacities and expertise, owing to a lack of diagnostic equipment and therapeutic means, such as blood for transfusion.

Moreover, the limits of the surgery that can be performed are most often determined by the level of anaesthesia, post-operative nursing care and physiotherapy available. In this respect too, the surgeon working in a resource-poor environment carries a particular responsibility and must, for instance, be able and willing to personally make the patient cough and breathe deeply and get the patient out of bed and walking and exercising.

Volume 2 of this manual deals with trauma specific to armed conflict. Blunt injuries also occur during war, but will only be mentioned to indicate what distinguishes them from injuries caused by projectiles and blast.


The chapters fall into a similar pattern. They start with the particularities of ballistics as applied to the organs of that region, and include a brief overview of the relevant epidemiology and the most important clinico-pathological presentations. These sections are followed by a description of the paraclinical investigations using the appropriate level of technology as is warranted by ICRC experience. Pre-operative and operative procedures, according to ICRC protocols, are then explained. Basic patient monitoring with limited means and post-operative care and physiotherapy complete the management sequence. The most common complications close the chapter.

As expressed in the Introduction to Volume 1, the authors hope that colleagues facing the challenge of treating the victims of armed conflict and other situations of violence under precarious and, at times dangerous, circumstances will find this book useful.



Christos Giannou

Senior ICRC surgeon,  
former ICRC head surgeon



Marco Baldan

Senior ICRC surgeon,  
former ICRC head surgeon



Åsa Molde

Senior ICRC surgeon,  
former Coordinator of  
ICRC surgical programmes,  
and former Vice-President  
Swedish Red Cross Society



Please note:

Three annexes have been added to Part F to facilitate the reading of this Volume. They include a short summary of wound ballistics, the Red Cross Wound Score, and the ICRC antibiotic protocols. Including them in Volume 2 allows for a quick reference. For detailed explanations, the reader should refer to the relevant chapters in Volume 1.

The manual, a film on the treatment of anti-personnel landmine injuries, and ICRC brochures dealing with physiotherapy techniques, the application of plaster-of-Paris and bone traction, and polypropylene technology for prostheses are included in the DVD attached to this volume. The disk also contains several downloadable files – annexes for the home care of spinal injury patients – written in simple English that can be translated and adapted for use in the everyday practice of home-care teams.

Cross references to topics presented in Volume 1 are given as references to a specific chapter or section without repeating the mention of Volume 1.

Many readers of this book are not native English speakers. Consequently both style and vocabulary have been chosen with this readership in mind and certain well-known abbreviations have been spelt out. Unless stated otherwise masculine nouns and pronouns do not refer exclusively to men, for the manual is gender neutral. Any use of trade or brand names is for illustrative purposes only and does not imply any endorsement by the ICRC. No patient was photographed without consent – explicit or implicit.

This volume supersedes and replaces several ICRC publications that will no longer be available. The knowledge and experience expressed in these works form the continuing basis of ICRC surgical protocols.

- *Surgery for Victims of War*, by Daniel Dufour, Soeren Kromann Jensen, Michael Owen-Smith, Jorma Salmela, G. Frank Stening, and Björn Zetterström. Second edition edited by Robin Gray; third edition revised and edited by Åsa Molde.
- *Amputation for War Wounds*, by Robin M. Coupland.
- *War Wounds with Fractures: A Guide to Surgical Management*, by David I. Rowley.

The authors have not received any outside remuneration for this manual and declare no conflict of interest.

## Acknowledgements

Volume 2 concludes the updating of *Surgery for Victims of War*, first published by the ICRC in 1988. In addition, several chapters have made extensive use of the ICRC brochures by Robin Coupland, *Amputations for War Wounds* (1992), and David I. Rowley, Professor of Orthopaedic and Trauma Surgery, University of Dundee, *War Wounds with Fractures: A Guide to Surgical Management* (1996).

The authors of the present manual and all ICRC surgeons owe a debt of gratitude to the pioneering work of their predecessors, and the clear and simple approach that has continued to serve as a model.

This Volume has benefited from the comments of many colleagues with much experience within and outside the ICRC. Valuable advice throughout was provided by:

Ken Barrand (UK)	Jorma Salmela (Finland)
Mauro Della Torre (Italy)	Valery Sasin (Byelorussia)
Herman Du Plessis (South Africa)	Harald Veen (Netherlands)
Jacques Goosen (South Africa)	Günter Wimhoefer (Germany).
Hans Husum (Norway)	

Daniel Brechbuehler (Switzerland), Victor Uranga (Mexico), and Björn Zackari (Sweden) also contributed comments to various chapters.

Beat Kneubuehl (Switzerland) acted as the scientific adviser on ballistics and blast effects. Ben Lark (UK) of the ICRC was solicited for technical advice on blast phenomena. The course on wound ballistics given by M.C. Jourdan at the Hôpital d'Instruction des Armées, Ste Anne, Toulon, France, was kindly made available. Dominique Loye (Switzerland) of the ICRC served as technical adviser on matters pertaining to weapons and international humanitarian law.

David Rowley (UK) and Richard Gosselin (Canada) served as technical advisers on orthopaedics, as did Michel Richter (Switzerland) on maxillo-facial injuries and Alain Reverdin (Switzerland) for cranio-cerebral wounds. Fabrice Jamet (France) and Helena laasonen (Finland) were technical advisers on war wounds in pregnant women and Assad Muhyddin Taha (Lebanon) on wounds of the torso. Michael Baumberger and Karin Roth of the Swiss Paraplegic Centre in Nottwil provided useful comments on spinal cord injury and Mahiban Thomas (India – Australia) on maxillo-facial injuries.

Astute observations and quotable quotes were contributed by Tim Hardcastle (South Africa) and Louis Riddez (Sweden) and permission to quote was also extended by Norman E. McSwain Jr (USA) and Jean-Louis Vincent (Belgium).

The Second ICRC Master Surgeons Workshop, held in Geneva in December 2010, revised the ICRC protocols on antibiotics, nutrition, and the management of chest tube drainage and skeletal traction amongst other topics. Participants included:

Joseph Adase (Ghana)	Marco Garatti (Italy) representing the non-governmental organization EMERGENCY
Marco Baldan (Italy)	
Ken Barrand (UK)	Christos Giannou (Greece – Canada)
Massey Beveridge (Canada)	Richard Gosselin (Canada)
Daniel Brechbuehler (Switzerland)	Fabrice Jamet (France)
Amilcar Contreras (El Salvador)	Paul MacMaster (UK) representing Médecins Sans Frontières (MSF)
Mauro Della Torre (Italy)	Netherlands
Jean-Marc Fiala (Switzerland)	

Tesfaye Makonnen (Ethiopia)	Enrique Steiger (Switzerland)
Alberto Nardini (Italy)	Kazmer Szabo (Hungary)
Hassan Nasreddine (Lebanon – Switzerland)	Harald Veen (Netherlands)
Valery Sasin (Byelorussia)	Julio Guibert Vidal (Peru)
	Günter Wimhoefer (Germany).

The authors were pleased that collaborators for Volume 1 also participated in the production of this volume: Christiane de Charmant handled the editing of the final text and was responsible for the production while Lisa Zeitoun and Pierre Gudel of SimpleCom Graphics, Yverdon, Switzerland provided the graphic design. Their contribution, as always, is greatly appreciated.

### Permissions and assistance

Apart from ICRC surgeons, a number of colleagues have made photographs available for this manual. The authors wish to thank Takashi Shiroko and Masaharu Nakade of the Japanese Red Cross Society; Franco Plani at the Chris Hani Baragwanath Hospital, Soweto, South Africa; Gamini Goonetilleke, Sri Jayewardenapura General Hospital, and Past President of the College of Surgeons of Sri Lanka; K.N. Joshi, Lumbini Zonal Hospital, Nepal; Dan Meckelbaum, McGill University Hospital; Rusta Saleah, Pattini Provincial Hospital, Thailand; Burapat Sangthong, Songkla University Hospital, Thailand; Michael Stein, Rabin Medical Center – Beilinson Hospital, Petach-Tikva, and Chairman of Israel Trauma Society; Assad Taha, American University of Beirut Medical Center; Moufid Yacoub, Rafidia Hospital, Nablus, West Bank (Palestine); and Assefa Weldu at the Army General Hospital, Addis Ababa, Ethiopia.

The authors also wish to thank the Surgical Centre for War Victims, EMERGENCY, Kabul, Afghanistan; and Erik Erichsen and the Aira Hospital, Oromia Region, Ethiopia, for permission to use their photographs.

In addition, Figure A.5, Crown Copyright, was reproduced with the kind permission of the Editor of the Journal of the Royal Army Medical Corps. Permission was granted by the authors of Bryusov PG, Shapovalov VM, Artemyev AA, Dulayev AK, Gololobov VG. *Combat Injuries of Extremities*. Moscow: Military Medical Academy, GEOTAR; 1996 and Nechaev EA, Gritsanov AI, Fomin NF, Minnullin IP, eds. *Mine Blast Trauma: Experience from the War in Afghanistan*. St Petersburg: Russian Ministry of Public Health and Medical Industry, Vreden Research Institute of Traumatology; 1995, to use and adapt some of their drawings.

The authors must mention Maurice King, editor, *Primary Surgery*, as the inspiration for a number of drawings that have been adapted by the ICRC artist. This book was first published by Oxford University Press and is now available at <http://www.primary-surgery.org/ps/vol2/html/index.html> through the generosity of GTZ, the German Agency for Technical Cooperation. Reproduction of the originals was not possible for technical reasons. The ICRC artist was Nikos Papas, whose collaboration was most welcome.

The Editor of Military Medicine: International Journal of AMSUS (Association of Military Surgeons of the United States) assisted in the research by making certain articles available. In addition, the senior author is greatly indebted to the Ptolemy Project of the Office of International Surgery, University of Toronto, Canada, which provided internet access to the university library. This access was indispensable for the research necessary in the writing of both Volumes 1 and 2 of this manual.



**Part A**

# **BLAST PHENOMENA**

A	BLAST PHENOMENA	
A.1	Short history of the weapons of war and armed conflict	19
A.2	Munition composition	20
A.3	Open-air bomb explosion	20
A.3.1	Positive-pressure shock wave	21
A.3.2	Negative-pressure suction wave	21
A.3.3	Blast wind	21
A.4	Effects due to the environment	21
A.5	Specific explosive devices	22
A.5.1	Enhanced-blast explosive devices	22
A.5.2	Shaped-charge explosives	22
A.5.3	Improvised explosive device (IED)	22
A.5.4	Dense inert metal explosives (DIME)	22
A.5.5	Landmines and unexploded ordnance (UXO)	23

## Basic principles

Weapons systems can act at a greater and greater distance from the victim.

Explosive devices have become the major weapons deployed in contemporary warfare.

Fragments from explosive devices have become the most common mechanism of wounding.

An open-air bomb explosion consists of three phases: positive-pressure shock wave; negative-pressure suction wave; and blast wind.

### A.1 Short history of the weapons of war and armed conflict

From traditional face-to-face combat using bare fists, sticks and stones, knives, swords and spears, other “hand-energized” weapons that struck at a distance came into being: the sling-shot, javelin and bow and arrow. The invention and propagation of gunpowder triggered off a revolution in warfare with the development of weapons that act at an even greater distance: explosive devices and the rifle.

The evolution of warfare has in certain respects largely been based on such technological developments that have engendered a wide variety of tactical combat situations and greatly affected the numbers of casualties and the types of wounds incurred.

Advances in the technology of modern high-order explosives and especially their delivery systems constitute one of the major factors that allow combatants to overcome more readily the “natural inhibition” against killing fellow human beings.<sup>1 2 3</sup> These developments have given rise to an enormous variety of combat scenarios from massive artillery and aerial bombardment of urban areas to the widespread use of landmines, the “perfect” remote and indiscriminate weapons that do not even require the perpetrator to pull a trigger.

Practically speaking, the result of this evolution has been the change in the preponderant wounding mechanism in the last 100 years from bullets to fragments or “shrapnel”, which now cause up to 80% of the injuries seen in wars between classical armies. Guerrilla warfare still results in a higher incidence of gunshot wounds (see Section 5.5).

Fragments are the result of various explosive mechanisms and systems: aerial bombs, artillery or mortar shells; rocket-propelled and hand grenades; landmines and improvised explosive devices.

Sections 3.3.6 and 3.4.8 in Volume 1 discuss the wound ballistics of fragments. However, in addition to the production of fragments, explosive devices also have a primary blast effect that causes lesions with particular characteristics. Part A of Volume 2 is devoted to blast injuries.



**Figure A.1**  
Collection of various munitions.

1 John Keegan. *The Face of Battle*. London: Jonathan Cape Ltd; 1976.

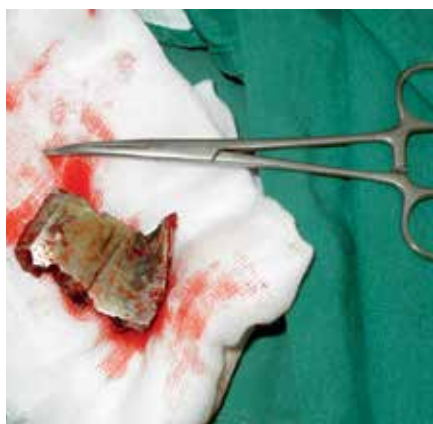2 Lt. Col. Dave Grossman. *On Killing: The Psychological Cost of Learning to Kill in War and Society*. New York, NY: Little, Brown and Co.; 1995.

3 Joanna Bourke. *An Intimate History of Killing: Face-to-Face Killing in Twentieth-Century Warfare*. London: Granta Books; 1999.

## A.2 Munition composition



**Figure A.2**  
Civilian and military-grade plastic explosives.



**Figure A.3**  
Irregular fragment removed from a victim's body.

Explosives are described as either high- or low-order and provoke different patterns of injury. Low-order explosives include gunpowder, small bombs such as pipe bombs, and “Molotov cocktails” (petroleum based). High-order explosives can either be improvised using simple substances available commercially, such as fertilizer and diesel fuel, or specifically manufactured. The latter can be for civilian use, for example quarrying, building dams and other large civil engineering projects, or “military-grade”, and include TNT, dynamite, Penta, and plastic explosive (PE4, C4, Semtex). Munitions normally use a combination of specialized high-order explosives.

All munitions contain an explosive train: a series of components that are designed to ensure the explosive charge functions in the required way at the required time. In a gun or rifle it is a *low-explosive* train, where a primer is struck that produces a flash igniting the propellant contained in the cartridge case. The burning propellant produces gases in a restricted volume thus causing a high pressure to build up. This pressure acts on the base of the bullet and accelerates it through the barrel (Figure 3.6).

The *high-explosive* train in a bomb or explosive device has three basic serial components: the primer or detonator, a booster charge, and a final main charge that produces the desired effect and is the principal determinant of destructive power. The bomb casing holds the components of the device together. It may be purposely designed to break up into projectiles (pre-formed fragments of modern weapons, 100 – 500 mg in weight and 2 – 3 mm in diameter) that increase the probability of hitting a person and are more lethal than ordinary irregular fragments. Otherwise, the casing breaks up irregularly.

## A.3 Open-air bomb explosion

The detonation of an explosive is an exothermic<sup>4</sup> chemical process that converts the explosive charge into high-pressure gases in an extremely short time, measured in microseconds.<sup>5</sup>

In an open-air bomb explosion, part of the energy from the gases produced ruptures the casing, imparting high kinetic energy to the resulting fragments; their initial velocity may be up to 2,000 m/s. Another part produces heat in the form of a fireball, as well as sound, light and smoke. The remaining energy causes the gases to expand rapidly, compressing the surrounding air to produce a blast or shock wave – a pressure pulse – that spreads out spherically in all directions from the point of origin. This blast wave expands faster than the speed of sound and has three components.

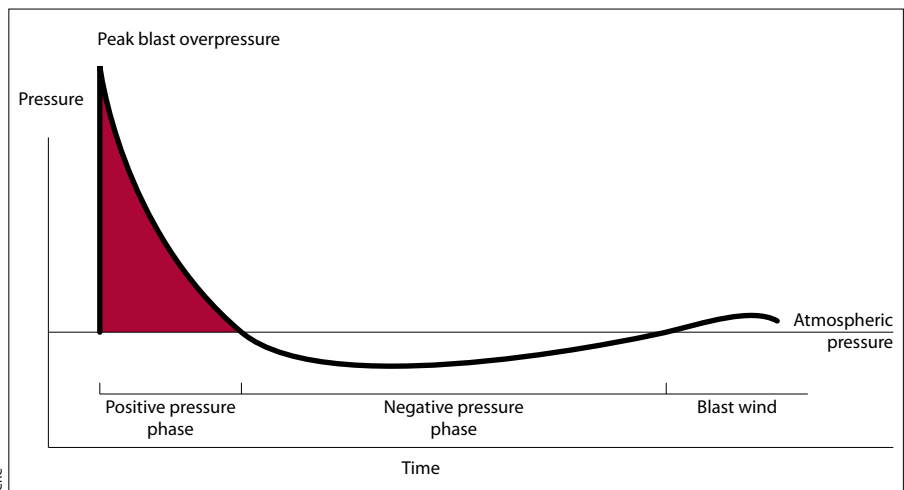
**Figure A.4**

Friedlander curve: pressure-time relationship of a blast wave in open air without obstacles in its path. The area under the curve is the total impulse per unit area.

Positive-pressure shock wave: a pulse of peak overpressure that travels through the ambient medium – air, water or the ground. Only high-order explosives cause an overpressure shock wave.

Negative pressure or rarefaction phase: a suction wave, again only occurring with high-order explosives.

Blast wind: phase of dynamic overpressure with the mass movement of heated air and combustion products. This is produced by both high- and low-order explosives.



4 An exothermic chemical reaction converts the energy in chemical bonds into heat, in contradistinction to an endothermic reaction that absorbs heat.

5 For a low-grade combustion, such as occurs with the gunpowder in a bullet cartridge, this process is about 200 – 400 m/s, relatively slow. For a high-grade combustion in the case of military munitions, the conversion takes place at a speed up to 9,000 m/s or more.



### A.3.1 Positive-pressure shock wave

The positive-pressure shock wave is a moving peak of high pressure and density travelling at supersonic speed at first, as high as 3,000 – 9,000 m/s, but decreasing very quickly with distance. It is of very short duration – in the order of milliseconds – but of very rapid onset, and reaches its maximum pressure load almost instantaneously. This high-pressure peak, in the order of hundreds of bars,<sup>6</sup> also decreases rapidly as the wave moves away from the source of the explosion (inversely proportional to the cube of the distance). Its leading edge in air is called the “blast front” and is visible because of the way it refracts light (Figure A.5). The overpressure of the blast front provokes a shattering effect, also known as *brisance*. Tissue damage depends on the magnitude and duration of the peak overpressure: the impulse.



Figure A.5  
Explosive detonation. Note the blast front indicated by the arrow.<sup>7</sup>

### A.3.2 Negative-pressure suction wave

The passage of the positive component is followed by a negative pressure trough, a *relative vacuum*, which sucks in air and debris. The pressure differential is much less than the positive phase, but can last three to ten times as long, and during its first phase it has more destructive energy than the positive peak.

### A.3.3 Blast wind

The rapidly expanding gases from the explosion displace an equal volume of air and, together, produce a blast wind. This mass movement of air creates a “dynamic overpressure” that travels immediately behind the shock wave, but at a much lower speed. Nonetheless, it can reach several hundred km/h (approximately 100 m/s). It is of lower amplitude than the shock wave, but lasts much longer and travels much further. This dynamic overpressure knocks over or scatters any object shattered by the brisance effect of the shock wave.

## A.4 Effects due to the environment

The propagation of the blast wave can become very complicated in the presence of obstacles or when channelled along streets, corridors, or through pipes and tunnels. Like sound waves, a blast shock wave flows over and around an obstacle and will affect someone sheltering behind. On the other hand, obstacles can also create blast wave turbulence immediately behind them with the formation of relatively safe areas, which is why sometimes people close to explosions survive with relatively minor injuries, or none at all, while those further away suffer more serious injuries or are killed. The wearing of body armour protects against penetration of fragments but not against the overpressure shock wave.

Blast waves hitting a wall perpendicularly exert much greater pressure than those hitting surfaces at an angle. In addition, the perpendicular wave is compressed and reflected back by the wall, causing an amplification of the waves and creating a region of more intense pressure. Thus, a blast in an enclosed or confined space (building, bus, etc.) results in additive reflections of the pressure wave rebounding off the walls; the amplified overpressure is much higher and the impulse lasts longer (Figure A.6). This has an important influence on mortality and on the severity of injury among the people inside. In addition, an explosion in an enclosed space increases the likelihood of the building collapsing.

In underground and underwater explosions the shock wave travels more rapidly and much further because sound has a higher velocity in the denser medium. The radius of lethal injury is about three times greater in water explosions than in air, and injuries at the same distance are more severe.

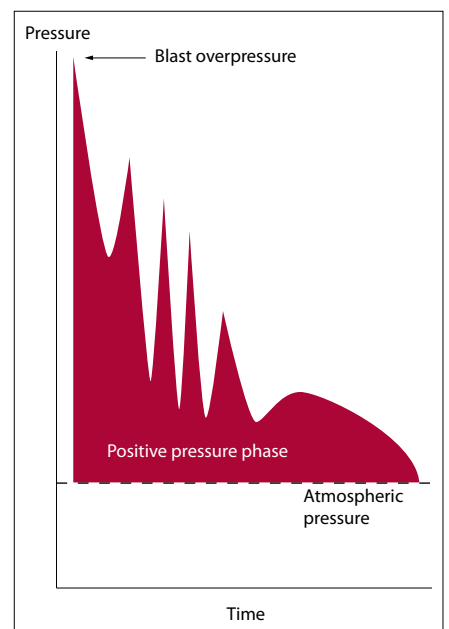


Figure A.6  
Typical pressure – time relationship of a blast in an enclosed space.

<sup>6</sup> In physics the correct term is Newton per m<sup>2</sup>, which has its own unit, the Pascal. In ballistics and meteorology, the term bar is used. One bar equals 100 kilopascals and is approximately equal to atmospheric pressure at sea level. In non-scientific layman's language, this is the equivalent in this specific case of hundreds of kg/cm<sup>2</sup>.

<sup>7</sup> Harrison SE, Kirkman E, Mahoney P. Lessons learnt from explosive attacks. *JR Army Med Corps* 2007; **153**: 278 – 282.

## A.5 Specific explosive devices

A number of variations on basic ordnance have been developed to fulfil specific military demands. A short, non-exhaustive list follows.

### A.5.1 Enhanced-blast explosive devices

With a thermobaric or fuel-air weapon a first small detonation spreads out explosive material as a fine aerosol that mixes with atmospheric oxygen, which is then triggered to produce a second explosion. The disseminated explosive aerosol creates a much larger area of propagation of the shock wave and the initial overpressure lasts longer and reaches further than in an ordinary explosion. In addition, the consumption of atmospheric oxygen in the explosion causes death by asphyxiation. There are few survivors within the range of the primary blast.

### A.5.2 Shaped-charge explosives

In these weapons, the explosive device is constructed in such a way as to amplify the blast overpressure and brisance effect and to channel it into a tight trajectory. The blast wave thus extends as a cone rather than as a sphere starting from a point. The blast overpressure has a devastating effect within the cone, but very little damage is caused outside it. One type of anti-tank mine (ATM) is equipped with a shaped charge.

An explosively-formed projectile is a particular type of shaped charge incorporating a disc that is deformed on detonation into an aerodynamically efficient metal slug that can go through armour. Such projectiles are used in manufactured ATM and, increasingly, have been deployed as improvised "roadside bombs" against tanks and armoured personnel carriers. Once they break through the armour they cause devastating wounds in the individuals they hit, with relatively minor blast injury to those nearby.

### A.5.3 Improvised explosive device (IED)

As the name implies, these are home-made bombs. The explosive material may be military munitions (mortar or artillery shells, or landmines) or commercially available products. IED are used by insurgent groups and non-State actors and factions, and include a great diversity of types, small and large, and are more-or-less efficient: pipe bombs, car bombs, roadside bombs, booby-traps, etc.

### A.5.4 Dense inert metal explosives (DIME)

This device mixes tiny particles of an inert heavy metal, such as tungsten, together with the explosive; thus the fragments are incorporated into the explosive itself rather than derived from the casing, which is made of a material with little fragmentation effect. The result is the creation of a shower of "microfragments" on detonation producing an increased brisance from a relatively low initial blast yield. These microfragments are highly lethal at close range, but the effects fall off very rapidly and the lack of casing fragmentation limits injury to others nearby. Survivors typically present traumatic amputations or severe soft-tissue injuries and retained heavy metal dust, which may be a source of toxicological concern.<sup>8</sup>



ICRC

**Figure A.7**  
Disc incorporated into an explosively-formed projectile.

<sup>8</sup> The data concerning the toxicity of tungsten is limited and contradictory and mostly confined to chronic exposure. Acute intoxication is rare but may present with nausea and the sudden onset of seizures, coma and encephalopathy, and acute tubular necrosis. Carcinogenic potential is a possibility. Treatment is supportive and symptomatic. Please see Selected bibliography.

### A.5.5 Landmines and unexploded ordnance (UXO)

A landmine constitutes a particular explosive device that is *legally defined* by the method of activation. Whether industrially-manufactured or improvised, a mine is activated by the victim. An anti-tank or anti-vehicle mine is “designed to be detonated or exploded by the presence, proximity or contact ... of a vehicle”<sup>9</sup> An anti-personnel mine is defined as “designed to be exploded by the presence, proximity or contact of a person”.

Anti-personnel mines have been banned by an international convention, which has changed the military doctrine of many countries.<sup>10</sup> Nonetheless, APM continue to be used during some conflicts, albeit far less frequently and in far smaller quantities than before.

Other unexploded ordnance and abandoned explosive ordnance also litter battlefields long after combat has ceased: these are the infamous explosive remnants of war (ERW).<sup>11</sup> Cluster munitions “release explosive submunitions each weighing less than 20 kilograms”,<sup>12</sup> which in many cases do not explode as they should and constitute a form of UXO. The same can be said of booby-traps.<sup>13</sup>



Figure A.8  
Unexploded ordnance.



Figures A.9.1 – A.9.3  
Cluster munitions.

Observers and data collection systems are usually not capable of distinguishing between different types of mines and UXO, and all these weapons constitute a danger for civilian populations and clearance experts well after the cessation of hostilities. The mechanism of injury and clinically important sequelae are the same for bombs, landmines and UXO.

Chapter 19 deals more broadly with the primary blast effects of explosions and expands on Section 3.1.4. Chapter 20 considers anti-tank mines, while Chapter 21 develops Section 3.1.3 and discusses in detail the specific example of anti-personnel landmines.

- 9 Convention on Prohibitions or Restrictions on the Use of Certain Conventional Weapons which May be Deemed to be Excessively Injurious or to Have Indiscriminate Effects, Protocol II on Prohibitions or Restrictions on the Use of Mines, Booby-Traps and Other Devices. Geneva, 10 October 1980, as amended on 3 May 1996.
- 10 Convention on the Prohibition of the Use, Stockpiling, Production and Transfer of Anti-Personnel Mines and on their Destruction, 18 September 1997. As at 31.12.2012, there were 160 States Parties to this Convention.
- 11 Protocol on Explosive Remnants of War (Protocol V to the 1980 Convention), 28 November 2003.
- 12 The Convention on Cluster Munitions, 30 May 2008, has banned the use of cluster ammunitions. As at 31.12.2012, there were 77 States Parties to this Convention.
- 13 “Booby-trap” is defined as “any device or material which is designed, constructed or adapted to kill or injure and which functions unexpectedly when a person disturbs or approaches an apparently harmless object or performs an apparently safe act”, according to the 1980 Convention on Conventional Weapons (Protocol II).



## **Chapter 19**

# **EXPLOSIONS AND PRIMARY BLAST INJURIES**

19.	EXPLOSIONS AND PRIMARY BLAST INJURIES	
19.1	Introduction	27
19.2	The single bombing incident	27
19.3	Epidemiology	29
19.3.1	Mortality	29
19.3.2	Survivors	31
19.4	Pathogenesis and pathophysiology	32
19.4.1	Primary blast injury: barotrauma	32
19.4.2	Secondary blast injury: fragment wounds	34
19.4.3	Tertiary blast injury: blast wind	34
19.4.4	Quaternary or miscellaneous blast injury	34
19.5	Clinical presentations and management	34
19.5.1	General concussion syndrome: resistance to resuscitation	35
19.5.2	“Shell shock” and the “bewildered” walking wounded	35
19.6	The ear and ruptured tympanum	36
19.6.1	Management	36
19.7	Blast lung	36
19.7.1	Clinical presentations	36
19.7.2	Chest X-ray and pulse oximetry	37
19.7.3	Assessment of patients with suspected lung injury	38
19.7.4	Patient management	38
19.8	Arterial air embolism	39
19.9	Visceral injury	39
19.10	Eye and maxillo-facial injuries	40
19.11	Other injuries	40
19.12	Removal of unexploded ordnance	40

## Basic principles

A single explosion can produce many victims suffering a variety of injuries.

A single victim may present all four types of blast injury; fragment wounds usually predominate.

Few casualties survive significant primary blast injury.

Deafness should be suspected in confused or unresponsive patients.

Blast lung can develop insidiously up to 48 hours after exposure and is often fatal.

## 19.1 Introduction

Explosions can be caused by various events.

- Physical-mechanical: exploding pressure cooker.
- Exothermic chemical: conventional military-type explosion transforming a chemical compound – solid or liquid – into a large quantity of gas in an exothermic reaction, as seen in bombs, shells, mines and incendiary bombs (napalm, white phosphorus).
- Nuclear: fission or fusion device, atomic and hydrogen bombs.

Non-conventional chemical weapons may or may not involve a conventional detonation that bursts open a container spreading out a toxic chemical substance. A radiological dispersal device, a so-called “dirty bomb”, works in the same way, with a conventional explosive surrounded by radioactive material that is spread out by the explosion; it is not a nuclear device. This chapter deals only with conventional weapons.

Explosive devices have been given different names, usually indicating the means of delivery: letter, pipe, car or aerial bomb; artillery or mortar shell; cruise missile; hand grenade and rocket-propelled grenade; and landmine. Some, such as military ammunition, are industrially manufactured; others are “home-made” and are known as improvised explosive devices. Whether an explosive device is industrially manufactured or improvised makes little qualitative difference in the physics of the explosion and the clinical results of its blast effects.

### Blast injuries are commonly categorized into four types

1. Primary, due to direct pressure effects.
2. Secondary, due to fragment projectiles.
3. Tertiary, due to the blast wind.
4. Quaternary, or miscellaneous: burns, toxic gases, etc.

See also Section 3.1.4.

Most of the clinical discussion of this Chapter pertains to primary blast injury.

## 19.2 The single bombing incident

The great difference between the individually-held assault rifle and an explosive device is in the number of victims that can be produced by a single combatant during a single incident. The range of scenarios using explosive devices during armed conflict is thus far more varied than with simple firearms, and injuries due to the different blast effects of explosions have become more common in modern warfare. However, few single bomb explosions have a preponderance of primary blast effects (USS Battleship Cole in Aden harbour, 2000, was one recent example of this).

In wartime, most medical services and facilities – whatever the level of resources – are prepared and expect the arrival of large numbers of casualties, which they deal with to the best of their capabilities. Even the civilian population learns to take certain protective measures and violence is expected. However, the single bombing incident in an urban environment, taking the system by surprise, results in a number of characteristic problems. General confusion reigns: there is often panic and hysteria among survivors and bystanders. Coordination and communication between armed forces or militias, police, fire-fighters, and first-aid or paramedical teams and ambulances are usually insufficient. In addition, the lines of communication are often cut or overburdened and become non-functional.

If there is structural collapse of a building, delayed rescue and evacuation of patients with a heavy death toll is common. Injuries may also occur among rescuers. Evacuation of most casualties is done by private means: taxis, private cars, or manually-borne stretchers, in a crowded urban environment where the streets are blocked by road traffic. The closest hospitals are invariably flooded with the early arrival of patients with relatively minor wounds: the “reverse triage” phenomenon (see Sections 7.7.8 and 9.13).



M. Della Torre / ICRC

**Figure 19.1**

Fireball and plume of dust and smoke arising from a bombing.

**Figure 19.2**

Building collapse: the frequent result of a bombing.



Magnum / C. Anderson / ICRC

Most fatalities are immediate and located at the scene. About one half of all the survivors arrive at hospital within the first hour, giving an approximate indication of the total number of wounded. Most survivors, however, are not severely injured and the majority can be treated as outpatients. Late neurological and psychological sequelae among survivors are common and may overlap with the signs and symptoms of post-traumatic stress disorder (PTSD).

The limbs, head and neck are the most commonly injured areas, particularly in people who are only superficially wounded. Only about 10% of the survivors admitted to hospital have critical injuries.



## 19.3 Epidemiology

The general epidemiology of armed conflict as described in Chapter 5 applies. Most war wounds are the result of fragments from some sort of explosive device, but most wounded survivors have been injured beyond the radius of the primary blast effect. Indeed, within this radius the density of primary and secondary fragments is so great that lethal injuries are caused by both primary blast effect and fragments. However, many different tactical situations exist. This section describes some epidemiological observations from single bomb explosions where casualties are close enough for all four mechanisms of injury to come into play.

Blast event: multiple mechanisms, multiple casualties, multiple body regions hit.

With bomb explosions there is a potential for multiple casualties and multiple wounds in the same patient. Most explosions create mixed injuries with fragment injuries predominating. The number of casualties and the ratio of different kinds of injuries are determined by a number of factors:

- power of the explosion (magnitude and duration of peak overpressure);
- distance of people from the blast point and their degree of personal protection;
- environmental conditions of the spread of the blast wave
  - topography and relief of the terrain;
  - presence of buildings and other obstacles;
  - meteorological conditions;
  - confined space;
  - presence of water;<sup>1</sup>
- tactical situation – crowded street or market place, or other public space, etc.

### 19.3.1 Mortality

*“La mort était due à la grande et prompte dilation [sic] d’air.”*

(Death was caused by the great and immediate expansion of air.)

Pierre Jars<sup>2</sup> 1758

Casualties may suffer total body disruption or fireball carbonization. Some bodies may show no recognizable external sign of penetrating or blunt injury – there are many anecdotal reports from World Wars I and II of dead soldiers found on the battlefield without any external signs of injury.



Figure 19.3

Total body carbonization of a mother and two children following a bomb explosion.

<sup>1</sup> People who are partially submerged in water when subjected to a blast explosion, for example, suffer very different injuries to the under-water and above-water body parts.

<sup>2</sup> French physiologist who was the first to correctly determine the expansion of gas as the primary effect of a blast explosion. Cited in Hill JF. Blast injury with particular reference to recent terrorist bombing incidents. *Ann R Coll Surg Engl* 1979; **61**: 4 – 11.

Table 19.1 gives a short list of various contemporary single bomb incidents and the different tactical situations: open space, confined space, “ultra-confined” space of a bus, building collapse, etc.

Event	Type	Immediate deaths (% mortality)	Injured	Hospitalized (%)	Critically injured* (%)	Critical mortality (%)	Remarks	Reference
Bologna railway station, Italy, 1980.	Confined space; partial building collapse.	73 (25%)	218	181 (83%)	25 (10%)	11 (44%)	Partial collapse with stones from the building as secondary missiles.	Brismar & Bergenwald, 1982.
Beirut US Marine barracks, Lebanon, 1983.	Open air, large bomb; building collapse.	234 (68%)	112	86 (77%) referred onward.	19 (17%)	7 (37%)	All evacuated to ship.	Frykberg & Tepas, 1989.
Paris metro, France, 1985 – 86.	Confined space; small home-made bombs.	13 (5%)	255	205 (80%)	40 (16%)	7 (18%)	Large number of severely injured; small blast in crowded confined space.	Rignault & Deligny, 1989.
Civilian bus Jerusalem, Israel, 1988.	Small confined space; bus windows closed. Bomb inside bus.	3 (5%)	55	29 (53%)	8 (31%)	3 (37.5%)	High rate of primary blast injuries: perforated ear drums 76%; blast lung 38%; abdominal blast injuries 14%.	Katz et al., 1989.
Federal Building Oklahoma City, USA, 1995.	2,000 kg bomb fertilizer + fuel oil. Open space, building collapse.	166 (21%)	592	83 (14%)	52 (9%)	5 (10%)	Fatalities primarily in collapse zone: out of 361 inside building 163 dead (45%) and 156 injured (88% of total casualties).	Teague, 2004 & Mallonee et al., 1996.
USS Battleship Cole, Aden harbour, Yemen, 2000.	Confined space; no collapse of superstructure; efficient fire-fighting.	16 (30%)	39	All evacuated.	11 (27%)	1 (9.1%)	All dead had severe orthopaedic injuries; 64% of survivors had orthopaedic injuries; peripheral wound thrombosis up to 72h later.	Langworthy et al., 2004.
Khobar Towers, Saudi Arabia, 2001.	20 kg bomb; open space; building collapse.	19 (5%)	555	66 (16%)	24 (6%)	0	Fatalities: multiple blunt, glass and foreign body injuries; 27% injured during rescue and evacuation or clean-up.	Thompson et al., 2004.
Shopping centre Helsinki, Finland, 2002.	Open space.	5 (4%)	161	66 (41%)	13 (20%)	1 (8%) (1 DOA**)	Efficient pre-hospital and dispatch system.	Torkki et al., 2006.
Suicide car bomb Karachi, Pakistan, 2002.	Small confined space. Bomb next to and below bus.	24 (67%)	11	11 (100%)	2 (18%)	***	11/12 survivors with fracture / dislocation calcaneus and bones of foot: "pied de mine" effect.	Zafar et al., 2005.
Israel 2002 – 2003.	5 bus bombings.	56 (21%)	208	121 (58%)	17 (8%)	0	Most lethal: bus is defined as an "ultra-confined space".	Kosashvili et al., 2009.
	3 closed-space bombings (restaurant, etc.).	52 (17%)	256	101 (40%)	35 (13%)	9 (2.9%)	Relatively lethal scenario.	
	4 open-space bombings.	26 (8%)	305	120 (39%)	25 (8%)	5 (1.5%)	Least lethal scenario.	
Madrid train bombing, Spain, 2004.	Confined space.	177 (8.6%)	2,062	512 (25%)	72 (14%)	14 (19.5%)	Large numbers with superficial injuries and emotional shock: not hospitalized but burden on triage.	Turégano-Fuentes et al., 2008.
London transport bombings: 3 underground trains + 1 bus, UK, 2005.	Confined space, small explosions.	53 (7%)	722	667	20 (3%)	3 (15%)	Good pre-hospital triage. Large number of walking wounded nevertheless hospitalized.	Aylwin et al., 2006.

\* Injury Severity Score (ISS) > 15.

\*\* DOA: dead on arrival.

\*\*\* Victims were French engineers; evacuated within 24 hours by order of French authorities.

Table 19.1 Major contemporary single bomb incidents: a partial list. References are to be found in the Selected bibliography.

Explosions with very high rates of immediate death have certain characteristics, whatever the source or means of delivery (car bomb, aerial bombardment, etc.):

- very powerful explosion – the larger the bomb, the greater the destructive effects;
- explosion in a confined, closed space – mortality can reach 50% or higher;
- building collapse – very few survivors amongst those crushed and trapped by the rubble;
- ignition of secondary fires.

Explosions in confined spaces are particularly devastating, with an overall higher mortality rate. Survivors have more severe injuries with a higher incidence of primary blast injuries, including a predominance of blast lung and burns affecting a large body surface area.<sup>3</sup>

Most fatalities present multiple trauma and are due to total body disruption, injuries to the skull and brain, rupture of one of the solid abdominal organs, blast lung and traumatic amputation.<sup>4</sup>

Most bombings, however, generate a large number of casualties with relatively superficial wounds that do not require hospitalization, as shown in Table 19.1. Accurate and efficient triage permits quick identification and treatment of severely-injured patients, thus lowering the critical mortality rate.<sup>5</sup>

### 19.3.2 Survivors

Amongst survivors, as is the case with other weapons systems, most injuries due to explosive blast and requiring surgery involve the limbs. Up to 85% of hospitalized patients have musculoskeletal injuries.

Many patients suffer multiple injuries caused by a wide variety of blast effects, covering a whole spectrum of trauma. Representative of this are the injuries recorded following the bomb attacks against the Madrid trains in 2005; only 512 patients among more than 2,000 casualties were deemed seriously injured enough to be recorded in this study (Table 19.2).

Body region	Patients wounded	Injuries
Head, neck and face	340	
Brain and skull		41
Neck		8
Tympanic perforation		240
Eye injuries		95
Maxillo-facial fractures		48
Other face		14
Chest	199	
Abdomen	28	
Limbs	71	
External	263	
Shrapnel wounds: non-penetrating		211
Burns		89

**Table 19.2** Distribution of injuries according to body regions, Madrid railway bombings 2005.<sup>6</sup> Patients with superficial bruises, transient hearing loss, and/or emotional shock only were excluded. Many patients suffered more than one injury; therefore, the total number of injuries exceeds the number of patients.

3 Leibovici D, Gofrit ON, Stein M, Shapira SC, Noga Y, Heruti RJ, Shemer J. Blast injuries in a bus versus open-air bombings: a comparative study of injuries in survivors of open-air versus confined-space explosions. *J Trauma* 1996; **41**: 1030 – 1035.

4 Hill JF. Blast injury with particular reference to recent terrorist bombing incidents. *Ann R Coll Surg Engl* 1979; **61**: 4 – 11.

5 The critical mortality rate concerns patients with an Injury Severity Score greater than 15.

6 Adapted from Turégano-Fuentes F, Caba-Doussoux P, Jover-Navalón JM, et al. Injury patterns from major urban terrorist bombings in trains: the Madrid experience. *World J Surg* 2008; **32**: 1168 – 1175.

## 19.4 Pathogenesis and pathophysiology

Although four different categories of blast injury are described, they often coexist in a single patient.

### 19.4.1 Primary blast injury: barotrauma

Primary blast injuries are due to the direct effects of over- and under-pressure caused by the shock wave: i.e. barotrauma. These injuries are usually confined to a relatively small area around the point of explosion.

The peak overpressure induces surface compression and deformation waves upon hitting the body and interacts with the tissues to produce two types of energy: stress and shear waves.

A *stress wave* passes longitudinally through the tissues. When it reaches a plane between two tissues of differing density part of it is reflected and part continues, creating pressure differentials. These are particularly acute at air-solid (e.g. ear), air-fluid (e.g. hollow viscera, lung alveoli) and fluid-solid interfaces of delicate structures (e.g. blood vessels).

The air-fluid interface is exceptionally sensitive. The positive pressure stress wave rapidly compresses air in any isolated pockets. With the negative pressure phase the air re-expands violently, rupturing the surrounding tissues. This causes *spalling*, presenting an effect much like that of air bubbles in boiling water.

*Shear waves* propagate transversely to tissue interfaces, similar to the deceleration forces seen in a motor vehicle collision. Contiguous tissues with different densities are accelerated and decelerated at different rates creating a shearing action that overstretches natural tissue elasticity and causes tearing and disruption of attachments. This is especially prominent in solid organs and organs with an elastic anatomic fixation, such as the mesentery of the bowels, the tracheo-bronchial tree or the placenta.

Primary blast effects include specific injury to various parts of the body.

#### Ear

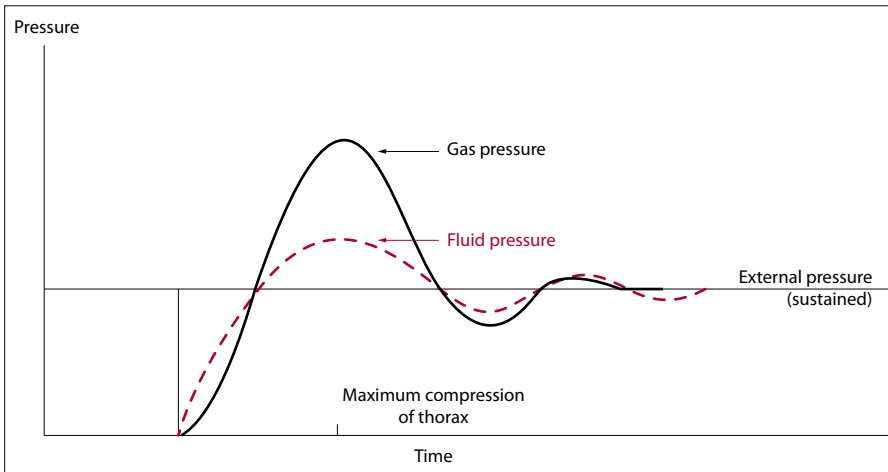
Rupture of the tympanic membrane is the *most common injury*, but does not depend only on the absolute blast overpressure. The orientation of the head, i.e. the external auditory canal acting as a corridor for the passage of blast pressure, is an important consideration. Transitory sensorineural deafness (neurapraxia of the receptor organs) is very frequent. Degloving of the cartilage of the external ear may also occur.

#### Lung

Lung injuries carry the *highest morbidity and mortality*. The alveolar-capillary septum is the typical air-fluid interface where spalling may occur. Alveolar air is compressed by the positive pressure wave and, with the negative phase, the alveoli burst. Inertial shearing occurs at the attachments of the tracheobronchial tree.

The disruption of peripheral alveoli may lead to the formation of subpleural cysts and tearing of the visceral pleura. Pneumothorax, haemopneumothorax, pneumomediastinum and/or surgical emphysema may result.

The increase in air pressure in the alveoli, above that of the fluid pressure in the vascular tree, produces rupture of this membrane with intra-alveolar haemorrhage and oedema, and alveolar-venous fistulas; the negative pressure phase may induce systemic air emboli.



**Figure 19.4**

Alternating phases for lung haemorrhage and vascular air emboli.

Normally, the intravascular fluid pressure is greater than the air pressure in the alveoli. This intravascular pressure reacts less to the changes due to blast than the alveolar air.

With peak pressure, the alveolar-capillary membrane ruptures and intravascular fluid enters the alveolar space: fluid to gas phase causing "forced" haemorrhage and oedema.

With negative pressure, intra-alveolar air is pressed into the capillaries: gas to fluid phase causing "forced" air embolization.<sup>7</sup>

The resultant oedematous and haemorrhagic lungs (hepatization or "wet lung" syndrome) are stiff and heavy: up to 2 – 3 times their normal weight. As in blunt injury to the lungs, alveolar haemorrhage and oedema cause ventilation-perfusion disequilibrium (intrapulmonary shunt) and decreased lung compliance, resulting in hypoxia and greater effort to breathe.

Furthermore, the positive pressure wave can deform the bony thoracic cage causing fractures of the ribs that may lacerate the lungs or compress the lungs between the sternum and vertebral column resulting in direct pulmonary contusion, characterized by the haemorrhagic stripes on the lung surface.

#### Hollow viscera

Any perforation due to the direct effect of the pressure wave is usually immediate and most commonly affects the ileo-caecal region or colon.

Less common are delayed perforations that develop insidiously in stages owing to a process of intramural haemorrhage and/or mesenteric ischaemia, both leading to infarction, necrosis and gangrene of the affected site. Pathological studies on rats have shown the injury to begin in the mucosa and then migrate toward the serosa.<sup>8</sup> Necrosis begins 6 hours after injury and perforation after 48 hours, usually occurring between day 3 and 5 in human clinical studies. As a consequence, and unlike projectile injury, any serosal injury due to primary blast seen at operation indicates that the entire intestinal wall is involved and requires debridement and repair.

#### Solid organs

Ischaemia, infarction or haemorrhage often occur; complete rupture of the liver, spleen or kidney is rarely seen in survivors.

#### Musculoskeletal system

Brisance can fracture long bones; the blast wind that follows the shock wave then strips away the soft tissues. One possible result in victims close to the blast epicentre is traumatic amputation, which usually occurs at the upper third of the tibia. Abdominal evisceration is also seen. Massive soft-tissue wounds are frequent.

#### Eye

Rupture of the eye globe and open fracture of the orbital ridge are possible.

#### Head and central nervous system

Direct blast overpressure causes diffuse axonal injury, and coup-counter-coup injury as well as fractures of the skull. Petechial haemorrhages with brain oedema are seen. Cerebral vasospasm that can last for up to a month may occur and some authors have reported pseudoaneurysms of the cerebral vessels following the vasospasm.

Pathological changes of secondary neurodegenerative effects at the molecular and cellular levels may continue for hours or even days after exposure. Various metabolic



**Figure 19.5**

Traumatic amputation of the lower legs through the tibia.

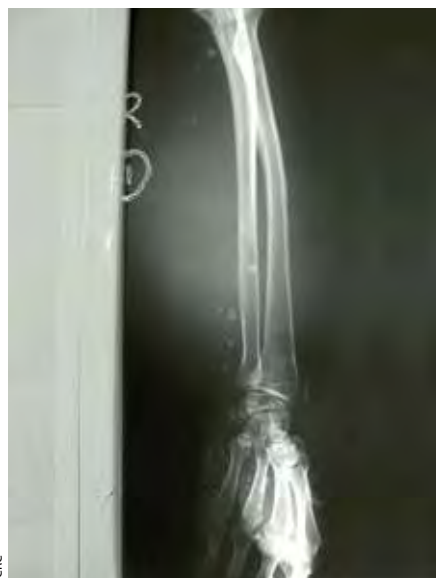<sup>7</sup> Adapted from Hill JF, 1979.

<sup>8</sup> Tatic V, Ignjatovic D, Jevtic M, Jovanovic M, Draskovic M, Durdevic D. Morphologic characteristics of primary nonperforative intestinal blast injuries in rats and their evolution to secondary perforations. *J Trauma* 1996; **40 (Suppl.)**: S94 – S99.

and neuroendocrine effects as demonstrated by certain biochemical markers have been observed.<sup>9,10,11</sup> Late residua have been reported in survivors with even mild brain trauma and can prove debilitating.

#### Autonomic nervous system

The blast wave can stimulate the pulmonary C-fibre receptors of the vagus nerve located in the alveolar septa, thus activating the “pulmonary defensive reflex” of a pronounced vagal state: a triad of apnoea, bradycardia and hypotension. The result is the paradoxical condition of profound shock with bradycardia, rather than compensatory tachycardia, as well as the absence of compensatory peripheral vasoconstriction. A loss of skeletal muscle tone is also a feature of this vagal nerve-mediated response, which can reach extreme levels of temporary flaccid or spastic paralysis.<sup>12,13</sup>



**Figure 19.6**  
X-ray showing glass shards in the tissues.

### 19.4.2 Secondary blast injury: fragment wounds

Projectiles may be primary fragments, derived from the casing or bomb contents, or secondary missiles: objects mobilized by the blast wind or arising from environmental debris (glass shards from shattered windows, wood splinters, soil and stones).

Fragment wounds within the radius of the primary blast effect result in more severe injuries; the cavitation effect described for projectiles is compounded by blast-driven debris and delayed thrombosis of small vessels.

### 19.4.3 Tertiary blast injury: blast wind

The blast wind can displace people, throwing them against objects, or mobilize large objects in the environment which then strike people, causing blunt trauma. Brisance and the blast wind can cause building collapse with subsequent entrapment and crush injuries as well as head trauma, traumatic asphyxia, fractures and spinal injury.

### 19.4.4 Quaternary or miscellaneous blast injury

The fireball of the explosion may reach 3,000° C causing flash burns; it may also set fire to the environment, as when a building goes up in flames. Most affected are the face and hands because clothing offers some protection, although it often also catches fire. The combination of blast effect and a burn injury affecting more than 30% body surface area is usually fatal.

The blast can let off toxic gases, including carbon monoxide, leading to asphyxia. Inhalation of dust, smoke and other contaminants can also affect respiration.

## 19.5 Clinical presentations and management

Most patients suffer from a combination of the four blast injury mechanisms. The clinical presentation and basic management of soft-tissue fragment wounds are covered in Chapters 10 and 11 and those of specific anatomic regions are the subject of the remaining chapters of this Volume. This section describes only primary blast injury. Pure primary blast injury is rare, except from explosions in an extremely confined space, as well as underwater and fuel-air explosions. The environment and the particulars of the event should alert the surgeon to the possibility of primary blast injury.

9 Cernak I, Savic J, Ignatovic D, Jevtic M: Blast injury from explosive munitions. *J Trauma* 1999; **47**: 96 – 104.

10 Cernak I, Savic J, Zunic G, Pejnovic N, Jovanikic O, Stepic V. Recognizing, scoring, and predicting blast injuries. *World J Surg* 1999; **23**: 44 – 53.

11 Cernak I, Wang Z, Jiang J, Bian X, Savic J. Ultrastructural and functional characteristics of blast injury-induced neurotrauma. *J Trauma* 2001; **50**: 695 – 706.

12 Guy RJ, Kirkman E, Watkins PE, Cooper GJ. Physiologic responses to primary blast. *J Trauma* 1998; **45**: 983 – 987.

13 Irwin RJ, Lerner MR, Bealer JF, Mantor PC, Brackett DJ, Tuggle DW. Shock after blast wave injury is a vagally mediated reflex. *J Trauma* 1999; **47**: 105 – 110.

### 19.5.1 General concussion syndrome: resistance to resuscitation

Russian surgeons in Afghanistan and, more recently, US surgeons in Iraq and Afghanistan have described patients with mixed patterns of blast injury, largely due to anti-tank and anti-personnel landmines in the first case and improvised explosive devices in the latter. Separated by over twenty years, the clinical descriptions are eerily similar.

The condition manifests itself clinically as haemorrhagic shock that is resistant to aggressive fluid resuscitation after haemorrhage control. Hypotension may be constant or recurrent after a temporary positive response, but haemodynamic stability cannot be maintained. Mortality is high.<sup>14</sup>

The cause has been ascribed to a combination of barotrauma to the central and autonomic nervous systems and hormonal and metabolic changes, including the inflammatory cascade. The condition may be so severe that some authors have spoken of a “general concussion syndrome”.<sup>15 16</sup>

### 19.5.2 “Shell shock” and the “bewildered” walking wounded

Survivors of the sudden flash, sonic boom and neural barotrauma of an explosion can experience what was once called “shell shock”. Wind of shot, *vent du boulet*, soldier’s heart, combat fatigue, reflex paralysis, air concussion, shell concussion, blast concussion,<sup>17</sup> are all terms that were used in the past to describe similar conditions – nowadays they would be considered extreme forms of PTSD.

The patient appears disorientated and dazed and does not respond well to questions during the clinical examination in spite of having an intact eardrum. However, mild blast neurotrauma may also be combined with a defect in hearing. In a civilian population subjected to an isolated bombing event there is probably also a subjective psychological element of horror, fear and disorientation – “psycho-emotional shock” – in addition to physiological somatic changes.

Bradycardia and hypotension may set in and persist in the absence of an obvious cause. Severe cases can go into convulsions or paralysis, including paraplegia. A possible extreme vagal state may even be falsely diagnosed as death: very slow pulse, unrecordable blood pressure, very slow respiration or even absence of respiratory effort.

Most such signs and symptoms are usually transient and resolve in minutes to hours after exposure. Observation for four to six hours after blast exposure is usually sufficient. Management is conservative and supportive: maintaining good oxygenation and observation of the patient for any signs of increased intracranial pressure. Physical effort should be minimal during recuperation with a gradual return to everyday activities; treatment is symptomatic, e.g. paracetamol for headache. Long-term neurological and psychological effects are common.

The incidence of mild blast neurotrauma is probably greatly underestimated.

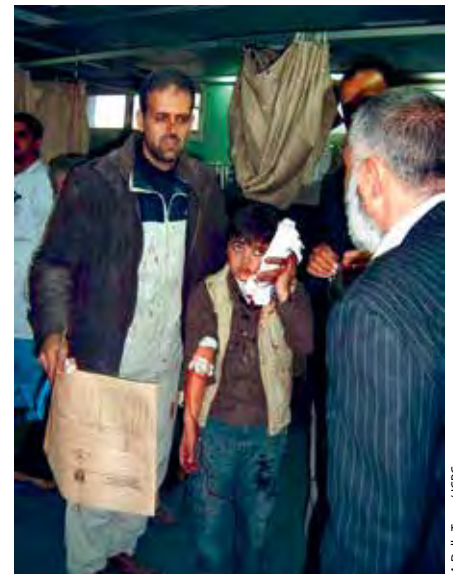

Figure 19.7

The walking wounded: dazed, disoriented, and frightened.

M. Della Torre / ICRC

- 14 Nelson TJ, Clark T, Stedje-Larsen ET, Lewis CT, Grueskin JM, Echols EL, Wall DB, Felger EA, Bohman HR. Close proximity blast injury patterns from improvised explosive devices in Iraq: a report of 18 cases. *J Trauma* 2008; **65**: 212 – 217.
- 15 Nechaev EA, Gritsanov AI, Fomin NF, Minnullin IP, eds. *Mine Blast Trauma: Experience from the War in Afghanistan*. St Petersburg: Russian Ministry of Public Health and Medical Industry, Vreden Research Institute of Traumatology; 1995. [English translation: Khlunovskaya GP, Nechaev EA. English publication: Stockholm: Council Communications; 1995.]
- 16 Bryusov PG, Shapovalov VM, Artemyev AA, Dulayev AK, Gololobov VG. *Combat Injuries of Extremities*. Moscow: Military Medical Academy, GEOTAR; 1996. [Translation by ICRC Delegation Moscow]
- 17 Various denominations and references cited in Clemedson C-J. Blast injury. *Physiol Rev* 1956; **36**: 336 – 354.

## 19.6 The ear and ruptured tympanum

Almost all persons closely exposed to a significant blast suffer functional perceptive deafness and some dizziness at the time of the explosion; the inner ear can suffer damage at a pressure insufficient to rupture the tympanum. Most recover rapidly with a return to normal hearing within a matter of minutes or hours.

Apart from transient sensorineural deafness and dizziness, perforation of the tympanic membrane is the most common organic injury and occurs at the lowest blast pressures.

It is rare for a casualty to have an intact tympanum yet suffer other serious injury. An otoscopic examination on its own, however, is insufficient to rule out the possibility. Consequently, the otoscopic examination must be assessed *in correlation with other signs and symptoms*, particularly of the respiratory system, to determine which patients require continued observation in hospital.

Please note:

In a mass casualty situation, amidst the inevitable confusion, the performance of an otoscopic examination is not a simple procedure to carry out in the emergency room. The ear should be kept clean and dry until proper assessment is possible.

An otoscopic examination on its own is insufficient to rule out other serious injury, but should be conducted for all blast victims including the unconscious.

Rupture of the tympanic membrane is manifested by deafness, tinnitus, otalgia, and ear discharge. The surgeon may have to resort to writing notes in order to communicate with the patient.

### 19.6.1 Management

Dazed but stable patients with a ruptured eardrum do not require a chest X-ray, providing there are no respiratory symptoms or other clinically significant injuries. They should however be observed for four to six hours.<sup>18</sup>

Initial treatment of a ruptured tympanic membrane is conservative (see Chapter 28). Most heal spontaneously.

## 19.7 Blast lung

The lungs are the second most commonly injured organ following exposure to primary blast, but the leading cause of late blast mortality. The diagnosis of blast lung injury (BLI) is made on a clinical basis and confirmed by chest X-ray.

### 19.7.1 Clinical presentations

There are three major clinical presentations of *respiratory insufficiency* in blast victims.

1. Severe respiratory distress with bloody, frothy sputum and rapidly deteriorating level of consciousness shortly after exposure, often within minutes.

The condition is immediately life-threatening and the prognosis grave whatever the treatment. In a mass casualty situation where resources are limited, these patients are classed as “expectant” (Category IV).

2. Progressive respiratory insufficiency developing insidiously over time, often with a full-blown picture only after 24 – 48 hours, and resembling pulmonary contusion from blunt trauma.

18 Ashkenazi I, Olsha O, Alfici R. Blast injuries: letter. *N Engl J Med* 2005; **352**: 2651 – 2652.



The patient may present at first with mild haemoptysis or persistent cough, and progresses to dyspnoea and tachypnoea with air hunger and cyanosis, tachycardia and hypotension. Moist crepitations are heard in both lung fields. Blood may be found in the endotracheal tube or naso-gastric tube aspirate and petechial haemorrhages seen in the walls of the larynx. Particular attention should be paid to the oxygen saturation by pulse oximetry; a decrease is an early sign of BLI. The condition can rapidly evolve to a fatal outcome and is the major cause of delayed deaths.

3. Late development of acute respiratory distress syndrome (ARDS) due to a mixture of physiological insults from multiple pathologies: primary blast, inhalation of smoke and toxic gases, hypoxia, haemorrhage and resuscitation with large quantities of crystalloids and coagulopathy, sepsis, fat embolism, etc.

Signs of pneumothorax, haemothorax, pneumomediastinum (retrosternal crepitus on pressure) and surgical emphysema should be sought in all cases.

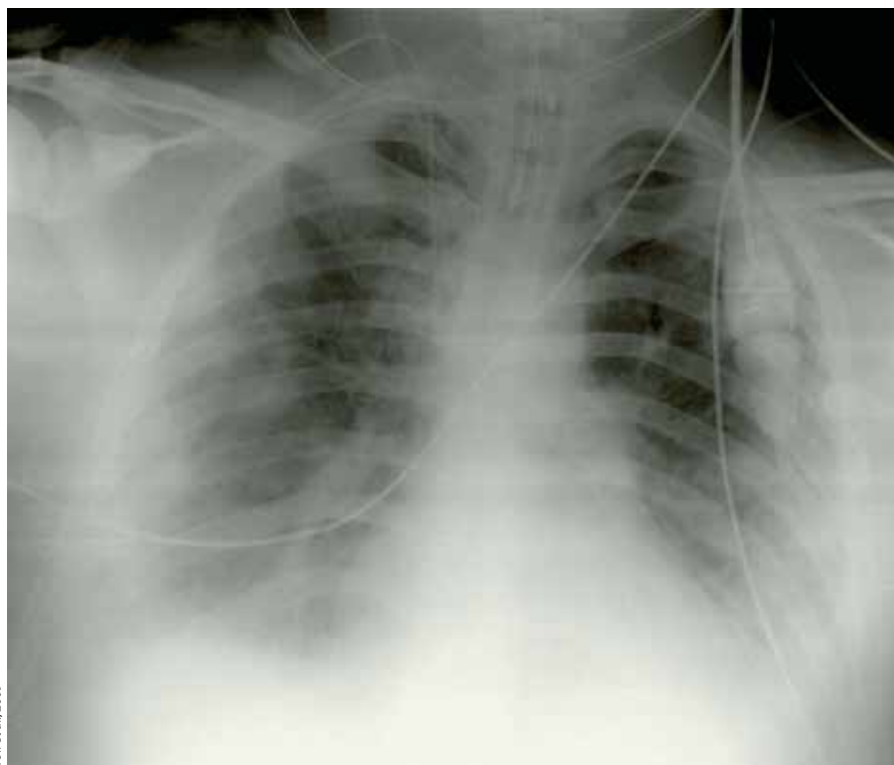
### 19.7.2 Chest X-ray and pulse oximetry

Any patient subjected to explosive blast and suffering the slightest respiratory sign or symptom, should have a radiograph taken of the chest and be held under observation for 4 – 6 hours, including pulse oximetry.

The first X-ray may be clear because clinical symptoms appear before radiological signs. Patients with a normal X-ray, but still showing clinical signs or symptoms of pulmonary effects after 6 hours, should have a repeat X-ray performed and remain hospitalized under observation.

The slightest respiratory sign or symptom calls for a chest X-ray and observation for six hours, including pulse oximetry.

Positive X-ray findings are usually observed within 4 hours if there is BLI and show as pulmonary opacities: infiltrates that are classically described as a “bilateral butterfly” pattern. Typically, these reach a maximum at 24 – 48 hours and resolve slowly over 7 days in survivors. Progression of infiltrates after 48 hours indicates ARDS or pneumonia.



**Figure 19.8**

Bilateral “butterfly” pulmonary infiltrates : central consolidation, compatible with lung contusion is seen in the chest X-ray.

### 19.7.3 Assessment of patients with suspected lung injury

Of the three clinical presentations mentioned above, immediate respiratory distress and ARDS are self-evident. The diagnostic problem lies with the insidious development of BLI and, therefore, begs the question of how long to keep patients under observation.

The real world scenario of actual time elapsed since exposure to the blast resembles the following picture.

1. Casualties of an explosion are transported to the hospital, and reach it with some delay.
2. Confusion in the emergency reception is common during the triage of mass casualties and results in more time passing by.
3. All dazed but stable patients without clinically significant injury are classed Category III and sent off to a holding area, with further passage of time.
4. These patients usually have minor wounds and bruises; many have sensorineural deafness or even a ruptured eardrum. They still need to be examined properly, which results in further delay. They are often also frightened and require some calming down before discharge can be considered.

By this time, the scenario is well into the first couple of hours after exposure, if not more. Any patient who does have pulmonary injury, and who did not have symptoms originally, will start presenting some symptoms before reaching the point of discharge. Re-examination in the holding area will send this patient into the hospital.

### 19.7.4 Patient management

Not all patients suffering from BLI require intubation and mechanical ventilation; only severe cases presenting respiratory distress or progressing insufficiency with hypoxaemia do. Treatment of blast lung is challenging even with the aid of mechanical ventilation; high ventilation pressures increase the risk of air embolism or tension pneumothorax and should be avoided. If mechanical ventilation is available, the simplest recommended protocol is permissive hypercapnoea, and high-frequency, high-oxygen flow by means of a small naso-gastric tube inserted into the trachea, made easier by a tracheostomy. Tidal volumes should be decreased (5 – 7 ml/kg instead of 8 – 10) and peak airway pressure kept low.

Any pneumo- or haemothorax should be treated immediately; some surgical teams introduce bilateral prophylactic chest tubes.

The usual situation when working with limited resources is that intubation with mechanical ventilation is not available and only supportive treatment can be instituted:

- supplemental oxygen;
- suctioning of blood and secretions;
- tracheostomy in severe cases to facilitate suctioning, which also reduces the effort of breathing;
- meticulous fluid balance to ensure tissue perfusion, while keeping i.v. crystalloids to a minimum to decrease lung oedema;
- control of chest-wall pain if present – i.v. analgesics, intercostal nerve block;
- regular change of position, including prone; and
- good chest physiotherapy.

Positioning of the patient can be done as a clinical test. The lateral position with the unaffected or less affected side up allows for better ventilation and less bleeding into the good lung. On the other hand, gravity may augment the blood flow to the lower injured lung, increasing the bleeding and oedema. The test is performed with the good side up first: if the condition of the patient is improved, it is maintained. If not, the position is reversed.

A dilemma arises in patients with BLI complicating other injuries accompanied by haemorrhage and shock. The treatment protocols tend to contradict each other.

In this case, hypotensive resuscitation may be employed since excess i.v. fluids tend to increase pulmonary oedema, but only for a short period of time (see Section 8.5.4). Prolonged hypotensive resuscitation, over 2–3 hours, has a very negative outcome and should be avoided.<sup>19</sup>

In the absence of other life-threatening injuries, any surgery requiring general anaesthesia should be postponed for 24 – 48 hours until the patient's condition has stabilized.

Delay general anaesthesia for 24 – 48 hours.

Local, regional or spinal anaesthesia, or ketamine without muscle relaxation and intubation is advised. Where resources are limited, the only operating theatre ventilation to be used is “bagging” the patient, gently.

In case of general anaesthesia, resort to gentle bagging of the patient.

The usefulness of corticosteroids has not proven conclusive and is not recommended by ICRC surgeons.

## 19.8 Arterial air embolism

Systemic air emboli to the brain and myocardium are rapidly fatal. The diagnosis is usually missed. In survivors, sudden death may occur, especially at the initiation of positive pressure ventilation, whether manual or mechanical.

Rupture of the alveoli and alveolar-venous shunts may cause systemic air embolism.

Blunt or barotrauma to the head must be excluded before pronouncing a diagnosis of air embolism, and air bubbles in the retinal vessels sought. Embolism may also affect the spinal cord or intestine.

Should the diagnosis be made, some authors recommend placing the patient in the left lateral recovery position, tilted 45°, with the legs higher than the head. This position is described as resulting in the trapping of any air in the right side of the heart and distributing any air bubbles to the lower extremities rather than to the head.

If air embolism does not kill, then, according to a few published reports, the cardiac and neurological effects gradually resolve.

## 19.9 Visceral injury

Rupture of solid organs (liver, spleen or kidney, testicles) from primary blast injury is rarely seen in surviving patients. Far more common presentations are secondary (projectile) or tertiary (blunt and crush) blast injuries.

Children are more susceptible to abdominal blast injury than adults. Not only is the abdominal wall smaller and thinner, offering less protection, but the liver and spleen are proportionately larger organs and more vulnerable to blast and blunt trauma.

Immediate perforation of the intestine due to primary blast offers the clinical picture of an acute abdomen. The main clinical problem is *late perforation with delayed*

19 Garner J, Watts S, Parry C, Bird J, Cooper G, Kirkman E. Prolonged permissive hypotensive resuscitation is associated with poor outcome in primary blast injury with controlled hemorrhage. *Ann Surg* 2010; **251**: 1131 – 1139.

*diagnosis*; in addition, the existence of serious injuries to other body regions may distract the clinician.

With open air blast, the ileo-caecal region is most often affected. Any serosal injury from blast trauma seen on laparotomy indicates full-thickness pathology of the intestinal wall and requires debridement and repair. In the colon and rectum, diversion is probably a wiser choice because of the risk of thrombosis in the intestinal wall following blast injury.

*Abruptio placentae* has been reported following explosions. The placenta is separated from its uterine attachment by a shearing effect. Pregnant women exposed to blast should be admitted for 24 hours for monitoring of the foetus and the occurrence of any bloody vaginal discharge.

## 19.10 Eye and maxillo-facial injuries

Rupture of the eye globe, serous retinitis, retinal detachment, and hyphaema have all been reported, as well as air embolism to the central artery of the retina. Fractures of the orbit, with possible injury to the optic nerve, as well as to the frontal and maxillary paranasal sinuses are possible. Secondary injury of the eyes and eyelids from shattered glass is far more common.

Treatment follows standard ophthalmology protocols according to the lesion (see Chapter 29).

A possible complication of eye contusion from blast is the delayed onset of cataract, usually revealing itself after some weeks.

## 19.11 Other injuries

Burns incurred in combination with primary blast effects are much more serious and have a worse prognosis than those without. Patients suffering burns affecting more than 30% body surface area and primary blast injury rarely survive, even in specialized centres that commonly deal with even more serious burn injuries. Circumferential burns may require a full fasciotomy and not just escharotomy (see Section 15.6.1).

Combined blast and fragment wounds are more liable to sepsis and thrombotic phenomena. This is particularly true of anti-personnel landmines (see Chapter 21).

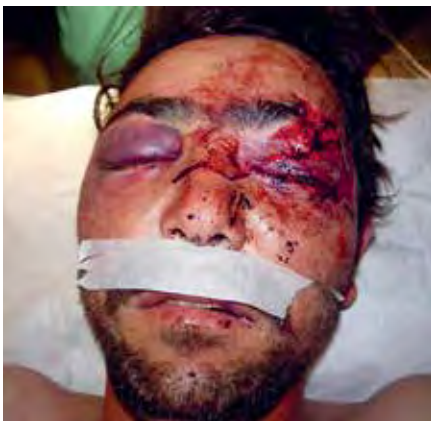## 19.12 Removal of unexploded ordnance

An exceedingly rare but disconcerting case is the patient presenting with a retained live munition. A projectile has hit and penetrated the body, but not exploded. The cases reported in the literature usually deal with mortar or RPG grenades with the tip in the body and the rest of the munition protruding out. The patient may be moribund or not – the projectile may not have struck a vital organ.

It is obvious that only specifically qualified people are capable of dealing with the munition itself. Such specialists have presented an appropriate protocol.<sup>20</sup> The hospital staff must create the conditions for the safe removal of the projectile while treating the patient and protecting themselves.

The following steps are recommended.

- Local military authorities must be notified.
- The munition itself should not be touched or manipulated in any way.



F. Piant / ICRC

**Figure 19.9**  
Trauma to the brain, orbit and eye globe.

20 Lein B, Holcomb J, Brill S, Hetz S, McCrory T. Removal of unexploded ordnance from patients: a 50-year military experience and current recommendations. *Mil Med* 1999; **164**: 163 – 165.

- In a mass casualty situation, such patients should be put in the expectant category (IV) and moved to an isolated part of the hospital.
- An *ad hoc* operating theatre should be organized in a secluded and protected part of the hospital to keep to a minimum any damage in the event of premature detonation. The ambient temperature should be kept constant and the theatre located away from any source of vibration, such as an electric generator.
- The walls of the theatre must be lined with sandbags.
- Staff should use body armour if available.
- Manipulation and movement of the patient is kept to a minimum, closed cardiac massage should not be employed.
- The only diagnostic imaging to be used is plain radiography.
- Ketamine, regional or spinal anaesthesia should be used. Oxygen should be excluded from the theatre.
- Electrocautery, a defibrillator or any other electrical equipment should not be used.
- The munition should be removed *en bloc* with the surrounding tissues. The surgeon should dissect without metal instruments coming into contact with the munition.
- Once the round is removed, the patient can be transferred to a more appropriate operating theatre if necessary for completion of the operation.
- Depending on the type of munition, the specialized military personnel deal with it in place or remove it elsewhere.

#### Summary of major clinical considerations

- Serious primary blast injuries are uncommon in survivors; fragmentation injuries predominate and most patients have relatively minor wounds.
- Nonetheless, primary blast injury should be looked for and excluded in all persons exposed to blast.
- Many patients suffer from combined blast trauma due to different blast effects; fragment wounds incurred within the radius of primary blast are more severe.
- Perforation of the tympanic membrane is common, but not indicative of the presence of other serious injuries.
- The unresponsive and confused patient usually cannot hear, and may or may not have suffered head injury.
- The diagnosis of blast lung is based on clinical observations and confirmed by plain chest X-ray.
- Abdominal primary blast injury may present as an acute abdomen, or be delayed until the onset of peritonitis.
- The occurrence of mild traumatic brain injury due to primary blast is underestimated and many survivors suffer long-term psychological and neurological sequelae similar to PTSD.



## **Chapter 20**

# **INJURIES DUE TO ANTI-TANK MINES**

20.	INJURIES DUE TO ANTI-TANK MINES	
20.1	Introduction	45
20.2	Epidemiology	45
20.3	ATM effects on an armoured vehicle	46
20.3.1	Non-penetration of the armour	46
20.3.2	Penetration of armour	47
20.4	Clinical presentations	47
20.4.1	Injuries without penetration of the armour	47
20.4.2	Injuries with penetration of the armour	48



## Basic principles

For people inside a vehicle hitting an anti-tank mine the type and severity of injuries depends on whether the armour of the vehicle is penetrated or not.

All kinds of fractures, as well as spine injuries, may be incurred.

People travelling in an open vehicle such as a lorry – a common mode of civilian transport in low-income countries – that hits an anti-tank mine may suffer fractures to the legs or be thrown out onto the ground.

## 20.1 Introduction

An anti-tank mine contains a large amount of explosive, 7 kg and more, and requires a larger weight (110 – 350 kg) to set off the explosion than an anti-personnel mine. If the fuse is damaged the pressure required may be less. Some are manufactured purposefully to penetrate armour as described in Part A.5.2.

Unlike the deployment of anti-personnel mines, the use of anti-tank landmines is not prohibited, but is nonetheless constrained by treaty.<sup>1</sup>



Figure 20.1

Explosion of an anti-tank mine on a road during mine clearance.



Figure 20.2

Collection of anti-tank mines.

## 20.2 Epidemiology

Most epidemiological studies do not differentiate between anti-tank and anti-personnel mines when referring to “injured by mines”. In addition, reports dealing with the major tank battles of history do not, and probably cannot, discriminate between the casualties seen when armoured vehicles were hit by an anti-tank mine, a cannon shell, rocket-propelled grenade (RPG) or “Molotov cocktail”.

One of the very few reports that do make the distinction between ATM and APM comes from Kuito, Angola, in 1995.<sup>2</sup> Although APM accounted for the vast majority of incidents, injuring more people in total, the few ATM accidents were much deadlier. Greater explosive power and large numbers of passengers account for the greater number killed and injured by a single ATM incident than by an APM.

1 Protocol on Prohibitions or Restrictions on the Use of Mines, Booby-Traps and Other Devices (Protocol II). Geneva, 10 October 1980, as amended on 3 May 1996.

2 Chaloner EJ. The incidence of landmine injuries in Kuito, Angola. *J R Coll Surg Edinb* 1996; **41**: 398 – 400.

### 20.3 ATM effects on an armoured vehicle

An armoured vehicle is constructed with thick, reinforced sides and undercarriage. A tank is the prime example. Armoured personnel carriers have less armour protection, and even the metal body of a civilian vehicle can be regarded as a type of “armour”, although a weak one. When a vehicle runs over an ATM, which is usually buried, or is struck by a roadside bomb or an improvised explosive device (IED), which usually results in a directed open-air explosion, a number of phenomena come into play. Whether the armoured shield is penetrated or not is primordial in determining the type and extent of injuries to the crew members.

Penetration of the armour is the single most important factor in determining the lethality and extent of injuries to persons inside a tank after an ATM explosion.

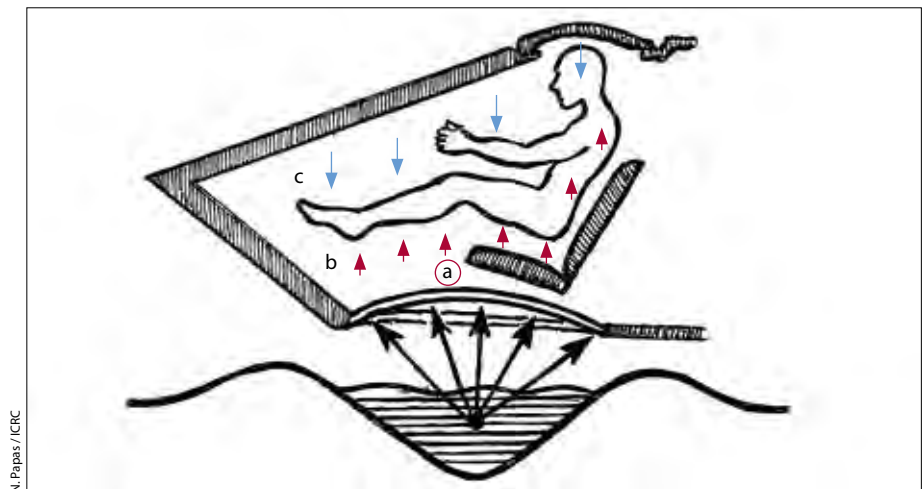
#### 20.3.1 Non-penetration of the armour

The shock wave of an ATM explosion does not enter the passenger cabin, it simply reflects off the armour or at the soil-air interface of the buried explosion. The detonation does result in two distinct physical phenomena that both transmit kinetic energy to the vehicle. The rapid expansion of the explosion gases imparts an impulse to the vehicle that can deform or even rupture the floor or result in the destruction of the various parts of the vehicle. The explosion also excavates a crater; a large quantity of soil is then projected at a very high velocity towards the vehicle imparting another impulse and causing its rapid acceleration. In addition, loose contents of the compartment are accelerated which turns them into secondary missiles.

Figure 20.3

Blast impulse and vehicle acceleration causing injuries within a vehicle striking an anti-tank mine.

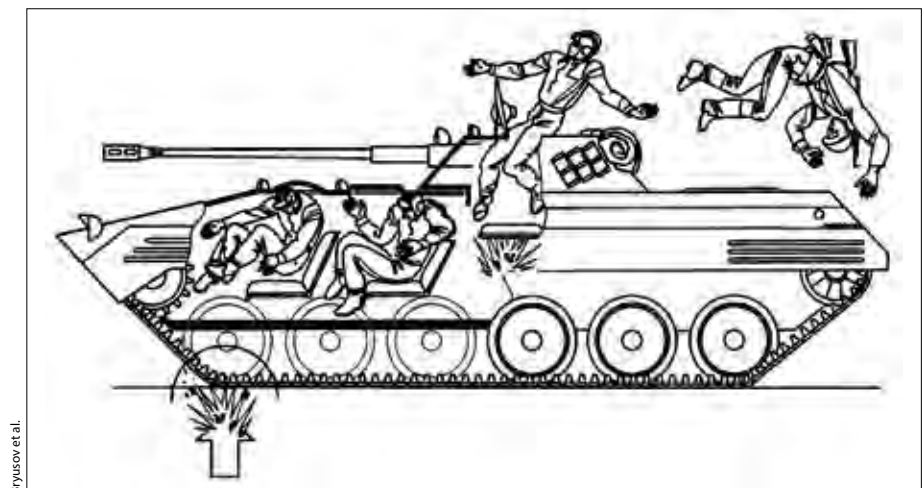
- a. Deformation of the floor of the vehicle.
- b. Parts of the body submitted to the direct transmission of the blast impulse and axial load to the bones of the skeleton (→).
- c. Parts of the body that strike the interior of the passenger compartment upon acceleration of the vehicle – acceleration-deceleration effects that are similar to what occurs in a motor vehicle crash (→).



N. Papas /CRC

Figure 20.4

Acceleration of the vehicle may cause passengers to be flung against the top or sides of the compartment and any passengers riding on top or in an open entry hatch may be thrown out onto the ground.



Bryusov et al.

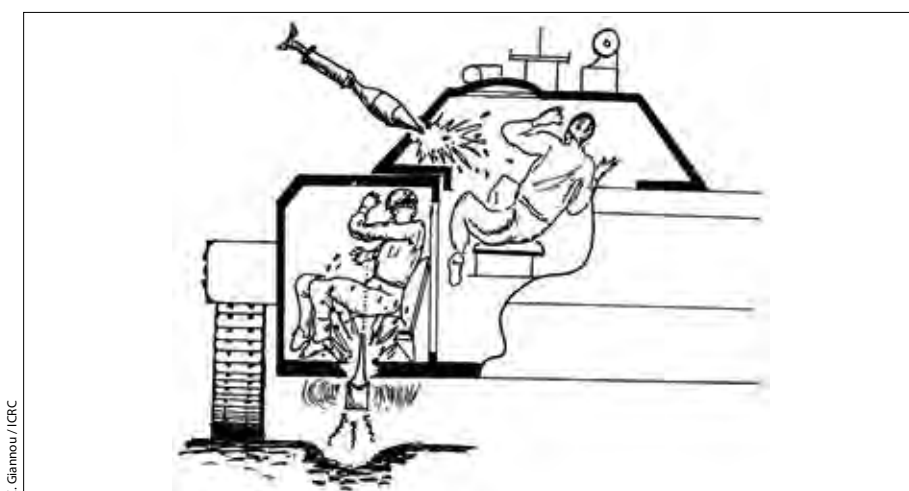
The intense vibration of the metal carriage of the vehicle amplifies the noise of the explosion, which may cause acoustic trauma. Damage to the fuel tank may result in its ignition and explosion.

Attempts to decrease these effects include placing sand bags on the floor of the vehicle or reinforcing it, and wearing body armour.

### 20.3.2 Penetration of armour

Armour undoubtedly confers a great deal of protection. However, when it is penetrated, the results are more complex. Besides all the effects described under non-penetration, primary fragments from the mine and secondary fragments from the armour itself turn into projectiles and the rupture of the armour allows hot gases to penetrate the passenger compartment. The effects are compounded by possible ignition and explosion of the ammunition carried by the vehicle. However, even with penetration of the armour, primary blast effects within the passenger compartment are minimal.

In the case of an armour-piercing mine or projectile there is, in addition, a high-velocity and high-temperature "jet flow" comprising gases, melted metal, flames and the toxic by-products of the explosion. The temperature of this jet flow may reach 900 – 1,000° C or more.



**Figure 20.5**

Penetration of the armour: the same effects result from a rocket-propelled grenade or a shaped-charge anti-tank mine breaching the armour: fragments from the armour and weapon, residual jet material from the weapon. The difference is one of degree.

#### Please note:

Similar considerations apply to a ship hitting an underwater mine. The impulse is propagated through an armoured protective shield into an enclosed space: the classically described "deck slap". Penetration, again, multiplies the effects.

## 20.4 Clinical presentations

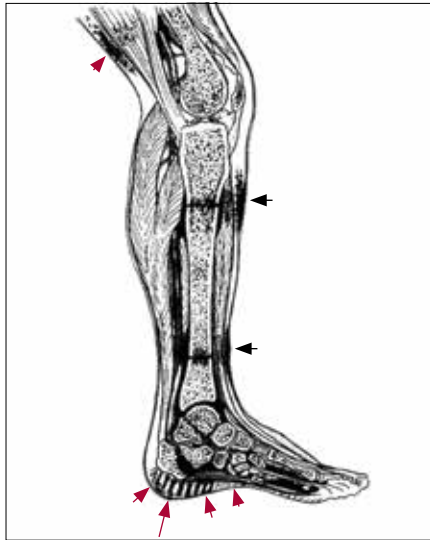
Tertiary blast effects predominate with non-penetration of the armour. Only penetration of the armour by an ATM can cause all four types of blast injuries to a greater or lesser extent.

### 20.4.1 Injuries without penetration of the armour

Victims inside a vehicle that has not been penetrated suffer particularly from closed and open fractures of the limbs, skull and spine.

Fractures of the limbs present a wide spectrum of severity: about half are closed and half open, and one-third are bilateral. Of particular note is the classically-described "*ped de mine*": the foot is transformed into an intact bag of skin containing the shattered bones of the foot.<sup>3</sup> These injuries tend to primarily affect the calcaneus.

<sup>3</sup> Ramasamy A, Hill AM, Phillip R, Gibb I, Bull AMJ, Clasper JC. The modern "deck-slap" injury – calcaneal blast fractures from vehicle explosions. *J Trauma* 2011; **71**: 1694 – 1698.



Nechter et al.

Figure 20.6

Pathogenesis of "pied de mine" injury.

- ➔ zones of primary direct impulse transfer and axial load.
- ➔ zones of indirect shearing of bone.

Although these injuries are usually described in relation to military vehicles, they have also been seen in a civilian context. For instance, among the 57 passengers travelling in pick-up trucks in Namibia, all wearing footwear and standing upright when their vehicle hit an ATM, injuries included 22 closed and 29 open calcaneal fractures.<sup>4</sup> The same may happen to passenger-carrying lorries, a commonly-used mode of transport in low-income countries; the victims are frequently thrown out of the vehicle and onto the ground.

In a suicide car bomb attack in Karachi, Pakistan, a vehicle was driven into a bus, hitting the side and undercarriage. The shock wave was transferred upwards into the confined space through the open windows resulting in a large number of deaths. Amongst the survivors, almost all suffered from a ruptured tympanum owing to barotrauma and the fracture-dislocation of the calcaneus and other bones of the feet and ankles owing to the impulse transfer.<sup>5</sup>

Civilian vehicles also hit anti-tank mines.

In addition to various limb injuries, the impulse transfer and upward acceleration of the vehicle after an ATM explosion can create an axial spinal load that results in lumbar burst fractures, with or without paraplegia, or a fracture-dislocation of the cervical vertebrae, usually fatal.

Other injuries may include penetrating wounds due to loose objects becoming secondary missiles and acoustic trauma from the high intensity of noise.

#### 20.4.2 Injuries with penetration of the armour

Penetration of tank armour is frequently lethal because the resulting ignition of ammunition and fuel carbonizes the bodies of the occupants. This is especially the case with an armour-piercing munition and the resultant high temperature "jet flow". Otherwise, primary- and secondary-fragment injuries predominate.

##### Summary of blast effects in an armoured vehicle hitting an anti-tank mine

- Without penetration of the armour, the main cause of injury is impulse transfer and displacement of persons inside the vehicle.
- With penetration, fragments from the armour are the main cause of injury.
- Loose objects can cause penetrating injuries.
- High-intensity sound waves can cause acoustic trauma.
- Damage to fuel tanks or ammunition can cause burns.

4 Jacobs LGH. The landmine foot: its description and management. *Injury* 1991; **22**: 463 – 466.

5 Zafar H, Rehmani R, Chawla T, Umer M, Mohsin-e-Azam. Suicidal bus bombing of French nationals in Pakistan: physical injuries and management of survivors. *Eur J Emerg Med* 2005; **12**: 163 – 167.





## **Chapter 21**

# **INJURIES DUE TO ANTI-PERSONNEL MINES**

21.	INJURIES DUE TO ANTI-PERSONNEL MINES	51
21.1	Introduction: the humanitarian challenge	53
21.2	Mechanism of injury	54
21.2.1	Blast mines	54
21.2.2	Fragmentation mines	54
21.3	Clinico-pathological patterns of injury	55
21.3.1	Pattern 1 injury	55
21.3.2	Pattern 2 injury	56
21.3.3	Pattern 3 injury	56
21.4	Epidemiology	57
21.4.1	Definitions, classifications and data collection	57
21.4.2	Consequences of the tactical use of landmines	57
21.4.3	Effects on civilians post-ceasefire and post-conflict	58
21.4.4	Mortality	59
21.4.5	Survivors	60
21.4.6	Hospital resources and workload	60
21.5	Blast mine injury: pathogenesis and clinical implications	60
21.5.1	The effect of body size and footwear	62
21.5.2	More proximal lesions	63
21.6	Clinical presentation and management	64
21.6.1	First aid	64
21.6.2	Emergency room care	65
21.7	Surgical management of pattern 1 traumatic amputations	66
21.7.1	Preparation of the patient	66
21.7.2	Level of amputation and surgical technique	66
21.7.3	Classical approach to amputation	67
21.7.4	“Umbrella effect” and myoplastic amputations	67
21.7.5	Other operative considerations and DPC	68
21.7.6	Other pattern 1 injuries	68
21.8	Special features of mine-blast injury to the foot	68
21.9	Special features of mine-blast injury to the hand: pattern 3	69
21.10	Surgical management of pattern 2 injuries	69
21.11	Physical and psychological rehabilitation	70
21.12	Conclusion: the humanitarian challenge	70
	ANNEX 21. A Humanitarian repercussions of landmines	71



## Basic principles

The widespread use of anti-personnel mines has resulted in a humanitarian challenge for entire societies.

The victims are often civilians and many casualties occur well after the conflict is over.

Anti-personnel mines produce three patterns of injury.

Blast mines are designed to cause a traumatic amputation.

The final level of amputation might be much higher than what is seen initially.

Proper debridement and delayed primary closure is necessary for good healing.

Physiotherapy is an essential part of the treatment and must start immediately post-operatively.

Physical and psychological rehabilitation and life-long provision of artificial limbs is necessary for the socio-economic integration of the victims.

## 21.1 Introduction: the humanitarian challenge

“The worldwide epidemic of landmine injuries is a classic example of a pathology that is not simply biological in scope; like all epidemics, in their causes and consequences, it is a social, economic, health, and political event, which particularly targets the innocent, the weakest, and the least prepared.”<sup>1</sup>

Anti-personnel mines (APM) are a distinct subset of explosive devices and are amongst the most noxious of weapons systems. The wounds they cause are horrendous, and their effects reach far beyond the individual victim: they have profound repercussions on public health and society at large.

Even if soldiers attempt to respect the fundamental rules of international humanitarian law governing the conduct of hostilities, the intrinsic nature of anti-personnel mines leads to excessive suffering and indiscriminate effects. Anti-personnel mines do not distinguish between civilians and combatants. They do not obey orders to cease and desist; do not respect ceasefires, peace treaties, post-conflict reconciliation or democratic elections.

“The indiscriminate use of landmines does not gain any durable military advantage and does not obey the principles of military necessity or opportunity.”

Salim Ahmed Salim, Secretary-General of the Organization of African Unity

The humanitarian consequences of the deployment of anti-personnel mines in contemporary warfare are widespread. Landmines render whole regions useless for human habitation and activity, causing population displacement and demographic pressures that destabilize neighbouring regions. As many small mines are water resistant, cleared areas are often re-polluted by floating mines during floods or the rainy season. Their presence frequently compromises post-war reconstruction and development in societies that all too often are already desperately poor.

In some countries, they kill and injure more civilians – women fetching water, children gathering firewood, pastoralists and farmers at work in their fields – than combatants, and continue to do so long after a ceasefire. Caring for the victims of anti-personnel mines challenges every part of a public health care system and the problem is most acute in the countries least able to bear the burden. Although the Mine Ban Convention provides for mine clearance and medical assistance, much must still be accomplished



P. Dutoit / ICRC



G. Diffident / ICRC



ICRC

Figures 21.1.1 – 21.1.3  
Landmines contaminating civilian environments.

<sup>1</sup> Giannou C. *The Worldwide Epidemic of Landmine Injuries*. Geneva: ICRC; 1995.

in this regard and many of the challenges of the humanitarian consequences of APM remain. The humanitarian repercussions of landmines are detailed in Annex 21.A.

This chapter is a detailed elaboration of Section 3.1.3.

## 21.2 Mechanism of injury

An anti-personnel mine is a small bomb, containing between 8 and 500 g of explosive and, by definition, is set off by the victim. It is conceived as an “anti person” weapon and comes in two main types: blast and fragmentation. The main mechanisms of injury are the primary blast effect, penetrating fragments, and the thermal reaction; exactly what can be expected from a small explosive device.

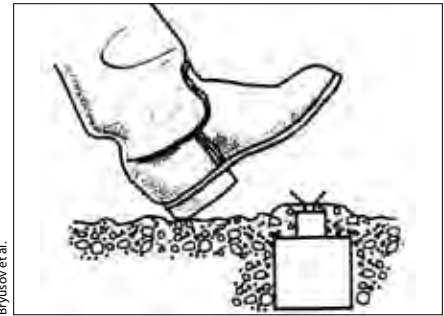
### 21.2.1 Blast mines

Blast mines are usually buried or laid on the surface of the ground and are activated by contact with a pressure plate. The casing is plastic, metal or wood. Blast APM are designed so that their detonation causes at least a foot injury in an infantryman wearing a combat boot or bursts the tyre of a vehicle. The great majority are industrially manufactured; some armed groups have produced improvised or “home-made” mines. Injury is caused by what amounts to a miniature and extremely localized explosive blast.



ICRC

**Figure 21.2.1**  
Blast mine.



Bryusov et al.

**Figure 21.2.2**  
Mechanism of detonation of a blast mine.

### 21.2.2 Fragmentation mines

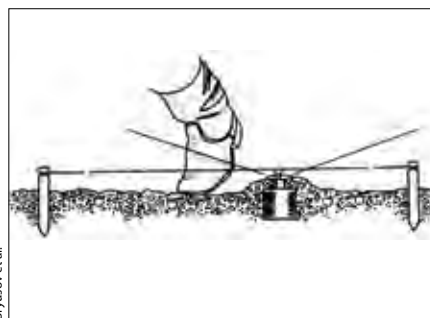
These mines scatter metal fragments on detonation. They are set off by the victim hitting a tripwire or fuse. Different types have different modes of operation: held on a stake just above the ground; bounding up into the air 1 m before exploding; or spewing out fragments over a defined arc in a chosen direction, i.e. directional mines of the “Claymore”-type. With the first two, multiple metallic fragments derived from the outer casing or the contents are projected at 360° and are lethal up to a radius of about 25 m depending on the type. Directional mines usually include metal spheres or cubes and may be lethal up to a distance of 150 m.

The wounds produced are the same as those caused by any other fragmentation device, such as a grenade, mortar shell, etc.



T. Gassmann / ICRC

**Figure 21.3.1**  
Fragmentation stake mine in field with tripwire detonation mechanism.



Bryusov et al.

**Figure 21.3.2**  
Activation of a fragmentation mine by hitting a tripwire.



ICRC

**Figure 21.3.3**  
Directional fragmentation mine.

## 21.3 Clinico-pathological patterns of injury

As a subset of blast injuries, the same general factors affect the pathological patterns and severity of injury:

- type of mine;
- amount and type of explosive material;
- distance from or contact with the device and position of the victim at the moment of explosion;
- the environment, in this case any means of protection worn by the victim (special boots, flak jacket, etc.).

As described in Section 3.1.3, ICRC surgeons have defined three different clinico-pathological patterns of injury based on their clinical field experience.<sup>2</sup> These three patterns are important in determining requirements for hospital resources and long-term rehabilitation. Mine amputees need both in far higher proportions than do the non-amputee mine-injured or, more generally, other war-wounded.

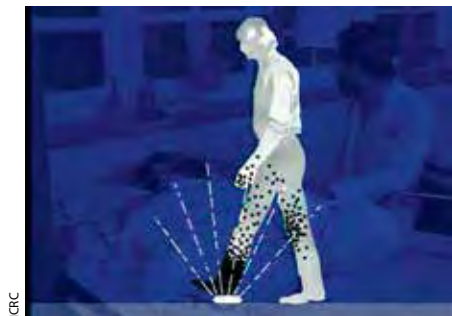

Figure 21.4.1  
Pattern 1 injury.



Figure 21.4.2  
Pattern 2 injury.



Figure 21.4.3  
Pattern 3 injury.

### 21.3.1 Pattern 1 injury

The victim steps on the pressure plate of a blast mine: the foot or leg is blown away causing a traumatic amputation, with varying degrees of penetrating injuries and burns to the contralateral leg, perineum and buttocks, abdomen, chest or arm.

The severity of the injury, as well as the level of traumatic amputation, is a function of the amount of explosive material relative to the body mass of the victim and the position of the foot at the moment of contact. If the explosive charge in the mine is large enough, it will kill outright; but the usual intent is simply to maim.

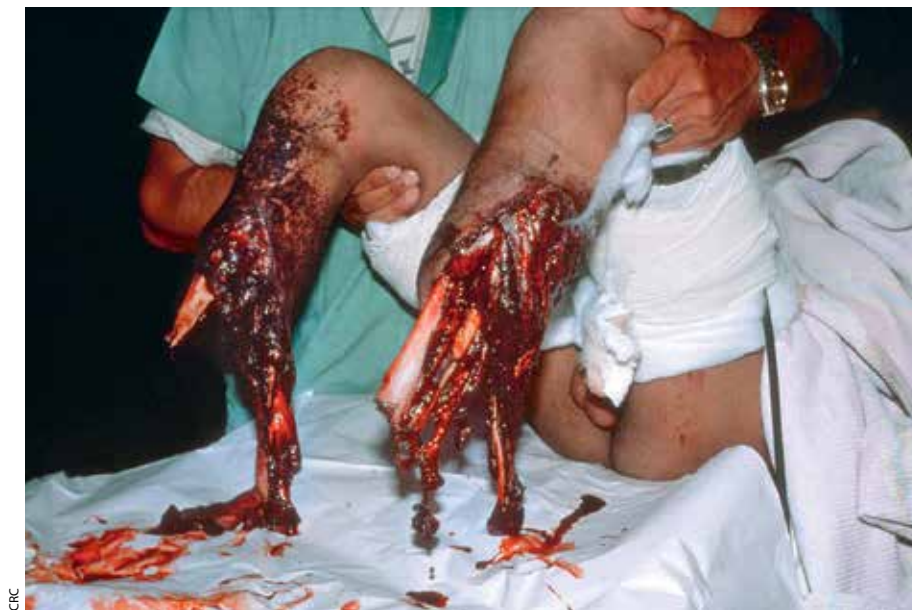

Figure 21.5  
Bilateral pattern 1 injury.

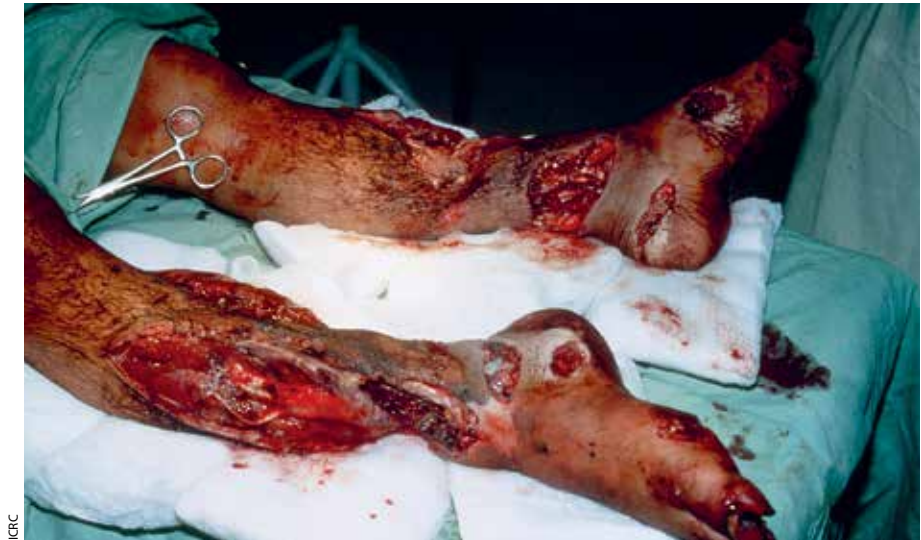<sup>2</sup> Coupland R. M., Korver A. Injuries from antipersonnel mines: the experience of the International Committee of the Red Cross. *BMJ* 1991; **303**: 1509 – 1512.

### 21.3.2 Pattern 2 injury

The victim detonates a fragmentation mine by hitting a tripwire or fuse and the resulting explosion scatters metal fragments in the same manner as any explosive device. In another instance, someone may be injured by fragments when standing near a person or an animal, such as a cow taken out to pasture, who steps on a blast or fragmentation mine. The fragments may hit any part of the body and their penetration can be superficial or deep depending on the distance of the victim from the explosion. They can tear a body to shreds at close proximity, or cause a traumatic amputation, especially within the radius of primary blast effect, but this is less common than with pattern 1 injuries.

Figure 21.6

Pattern 2 fragmentation mine wounds.



### 21.3.3 Pattern 3 injury

Manipulation of a mine causing its detonation may injure combatants laying mines, mine-clearance personnel, peasants touching a mine while planting rice in a paddy field, or curious children playing with a mine, especially the small and fascinating "butterfly" mine (Figure 3.3.3).

Victims suffer amputation of the fingers or hand, with varying degrees of penetrating injury and burns to the face, neck and chest; many are blinded. The presence of face burns affecting the airway increases mortality by a factor of three. Survivors have handled very small mines; a large amount of explosive material inevitably proves fatal. The same mechanism of localized blast injury is at work in patterns 1 and 3.

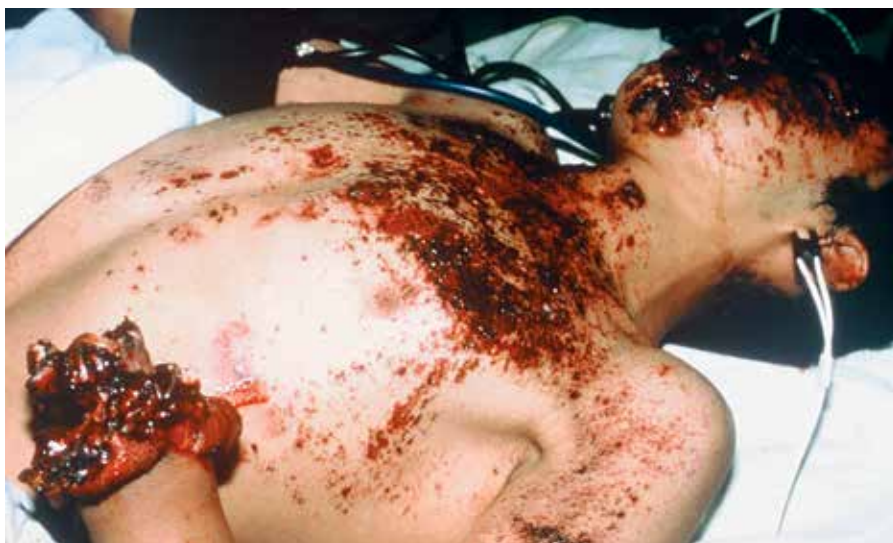

Figure 21.7.1

Pattern 3 injury: amputation of the hand and injuries to the chest and face.

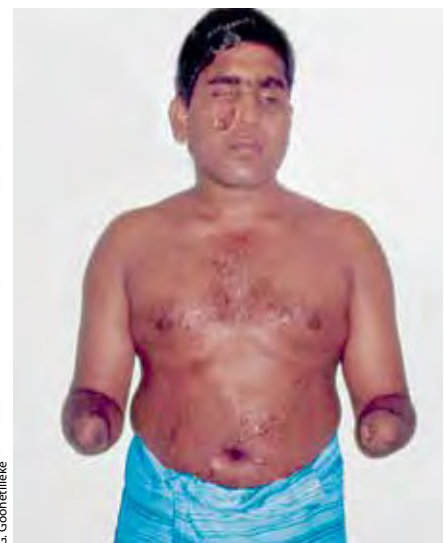

Figure 21.7.2

The victim is blind and has suffered amputation of both hands.

## 21.4 Epidemiology

Epidemiological studies on the use of landmines are by and large divided into two categories; the first deals with the general public health and socio-economic consequences; the second with the more purely medical aspects.

### 21.4.1 Definitions, classifications and data collection

Data on landmines are confusing because of the problem of definitions. Whether industrially-manufactured or improvised, a mine is activated by the victim. Devices activated by an individual are classed as anti-personnel mines, while those that require the weight of a vehicle are considered anti-tank or anti-vehicle mines. The various explosive remnants of war – unexploded ordnance, especially cluster-bomb submunitions – cause injuries in a similar fashion and their clinical effects are indistinguishable from those due to mines. In many cases it is impossible for doctors and nurses, or the patient, to understand whether the device was a mine or an UXO. Similarly, many hospital records do not distinguish between anti-personnel and anti-tank mines.

The most important challenge that has rendered the epidemiological study of the effects of landmines and ERW difficult has been the paucity of consistent, reliable data. Many attempts have been initiated to correct this since the signing of the Mine Ban Convention in 1997. Several organizations and government agencies have played a role in developing the necessary data collection systems to remedy this and to contribute to a better understanding of the multiple medical and socio-economic effects of landmines and the explosive remnants of war.<sup>3</sup>

### 21.4.2 Consequences of the tactical use of landmines

The pattern of landmine use in international wars, local wars, and guerrilla wars differs. The armies of States tend to place them along borders or front lines; guerrilla warfare knows no such limitations: there are no front lines and landmines are often placed more randomly.<sup>4</sup> However State armed forces can also deploy mines and cluster munitions by aircraft and artillery which can result in widespread lethal contamination beyond border areas and front lines. Thus, the proportion of landmine and ERW casualties out of the total number of wounded in any conflict varies according to the type of military activity and the nature of the terrain. Table 5.3 shows a number of examples in different conflicts.

In the ICRC surgical database described in Annex 5.A, the victims of landmines or ERW account for 18% of those admitted to ICRC-run hospitals.<sup>5</sup> Table 5.4 shows the percentages for different hospitals, ranging from 0 to 63%, according to the tactical characteristics of combat in the different conflicts. The efficiency of pre-hospital care and evacuation must be taken into account when considering these hospital statistics; field mortality can be very high and reach 30 – 40% or more in some contexts.

In most contemporary conflicts, during the actual fighting, the majority of victims of landmines are military, the proportion of civilian casualties varying according to the country. One example was the conflict in Bosnia-Herzegovina, where most minefields were laid along front lines that remained fairly stable. Civilians generally fled these areas. Of the 2,807 known to have been killed or injured by mines between 1992 and 1995, 2,076 (74.0%) were soldiers on military duty, 99 of whom were soldiers demining

3 Contributions have come from the International Campaign to Ban Landmines (ICBL) through its annual Landmine Monitor report; the Geneva International Centre for Humanitarian Demining through its International Management System for Mine Action (IMSMA) deployed in many affected countries; the World Health Organization which prepared a standard reporting format for IMSMA; UNICEF; the Centers for Disease Control and Prevention; and the ICRC. The ICRC has organized data collection registries in Afghanistan and Bosnia-Herzegovina. At present the primary reference on landmine and ERW casualties is the "Landmine Monitor" report of the ICBL.

4 International Committee of the Red Cross. *Anti-personnel Landmines: Friend or Foe? A study of the military use and effectiveness of anti-personnel mines*. Geneva: ICRC; 1996.

5 One shortcoming of this database is the lack of differentiation between APM and ATM; however, most of the patients are considered to be victims of anti-personnel mines because of the nature of the conflict.

(3.53%); 611 (21.8%) were civilians and 120 (4.3%) were of unknown status.<sup>6</sup> The most malicious aspect of mine warfare, however, is that after a conflict is over most casualties are civilians and people involved in mine clearance.

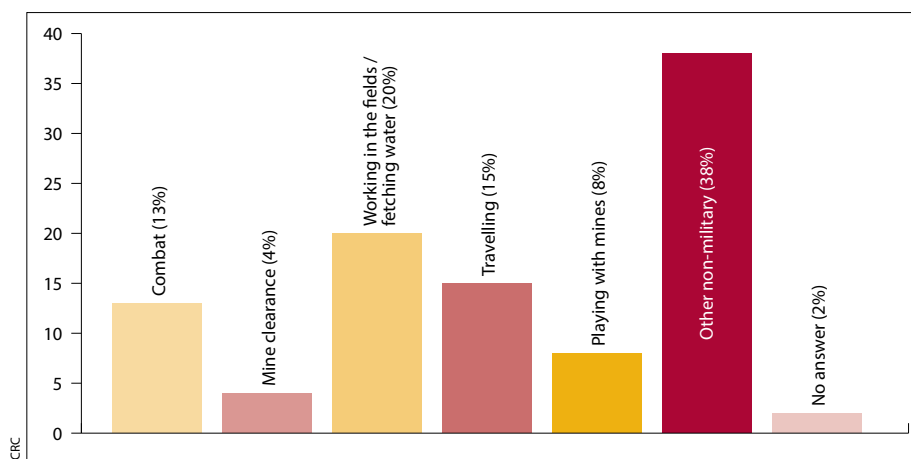
### 21.4.3 Effects on civilians post-ceasefire and post-conflict

Several studies undertaken by ICRC staff demonstrate this particularly pernicious consequence of the widespread use of APM on the civilian population. The ICRC Sarajevo Database shows that after the Dayton Agreement was signed in December 1995, there was a dramatic change in the kind of victim injured by landmines. Of the 1,055 people listed as killed or injured between 15 December 1995 and 31 December 1998, 822 (77.9%) were civilians, 131 (12.4%) were military (29 of whom were involved in demining) and 102 (9.7%) were of unknown status. Thus, the percentage of civilian casualties rose from 21.8% during the war to 77.9% in the immediate post-war period. This can be explained by the fact that a large number of people resumed pre-war activities, in particular farming, and many travelled to areas where heavy fighting had taken place, in order to assess damages or return to their homes. Mine incidents increased greatly during the first six months following the war, while later, as people became more knowledgeable about the threat, they decreased.

Another example followed the fall of the regime in Kabul, Afghanistan, in 1992, which allowed the return of many refugees from Pakistan. The number of mine-injured admitted to the ICRC Peshawar hospital doubled from 50 to 100 per month. Eighty-five per cent of the patients had been engaged in non-military activities (Figure 21.8) and 78% said they had only recently returned to Afghanistan. The ICRC surgical team in the Jalalabad University Hospital, in Afghanistan just across the border from Peshawar, also noted a sharp increase in landmine injuries from 35% to 60% of all war-wounded, after the repatriation of large numbers of refugees to nearby rural areas in early 1993. Children and adolescents were particularly at risk – while playing and fetching firewood or water, or because of simple curiosity – indeed the percentage of children among the victims often rises in the post-conflict period in many countries.

**Figure 21.8**

ICRC Peshawar Hospital study 1992 – 93: activities of mine victims (N = 600).<sup>7</sup>



These scenarios are repeated time and again in many countries that have witnessed the widespread use of landmines. Victims are still being killed and injured every year in the minefields dating from the Second World War in el-Alamein, Egypt. Similar incidents due to mines and UXO from World Wars I and II are reported in Europe almost every year.

The true extent of the problem of landmines is not known. However, the simple number of landmines or casualties is an inadequate criterion for judging the severity of the problem in a particular country or region, and says nothing about the total humanitarian effects. Annex 21.A underlines the socio-economic consequences of landmines and the effects on mine clearance, relief, and health programmes.

<sup>6</sup> ICRC Landmine Victim Database, Sarajevo.

<sup>7</sup> Jeffrey SJ. Antipersonnel mines: who are the victims? *J Accid Emerg Med* 1996; **13**: 343 – 346.

## 21.4.4 Mortality

The tactical use of APM has serious and long-lasting effects. The use of mines over wide regions of rural countryside, far from urban centres and communications, means that a large number of casualties are alone when they suffer injury. If they happen to be accompanied, their companions must be exceedingly careful when rushing to the rescue, for they too will be entering the minefield and risk being killed or injured. The number of people who die in isolated rural areas is seldom known.

Various community-based public health surveys have estimated that the death rate in the field reaches 50% and more in certain countries (e.g. Mozambique, Angola, or Somalia). Almost all ICRC surgical teams working in Afghanistan or Sudan over a period of many years returned from their assignment with stories of patients who had taken 10 to 15 days, or more, to reach the hospital. Survival rates can improve, however, with the implementation of appropriate and cost-effective community-based first aid and pre-hospital trauma systems. In the former Yugoslavia, the ICRC Sarajevo database shows a mortality rate of only 17% and in contexts where evacuation is very efficient and of short duration even lower figures are to be found.

The lethality of APM is formidable, especially in formal minefields where mixed ATM and bounding fragmentation APM are used, as is shown in Table 21.1 by the figures for the Iranian border, the Guantanamo Bay military base in Cuba, and the Greek-Turkish border.

Place	Total injured	Total dead / (Dead in the field)	Case fatality rate / (Field mortality rate)	Hospital mortality	Source
Iran 1988 – 2002	6,765	2,840	42 %	–	ICBL Landmine Monitor
Ilam, Iran 1989 – 1999	1,082	394	36.4 %	–	Jahunlu et al., 2002.
Greece 1988 – 2003	40	(21)	(52.5 %)	0	Papadakis et al., 2006.
Guantanamo Bay, Cuba 1967 – 88	27	(14)	(51.9 %)	23.1 %	Adams & Schwab, 1988.
Afghanistan 1980 – 94*	1,265	699	55 %	–	Andersson et al., 1995.
Cambodia 1978 – 94*	443	136	31 %	–	Andersson et al., 1995.
Bosnia-Herzegovina 1992 – 94*	195	79	41 %	–	Andersson et al., 1995.
Mozambique 1980 – 94*	197	83	42 %	–	Andersson et al., 1995.
Mozambique 1980 – 93*	251	120	48 %	–	Ascherio et al., 1995.
Afghanistan 2001 – 2002	1,636	154	9.6 %	–	Bilukha et al., 2003.
Afghanistan 2002 – 2006	5,471	939	17.2 %	–	Bilukha et al., 2008.
Chechnya 1994 – 2005	3,021	687	22.7 %	–	Bilukha et al., 2006.
Sri Lanka 1996 – 1997	328	(45 DOA**)	(13.7 %)	3.9%***	Meade & Mirocha, 2000.

\* Based on a cluster survey of households performed in 1994.

\*\* DOA: Dead on arrival at the hospital. The total number of dead in the field was unknown.

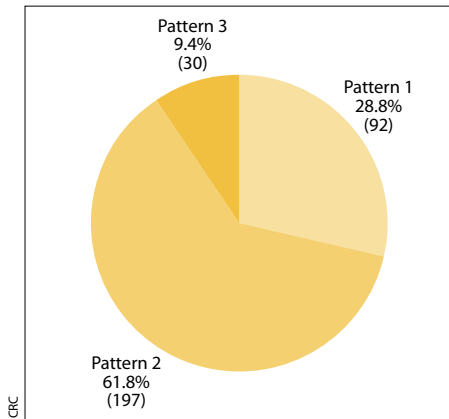
\*\*\* Hospital mortality based on 283 patients reaching hospital alive.

**Table 21.1 Case fatality rates in selected countries. Includes landmines (APM, ATM), cluster munitions, other UXO. Dead in the field and field mortality rate do not include later hospital mortality. Source references are to be found in the Selected bibliography.**

The ICRC in-hospital mortality rate for APM victims is 3.7%; the same as for patients wounded by other weapons. It increases to over 6% in the case of those who suffer traumatic amputation due to APM. However, the longer the patients have spent on the road, the lower the hospital mortality rate: “automatic triage” of the most severely wounded takes place, as they do not live to reach medical care (see Section 5.8.4).

### 21.4.5 Survivors

Patients surviving both the injury and delays in transport arrive with a large variety of wounds presenting one of the three clinical patterns. Figure 21.9 shows the distribution for 319 patients treated by an ICRC team at the Mongkol Borei Hospital, Cambodia, during the first 8 months of 1991.



**Figure 21.9**  
Distribution of patterns of APM-injury, Mongkol Borei Hospital, Cambodia, January – August 1991: N = 319.

- Pattern 1: traumatic amputation of lower limb.
- Pattern 2: dispersed fragment wounds.
- Pattern 3: traumatic amputation of the hand.

These different patterns of injury explain the enormous variety of wounds seen (Table 21.2). Out of the pattern 1 group of lower-limb traumatic amputations, 72% had transtibial amputations and 25% transfemoral; four patients had bilateral amputations: two above and two below the knee.

The number of head and torso injuries was probably higher, but casualties with such wounds often die on the way; hospital-based statistics can only give a partial picture of the full spectrum.

Anatomic region	Percentage
Head & neck	7.8
Thorax	13.5
Abdomen	12.5
Genitalia	1.6
Upper limbs	15.1
Lower limbs	84.3

**Table 21.2** Anatomic distribution of injuries, Mongkol Borei Hospital, Cambodia.

The noxious nature of APM as a weapon system creating excessive suffering is best illustrated by a report covering the years 1979 – 2010 at the ICRC prosthetic centres in Afghanistan, a country that has witnessed widespread use of landmines for three decades: out of a total of 37,337 amputees, 79.6% were due to APM.

### 21.4.6 Hospital resources and workload

Landmine victims require a disproportionate amount of hospital resources. In the ICRC’s experience, the average stay in hospital for a patient with a bullet or shrapnel injury is two weeks; for all mine-injured patients three weeks, and for a mine amputee it rises to almost five weeks. This means a much heavier workload for the nursing staff and demands more time and effort on the part of physiotherapists.

As demonstrated in Table 5.22 and Figure 5.8, persons suffering from APM injuries undergo more operations than those injured by other weapons; many require eight or more operations because of burns, necrosis of the tissues, and infection. It should be noted that the traumatic amputation of a limb qualifies immediately as a Grade 3 wound according to the Red Cross Wound Score.

Blood transfusion requirements from ICRC studies show the same trend: 27.9% of all landmine-wounded patients require blood transfusion, whereas only 15% of patients suffering bullet and 13.1% presenting fragment wounds do (Table 8.3). For landmine amputees, the figure shoots up to 75%. Another way of putting this is refer to average blood transfusion requirements for 100 wounded: bullet and fragment-injured patients need 40 units or less; landmine-injured 100 units; and landmine amputees require 300 units.

## 21.5 Blast mine injury: pathogenesis and clinical implications

The pathology of traumatic amputation due to anti-personnel blast mines is unique.

The most common are pattern 1 injuries at the level of the tibia and this is used as the prime example for the discussion in this section.

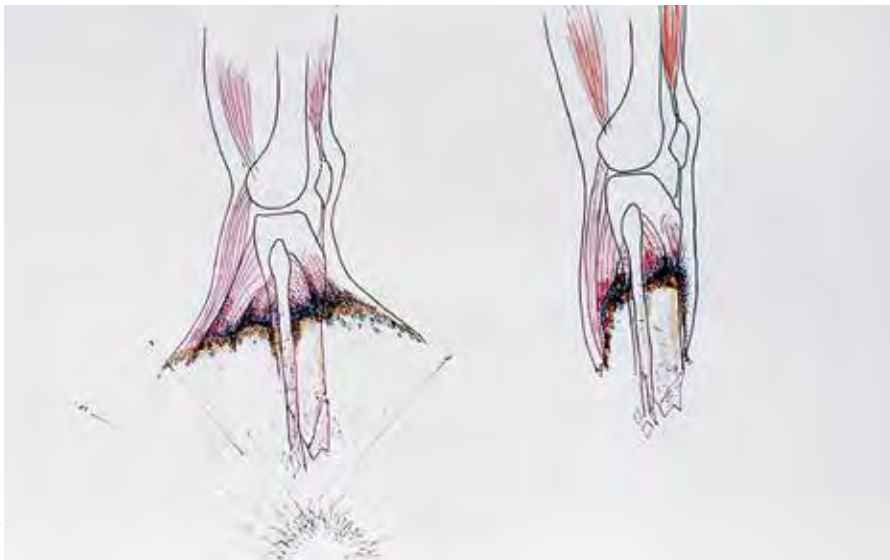


It is the close contact with a body part at the time of explosion that makes blast mine injury so particular. These wounds are the “perfect” example of the dirty and contaminated war wound. The blast tears through the tissues, driving soil, grass, gravel, metal or plastic fragments of the mine casing and pieces of shoe and bone fragments of the shattered foot, up into the leg. Therefore, a classic pitfall for the inexperienced surgeon is to underestimate the extent of tissue damage and the quantity of contaminants.

Blast mine injury: the “perfect” example of the dirty and contaminated war wound.

The overpressure of the blast wave compresses and shatters the contact foot. The subsequent stress waves are propagated through bone, blood vessels and the soft-tissue planes of the entire length of the limb. These stress waves cause fractures in the bones. In the next immediate phase, the blast wind provokes a torsion of the fracture sites that causes the foot to be torn away.

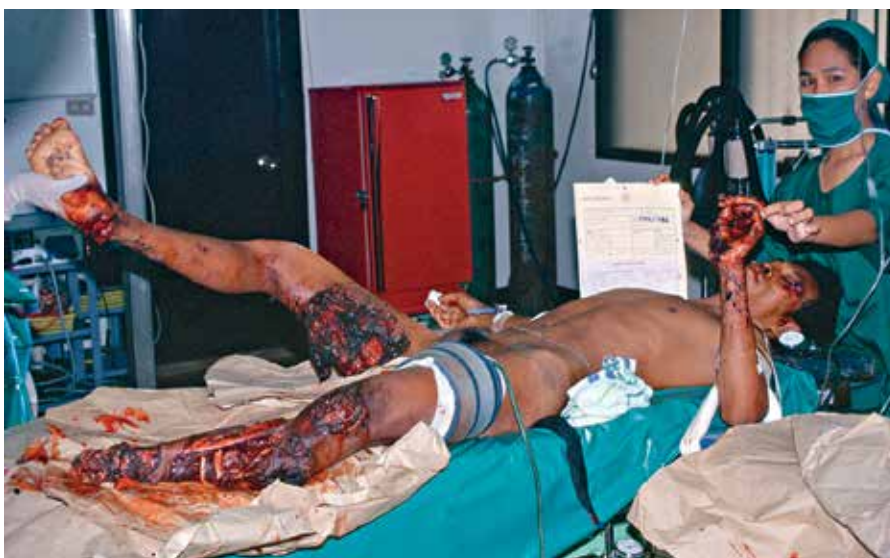At the same time the muscles of the leg are pushed up and out in what can be described as an “umbrella” effect. The localized shock wave of the explosion gases strips the periosteum and attached muscles from the remaining bone: the umbrella opens. All the muscles then drop down: the umbrella closes. The superficial muscles (gastrocnemii) are thrown out further and suffer less damage than the deeper muscle layers of the anterolateral compartment and the soleus. The fascial planes are separated out proximally causing irregular and variable skin loss.



**Figure 21.10.1**

Typical pattern 1 injury with large amount of explosive. Note the “umbrella” effect of the skin and muscles being pushed up and out. The deeper tissue planes suffer greater damage than the more superficial ones.

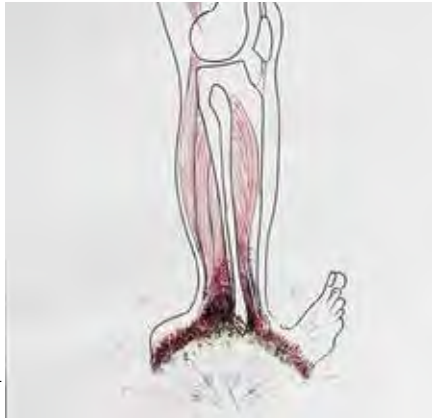
R. Coupland / ICRC



**Figure 21.10.2**

Traumatic amputation of the left leg with injury to the other leg; note the proper application of a pneumatic tourniquet.

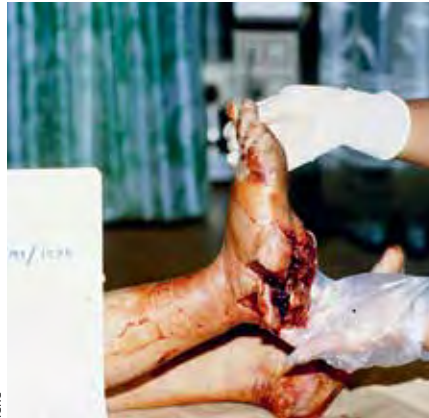ICRC



R. Coupland / ICRC

**Figure 21.11.1**

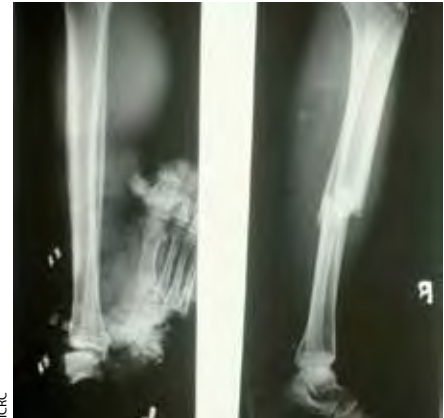Pattern 1 injury, small amount of explosive. Note that the calcaneus is completely shattered while the forefoot and attachment of the Achilles tendon are intact. The damage to the deep tissues around the end of the tibia rises proximally beyond the level of damage to more superficial tissues.



ICRC

**Figure 21.11.2**

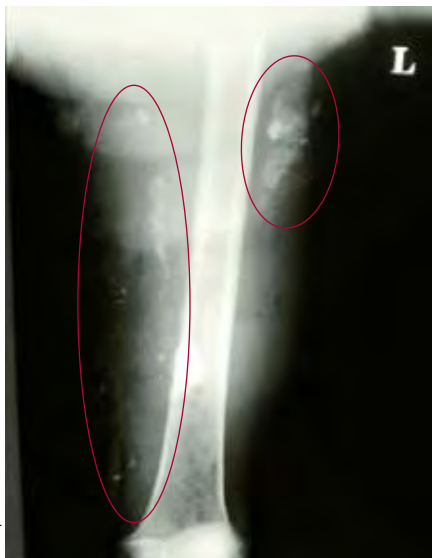Pattern 1 injury completely destroying the calcaneus.



ICRC

**Figure 21.11.3**

Radiograph showing complete destruction of the calcaneus and closed transverse fracture of the other leg.



R. Coupland / ICRC

**Figure 21.12.1**

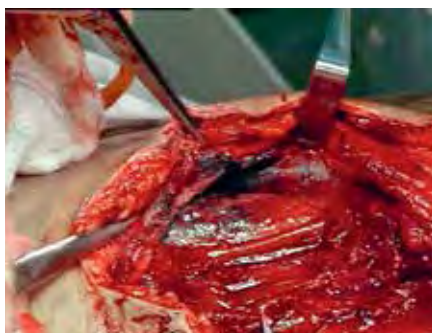Radiograph showing multiple foreign body fragments and air driven up along the fascial planes.

The final open wound takes the circular form of the limb, with only skin tags and tendon ends dangling below. The spared structures that were pushed up and away have fallen back down, covering over and masking the extensively damaged deeper tissues. The deepest penetration of the blast wind takes place along the “weak” spaces of the limb: areolar tissue around neurovascular bundles and fascial planes – thus the damage extends far beyond the level of the traumatic amputation. Haematoma, oedema fluid, and in the event of infection, pus, can track proximally through these weak spaces.

In addition, the heated gaseous products of the detonation not only vaporize the contact foot, but can also cause coagulative necrosis of the bone ends and the soft tissues. This coagulation of the vessels may effectively stop the bleeding. However, burns of the skin and muscles occurring within the primary blast radius are particularly nasty and difficult to treat.

Taking everything into consideration, the required level of surgical amputation is, therefore, higher than is apparent to the inexperienced eye.

The required level of surgical amputation is higher than is apparent to the eye.



ICRC

**Figure 21.12.2**

Blast effect propagated along fascial planes: far-reaching contamination and contusion of the tissues.

### 21.5.1 The effect of body size and footwear

Many surgeons have witnessed the difference in severity of injuries seen in various patients who have detonated the same type of mine. This can be explained by considering that the extent of tissue destruction depends on the distance or gap between the explosion and the core mass of the body and on the quality of the footwear.

Russian surgeons have performed laboratory studies comparing the results of different sized feet – therefore different body height – in contact with a blast mine.<sup>8</sup> Longer legs provide a greater gap between the mine and the body mass and result in a lower level of traumatic amputation. This “distance” proves to be the most effective protection against the shattering brisant effects of a blast mine. It also explains the much greater severity of injury suffered by children.

8 Nechaev et al., 1995.

As a consequence, ordinary shoes offer little protection; they only minimally increase the gap between the foot – and therefore the body mass – and the mine, but on the other hand augment the secondary fragments that may be propelled into the proximal tissues. Paradoxically, the wearing of footwear may actually increase the transfer of energy to the tibia.<sup>9</sup> One example comes from Thailand where soldiers wearing army boots who were injured by APM all suffered transfemoral amputations, while only 29% of those wearing tennis shoes or sandals at the time of injury were amputated.<sup>10</sup> Specialized gear worn by mine-clearance personnel certainly offers greater protection, but much trial and experimentation remains to be accomplished.

### 21.5.2 More proximal lesions

The more proximal parts of the limb (the blast wave can cross the joints) suffer an irregular zone of tissue contusion and cellular concussion whose limits are difficult to determine. During the first three days after injury, tissue oedema becomes marked and may lead to proximal compartment syndrome.

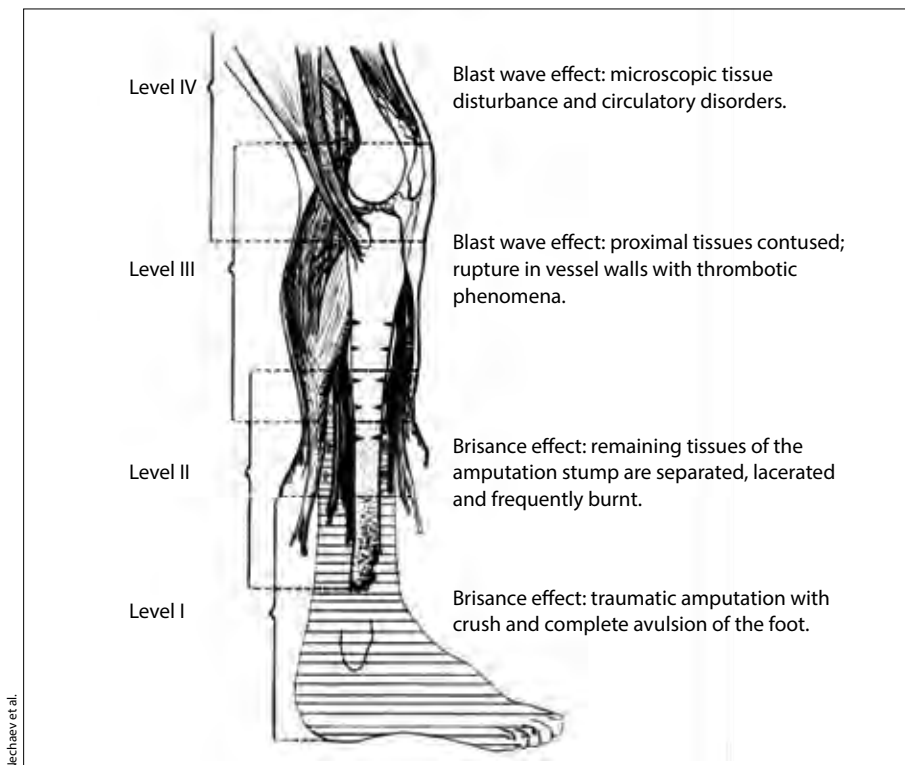


Figure 21.13.1

Levels of injury after a traumatic amputation.

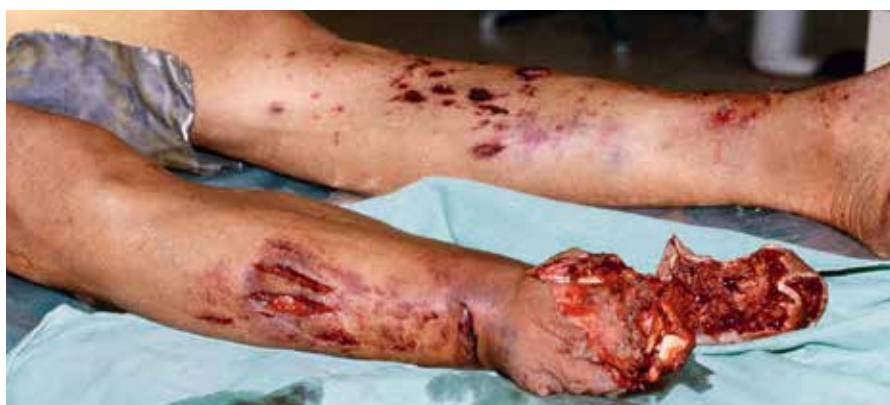

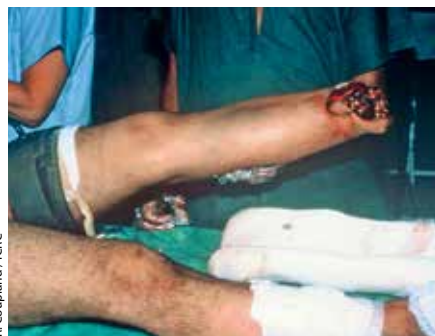Figure 21.13.2

The blast effect has caused a traumatic amputation of the right foot and splitting of the skin on the proximal lower leg.

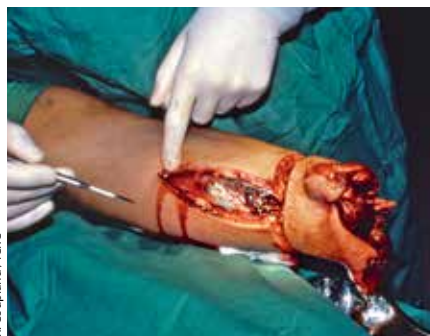The stress waves propagated through the column of blood in the vessels of the limb can provoke variable levels of fissuring of the tunicae intima and media, leading to thrombosis, as well as contusion of the muscles with subsequent compartment syndrome.

9 Trimble K, Clasper J. Anti-personnel mine injury; mechanism and medical management. *J R Army Med Corps* 2001; **147**: 73 – 79.

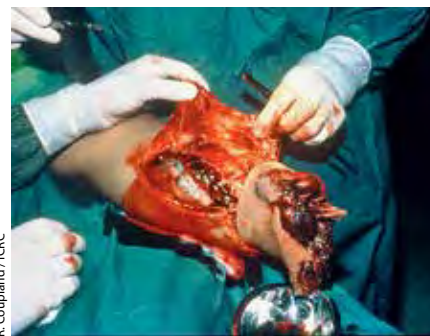10 Traverso LW, Fleming A, Johnson DE, Wongrukmitr B. Combat casualties in Northern Thailand: emphasis on land mine injuries and levels of amputation. *Mil Med* 1981; **146**: 682 – 685.



R. Coupland / ICRC



R. Coupland / ICRC



R. Coupland / ICRC

**Figures 21.14.1 – 21.14.3**

Blast-induced thrombosis and compartment syndrome.

An extreme case of thrombus propagation: note the “tense” appearance of the muscles of the calf. On palpation, they felt “hard and full”, denoting compartment syndrome. Proximal dissection revealed tissue contusion and thrombosis up to the popliteal vessels. Not all patients suffer as extensive damage as this, but the example indicates the need for a close examination – thorough palpation – of the proximal segments of the limb to diagnose any increase in tissue tension. Some patients may then require simple fasciotomy, others a more proximal level of amputation.

Similar lesions as those seen with primary air blast trauma may occur in the organs of the torso (primarily contusion of the heart and lungs and haematomas of the root of the mesentery) and the central nervous system, depending on the strength of the explosion.

#### ICRC EXPERIENCE

ICRC surgeons and colleagues from Russia, Sri Lanka and Iraq have reported anecdotal incidences of sudden death hours or one to two days following resuscitation and surgery for a traumatic amputation due to APM. No presence of airway or torso injury was observed in these patients.

Some surgeons have presumed that fat or thrombotic emboli lead to the sudden death. There is no conclusive evidence-based reason for the occurrence; however, this might be an example of what has been described as the “general concussion syndrome” mentioned in Section 19.5.1 under primary blast injury.

In some contexts, colleagues have taken to administering steroids to patients suffering from APM traumatic amputation; again, not evidence based. This practice is not followed by ICRC surgeons.

## 21.6 Clinical presentation and management

The management of APM injuries poses a challenge to the entire chain of casualty care, from pre-hospital first aid through to physical and psychological rehabilitation.

### 21.6.1 First aid

Pre-hospital care in cases of APM injury is often rendered difficult and dangerous by the prevailing circumstances: the patient is in the middle of a minefield! It is important for first aiders to understand that the last thing to do is to rush to the assistance of the wounded, thus putting themselves in danger. Someone should go for specialized help to assist with the extraction of the injured person.<sup>11</sup>

However, the first aider can do much to assist the victim *in situ*. The casualty is often conscious and can be “talked through” a series of measures to be undertaken.

A simple protocol for the first aider is proposed.

1. Keep calm.
2. Reassure the person that help is on the way.

<sup>11</sup> It is not within the competency of the authors or the ICRC to describe the procedures of victim extraction, and the reader should seek the expertise of mine clearance agencies or military specialists. Furthermore, these first-aid guidelines may not apply to military paramedics.

3. Tell the casualty not to move about; there is a risk of setting off another mine.
4. Ask the casualty to remove a shirt or other appropriate piece of clothing and pack it into the open wound and apply pressure. Any overt haemorrhage usually ceases after a few minutes and the effort keeps the casualty occupied and focused.

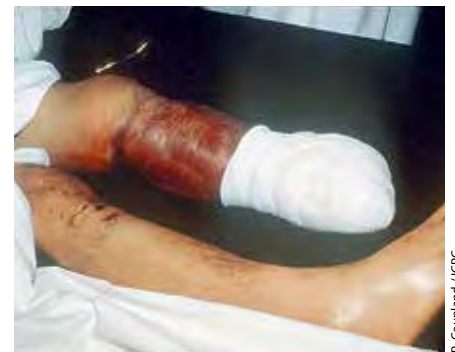Often, the larger vessels in the depth of the wound have been coagulated by the heat of the explosion or have retracted and gone into spasm: packing and direct pressure is most often sufficient. Trying to *improvise a tourniquet* under these conditions is usually self-defeating.

5. Throw the person bottles of water and instruct to take numerous small sips.
6. The same can be done with simple analgesics, if available.

Once extracted from the mined area, the basic principles of first aid apply. Packing the open wound of a traumatic amputation, applying a compressive bandage, and raising the limb are usually sufficient to stop any haemorrhage. A proximally-placed and sufficiently tight tourniquet is very painful after some time and, while stopping the bleeding, creates total ischaemia of the distal part of the limb by shutting off all collateral circulation.

#### ICRC EXPERIENCE

Lay persons – horrified by the aspect of a traumatic amputation – often attempt to place an improvised tourniquet even if there is no ongoing haemorrhage. Usually, the tourniquet is not placed correctly. If not tight enough, it closes off venous return but does not shut down arterial perfusion, which might lead to exsanguination. A tight tourniquet high up on the leg and left on for many hours without being loosened can transform a traumatic amputation of the foot into a surgical amputation of the whole limb at thigh level. ICRC surgical staff have all too often witnessed such tragedies.



21

R. Coupland / ICRC

**Figure 21.15**

Inappropriate tourniquet applied at the knee for a traumatic amputation of the foot and left on for more than 12 hours. The patient subsequently developed gas gangrene.

The subject of the hospital management of a field tourniquet is dealt with in Section B.9.1.

### 21.6.2 Emergency room care

#### Examination

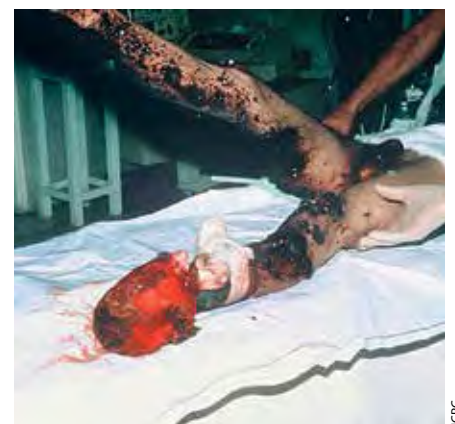As with all trauma patients, the initial examination and resuscitation are based on the ABCDE algorithm (see Chapter 8). It is important to recognize the aforesaid patterns of APM injury to avoid missing any hidden injuries. Pattern 3 is most likely to produce injuries that affect the airway and breathing (Figure 21.7.1).

As with all fragment injuries, close examination for small penetrating wounds is mandatory. This is particularly the case in pattern 1 where meticulous examination of the genitalia and perineum are called for; a small entry wound may easily go unnoticed and small fragments can readily reach into the pelvis or peritoneal cavity.

One must never forget the possible primary blast damage suffered “at a distance”.

#### Resuscitation

Patients suffering APM wounds frequently are injured in remote rural areas with exceedingly long evacuation times. Dehydration and tissue oedema compound the effects of any original haemorrhage and require adequate resuscitation prior to surgery. In addition, the proximity of the blast may induce “resistance to resuscitation” (see Section 19.5.1). Furthermore, the extremely contaminated nature of these wounds means that sepsis is a constant danger. Antibiotics should be administered as soon as possible. The ICRC protocol calls for penicillin and metronidazole.



ICRC

**Figure 21.16**

Pattern 1 injury with burns and wounds in the perineum and penetration of the abdomen.

The surgeon must take into account the pattern of injury and any associated injuries to determine management strategies.

## 21.7 Surgical management of pattern 1 traumatic amputations<sup>12</sup>

It is the traumatic amputation of patterns 1 and 3 due to blast mines that poses the greatest technical challenge to the inexperienced surgeon and where war surgery differs most from civilian trauma and even from the rest of war trauma. An understanding of the pathology is essential.

The general topic and operative surgical details of amputations and disarticulations are dealt with in Chapter 23. This section deals with the *specificities of blast-mine amputations*, and of pattern 1 in particular. The most common such injury involves a transtibial below-knee amputation and this operation is taken as the basis for discussion.

### 21.7.1 Preparation of the patient

Given the highly contaminated nature of these wounds, the affected limbs should be thoroughly scrubbed with soap and water and a brush after induction of anaesthesia.

Scrub the limb clean and use a pneumatic tourniquet.

### 21.7.2 Level of amputation and surgical technique

Surgery involves performing a formal amputation above the irregular and soiled traumatic amputation stump, transforming it into a clean, properly-moulded surgical one.

The surgical amputation must excise all dead and contaminated tissue.

The surgeon must remember the pathology of the “umbrella” effect: deeper muscle layers suffer greater damage than more superficial ones and distal skin is still viable. Thus, an amputation level based on civilian trauma knowledge would be too radical with respect to the superficial tissues and not radical enough with respect to the deeper tissues. In addition, primary blast effects may produce tissue oedema and compartment syndrome far proximal to the open wound.

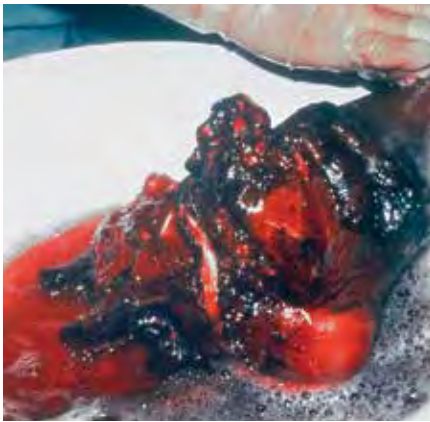
Do not forget to check for proximally-extending compartment injury.

In practice, and as a rule of thumb:

- destruction of the foot up to the malleoli usually results in amputation through the middle third of the tibia;
- injury to the lower third of the tibia leads to an amputation through the upper third;
- traumatic amputation at the level of the middle or upper third of the tibia invariably involves knee disarticulation or a transfemoral amputation.

The surgeon should begin by closely examining the wound, grasping the skin remnants, muscle and tendinous tags of the traumatic stump, and pulling them up and out (opening the “umbrella”) to fully expose the depths of the wound in order to determine properly the extent of muscle injury at the deepest tissue planes.

Pull the “umbrella” open to observe the depth of injury.



E. Winiger / ICRC

Figure 21.17

Scrubbing of a highly contaminated APM wound.

12 Large parts of this section are based on the brochure by R. M. Coupland, *Amputations for War Wounds*. Geneva: ICRC; 1992.

Please note:

It may be very difficult to ascertain precisely the distal border of viable muscle tissue because of the blast effect. The surgeon should follow the guideline of the 4 Cs: colour, consistency, contractility, and capillary bleeding (see Section 10.5.5). In case of doubt, it is better to err on the radical side.

It is appropriate to first perform excision of the soft tissues and then plan the bone section as distal as possible. In practice, this often means raising unconventional skin flaps as determined by the injury, taking into account any burns. As much skin as possible should be retained: any excess can be excised at delayed primary closure. The bone is cut and vessels and nerves sectioned according to standard techniques.

### 21.7.3 Classical approach to amputation

The surgeon removes all dead, devitalized and contaminated tissue and amputates “as distal as possible through viable tissue” using techniques resembling civilian amputations, while taking the specific pathology into consideration.

Skin flaps are raised and then pulled back once more to expose the damage to the deep muscles, all of which are *cut across obliquely* proximal to this level. This is particularly important in the anterolateral compartment of the leg; tissue damage can extend a good deal more proximal to what is at first observed and usually requires cutting the muscles short. They are not of great use for stump closure at DPC, which is based more on posterior muscle flaps. The irregular tissue damage and swelling of the sectioned muscles may render closure difficult. It is all too easy to underestimate the extent of muscle swelling post surgery.

### 21.7.4 “Umbrella effect” and myoplastic amputations

The principle of a myoplastic amputation involves leaving the *muscle intact* rather than cutting across its fibres. The whole muscle is dissected out; only the distal tendon attachment is sectioned. The umbrella effect that spares the superficial muscles makes myoplastic amputations particularly suitable for APM injuries.

The intact muscle and overlying skin form a myoepithelial flap: particularly useful after the umbrella effect of APM amputations.

ICRC surgeons have found three myoplastic amputations to be appropriate and effective. The operative details are to be found in Chapter 23.

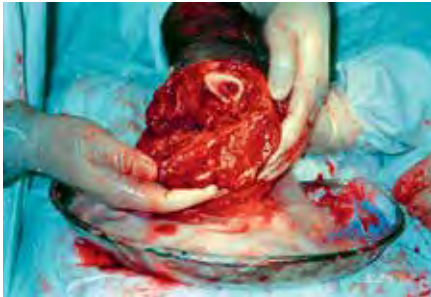The soleus myoplastic amputation is well suited to a patient with irreparable damage to the foot if the leg is unaffected. It is performed through the middle third of the tibia.

The medial gastrocnemius myoplastic amputation is most commonly performed when the injury extends above the malleoli. Since the gastrocnemius muscle is not contained in a tight compartment and has a proximal blood supply, the muscle and overlying skin tend to be spared injury. Should the medial gastrocnemius have suffered damage, the lateral is available; and should both have been injured, then an above-knee amputation or disarticulation is usually necessary.

The vastus medialis myoplastic amputation is suitable when the injury is confined to the lower leg but a successful transtibial amputation is not possible. A pitfall in transfemoral amputations after blast-mine injury is that contaminants may be pushed up and oedema fluid, haematoma or pus track up proximally around the large sciatic nerve. The surgeon should examine the fat in the track of the divided for any sign of contamination or haematoma that may require excision.

### 21.7.5 Other operative considerations and DPC

The standard operative protocol applies: removal of the tourniquet and definitive haemostasis; copious irrigation; leaving the wound wide open; and application of a large, bulky dressing. After 4 – 5 days, the dressings are removed in the operating theatre and the wound inspected under anaesthesia.



**Figure 21.18**  
Rinsing of the clean amputation stump.

Leave the stump open for DPC.

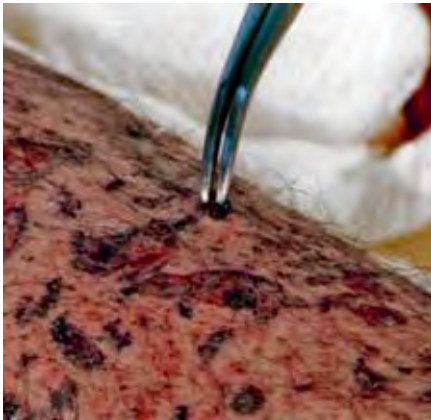
Once the wound is clean, the surgeon can proceed to delayed primary closure. However, mine-induced amputations are notorious for a high incidence of wound infection and multiple operations. Re-amputation in a seriously sick and toxic patient with multiple injuries is a delicate endeavour.

Blast stress waves cause demyelination of major peripheral nerves high up above the level of traumatic amputation. Severe and disabling pain in the long term is more common in amputees injured by APM than from other causes. With good analgesia, physiotherapy and stump care can begin immediately to decrease this risk.

### 21.7.6 Other pattern 1 injuries

The contralateral limb is often injured in pattern 1 injuries. Some wounds may be large, others small. Unlike small soft-tissue wounds due to ordinary fragments, which often do not require debridement because the body's defence mechanisms are capable of dealing with the damage and contamination (see Section 10.8.1), *all blast-mine fragment wounds should be debrided*. Soil, mud, leaves or other contaminants are habitually found in these wounds.

In the case of traumatic amputation of one limb and extensive injury to the other, the surgeon may decide to perform serial debridements. A large fasciotomy should be part of the operative procedure. As with all serial debridements, this is time-consuming and uses up even more hospital resources.

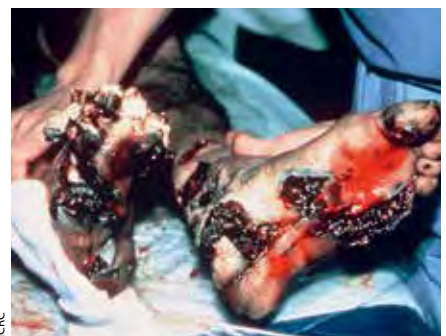
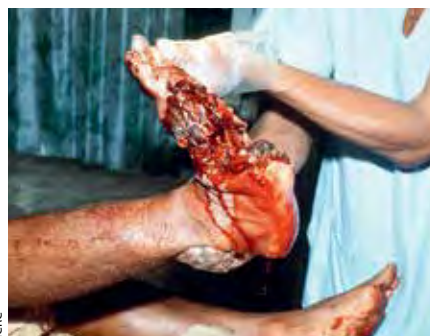
**Figure 21.19**  
Removal of a piece of the mine casing and mud from superficial wounds of the contralateral limb.

## 21.8 Special features of mine-blast injury to the foot

Certain anti-personnel mine injuries to the foot do not result in complete traumatic amputation because of the very small quantity of explosive material. Instead, there is wide and deep soft-tissue injury to the sole of the foot, a mini-umbrella effect and perhaps loss of one or several toes.

**Figures 21.20.1 and 21.20.2**  
Complex mine-blast injury to the foot without traumatic amputation.



Meticulous serial debridements every 2 – 3 days are often necessary if there is to be any hope of saving the foot. Dissection under tourniquet control is performed to identify and excise all necrotic tissues without sacrificing important viable structures. Decompression fasciotomy may need to be carried out across the anterior surface of the ankle joint and up into the anterolateral compartment of the leg. Drains should be placed in pockets of exudative oedema.

Reconstruction is difficult and is usually not possible if the patient presents more than 24 hours after injury because of infection. Split or full-thickness skin grafts to resurface



the sole often break down and it may be difficult to identify the pedicle vessels of local rotation flaps. Specialist techniques are often required.<sup>13</sup> The topic of “limb salvage surgery”, and the burden that the attempt to save the foot may create is dealt with in Section B.5.1.

More often than not, the appropriate recourse for the general surgeon with limited resources is to perform an amputation through the lower third of the tibia and send the patient for prosthetic fitting. It may not be easy to convince the patient of this, especially if he can still “wiggle the toes”.

## 21.9 Special features of mine-blast injury to the hand: pattern 3

Some patients will suffer complete traumatic amputation of the hand, others of one or several fingers. The primary blast effects described previously also pertain here.

In the hand, it is even more imperative to retain important anatomical structures if any function is to be preserved. Again, meticulous and conservative serial debridements are carried out and only grossly necrotic tissues excised bit by bit. Decompression by carpal tunnel release is recommended and may have to be extended up into the forearm.

A fluffy loose dressing that maintains what remains of the hand in a functional position is applied, supported by an anterior splint. The arm should be kept raised by a sling hung over an appropriate device such as an i.v. stand.

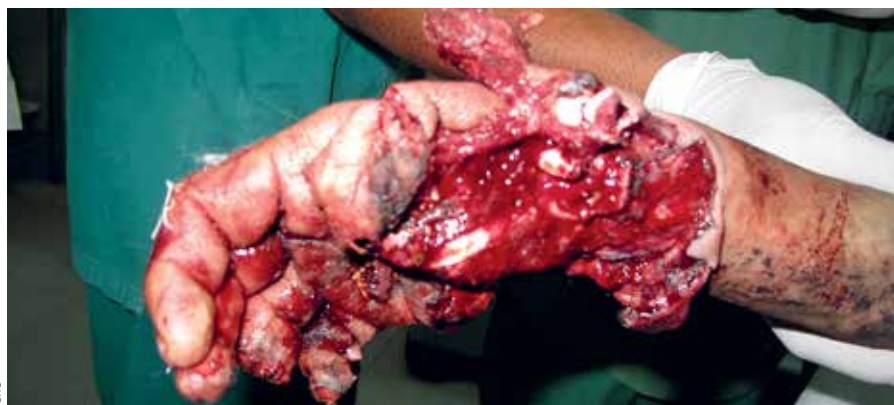
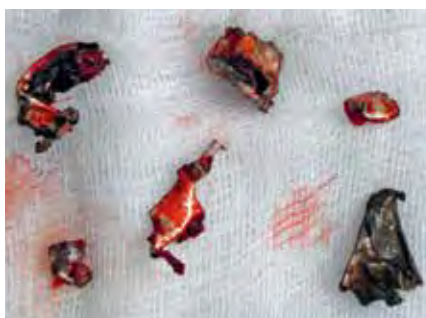
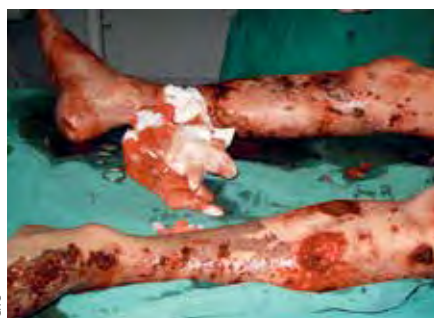Figure 21.21  
Mine-blast injury to the hand.

## 21.10 Surgical management of pattern 2 injuries

The management of pattern 2 injuries due to fragments follows the same rules and procedures as for those caused by other fragmentation devices. As mentioned previously, these wounds tend to be more severe if sustained within the radius of any primary blast effect. The management of fragment wounds in the various parts of the body is the topic of the other chapters in this volume.



Figures 21.22.1 and 21.22.2  
Pattern 2 injury and some of the fragments removed during wound excision.

13 Tajsic NB, Husum H. Reconstructive surgery including free flap transfers can be performed in low-resource settings: experience from a wartime scenario. *J Trauma* 2008; **65**: 1463 – 1467.

## 21.11 Physical and psychological rehabilitation

Successful surgical treatment of mine victims is only one step; then come the problems of the physical and psychological rehabilitation and social and economic reintegration of amputees. Although the immediate effects of draining hospital resources are considerable, the long-term consequences of rehabilitation costs and replacement of prostheses, loss of income and socio-economic dependency are debilitating to the individual, the family, and society as a whole. This is particularly true in low-income countries that have been the main theatres of contemporary mine warfare.

Figures 21.23.1 and 21.23.2

Mine-injury survivors at play and at work.



A full discussion of physical rehabilitation, psychological support and socio-economic reintegration is to be found in Section 23.10.

## 21.12 Conclusion: the humanitarian challenge

At the beginning of this chapter mention was made of the worldwide epidemic of landmine injuries. Political, social, economic and healthcare initiatives are necessary to overcome the humanitarian effects of anti-personnel mines and the other explosive remnants of war. The international treaties banning APM and cluster munitions contain initiatives to address these issues.

### Four levels of a public health approach to meet the challenges of APM

1. Primary action: stop deployment of APM.
2. Secondary action: mine-risk education and the detection, marking and clearance of known mine fields.
3. Tertiary action: good treatment of the injured, from first aid and evacuation to surgery and post-operative care.
4. Quaternary action: physical and psychological rehabilitation, fitting of appropriate prostheses, and socio-economic integration of the victims.

These measures are crucial to help the most vulnerable overcome the effects of the lethal remnants of war.

## ANNEX 21. A Humanitarian repercussions of landmines<sup>14</sup>

The general effects of anti-personnel landmines are direct, indirect and widespread and remain long after a conflict has ended: disabled individuals, handicapped families, and mutilated societies. The humanitarian effects described apply to all lethal remnants of war: anti-tank mines, unexploded and abandoned ordnance and cluster munitions, as well as to anti-personnel mines.

Landmines infesting agricultural land and water sources result in a severe loss of income for farmers, displacement of families forced to leave their homes, an increase in the rate of malnutrition and a rise in the incidence of water-borne diseases due to lack of access to safe drinking water. Mines cause a surge in casualties amongst returning refugees or displaced persons and their repatriation may be delayed or totally compromised. If roads are affected, the resumption of normal commercial activity, the provision of emergency relief supplies and rural immunization campaigns by mobile teams are all blocked.



V. Mvea-Yanke / ICRC

**Figure 21.A.1**

Boys on the way to school past a minefield, Lumesh-Kanjamba village, Angola.



G. Diffident / ICRC

**Figure 21.A.2**

Village near Prilep, Kosovo.

**Figures 21.A.1 and 21.A.2**

Minefields infesting a civilian environment.

21

These socio-economic repercussions can destabilize the fragile economies of post-war societies and, thus, after a civil conflict, exacerbate political tensions when the aim is to achieve national reconciliation.

The response to these humanitarian effects must comprise preventive, curative, and rehabilitative measures. These must include mine clearance, marking of mined areas and mine-risk education to warn populations at high risk of the prevailing danger, as well as medical assistance for the injured.



W. Lembyk / ICRC

**Figure 21.A.3**

Minefield near Kabalo, Katanga province, Democratic Republic of the Congo.



T. Mayer / ICRC

**Figure 21.A.4**

Mine clearance near Angkot village, Battambang province, Cambodia.

**Figures 21.A.3 and 21.A.4**

Marking of mined areas and mine clearance are essential.

Assistance begins with access to the wounded, evacuation and transportation of patients, and proper first aid. It involves correct surgery, physiotherapy, psychological support, and the fitting of an artificial limb when needed. Vocational training and social and professional reintegration are essential, but not always available. Working and living aids are all too often forgotten as well: special toilets for amputees, ramps

<sup>14</sup> Based on C. Giannou. *Mine Information System and the Humanitarian Factors Determining the Severity of Landmine Infestation*. Geneva: ICRC; 1997; presented at the signing conference of the Convention to Prohibit Anti-personnel Landmines, Ottawa, September, 1997.

for wheelchair access, specially adapted agricultural tools, sturdy wheelchairs for uneven terrain, etc.<sup>15</sup>

The true extent of the problem in any given country is simply not known. No one knows exactly how many landmines, anti-tank or anti-personnel, still litter the old and current battlefields of the world, not to mention unexploded submunitions, bombs, and other ordnance, all representing a danger to civilian populations. However, the absolute number of devices is in fact of little consequence. Whether a square kilometre of rural area contains 10 mines, 1,000 or 10,000 is not important; it is still one square kilometre of farmland that cannot be used to grow crops to feed families. The number of mines is of greater significance for mine-clearance teams.

The simple number of landmines, therefore, is an inadequate criterion for judging the severity of the problem in a particular country or region, and says nothing about the humanitarian effects. Some factors that determine these humanitarian effects, and the burden they impose on fragile societies, are given below. They must all be taken into account whenever a society deals with the consequences of mine warfare.

### **1. Mortality and morbidity:**

- number of killed and wounded;
- amputees – according to type of mine; need for artificial limbs and long-term investment in physical and psychological rehabilitation.

### **2. Capacity of the health system to deal with the needs:**

- access to the wounded, first aid, transportation;
- hospital infrastructure, qualified personnel, adequate medical supplies;
- physiotherapy, prostheses, rehabilitation, social and economic reintegration.

### **3. Civilian mined areas:**

- land use of affected areas – residential, agricultural, industrial;
- booby-trapped neighbourhoods and outskirts of cities and villages;
- percentage of farming or pastoral lands mined compared to those still available for economic activity; livestock lost; water sources infested, riverbanks rendered inaccessible;
- regions containing mineral resources; electric projects and pylons.

### **4. Percentage of civilian population affected in socio-economic terms:**

- loss of income;
- debt incurred following mine accidents;
- obligation to change residence because of the presence of mines.

### **5. Public or community programmes disrupted because of mines:**

- repatriation of displaced persons or refugees;
- rural immunization campaigns;
- access to schools.

### **6. Population density compared to density of mines laid.**

---

15 See: Hobbs L, McDonough S, O'Callaghan A. *Life after Injury: A rehabilitation manual for the injured and their helpers*. Penang, Malaysia: Third World Network; 2002.

**7. Transportation infrastructure affected:**

- roads, airstrips, ports;
- transport of relief supplies and operational consequences;
- resumption of commercial activity.

**8. Indigenous mine clearance capacity.****9. Security concerns:**

- ongoing conflict or post-conflict situation;
- new mines being laid;
- banditry, which can disrupt mine-clearance work.

**10. Method of laying mines:**

- by irregular forces or classically trained army;
- minefields marked and fenced off or not;
- existence of maps indicating mined areas;
- remotely delivered mines (cannon, helicopter, etc.) or hand placed.



**Part B**

# **LIMBS**

B.	LIMBS	
B.1	Introduction	77
B.2	Wound ballistics	78
B.3	Epidemiology	78
B.3.1	Mortality	78
B.3.2	Incidence	79
B.3.3	Combined bone and vascular injuries	80
B.3.4	Classification systems	80
B.4	Emergency room care	80
B.4.1	Initial examination	80
B.4.2	Complete clinical examination	81
B.4.3	X-ray evaluation	82
B.5	Surgical decision-making	82
B.5.1	Limb salvage versus amputation	84
B.5.2	Damage control for limb injuries	84
B.6	Patient preparation	85
B.6.1	Theatre use of a tourniquet	85
B.7	Surgical treatment	86
B.7.1	Initial wound excision	86
B.7.2	Initial post-operative care	88
B.7.3	Second operation: delayed primary closure	88
B.7.4	Definitive post-operative care	89
B.8	Topical negative pressure and vacuum dressing	90
B.9	Crush injury of the limbs: rhabdomyolysis	90
B.9.1	Extended tourniquet use: pseudo-crush syndrome	91
B.10	Compartment syndrome and fasciotomy	91
B.10.1	Fasciotomy of the foot	93
B.10.2	Fasciotomy of the lower leg	93
B.10.3	Fasciotomy of the thigh	94
B.10.4	Fasciotomy of the forearm and hand	94
B.10.5	Closure of fasciotomy incisions	95
B.11	Reconstructive surgery of the limbs	96
ANNEX B.1	Pneumatic tourniquet	97
ANNEX B.2	Crush injury	98



## Basic principles

Nowadays war wounds of the limbs seldom kill.

Limb wounds constitute the main surgical burden in hospitals treating the war wounded.

Injury to the limbs is a significant source of morbidity and disability.

Limb salvage as opposed to early amputation is very difficult in resource-poor settings.

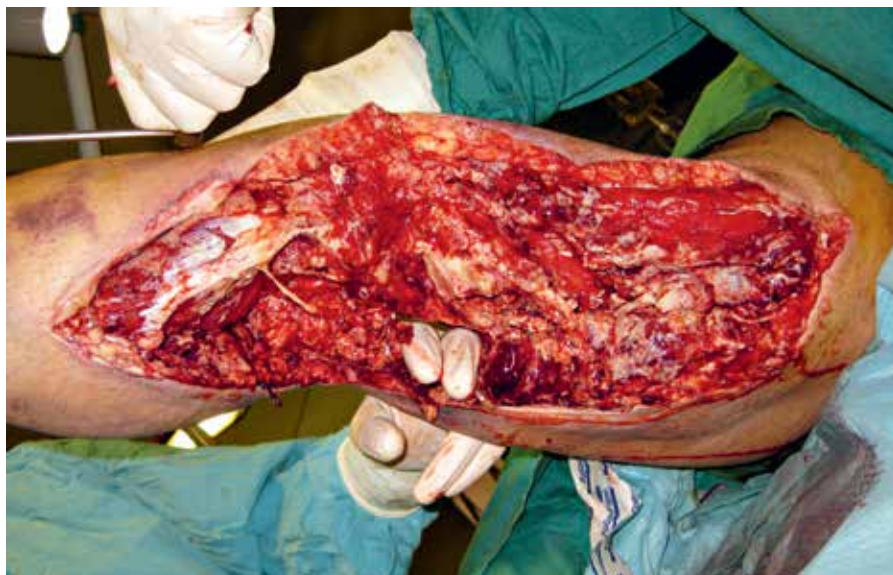Debridement and delayed primary closure are the basis of surgical treatment.

Fasciotomy is an important adjunct to the surgical treatment of many conditions.

Initial holding of fractures should be simple using splints, plaster-of-Paris (POP) or traction.

## B.1 Introduction

The management of war wounds of the extremities, more than in any other body system, requires a change in the mindset of the surgeon when working with limited resources. This is often difficult, especially for the trained orthopaedic surgeon.



**Figure B.1**

This patient has a fracture but that is not his primary problem.

ICRC

Limited resources usually mean “operating theatres of doubtful sterility and lack of adequate equipment and human resources making operative treatment of fractures impossible in many ... health care facilities”. Often this state of affairs is further complicated by the inappropriate training received by doctors from low-income countries in sophisticated hospitals in the wealthier parts of the world where “only casual reference to conservative fracture treatment” is made in standard textbooks. Frequently, the result is “doctors resorting to procedures that are either ill-suited to the local situation or to which they are not particularly conversant nor competent to perform.”<sup>1</sup>

All surgeons working in armed conflict should know the basic techniques of wound and fracture management.

Part B addresses the management of war wounds of the limbs by non-specialist surgeons using largely conservative techniques and methods. It is intended as a practical guide, whether or not the surgeon has had special training in orthopaedic trauma. Because limb wounds are so common during armed conflict, all surgeons must have some knowledge of basic fracture management.

<sup>1</sup> Museru LM, Mcharo CN. The dilemma of fracture treatment in developing countries. *Int Orthop* 2002; **26**: 324 – 327.

## B.2 Wound ballistics

It is in the limbs that all the classical phenomena of wound ballistics described in Chapter 3 are fully encountered. Specific ballistic effects affecting bones, blood vessels and nerves are discussed in separate chapters.

The commonest wounding agent in most modern combat is the fragment, whose non-aerodynamic irregular shape causes ballistic instability, with an early transfer of kinetic energy. All fragment injuries have the same wounding profile: a cone of tissue destruction which is greatest at the surface.

Primary blast waves produce a significant transfer of kinetic energy that can avulse soft tissues and open up fascial planes allowing severe contamination by fragments and other foreign matter. The wound resembles a mass of poorly vascularized oedematous tissue and foreign debris. Infection and compartment syndrome are significant occurrences. These wounds are more severe than those caused by simple fragment penetration incurred beyond the primary blast effect. Clinical examination, identifying the presence of haematoma and oedema, allows the surgeon to differentiate the high-energy fragment blast wound from a low-energy simple fragment injury.

Mangled limbs and traumatic amputations in war wounds are almost exclusively seen with primary blast injury. Anti-personnel landmines cause a particular type of proximity blast trauma.

Bullets produce wounds of very different shapes. Each specific bullet exhibits a unique wounding profile, which also differs according to the bullet's velocity at impact. An FMJ bullet must hit the body at more than 600 m/sec to tumble in the tissues and produce a significant temporary cavity. Whether there is an exit wound and at what stage of the wounding channel the exit takes place play significant roles in determining the size and shape of the lesion.

The wide variety of projectiles and impact velocities and blast effects means that one can only describe general characteristics of wound ballistics. The permanent wound channel that actually confronts the surgeon may assume various shapes (punctate, cigar-like, conical or flask-like), and the damage be more or less extensive.

## B.3 Epidemiology

As in all epidemiological studies on war surgery, the problem of definitions surfaces when dealing with wounds in the extremities, multiple wounds, wounds of the limbs and soft tissues: all these terms have been used. The full definition of anatomic regions and descriptive pathological categories is not standardized, although attempts have been made in the surgical literature (see Section 5.6.2).

Any study specific to wounds of the limbs or bony pelvic girdle can be described in terms of the anatomic structures injured: the Types ST, F, V, and VF of the Red Cross Wound Score for example.

### B.3.1 Mortality

Historically, open fractures and major soft-tissue war wounds of the limbs were accompanied by a high mortality rate from sepsis. In a previous era, amputation was considered the treatment of choice for war wounds with fractures. Times have changed and gangrene, tetanus and invasive haemolytic streptococcal infection are no longer the perils they once were, although they are still encountered in patients suffering from neglected and mismanaged wounds (see Chapter 12).

ICRC studies have shown that with a minimum of first aid, fluid resuscitation and antibiotics, and even without surgery, many fatal outcomes can be prevented, although disability in these patients remains high.<sup>2</sup> It is estimated that up to 40 – 50%

<sup>2</sup> Coupland RM. Epidemiological approach to surgical management of the casualties of war. *BMJ* 1994; **308**: 1693 – 1696.

of the relatively minor wounds affecting the soft tissues and bones can be safely treated with appropriate first-aid measures alone, thus easing the burden on hospital facilities and saving scarce resources and operating time.

In contemporary armed conflict, peripheral haemorrhage is the main cause of death from limb wounds, although it is also amenable to first-aid measures. However, as mentioned, in resource-poor contexts where first aid is not available and evacuation long and difficult, infection is still a killer.

### B.3.2 Incidence

Wounds of the limbs account for 50 – 75 % of all injured patients presenting at hospital during armed conflict (Table 5.6). This percentage increases where body armour is worn by soldiers, anti-personnel mines are widely deployed, and long evacuation times “triage out” the most severely injured. Although no longer a major cause of mortality, injuries to the soft tissues and bones of the limbs constitute the greatest burden on surgical workload because of their sheer volume (Tables 5.8 – 5.11). They also are the most significant contributor to long-term disability, an important consideration in low-income countries with few resources for services such as physical rehabilitation and socio-economic reintegration.

The lower limbs are injured more often than the upper, usually in a ratio of 1.5:1 to 2:1. This can reach 4:1 if anti-personnel blast mines are widely used. In addition, fractures are present in one-quarter to one-half of all extremity wounds; again, the widespread use of APM increases their frequency.

A particular, if extreme example, comes from an ICRC hospital that received 1,033 war-wounded patients from Afghanistan over a three-month period in 1984 – 85. Fragment injuries accounted for 49.2% of the wounded patients; gunshot wounds for 22.4% and APM injuries for 28.4%. Table B.1 shows the anatomic distribution of injuries. The relatively low number of head injuries is explained by the delay in evacuation for many patients, and the 4:1 ratio of lower- to upper-limb injuries by the extensive use of APM in combat. The mechanism of injury accounts for important differences in the type of tissue injury (Table B.2).

Anatomic region injured	Percentage
Head	4.6
Upper limb	21.3
Lower limb	87.1
Thorax	8.9
Abdomen	13.6
Spine	0.8

**Table B.1** Anatomic distribution of wounds in 1,033 patients, ICRC Peshawar hospital 1984 – 85. Percentage of total number of regions injured; many patients suffered multiple injuries.<sup>3</sup>

Tissue injury	Total series	GSW	Fragment	APM
Soft tissues of limbs	73 %	67.1 %	74.9 %	70.4 %
Bone	39.1 %	59.1 %	19.6 %	62.8 %
Intrathoracic	7 %	7.4 %	8.6 %	3.7 %
Intra-abdominal	11.2 %	10.4 %	13.8 %	7.5 %
Brain	2.5 %	0	4.7 %	0.7 %
Other	3.6 %	2.6 %	3.7 %	4.1 %

**Table B.2** Distribution of wounds according to tissue type in 1,033 patients, ICRC Peshawar hospital 1984 – 85. Percentages represent incidence of specific tissue injury; total is more than 100 %.<sup>3</sup>

<sup>3</sup> Trouwborst A, Weber BK, Dufour D. Medical statistics of battlefield casualties. *Injury* 1987; **18**: 96 – 99.

In this series, wound excision accounted for 73% of the operations and amputations for 13.6%, largely owing to the high number of mine injuries. Furthermore, APM caused injury to major nerves and blood vessels in over 50% of the patients injured by them.

### B.3.3 Combined bone and vascular injuries

One-quarter to one-half of projectile wounds in the extremities involve open fractures and the major arteries are injured in 0.5% – 1.5% of the patients. Many limb wounds with fractures and severe soft-tissue damage, with and without arterial injury, can be complicated by compartment syndrome.

Combined injuries of bone and vasculature are notorious for resulting in loss of limb. During World War II when all arterial injuries were ligated, the amputation rate reached 60% in arterial injuries associated with fractures, but only 42% in isolated arterial injuries.<sup>4</sup> Surgeons working with the US armed forces in Viet Nam implemented arterial repair leading to failure and amputation in 33% of combined injuries versus only 5% in isolated arterial injury.<sup>5</sup>

More specific epidemiological considerations are to be found in the various Chapters of Part B.

### B.3.4 Classification systems

The severity of limb wounds is determined by a combination of factors: extent of soft-tissue injury; gravity of bone comminution; presence of major arterial injury; and certain physiological parameters. Assessment of the severity has given rise to a number of classification systems.

The Gustilo-Anderson classification endeavours to define guidelines for the treatment of open fractures by taking into account the soft-tissue injury and adequacy of soft-tissue coverage as well as the fracture. The Ganga Hospital Open Injury Severity Score is a refinement of the Gustilo-Anderson Classification. The Mangled Extremity Severity Score (MESS) takes into account a number of physiological parameters in addition to soft-tissue and bone injury, in an attempt to predict the success of limb salvage procedures. Originally, the basis for these classification systems was blunt civilian trauma, and, as has often been mentioned in this manual, there are substantial differences between civilian and combat trauma. Nonetheless, some surgeons have adapted them and they are often used for patients suffering the trauma of war. The reader is referred to the Selected bibliography for details on these classification systems.

#### Red Cross Wound Score

It is for war wounds in the extremities that the RCWS has proven to be of greatest prognostic value (see Sections 4.5, 5.10.4 and 5.10.5). The entry, exit, cavity and fracture parameters offer a good estimate of the effective transfer of kinetic energy in terms of tissue damage. In the case of the extremities, the Vital = Haemorrhage parameter is more of a physiological one, putting the life or limb of the patient at risk.

## B.4 Emergency room care

### B.4.1 Initial examination

Priority goes to the life-threatening conditions of the ABCDE paradigm: the only pertinent parameter in the limbs is peripheral haemorrhage due to a lesion in a major blood vessel. Control of peripheral haemorrhage is an emergency and requires immediate intervention by means of a compressive bandage, tamponade, proximal digital pressure or a pneumatic tourniquet.

4 DeBakey ME, Simeone FA. Battle injuries of the arteries in World War II: an analysis of 2,471 cases. *Ann Surg* 1946; **123**: 534 – 579.

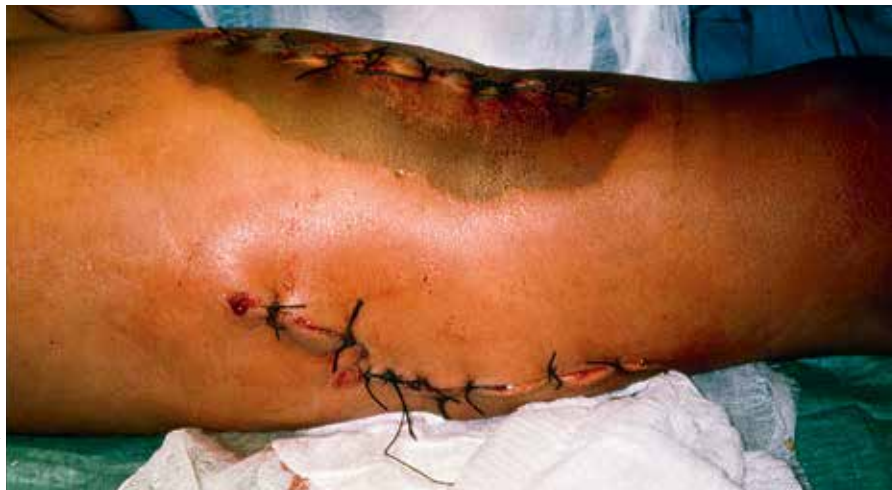5 McNamara JJ, Brief DK, Stremple JF, Wright JK. Management of fractures with associated arterial injury in combat casualties. *J Trauma* 1973; **13**: 17 – 19.

Fractures of the limbs are rarely life-threatening; however, a careful assessment must be made of the probable blood loss. Whether closed or open, bleeding from fractures may be considerable, reaching about 500 ml from the humerus and 300 ml from the radius/ulna, 1,000 – 2,000 ml from the femur and 750 ml from the tibia-fibula. These figures refer to bleeding from the bone itself, and do not take into account vascular or other injury. A casualty with multiple fractures can easily sequester enough blood in the fracture haematomas to go into hypovolaemic shock. Blood loss from extensive soft-tissue and bone wounds is frequently underestimated.

An injured limb, whether there is a fracture or not, should be splinted if this has not already been done during pre-hospital first aid, except in the case of very minor wounds. The vascular and nerve supply of the limb should be assessed and wounds covered by a sterile dressing before a splint is applied. Splints should be simple and effective. The arm may be bandaged to the side or put in a sling or on a padded wire-splint. The leg can be immobilized by one or several padded wire-splints or a Thomas splint. A splinted limb allows for optimal X-ray examination.

Tetanus toxoid, antibiotics and analgesia should be given, as per protocol.

Mismanaged wounds that have been closed primarily should have their sutures removed.



**Figure B.3**

Primarily sutured wound: fever, oedema, and the telltale signs of gas gangrene. All sutured wounds must be opened.

#### B.4.2 Complete clinical examination

The surgeon should look for entry and exit wounds, any swelling – haematoma, oedema – and fractures, and check the distal vascular and neurological status. It is important to keep in mind that:

- small entry and exit wounds can co-exist with extensive internal injury;
- compartment syndrome is an ever present possibility and danger;
- a wound in the groin or axilla may constitute a junctional trauma with injury to a major vessel in the root of the limb;
- wounds in the buttocks, thighs, or perineum can be associated with intra-abdominal injury;
- wounds of the upper arm and shoulder can be associated with intra-thoracic or neck injury;
- patients are not injured while standing in the “anatomic position”;
- projectiles do not always travel in straight lines inside the body.

Junctional trauma is discussed in Part D. The root of a limb and the adjacent region of the torso are the site of injuries that usually involve a major vessel emanating from the thorax or pelvis. The anatomic site does not allow for the placement of a tourniquet, making bleeding control problematic and usually involving entry into a torso cavity. Early diagnosis of the condition is essential. Life-saving haemorrhage control is the



**Figure B.2.1**

This traditional splint was placed pre-hospital.



**Figure B.2.2**

Kramer wire-splint.

first step; concomitant measures to preserve the limb come second. Fractures and major soft-tissue injury of the junctional region can be extremely difficult to treat and damage-control procedures are indicated in such cases.

Clinical diagnosis of injuries to the joints is based on the anatomic location of the wound, loss of function, and aspiration of intra-articular blood. A reverse arthrocentesis test may be helpful: under full aseptic precautions a solution of methylene blue is injected by syringe into the joint and exits through any wound.

### B.4.3 X-ray evaluation

X-rays are not required as a routine and judgement is necessary to determine which patients really need them; an important consideration when resources are scarce. If radiography is readily available, then all patients with limb wounds should be X-rayed after initial stabilization, except for cases with through-and-through soft-tissue wounds. The joints above and below any fracture site should be included and two views taken. For injuries in junctional areas, the proximal body region should also be X-rayed.

Note should be made of deformation or fragmentation of a bullet ("shower of lead") denoting massive transfer of kinetic energy to the soft tissues (see Section 10.2). Furthermore the presence of intrafascial or intramuscular air in healthy tissues some distance from the wound is usually due to temporary cavitation or blast effect and not clostridial infection (see Section 10.2 and Figures 10.6 and 21.12.1).

Intra-articular air or foreign bodies indicate penetration of the joint. The surgeon should remember that many foreign materials are not radio-opaque.

## B.5 Surgical decision-making

When dealing with projectile trauma, many authors, including those writing this manual, contrast "civilian" with "combat" wounds. Many authors contrast "civilian" with "military" or "combat" projectile wounds, including those writing this manual. The differences involve context and working conditions as well as wound pathology. It is more appropriate, and a better use of ballistics knowledge, to speak of energy-transfer wounds. Low-energy transfer wounds are found in both situations and the conservative approach developed by civilian surgeons is probably the most appropriate for most patients. On the other hand, medium- and high-energy transfer projectile wounds require the more aggressive attitude of classical war surgery.

Not all war wounds are equal.

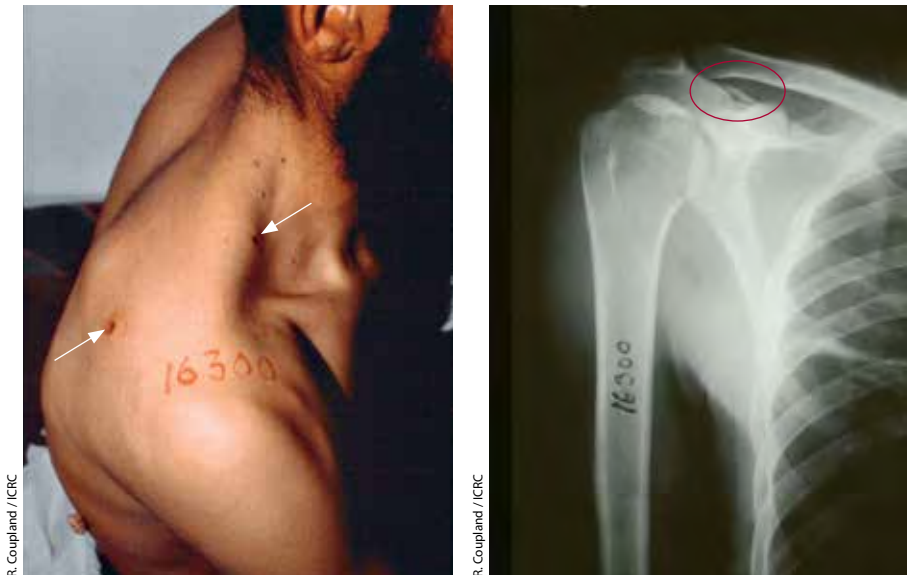
Patients do not present with wounds labelled "low-" or "high-energy transfer". A number of clinical signs assist the surgeon in evaluating the extent of tissue damage and the necessity for surgical treatment. Some telling clinical landmarks are listed below and many can be given RCWS equivalents even before surgery.

- Any wound with actual or possible vascular compromise requires exploration, whatever the extent of soft-tissue and bone damage.
- Injuries with entry or exit wounds exceeding 2 cm in diameter should be debrided.
- A limb that is swollen and tense to palpation denotes the presence of significant haematoma and/or oedema and is a good indication of soft-tissue damage requiring debridement.
- A wound that is frankly infected, no matter how small, requires surgery.
- Bullet fragmentation on X-rays (M = 2 according to the RCWS) indicates a high level of kinetic energy transfer with severe soft-tissue damage requiring debridement.

- Comminuted fracture with displaced fragments on X-rays (F = 2 according to the RCWS and therefore a Grade 2 or 3 wound) also indicates a significant transfer of kinetic energy necessitating surgery.

### Low-energy transfer wounds

Wound excision is not required for punctate superficial soft-tissue wounds due to fragments (see Figures 10.15.1 and 10.15.2). These injuries can be described as Grade 1 soft-tissue wounds according to the RCWS. Neither is debridement necessary for wounds with uncomplicated fractures without displaced bone fragments and with an entry and exit wound less than 2 cm wide: Grade 1, Type F1 wounds. Projectiles lodged in the bone or in the fracture haematoma of such wounds do not need to be removed.



Figures B.4.1 and B.4.2

Low-energy wound with no evidence of haematoma or oedema formation.

These injuries are equivalent to the low-kinetic energy handgun wounds regularly seen and often treated conservatively in civilian practice. At most, minimal excision of the devitalized skin margins to assist drainage is sufficient. Otherwise, non-operative management consists of simple wound cleansing and dressing, tetanus prophylaxis and a course of penicillin. The wounds are left open to heal by secondary intention.

The routine "over-debridement" of such wounds uses up scarce material resources and operating time, fills the wards unnecessarily, and places more burden on the nursing staff. The exception is wounds due to anti-personnel mine fragments whose degree of contamination with organic material is such that excision is mandatory.

Another exception is a low-energy wound in a joint; any metallic foreign body should be removed, the joint washed out, and the synovium and/ or capsule closed.

### Medium- and high-energy transfer wounds

Larger RCWS Grade 1 wounds (greater than 2 cm entry or exit) and Grades 2 and 3 require surgical exploration and consideration for the management of the entire limb since soft-tissue injury is usually extensive, the neurovascular bundle is at greater risk, and fractures tend to be more comminuted.

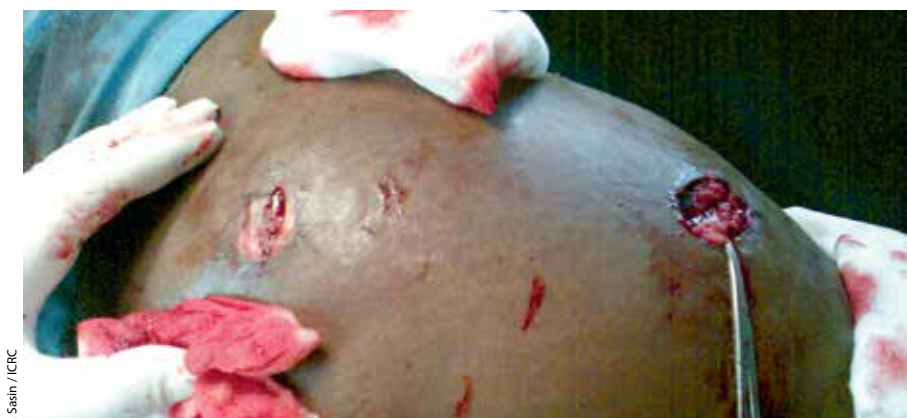

Figure B.5

Medium-energy wound of the right gluteal region.

### B.5.1 Limb salvage versus amputation

Whether to try to save a limb or proceed with amputation is one of the most difficult decisions in orthopaedic trauma.

Certain wounds in the extremities are near-traumatic amputations in their own right: extensive loss of soft tissue, severely comminuted bone, and section of the neurovascular bundle. There is little room for discussion when faced with such an injury.

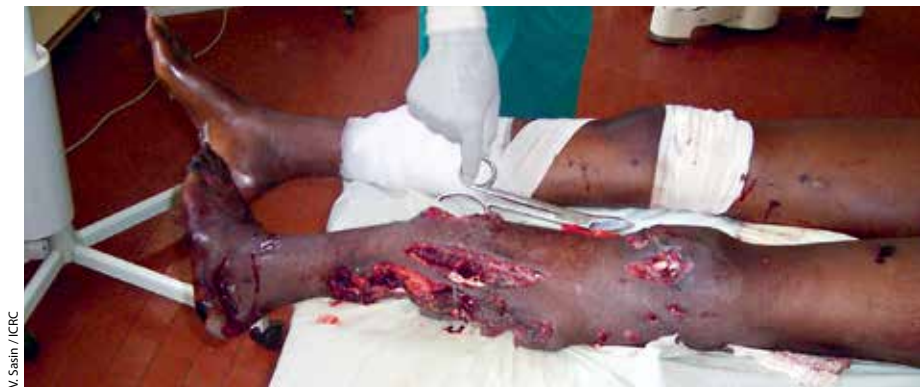There are, on the other hand, less extensive injuries that nonetheless put the limb in danger and present the surgeon with the dilemma of “limb salvage”. This is also often the case with crush injury or because of the prolonged and inappropriate use of an improvised field tourniquet. Of course, the life of the patient has priority and a limb might have to be sacrificed to preserve life.

Saving a limb may require an inordinate amount of work and resources to obtain an unpredictable functional result. Multiple operations to salvage the limb mobilize extensive resources and their inherent complications increase morbidity and consume even more resources. Sophisticated reconstructive procedures are not simple and necessitate specialized training. Even in the hands of experts, failure is common. In a military context the decision to proceed with early amputation may be easier to assume than in a civilian one.

Cultural concerns are also important. Many ICRC surgeons have had to “negotiate” an amputation with family and clan members. The individual surgeon must determine the best policy to follow according to the resources available – including the availability of physical rehabilitation services and prostheses – while taking into account the cultural context, yet never forgetting that the priority is to save life rather than limb. Even this last statement must be qualified; in some societies, people prefer death to the physical mutilation of an amputation and the wishes of the patient and family must be respected.

Figure B.6

High-energy multiple gunshot wounds of the left leg. Salvage of the limb can be problematic.



### B.5.2 Damage control for limb injuries

When faced with a patient suffering the lethal triad of hypothermia, acidosis and coagulopathy, abbreviated operations should be the rule. It must be kept in mind that “damage control is a principle, a treatment mode applied to severely-injured trauma patients with deranged physiology, to restore the physiology rather than the anatomy ... it is all about physiology”.<sup>6</sup>

Although usually employed for life-threatening abdominal or thoracic injury, several examples can be given for wounds of the limbs. A prime case is a temporary vascular shunt in a haemodynamically unstable patient. Another is a patient requiring an emergency laparotomy or thoracotomy and suffering numerous shrapnel injuries to the limbs “ranging in size from 2 to 6 cm in diameter and up to 5 – 8 cm deep. [The wounds are] quickly packed with the patient in the left or right lateral decubitus

6 Balogh ZJ discussion of Scannell BP, Waldrop NE, Sasser HC, Sing RF, Bosse MJ. Skeletal traction versus external fixation in the initial temporization of femoral shaft fractures in severely injured patients. *J Trauma* 2010; **68**: 633 – 640.



positions. The patient is then positioned in the supine position and laparotomy and/or thoracotomy initiated". The shrapnel wounds are dealt with at an opportune moment.<sup>7</sup>

The same logic underlies delayed or serial debridement in the treatment of certain patients, as in the example of our Afghan colleagues dealing with severe APM injuries described in Section 18.1. When faced with the traumatic amputation of one leg and extensive injury to the other, the shortage of blood for transfusion compelled them to a simple washing and dressing of the "intact" limb after completion of the surgical amputation. Debridement of the remaining leg was undertaken the next day after provision of blood and stabilization of the patient.

## B.6 Patient preparation

First, and foremost, is patient hygiene. Except for those with catastrophic bleeding, all patients should be showered before entering the operating theatre. Then, under anaesthesia in the OT, the affected limb and the wound should be scrubbed clean with soap and water and rinsed, and excessive hair shaved if necessary.

Wash the patient; wash the wound, with soap and water and a brush.

Positioning of the patient on the operating table and draping should allow proper exposure for any vascular exploration or for wounds on the posterior surface of the limbs.

All limb wounds can be debrided under ketamine anaesthesia, a few under local anaesthesia. Spinal and intravenous regional anaesthesia may prove useful at delayed primary closure.

### B.6.1 Theatre use of a tourniquet

Apart from minor injuries, limb wounds can best be debrided under a tourniquet to provide a bloodless field and minimize blood loss. However, the proper use of a tourniquet cuts off all blood supply to a limb causing tissue anoxia; it makes it difficult to assess tissue viability, and adds to any pre-existing ischaemic injury. Its use in general should be as short as possible and, especially in vascular trauma, limited to the time necessary for proximal and distal control of the bleeding vessel; it should then be released to allow the collateral circulation to the distal part of the limb to resume. The use of a tourniquet in the elderly with probable atherosclerotic changes, as well as in patients with sickle-cell disease, has given rise to some debate. In general, the benefits nevertheless appear to outweigh any hypothetical risks.

An operative tourniquet is a surgical instrument and should be treated as such. An Esmarch bandage, used to exsanguinate a limb prior to elective surgery, can be used as a tourniquet; but it is difficult to apply to the appropriate pressure. Over- and under-tightening are common pitfalls; practice and experience help determine the correct tightening and applied pressure.

By far the preferable option, if available, is a pneumatic tourniquet which works on the same principle as a sphygmomanometer and is provided with cuffs of different sizes. An ordinary blood pressure cuff can often be used as a tourniquet for children or on the upper limb of a thin patient. Although automatic tourniquets are commercially available, the most common type is hand-powered using a sphygmomanometer bulb or bicycle pump for inflation.

Proper care and use of a pneumatic tourniquet is described in Annex B.1.

<sup>7</sup> Almogly G, Belzberg H, Mintz Y, Pikarsky AK, Zamir G, Rivkind AI. Suicide bombing attacks: update and modifications to the protocol. *Ann Surg* 2004; **239**: 295 – 303.

## B.7 Surgical treatment

The key principles of wound excision and delayed primary closure, as described in Chapter 10, take soft-tissue and skeletal wounds of the limbs as their basis. This Section only aims to emphasize a few essential practical points.

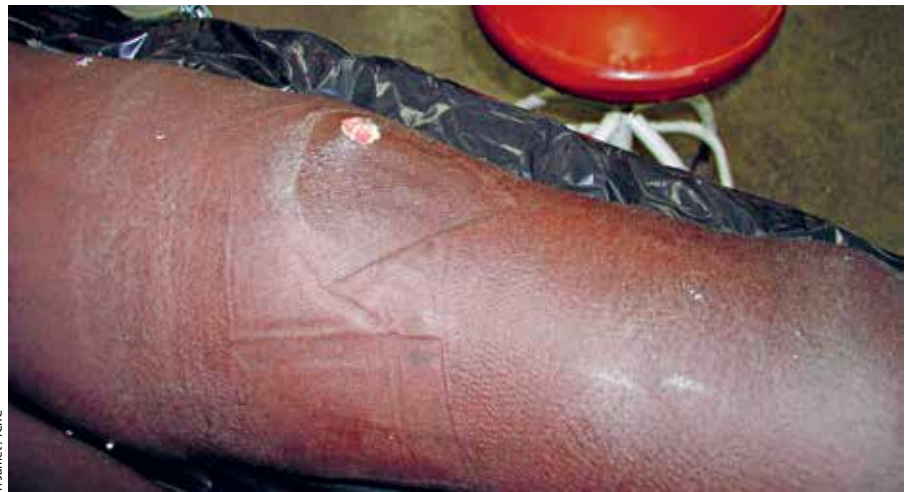### B.7.1 Initial wound excision

Wound excision is best performed in a systematic sequence, layer by anatomic layer, from the skin through the soft tissues down to the periosteum and bone.

1. Debridement of the skin wounds themselves should be conservative. Access to the wound track is through generous skin incisions in the long axis of the extremity, with deviation in the usual manner if the incision crosses a flexion crease. Deep fascia must be divided throughout the length of the incision to allow adequate exposure and decompression of the tissues (see also Figures 10.9.1 – 10.9.4).

Figure B.7.1

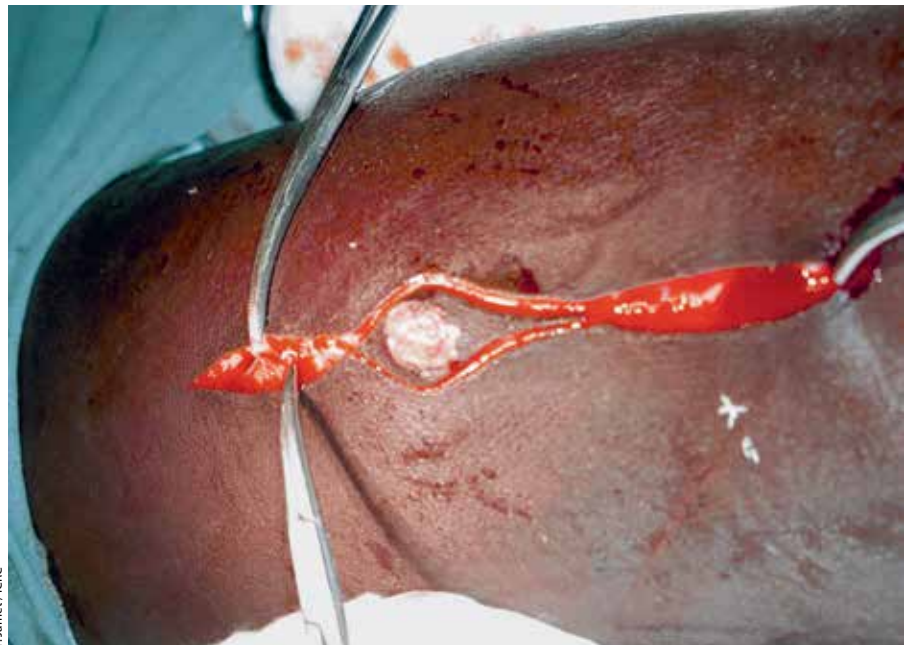
Entry wound on anterior aspect of thigh.



F. Jamez / ICRC

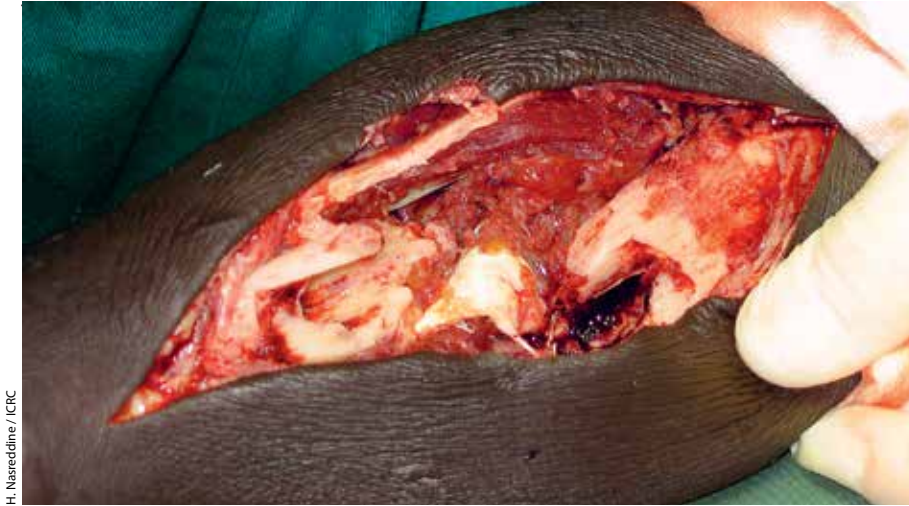
Figure B.7.2

The skin and deep fascia are widely incised to decompress the tissues and gain access to the depths of the wound.



F. Jamez / ICRC

2. The open exposed wound now allows proper finger exploration of its contents. The surgeon should wear two pairs of gloves and beware of sharp fractured bone ends. The wound cavity is often filled with haematoma and pulped muscle, bone fragments, debris and foreign material.



H. Nasreddine / ICRC

**Figure B.7.3**

The exposed wound cavity.

3. Muscles are debrided in the routine manner and all foreign material removed. The volume of damaged muscle in the permanent wound channel after all temporary effects have subsided is difficult to judge. Inexperience on the part of the surgeon leads either to inadequate surgery, infection and repeated debridements or to an overestimation of the amount of non-viable muscle and over-excision of the wound.
4. Fragments of cortical bone without any attachment should be discarded and the fractured bone ends aligned.
5. A major blood vessel should be repaired, shunted, or ligated.
6. The cut ends of a severed nerve should be tagged with a coloured non-absorbable suture and fixed to a nearby muscle to prevent retraction. It should not be repaired primarily.
7. Damaged parts of tendons are excised and loose frayed edges trimmed. The cut ends are tagged and fixed as when dealing with nerves. Any repair should be a delayed procedure.
8. After haemostasis at the completion of surgery, the surgeon should check that there is adequate decompression of all compartments that might be under tension. A formal fasciotomy extending throughout the entire anatomic compartment may be required.
9. The wound should then be irrigated by the simple pressure of a gently squeezed plastic i.v. bag or by the gravity-flow from a hanging bag, or by using a large syringe: up to 9 L for a large Grade 3 wound, 6 L for a Grade 2, and 2 – 3 L for Grade 1 wounds.

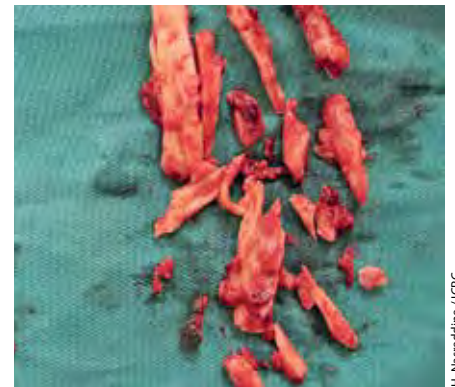Different solutions have been used historically (hydrogen peroxide, Eusol and Dakin solution, diluted povidone iodine, benzalkonium chloride and Castile soap) and considerable controversy surrounds their use. Many delay wound healing and are deleterious to the remaining healthy tissues, accounting for the rebound effect of increased wound bacterial counts 48 hours after irrigation.<sup>9</sup> This also occurs with normal saline, but much less than with other irrigation solutions.

Simple *normal saline* or *potable water* remain the best irrigation solutions and most readily available.

10. Any fractures are then stabilized with an initial method of bone immobilization.

**Foreign bodies removed from war wounds at a US hospital in Viet Nam, 1965 – 66<sup>8</sup>**

- bullets and shell fragments
- pieces of clothing
- grass and leaves
- sand and stones
- nails, nuts, bolts and screws and pieces of wire
- pieces of tin can
- glass fragments
- grease
- insects (dead and alive) and worms
- water buffalo faeces



H. Nasreddine / ICRC

**Figure B.7.4**

Unattached fragments of cortical bone are removed.

8 Adapted from Keggi KJ, Southwick WO. *Early Care of Severe Extremity Wounds: A Review of the Vietnam Experience and Its Civilian Applications*. AAOS Instructional Course Lectures, Vol. XIX: 183 – 203. St. Louis, MO: C.V. Mosby Co.; 1970.

9 Owens BD, White DW, Wenke JC. Comparison of irrigation solutions and devices in a contaminated musculoskeletal wound survival model. *J Bone Joint Surg Am* 2009; **91**: 92 – 98.



F. Jamet / CRC

**Figure B.7.5**  
The wound is left open without any suturing and covered with a large bulky dressing.

11. The wound should afterwards be left open to drain, not sutured primarily or packed tightly. It is finally dressed with a layer of fine mesh gauze in contact with the raw surface and a bulky non-occlusive dressing of loose, fluffed dry gauze and absorbent cotton wool held in place with an elastic bandage providing gentle compression.
12. Even in the absence of a fracture, the limb may be immobilized in an appropriate splint to help reduce pain and oedema.

Never close war wounds primarily.

**B.7.2 Initial post-operative care**

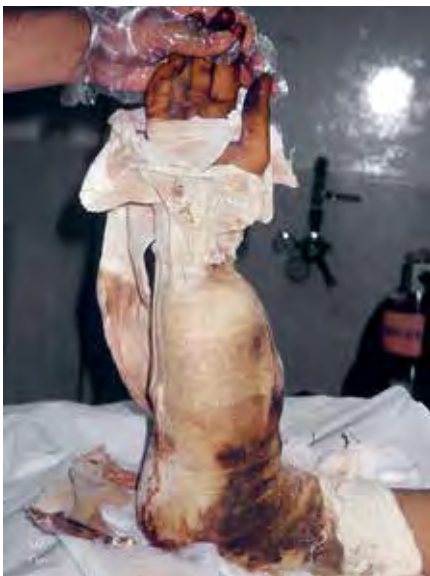The limb is kept elevated and physiotherapy commenced the day after wound debridement.

Constant vigilance must be maintained to make sure the onset of vascular complication or infection is quickly detected. Severe increasing pain that is out of proportion with what can be expected requires immediate intervention. Pain on passive flexion or extension of the fingers or toes is the single most sensitive sign of compartment syndrome requiring re-operation. Signs of acute infection also demand immediate inspection of the limb in the theatre.

If sanguineous exudate seeps through the dressing the wound should not be exposed: an overdressing with more gauze and cotton should be performed, removing the soiled dressings if necessary but not the last compress in contact with the wound. Otherwise, the dressing should be left intact until return to theatre for DPC.

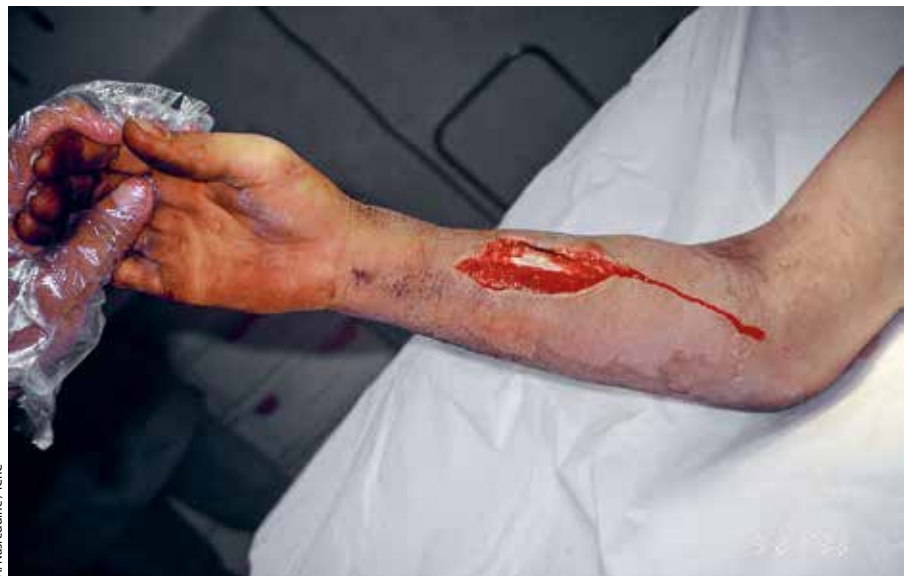**B.7.3 Second operation: delayed primary closure**

Soft-tissue oedema should have more or less settled within 5 days following debridement: the optimum time for delayed primary closure. A clean wound ready for DPC presents a final gauze compress sticking to the fibrin of the raw surface. Upon its removal, the muscle contracts and bleeds.



H. Nasreddine / CRC

**Figure B.8.1**  
Wound dressing at DPC showing dried blood and serum and giving off the “good bad odour” of a clean wound.



H. Nasreddine / CRC

**Figure B.8.2**  
Clean wound ready for DPC.

Many wounds and open amputation stumps often have a particular ammoniacal odour that can lead the inexperienced surgeon to believe that infection is present. ICRC surgeons have called this the “good bad odour” that is due to the products of serum protein degradation. It is quite normal and should not be confused with the “bad bad odour” of an infective process. In addition, wounds are sometimes covered by a yellowish film when bandages are taken down in the theatre. However, the distinction must be made between the yellowish colour of fibrin and that of pus. DPC must never be performed over pus but the presence of fibrin will not adversely affect healing.

#### Old lesson for new surgeons

The surgeon must learn the difference between the “good bad odour” of a clean wound and the “bad bad odour” of an infected one.

It is usually sufficient to close the skin alone with large, widely-spaced interrupted sutures; the deeper tissues collapse into place. A drain may have to be placed if there is any dead space. If the wound cannot be sutured without tension, skin grafting and/or a local rotation skin flap should be used. It may be possible to partially suture the wound; the defect should then either be grafted or left to heal by secondary intention. Skin grafting may be performed immediately or delayed for several days, depending on the anatomy of the specific wound.

If the wound is infected or further necrotic tissue has become apparent, it should be re-excised, any loose bone fragments removed, and the wound left open again. The patient returns to theatre for DPC 4 – 5 days later. The tendency for the inexperienced surgeon is to re-visit the wound every day or so. This usually increases trauma to the wound, delays healing, and exposes the patient to nosocomial infection.

At the time of the second operation, a decision can be made about the best method for the definitive fixation of fractures.

One major exception to performing DPC: the hospital is so overwhelmed with new patients arriving on a daily basis that there is no opportunity to re-operate the old patients for DPC. The Orr-Trueta method of POP casting of the limb after debridement is particularly useful in this situation and the wounds heal by secondary intention (see Section 22.8.3).

#### B.7.4 Definitive post-operative care

Nursing care and physiotherapy continue, as well as observation for any signs of infection. The patient should be mobilized with crutches unless on skeletal traction. Exercises to maintain muscle mass and joint mobility are important. Proper nutrition and patient hygiene must never be neglected.

Drains should be removed as soon as possible, usually within 24 – 48 hours. A clean, dry wound requires no change of dressing until removal of sutures as per routine.

If a large cavity not amenable to flaps or grafting persists, the wound should be left to granulate until such a time as skin grafting or a rotation flap can be performed. Repeated dressings with honey or sugar have been used throughout history to enhance the formation of granulation tissue and many ICRC teams have resorted to this technique; it is especially useful in cases of chronic infection (see Section 22.9.7 and Annex 22.D). Although much of the evidence is anecdotal, several clinical studies have been reported.

Superficial infection with *Pseudomonas aeruginosa* is common and can easily and cheaply be treated with dressings of acetic acid (diluted vinegar). Other superficial infections not amenable to surgery cede quickly with a change of dressing with a supersaturated saline solution, especially suitable in preparation for skin grafting (see Section 15.7.2).

## B.8 Topical negative pressure and vacuum dressing

Topical negative pressure has been used since the 1940s as a method of wound management. Experimental studies show that there exists a different metabolic environment for tissues under a vacuum and this apparently has a positive effect on wound healing by stimulating angiogenesis and formation of granulation tissue; in addition it causes physical shrinking of the soft-tissue wound. The technique was originally designed for chronic wounds, but it has been employed in the management of almost any kind of wound or skin ulcer: pressure sores, stasis and diabetic ulcers, necrotizing fasciitis, wounds with exposed bone, the open abdomen, securing skin grafts, etc.

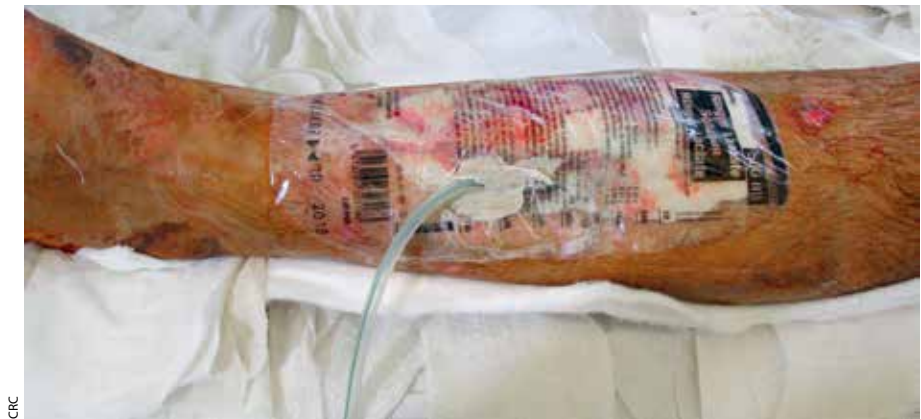Recently, vacuum assisted wound closure (VAC) has been used extensively by military forces in Afghanistan and Iraq, as an adjunct to and not a replacement for proper wound debridement. A vacuum dressing closes off the wound and protects it from the ambient environment. It is essentially the equivalent of the “bulky absorbent dressing” of standard ICRC care. Both prevent patients from “fiddling” with the wound and provide a barrier to bacterial contamination from other patients and hospital staff. Both also drain the inflammatory exudate, although the VAC is more efficient in this.

However, some authors have cautioned against its use in the management of wounds caused by blast injury. Patients have become septic and their deteriorating condition only improved when the VAC device was removed and the wounds opened.<sup>10</sup>

Another disadvantage is that commercially available vacuum-dressing devices are, at least for the time being, prohibitively expensive, particularly the constant low-flow suction apparatus. Low-cost alternatives have been improvised. ICRC surgical teams have had only sporadic experience with this method and cannot comment on this technology yet.

Figures B.9

Improvised vacuum-assisted dressing.



## B.9 Crush injury of the limbs: rhabdomyolysis

Crush injury results from persistent excessive pressure to a body part, usually the legs but the arms and trunk can also be the site of injury. It is most often seen in persons caught in the wreckage after a motor vehicle crash and after natural catastrophes such as earthquakes when people are trapped under rubble and debris. Bombardment leading to the structural collapse of a building is the wartime equivalent.

“A crush injury is a direct injury resulting from crush. Crush syndrome is the systemic manifestation of muscle cell damage resulting from pressure or crushing.”

I. Greaves et al.<sup>11</sup>

10 Marsh DJ, Abu-Sitta G, Patel H. Letter: The role of vacuum-assisted wound closure in blast injury. *Plast Reconstr Surg* 2007; **119**: 1978 – 1979. [doi:10.1097/01.prs.0000259773.52889.68]

11 Greaves I, Porter K, Smith JE. Consensus statement on the early management of crush injury and prevention of crush syndrome. *J R Army Med Corps* 2004; **150**: 102 – 106.

The degree and length of compression and the size of the muscular mass involved determine the seriousness of the injury. Crush syndrome comprises the systemic manifestations of rhabdomyolysis after reperfusion of the affected body part, subsequent to the release into the general circulation of electrolytes and the toxic products of muscle destruction. It presents as hypovolaemic shock and acute renal failure, often complicated by arrhythmias and cardiac arrest, sepsis, acute respiratory distress syndrome, disseminated intravascular coagulopathy, and psychological trauma following the extraction from debris.

Certain pseudo-crush syndromes are frequently encountered. The most common is the inappropriate and prolonged application of an improvised occlusive tourniquet, which can result in similar metabolic changes in the ischaemic limb.

#### ICRC EXPERIENCE

Unfortunately, the mistreatment of prisoners and/or civilians during armed conflict and other situations of violence occurs all too often, in contravention of human rights law and international humanitarian law.<sup>12 13</sup> Severe beatings – equivalent to repeated blunt injury – with forced dehydration can also lead to a pathology similar to crush syndrome with renal failure.<sup>14 15</sup>

The main objectives in the treatment of crush injury are to prevent the injury from turning into crush syndrome, and to salvage the limb.

Compartment syndrome is a closely related but distinct clinical entity where the capillary perfusion pressure in a closed space is less than the tissue pressure, resulting in local compromise of the circulation and viability of the tissues. It is one of the possible complications of crush injury.

Crush injury is discussed in greater detail in Annex B.2.

### B.9.1 Extended tourniquet use: pseudo-crush syndrome

Similar pathological changes to crush injury occur if an improvised occlusive tourniquet is left on for *more than six hours*. Release of the tourniquet may result in ischaemia-reperfusion injury. Close clinical examination of the limb is necessary to determine if the occlusion has been complete, unfortunately all too often the case. In this instance serial incisions are made to inspect the muscles for viability; they are usually necrotic and amputation above the level of tourniquet application is required (see Figures 7.3.1 and 7.3.2).

The dilemma arises in occlusive tourniquet application *between two and six hours duration*. Should an attempt be made to spare the limb, every precaution must be taken to lessen the development of a pseudo-crush syndrome with myoglobinuria and renal failure. Diuresis must be forced and the urine made alkaline before the staged removal of the tourniquet, as with classical crush injury. Fasciotomy should be performed for any tourniquet left on for more than two hours.

## B.10 Compartment syndrome and fasciotomy

Compartment syndrome is most often seen in the lower leg, but can also affect any other closed anatomic space or body cavity. Compartment syndrome in a limb usually occurs with less severe trauma than crush injury, but if neglected or inadequately treated can lead to similar systemic effects as with crush syndrome as the muscles undergo necrosis.

12 The 1948 Universal Declaration of Human Rights and the 1984 Convention Against Torture and Other Cruel, Inhuman or Degrading Treatment or Punishment.

13 Common Article 3 of the 1949 Geneva Conventions.

14 Bloom A, Zamir G, Muggia-Sullam M, Friedlander M, Gimmon Z, Rivkind A. Torture rhabdomyorhexis – a pseudo-crush syndrome. *J Trauma* 1995; **38**: 252 – 254.

15 François Irmay, ICRC surgeon, *Sjambok injuries, Une forme particulière de crush syndrome*. (Sjambok injuries, a particular form of crush syndrome.) Doctoral thesis N° 10002, Geneva Faculty of Medicine, 2 December 1998.

**Aetiology**

Compartment syndrome of a limb can result from a number of causes:

- multiple fractures in a single limb – more commonly in closed, but also possible after an open fracture – especially of the tibia;
- anti-personnel blast mine injury;
- multiple small fragments provoking a large intramuscular haematoma plus primary blast effect;
- any delay in limb reperfusion after vascular injury;
- crush injury;
- burn injury, particularly an electrical burn;
- cold exposure;
- snake bite;
- fracture of any bone when the patient suffers from a coagulation defect or is receiving anticoagulant therapy;
- prolonged forced position on a hard surface, also noted after mistreatment of prisoners.

Iatrogenic causes include prolonged application of an occlusive tourniquet or tight plaster cast and extravasation of an i.v. drip or intra-osseous infusion.

**Pathogenesis**

A vicious cycle sets in: tissue oedema in a tight closed space causes a rise in compartment pressure gradually leading to a compromise of the microcirculation with consequent tissue hypoxia. The hypoxia and by-products of cell death cause further oedema. When the compartmental pressure rises high enough, occlusion of the macro-circulation supervenes. The resultant ischaemia affects all vital structures in the compartment, including muscles, nerves, blood vessels and lymph channels.

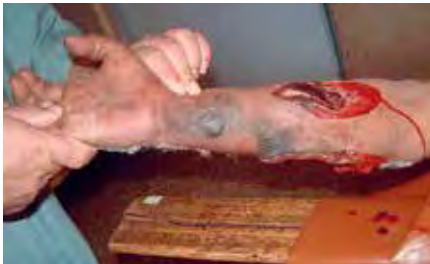**Clinical picture**

By far the most common occurrence of compartment syndrome is in the lower leg. The earliest and most important clinical sign of compartment syndrome in a limb is excessive pain out of proportion with the stimulus, especially on passive extension or flexion of the toes or fingers. The muscles become tense, swollen and hard and other signs of ischaemia appear including pallor and paraesthesia. The pulse may remain normal for some time.

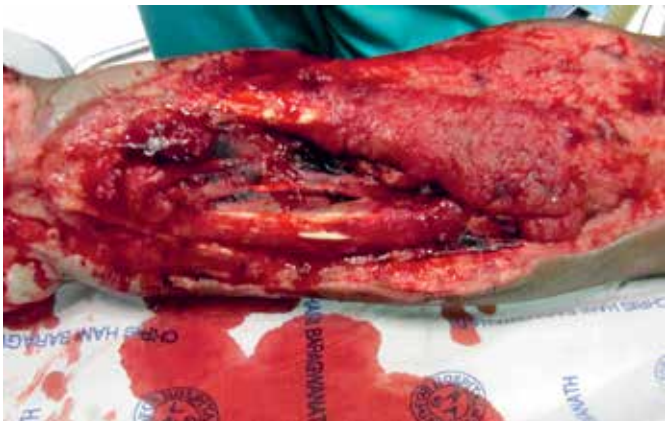**Treatment**

Decompression must be performed without delay if there is any suspicion of compartment syndrome.

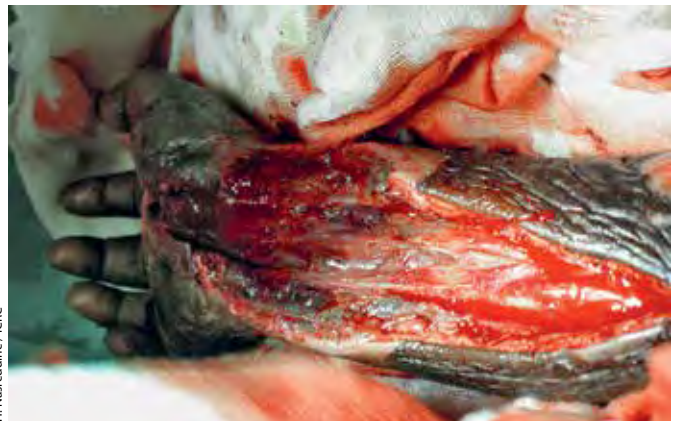
Compartment syndrome is a surgical emergency and fasciotomy should be carried out as soon as the suspicion of its existence arises.



**Figure B.10.1**  
Compartment syndrome of the forearm.



**Figure B.10.2**  
Compartment syndrome of the forearm with viable muscles.



**Figure B.10.3**  
Necrotic muscles following compartment syndrome of the forearm.



If compartment syndrome is fully established at fasciotomy and the muscles are found to be necrotic, they should be excised and treatment instituted by the anaesthetist in theatre as for crush syndrome, including a bolus injection of sodium bicarbonate and mannitol to prevent acute renal failure.

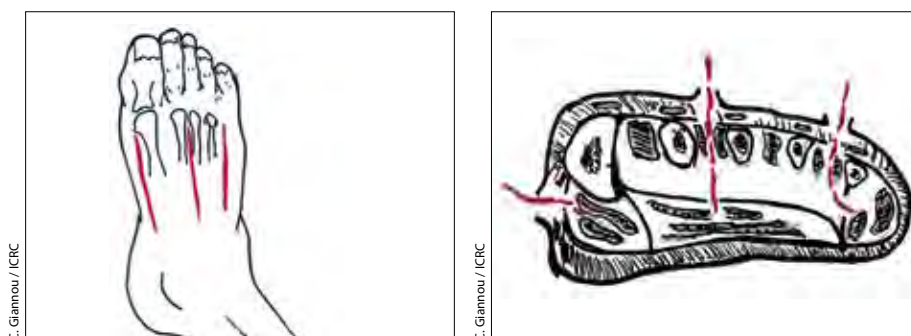
The fasciotomy incisions should be left open for delayed primary closure.

The limb should always be elevated afterwards. Delayed primary closure after subsidence of oedema and re-establishment of normal circulation is standard procedure. Infection is common and amputation is often the final result.

### B.10.1 Fasciotomy of the foot

The four compartments of the foot are decompressed through three dorsal incisions. The medial incision follows the lower border of the first metatarsal and extends up to the medial malleolus; it goes through the tough and thick plantar fascia. This decompresses the medial compartment and, by dissection, the central plantar space.

The lateral incision is made between the fourth and fifth metatarsals, decompressing the central dorsal space and, by lateral extension through the fascia into the lateral compartment. The final middle incision is performed between the second and third metatarsals to enter the central dorsal space and continued down into the central plantar space all the way to the plantar fascia.



Figures B.11.1 and B.11.2  
Incisions for fasciotomy of the foot.

### B.10.2 Fasciotomy of the lower leg

Adequate decompression involves all four compartments of the lower leg through two generous skin incisions. The fascial incisions should include the *entire length* of the respective fascia. The greatest error lies in making incisions that are too short.

The posterior compartments are best approached through a single incision extending from the knee to the medial malleolus, 2 cm posterior to the palpable postero-medial edge of the tibia. The deep fascia is incised to open the superficial compartment, the medial gastrocnemius and soleus muscles are pulled down and the fascia over the deep posterior compartment opened. Care must be taken not to injure the posterior tibial artery, tibial nerve or saphenous vein. This incision can be extended proximally to provide access to the popliteal vessels.

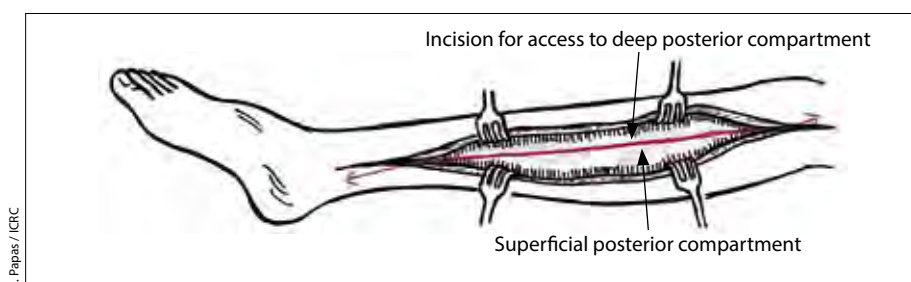
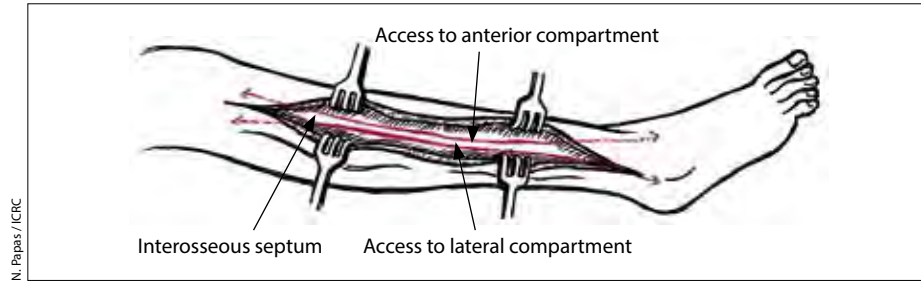
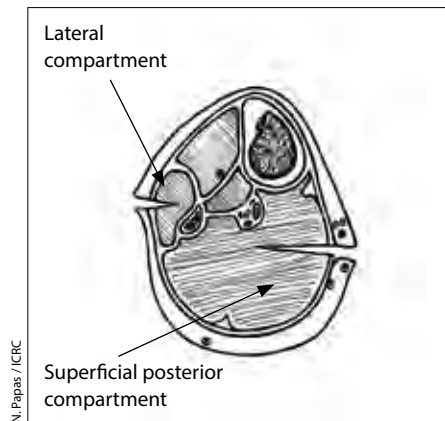


Figure B.12.1  
Medial fasciotomy incision.

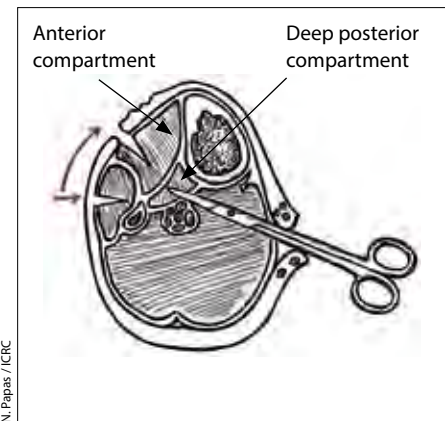
**Figure B.12.2**  
Anterolateral fasciotomy incision.



The anterior and lateral fascial compartments are approached through a single longitudinal incision extending from the knee to the lateral malleolus, 2 cm anterior to the shaft of the fibula, thus overlying the anterior intermuscular septum separating the two compartments. A nick is made in the deep fascia of one compartment and then the other, and the fascia slit open proximally and distally with long round-ended scissors. Care is taken to avoid the peroneal artery.



**Figure B.12.3**  
Decompression of the lateral and superficial posterior compartments.



**Figure B.12.4**  
After opening the lateral compartment, the skin flap can be rotated to gain access to the anterior compartment. The deep posterior compartment is accessed through the superficial compartment.

### B.10.3 Fasciotomy of the thigh

There are three compartments to decompress in the thigh – anterior, posterior, and the adductor – requiring two incisions. A lateral incision beginning at the greater trochanter and extending to the lateral condyle of the femur is carried down to split the fascia lata, allowing entrance into the anterior compartment. Subcutaneous dissection downwards allows for an incision just behind the fascia lata and the lateral fascial septum, affording entry into the posterior compartment.

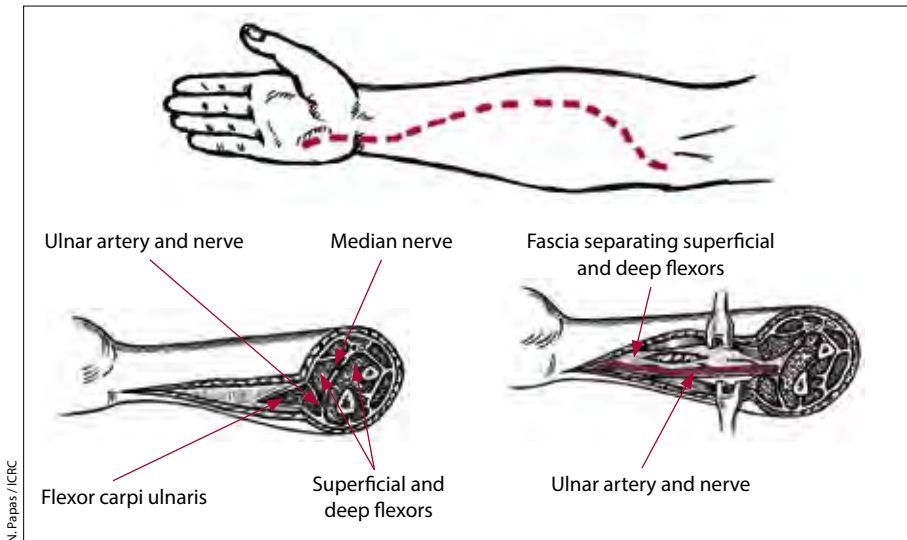
The adductor compartment can be entered by the standard incision for access to the femoral vessels.

### B.10.4 Fasciotomy of the forearm and hand

There are two aspects to fasciotomy in the forearm: the volar and the dorsal.

#### Volar compartments

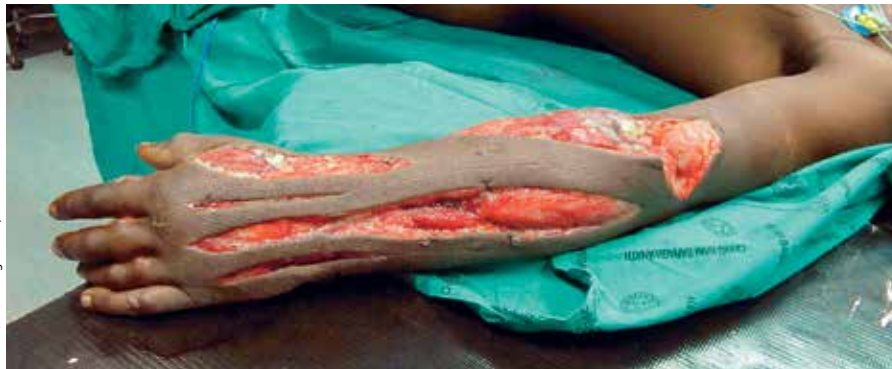A curving S-incision is made from the medial epicondyle across to the radial flexors and back to the ulnar end of the flexor crease. This is then carried across to the mid-palm immediately to the ulnar side of the thenar crease. The fascia over the flexor carpi ulnaris is incised and the muscle retracted medially; then the superficial flexor muscles are retracted laterally to reveal the fascia over the deep flexors. Each muscle is decompressed by a generous longitudinal incision of its sheath. Care is taken not to injure the ulnar artery or nerve, located between the flexor carpi ulnaris and the deep flexors.



**Figure B.13.1**  
Volar fasciotomy of the forearm.

### Dorsal compartment

A dorsal midline incision from the elbow to the wrist is carried down through the deep fascia to expose the extensor compartment. Each muscle has its own fascial sheath, which requires individual decompression. Two dorsal incisions of the hand between the second and third and fourth and fifth metacarpals complete the decompression.



**Figure B.13.2**  
Decompression of the dorsal aspect of the forearm and hand.

### B.10.5 Closure of fasciotomy incisions

The closure of a fasciotomy incision involves only the skin, leaving the fascia open. Closure of a forearm fasciotomy after 4 – 5 days and subsidence of oedema is usually not difficult. The same can be said for “prophylactic” fasciotomy of the lower leg during vascular repair.

There are many examples in the lower leg where such delayed primary closure *is* difficult, if not impossible, because it results in undue tension with subsequent necrosis of the skin edges. Split-skin grafting to cover the defect is one possibility.

Special skin-stretching devices exist, but are expensive and not always available. There are several other ingenious methods that have been developed and described over the years: skin taping, shoelace suture, etc. (see Selected bibliography). The basic idea is to induce stretching of the wound edges – skin and underlying subcutaneous tissue combined – until direct suture is possible.

## B.11 Reconstructive surgery of the limbs

War wounds, like other major trauma, often require major reconstructive surgery to obtain a reasonable functional result. Lack of surgical expertise, adequate facilities and time often limit the extent to which this type of surgery can be performed.

Nevertheless, there are occasions when appropriate reconstructive surgery is indicated and can be performed effectively, even where resources are limited. A certain number of basic techniques of reconstructive surgery are relatively simple and well within the ability of most general surgeons.

Three groups of patients and operations can be described.<sup>16</sup>

### 1. Primary emergency reconstruction performed as part of initial surgery.

In the limbs this concerns exposed blood vessels that have been repaired. A skin or muscle flap should be mobilized to prevent desiccation of the artery. The latissimus dorsi muscle can cover the axillary and brachial vessels; gracilis the femoral; and the gastrocnemius used for the popliteal vessels.

### 2. Delayed primary reconstruction performed at the time of DPC.

Significant soft-tissue loss often prevents simple approximation of the wound edges without tension, or approximation of the wound edges may be possible but a large dead space underneath makes direct suture inappropriate. Skin grafts or flaps are required to close the defect. Exposed avascular areas such as bone without periosteum or tendon without paratenon also require a flap for wound closure.

If the decision is made to apply an external fixator at DPC, simultaneous soft-tissue reconstruction can be performed and the pins placed so as not to interfere with the flap. Myoepithelial flaps, incorporating skin, fascia and muscle, are preferred.

The knee joint and upper third of the tibia are best covered by a medial gastrocnemius muscle flap. The soleus muscle is suitable for the middle third of the tibia. The muscles should be mobilized by first releasing them at the level of the Achilles tendon.

Wounds exposing the lower third of the tibia are the most difficult to manage since no local flap is available for coverage. For the general surgeon, a cross-leg flap is a major undertaking necessitating at least two stages and prolonged immobility of the patient. The subject is dealt with in greater detail in Section 22.8.3.

An abdominal skin flap is suitable for defects of the forearm, hand and wrist; wounds of the latter can also be covered by a groin flap.

### 3. Late elective reconstruction.

These procedures are usually undertaken three to six months after complete soft-tissue healing and may concern complicated wounds for which sophisticated reconstructive surgery is the only solution and special training essential. Examples include release of severe burn contractures and tendon transfer for nerve lesions. These are beyond the scope of this manual. Some simple procedures may include scar revision or replacement of split-skin grafts.

The reader is referred to standard surgical texts for operative details of the various techniques.

<sup>16</sup> Adapted from Coupland RM. The role of reconstructive surgery in the management of war wounds. *Ann R Coll Surg Engl* 1991; **73**: 21 – 25.

## ANNEX B.1 Pneumatic tourniquet

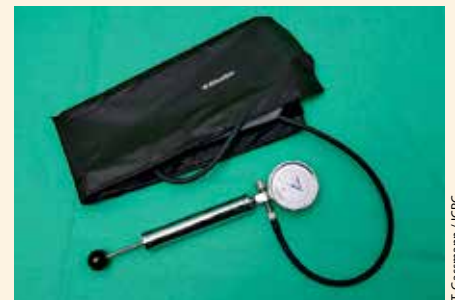A pneumatic tourniquet should be treated with as much respect as any surgical instrument; jarring, blows and shocks will damage the aneroid gauge. All parts should be inspected before use for leaks or loose connections. Regular calibration of the aneroid pressure gauge can be accomplished by hooking it up to the mercury column gauge of an ordinary sphygmomanometer. The pressure in the tourniquet is raised to 100 mm Hg on the aneroid gauge and then released into the mercury column line. This is repeated at 200 and 300 mm Hg. An inaccurate gauge should be discarded and replaced. An inflated cuff should not undergo pressure changes with time: this indicates a leak.

The use of a pneumatic tourniquet in-theatre is simple and straightforward, but a certain number of essential principles must be followed.

1. The position for a tourniquet is the thigh or upper third of the arm. The site of cuff application is covered with a layer of cotton wool three times the width of the cuff. This padding should be carefully applied and be free of folds or wrinkles.
2. As wide a cuff as possible is placed at the point of maximum circumference of the limb to spread the pressure exerted and decrease tissue damage. When wrapped around the limb, its length should exceed the circumference of the limb by at least 10 cm.

Its size should be adapted to the anatomy of the patients, especially for those of very thin or very stout build. In an obese patient it may be necessary for an assistant to grasp the fatty flesh just distal to the site of application and pull down the tissues before applying the cotton wool layer and cuff.

3. The tourniquet, cotton and cuff, is then sealed off with plastic sheeting to prevent soaking with blood.
4. The cuff should be steadily inflated to the minimum amount necessary to create a bloodless field. This is usually 50 – 70 mm Hg higher than the systolic pressure for the upper limb. Because of the large muscle mass of the thigh, the pressure needs to be greater: double the systolic pressure as measured in the arm.
5. The time of application and release of a tourniquet is recorded and the surgeon reminded periodically of ischaemia time. This is the responsibility of the entire OT team.
6. Inflation time of the tourniquet should be kept to a minimum. Different sources cite one, two or three hours. Three hours is a maximum, but most operations should require less than one and a half hours.
7. The tourniquet should be released before the end of the operation, the viability of remaining tissues confirmed and haemostasis accomplished.
8. Unless life-saving, tourniquets should never be applied to both legs at the same time.
9. Bilateral tourniquets should not be deflated simultaneously, but an interval of a few minutes allowed between the two because of the "autotransfusion" of sequestered blood that occurs.
10. The limb always swells after tourniquet use; the distal circulation should be confirmed after the final dressing and bandage have been applied, and monitored in the postoperative period as should be the standard for all limb injuries.



**Figure B.1**

Example of an adult-size pneumatic tourniquet.

## ANNEX B.2 Crush injury

Crush injury is most often seen after natural disasters such as earthquakes. It also occurs during armed conflict when buildings collapse on the occupants after bombardment. The extraction of the surviving victims may easily be delayed, bringing all the consequences of dehydration and hypothermia in its wake.

### B.2.a Pathology and pathophysiology

Continuous pressure on a body part for at least four hours or severe compression for as little as one hour causes physical disruption of the muscle fibres: acute traumatic rhabdomyolysis; and this occurs independently from any ischaemia. Although the pathology is muscular in origin, the trauma may also have caused fractures and crushing of bone.

The breakdown of a large muscle mass liberates enormous amounts of myoglobin, uric acid, potassium and other products of muscle destruction. However, these substances do not enter into the general circulation until the compression is released and the limb revascularized: reperfusion injury.

The resulting hyperkalaemia can be rapidly fatal and is the major cause of early mortality. Post-traumatic oedema develops in the injured limb owing to the sequestration of a large quantity of intravascular fluid. Hypovolaemic shock can occur in the absence of adequate fluid intake and is the second most common cause of early death. The myoglobinaemia and uric acidaemia lead to blockage of the renal tubules and acute renal failure, which is the main cause of delayed death. Other conditions leading to delayed death include coagulopathy, secondary haemorrhage, and sepsis.

### B.2.b Pre-hospital presentation and care

Depending on the time spent under compression and any other injuries, hypothermia and dehydration are often prominent. Typically the victim appears generally well, often without complaint of pain until after extraction, and then suddenly decompensates after release of the compression. This is due to reperfusion hyperkalaemia and hypovolaemia. A strong analgesic or ketamine just prior to extraction is indicated; the pain can be excruciating.

#### Precautions to be taken before extraction of a crush victim:

- fluid intake;
- application of a tourniquet;
- strong analgesia.

Early intake of fluids before extraction should be undertaken, especially if extraction is delayed. These should be given orally if the patient's condition permits and intravenous fluids are not available. If i.v. fluids are available, an immediate bolus of 20 ml per kg of normal saline should be given (1,500 – 2,000 ml in an adult), followed by 10 – 15 ml per kg per hour of half-isotonic saline (see below) until extraction. Delay in fluid resuscitation is the main overall cause of death.

The use of a tourniquet is obvious in the case of a trapped haemorrhaging limb or where extraction of the patient from under rubble and debris can only be achieved with a field amputation under ketamine anaesthesia. In the more common closed crush injury where extraction is possible without resorting to amputation its use is open to controversy. While the limb is under compression there is no need for a tourniquet. If one is to be applied, it should be done just prior to extraction to prevent the immediate "reperfusion storm", and to allow sufficient i.v. fluids to be given if this has not been possible beforehand. Evacuation time to the hospital should be taken into account in the application of any tourniquet as a general rule.

### B.2.c Clinical picture and emergency room care

Persons crushed under rubble often suffer multiple injuries. Initial examination follows the standard ABCDE paradigm and the usual resuscitation measures should be instituted.

The crushed limb itself may suffer closed injury, present an open wound, or be frankly mangled. In the first two cases the condition may mimic flaccid paralysis with a mosaic pattern of sensory loss and the condition misdiagnosed as spinal injury.

The limb is greatly swollen and tense but the oedema is not pitting at first, being entirely confined beneath the deep fascia. The skin is shiny or bruised and may present blisters. The pulses are usually present even in the presence of severe oedema.

Passage of a urinary catheter is essential to monitor the urine. Due precautions should be taken if the pelvis is involved in the crush injury.

Analgesia, tetanus and antibiotic prophylaxis are given according to protocol.

### B.2.d Medical treatment of crush injury

Patients suffering crush injury should be cared for in an intensive care unit with access to a proper laboratory, rarely available in the field. Optimum fluid therapy requires measurement of the central venous pressure and a full complement of laboratory analyses.<sup>17</sup> An intensive nursing unit with a minimum of laboratory analyses, preferably including serum electrolytes, is usually all that can be organized where resources are limited (see Part F).

The specific situation of the individual hospital determines to what extent the following protocol can be respected. Renal failure, however, is all too often the result and, in the absence of dialysis, usually leads to a fatal outcome.

Hospital resuscitation with i.v. fluids should begin *before removal of any tourniquet*, the release of which should be *staged*: the tourniquet is released then immediately reapplied and the procedure repeated several times before final definitive removal, to prevent overwhelming hyperkalaemia.

#### Main objectives of medical treatment of crush injury:

- prevent hyperkalaemia;
- overcome hypovolaemia;
- prevent crush injury from becoming crush syndrome.

The aim in the management of patients suffering crush injury is to overcome hypovolaemia and prevent renal failure by adequate fluid resuscitation, forced diuresis and alkalinization of the urine. Good clinical observation of the patient is essential to avoid overloading the circulation and precipitating pulmonary oedema.

The quantity, colour and pH of the urine should be monitored every hour. In addition, serum electrolytes should be measured every six hours, if available. Fatal hyperkalaemia is the most significant event, particularly in the first few days and in the most severely injured.

Oedema accumulates in the injured tissues as a third space sequestration; therefore the amount of i.v. fluid administered should be greater than the urinary output. To maintain the proper diuresis of 300 ml per hour requires approximately double the amount of i.v. fluids, which can be up to 12 litres per day. Fluid intake should be adapted to the clinical response of the individual patient. If close laboratory monitoring is not available, i.v. fluids should be limited to 6 litres of per day while monitoring the urine output.

<sup>17</sup> Laboratory analyses to properly care for a major crush injury should include at least full blood count, urea and electrolytes, creatinine kinase, lactate, amylase, liver function tests, clotting tests and blood grouping and cross matching.

The regimen of fluid therapy is a sequential “cocktail”.<sup>18</sup>

1. A bolus of normal saline 20 ml per kg body weight administered as quickly as possible.
2. This is followed by 10 – 15 ml per kg per hour of half-isotonic saline: normal saline diluted with glucose 5% to achieve 75 mEq/l NaCl (approximately half-and-half saline-glucose).

Alternatively, and to avoid contamination of the sterile i.v. fluids, one bag of normal saline and one of glucose 5% can be given simultaneously if two appropriate veins are available, or one litre of normal saline is alternated with one litre of glucose.

3. 50 mEq of sodium bicarbonate is added to each second or third litre of the half-isotonic saline to keep the urinary pH above 6.5. If one of the alternative methods is employed, 100 mEq is added to a litre of the glucose solution.

The repetition of bicarbonate administration is titrated to the urinary pH. It can usually be tapered off after 36 hours.

4. If diuresis is successful and urine output exceeds 20 ml per hour, 50 ml of 20% mannitol (10 g) should be added to each litre of infusion (1 – 2 g per kg per day, total 120 g) at a rate of 5 g per hour.

Mannitol protects the renal tubules, promotes the excretion of potassium, and decreases the pressure in the crushed muscular compartments.

5. Calcium gluconate 10% (10 ml) or calcium chloride 10% (5 ml) should be added daily to counteract the effects of hyperkalaemia on the heart.
6. Insulin with hypertonic dextrose in water is given to shift potassium from the extracellular back into the intracellular space according to the results of serum electrolyte analysis.
7. Recently, paracetamol (acetaminophen) in therapeutic doses (500 mg) has been shown to be protective of renal function in myoglobinaemia; clinical studies in humans are currently under way.<sup>19</sup>
8. Crush injury patients usually develop acute anaemia and ultimately require numerous blood transfusions.

The fluid regimen should continue until visible evidence of myoglobinuria disappears, denoting the end of active rhabdomyolysis, usually by 60 hours.

In spite of these measures, many patients develop acute renal failure. The prognosis then usually depends on the availability of haemodialysis or peritoneal dialysis.

### B.2.e Surgical management

Surgical treatment is limited and fraught with problems and complications.<sup>20 21</sup>

If the crush injury is open, surgery is warranted under two conditions.

- A severely mangled extremity or infection endangering the life of the patient calls for immediate amputation through healthy tissue without releasing a tourniquet if it has been applied.
- If the limb is salvageable, the surgeon should proceed with immediate fasciotomy.

18 Adapted from Sever MS, Vanholder R, Lameire N. Management of crush-related injuries after disasters. *N Engl J Med* 2006; **354**: 1052 – 1063 and Vanholder R, Sever MS, Ereik E, Lameire N. Rhabdomyolysis. *J Am Soc Nephrol* 2000; **11**: 1553 – 1561.

19 Boutaud O, Moore KP, Reeder BJ, Harry D, Howie AJ, Wang S, Carney CK, Masterson TS, Amin T, Wright DW, Wilson MT, Oates JA, Roberts LJ II. Acetaminophen inhibits hemoprotein-catalyzed lipid peroxidation and attenuates rhabdomyolysis-induced renal failure. *Proc Nat Acad Sci* 2010; **107**: 2699 – 2704.

20 The use of succinylcholine for intubation in these patients is to be avoided for up to a year after injury because it can cause massive release of potassium and cardiac arrest.

21 Adapted from: Michaelson M. Crush injury and crush syndrome. *World J Surg* 1992; **16**: 899 – 903.



If the crush injury is closed, surgery is also warranted under two conditions also.

- There is a line of demarcation of ischaemic gangrene indicating irreversible tissue necrosis that requires amputation at that level.
- The distal pulses and capillary filling are absent, denoting compartment syndrome and imminent gangrene requiring fasciotomy.

Should fasciotomy be performed, excision of all necrotic muscle must be radical. Haemostasis from bleeding muscle may be difficult and the best sign of viability is contraction on pinching or electrical stimulation with diathermy. Usually serial debridements are required and infection all too often sets in.

Otherwise, fasciotomy and debridement of bruised skin over a closed crush injury should *not* be performed. In this respect, crush injury differs from simple compartment syndrome; even the extensive myonecrosis of crush injury is not an indication for surgery. The elasticity of the skin withstands internal pressure very well; even contused it provides a barrier to infection.

Please note:

Some authors have argued that the early application of a tourniquet and amputation of a crushed limb should prevent crush syndrome by removing the reperfusion insult. However, there is no conclusive evidence to support the performance of amputation as a prophylactic measure.

There are many reports in the surgical literature that demonstrate salvage of even severely crushed limbs which eventually recover full function, but only when dialysis is available to care for renal failure. In conditions of limited resources two thirds of the patients die within a week.

The surgeon faced with a patient suffering from severe crush injury must consult with the patient and family and fully explain the situation in order to best determine the procedure to follow.

### **B.2.f Further care**

Elevation of the limbs is apparently not well tolerated and results in increased pain. Furthermore, such elevation does not appear to assist in the resorption of oedema. The patient is best left with the legs straight and flat. In addition, physiotherapy for the limbs should focus only on maintenance of muscle mass and tone, since passive movement of the joints is very painful. After 10 – 14 days the pain subsides and passive and active movements can be commenced.

Extreme caution is required for the nursing care of any open wounds. Infection frequently supervenes and often results in loss of the limb.



## Chapter 22

# INJURIES TO BONES AND JOINTS<sup>1</sup>

---

<sup>1</sup> Large parts of this chapter are based on the brochure by David I. Rowley, Professor of Orthopaedic and Trauma Surgery, University of Dundee: *War Wounds with Fractures: A Guide to Surgical Management*. Geneva: ICRC; 1996.

<b>22.</b>	<b>INJURIES TO BONES AND JOINTS</b>	
22.1	Introduction	105
22.2	Wound ballistics	105
22.2.1	Kinetic energy	105
22.2.2	Bone-projectile interface	106
22.2.3	Joints	108
22.3	Epidemiology	109
22.3.1	Anatomic distribution	109
22.3.2	Type of fracture	109
22.3.3	Joints	110
22.3.4	Red Cross Wound Score	110
22.4	Management of war wounds with fractures	112
22.4.1	Primary wound debridement	112
22.4.2	Delayed primary closure	114
22.5	Methods of bone immobilization: surgical decision-making	114
22.5.1	Plaster-of-Paris	116
22.5.2	Traction	116
22.5.3	External fixation	118
22.5.4	Damage-control orthopaedics	120
22.5.5	Internal fixation: osteosynthesis	120
22.6	Wounds involving joints	121
22.6.1	Joint debridement	121
22.6.2	Wound closure	121
22.6.3	Joint immobilization	122
22.6.4	Infected joints	122
22.6.5	Pelvi-abdominal injuries and the hip joint	122
22.6.6	Arthrodesis	122
22.6.7	Pseudo-arthritis arthroplasty	123
22.7	Hand and foot injuries	123
22.7.1	Examination	123
22.7.2	Surgical exploration and debridement	123
22.7.3	Immobilization	125
22.7.4	Delayed primary closure	125
22.8	Problematic cases	125
22.8.1	Malunion	126
22.8.2	Non-union	126
22.8.3	Chronically exposed bone	126
22.9	Bone infection	127
22.9.1	Wound management	128
22.9.2	Antibiotics for established bone infection	128
22.9.3	Surgical treatment	128
22.9.4	Preparing the patient	129
22.9.5	Radiography	129
22.9.6	Excision of the sinus	130
22.9.7	Dressing the wound and follow-up	131
22.10	Bone grafting	131
22.10.1	Indications for bone grafting	131
22.10.2	Donor site and types of bone graft	132
22.10.3	Follow-up of bone grafting	132
22.10.4	Complications of bone grafting	132
	<b>ANNEX 22. A Plaster-of-Paris</b>	<b>133</b>
	<b>ANNEX 22. B Traction</b>	<b>145</b>
	<b>ANNEX 22. C External fixation</b>	<b>156</b>
	<b>ANNEX 22. D ICRC chronic osteomyelitis study</b>	<b>163</b>
	<b>ANNEX 22. E Bone grafting</b>	<b>166</b>

## Basic principles

The soft tissues of the wound must be properly debrided.

Simple temporary stabilization of fractures is applied at initial debridement.

Definitive fracture fixation is envisaged at delayed primary closure.

The simplest method of bone immobilization that provides for fracture consolidation is preferred.

Physiotherapy should start immediately post-operatively.

## 22.1 Introduction

Limb injuries constitute the bulk of surgical work during armed conflict and fractures are present in a large number of them. It is thus essential that the general surgeon have a good knowledge of basic fracture management.

A fracture is often best described as a soft-tissue injury complicated by a break in a bone.

22

## 22.2 Wound ballistics

The basics of wound ballistics with respect to bone are dealt with in Section 3.4.5. Bone tissue is significantly denser and harder than soft tissue and less elastic; it does not simply deform, it breaks. Within the shooting channel, the exact point where the missile hits the bone is of overriding importance. During the narrow, phase 1 channel, an FMJ bullet simply punches a hole in the bone. During temporary cavitation, severe comminution results.

“The surgeon is confronted with the wound and a knowledge of ballistics is useful but very limited in the practical management of an individual case. A knowledge of ballistics gives an understanding of possibilities [of management]; nothing more.”

Å. Molde, R. Gray<sup>2</sup>

### 22.2.1 Kinetic energy

The key element determining the amount of tissue damage is the *effective transfer* of kinetic energy, which depends on several factors: the total energy available; the composition of the bone; and the duration of contact between projectile and bone, which is inversely proportional to the projectile's velocity. Thus a slow travelling FMJ bullet in stable flight may cause more damage than one with a much greater velocity because its contact with the bone lasts longer allowing it to transfer a greater amount of energy. The interaction between bone and bullet may cause the bullet to tumble, deform or even fragment.

The point in the wounding channel where the bullet comes into contact with bone is crucial, as demonstrated in the clinical cases depicted in Section 3.4.5. This explains the existence of small or large exit wounds.

Furthermore, and of great clinical importance, low-energy transfer wounds present little soft-tissue injury and relatively little contamination with bacteria and foreign

<sup>2</sup> Molde Å, Gray R. Letter to the Editor. *Injury* 1995; **26**: 131.

matter. High-energy transfer wounds are characterized by the vacuum created by cavitation with severe bacterial contamination, and present massive soft-tissue injury. As is often the case the very worst are the wounds caused by anti-personnel mines where the energy of the local blast effect is added to the penetration of fragments and foreign debris.

### 22.2.2 Bone-projectile interface

Projectiles must reach a threshold velocity that leads to sufficient energy density in order to penetrate tissue; otherwise, they simply bounce off the body. For bone, this is approximately 40 – 60 m/s. The penetration depth of a projectile in bone and the effective transfer of kinetic energy depend on the degree of projectile retardation by the tissues: the “push” of the bullet versus the resistance of the bone. The main factors influencing the resistance are the ratio of hard cortical versus soft cancellous bone and the state of bone mineralization. Thus, soft osteoporotic bone is more easily penetrated than healthy bone, but, owing to its lower resistance, less energy is transferred by the projectile.

#### Long bones

Long bones of the limbs are heterogeneous. The diaphysis has a relatively thick wall that is dense and brittle and may be compared to a fluid-filled rigid-walled tube: bone marrow surrounded by cortical bone. Therefore, the boundary effect comes into play if the diaphysis is affected by the temporary cavity (see Section 3.4.3). Cavitation generates an increase of the hydraulic pressure in the marrow that spreads in all directions and fractures the bone, thus propelling bone fragments in the direction of the travelling projectile *and* in the opposite direction.

The bone fragments are propelled to the edge of the temporary cavity. Then, when the cavity collapses, soft-tissue elasticity causes the bone fragments that retain their soft-tissue attachment to regroup around the fracture site. Other fragments become enclosed in pockets of damaged soft tissues and appear to lie some distance from the permanent wound channel, as though at the end of their own wound channel. However, the amount of kinetic energy transferred to each bone fragment is insufficient for them to create their own independent track outside the temporary cavity. *Bone fragments do not act as secondary projectiles* and remain within the confines of the temporary cavity. This has been confirmed by high-speed photography. Nevertheless, even though they do not become secondary missiles, bone fragments can injure a nearby neurovascular bundle included within the range of the cavity.

Fracture of the diaphysis at the site of temporary cavitation is accompanied by comminution; periosteal stripping is highly localized and confined to about 5 cm from the fracture ends. The major fracture ends undergo devascularization of the Haversian system and are often dirtied and black in colour. Numerous haemorrhages occur in the bone marrow.

Within two weeks, osteoneogenesis begins from the periosteum with a proliferation of osteoblasts and is significant in attached bone fragments. Unattached fragments, however, undergo avascular necrosis and are later absorbed by osteoclastic activity. These fragments are a prime source of infection.

Another result of cavitation seen in long bones is fracture “at a distance”, without a missile actually striking the bone. A large temporary cavity can accelerate a large mass of muscle; the compression wave at the edge of the cavity can bend and snap a diaphysis, usually resulting in a simple transverse or spiral fracture.

Fractures of the cortex may be minor: drill-hole or divot fractures, seen especially if the bone is hit during the phase 1 narrow channel. Often, longitudinal spiral fractures extend proximally and distally from the main fracture and are a function of the load on the bone: whether the person is standing on both feet or with one foot on the ground as when running, or carrying a heavy weight such as a backpack with ammunition.

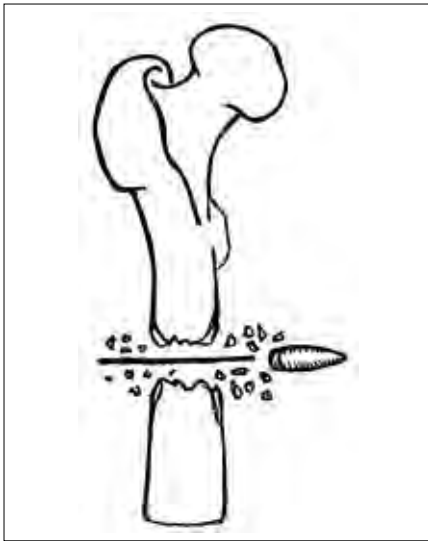


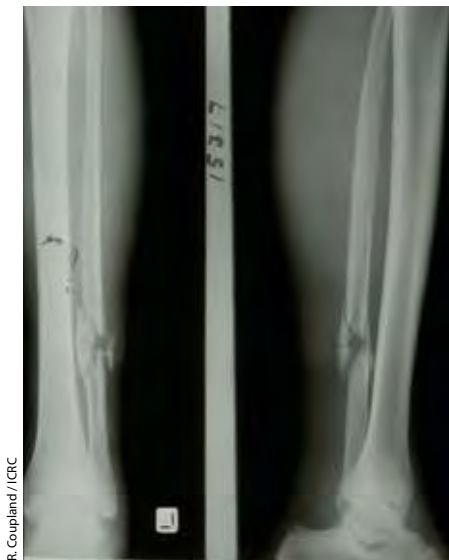
Figure 22.1

The effect of increased hydraulic pressure in the bone marrow of a long bone: bone fragments are dispersed in all directions.

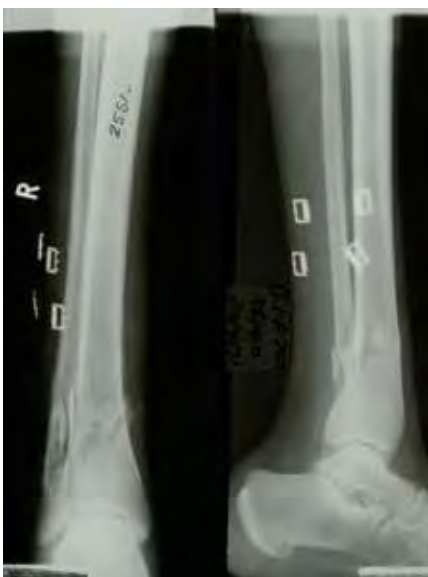

Figure 22.2

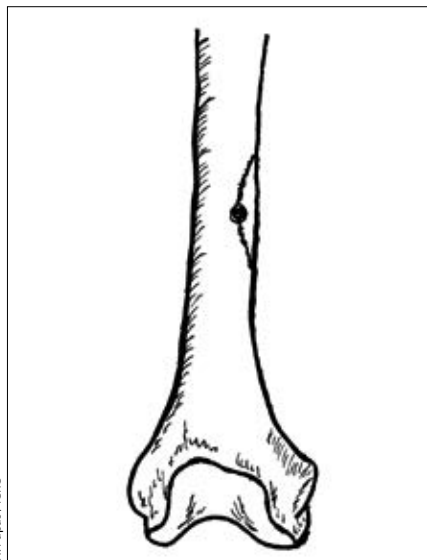
Drill-hole fracture in the cortical bone of the lower tibia and fibula.



R. Coupland / ICRC

**Figure 22.3.1**

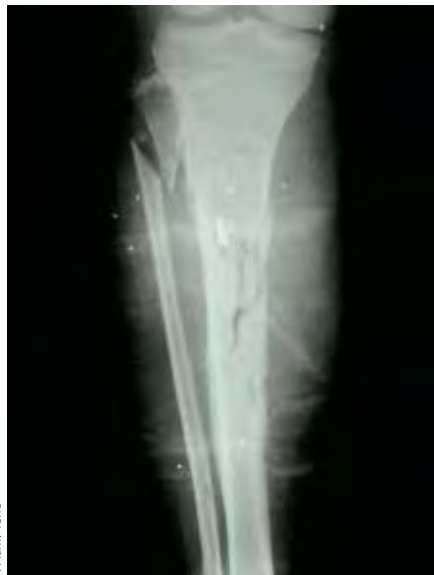Radiograph showing divot fracture of the fibula.



N. Papas / ICRC

**Figure 22.3.2**

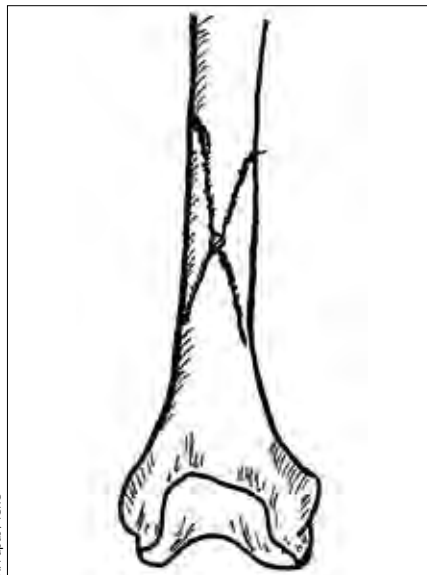
Divot fracture: the entire thickness of only one cortex is fractured. A small piece of bone is broken off from the main shaft, occasionally accompanied by a non-displaced fracture extending from the divot.



F. Plant / ICRC

**Figure 22.4.1**

Butterfly fracture of the tibia.



N. Papas / ICRC

**Figure 22.4.2**

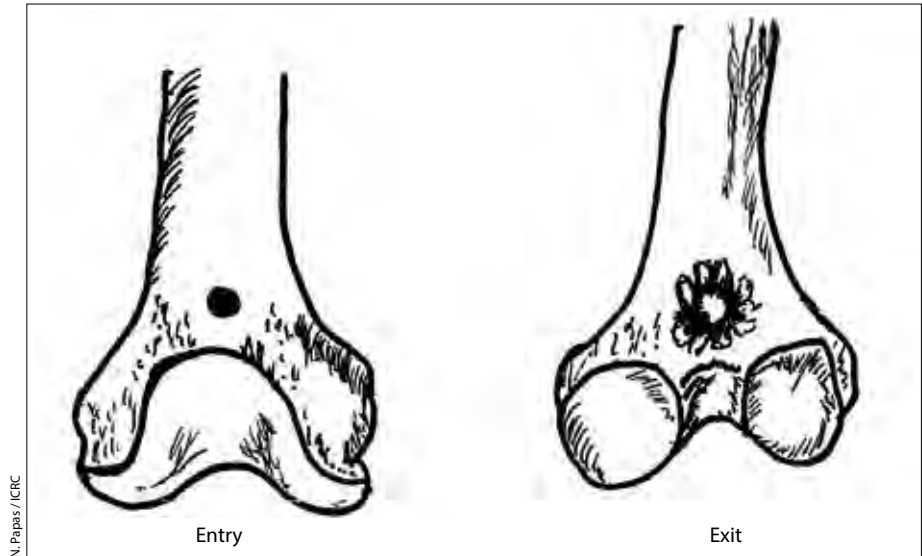
Double butterfly fracture.

Spongy and porous metaphyseal bone reacts differently; it more readily absorbs energy and accommodates cavitation better. In a low-energy transfer wound, the projectile simply crushes the bone in front of it forming a “drill-hole fracture” or, occasionally, a large-fragment fracture. High-energy transfer wounds on the other hand develop three distinct zones.<sup>3</sup> The first is composed of the defect of the wound track where the bone has been crushed. The second extends for about 3 cm and consists of multiple cancellous fragments that have retained their soft-tissue attachment. Finally, and reaching up to 9 cm from the track, there is a zone of fracture lines with minimal displacement. These drill-hole or localized comminuted fractures withstand a physiological load without further fracturing better than similar fractures in the diaphysis.

<sup>3</sup> Robens W, Küsswetter W. Fracture typing to human bone by assault missile trauma. *Acta Chir Scand* 1982; **508 (Suppl.)**: S223 – S227.

**Figure 22.5**

Drill-hole fracture through metaphyseal bone hit during the narrow phase 1 channel. The entry is usually the same size or slightly less than the diameter of the bullet and the edges of the exit are funnelled outwards. The diaphysis of a long bone reacts in the same way (see Figure 22.2).



**Flat bones**

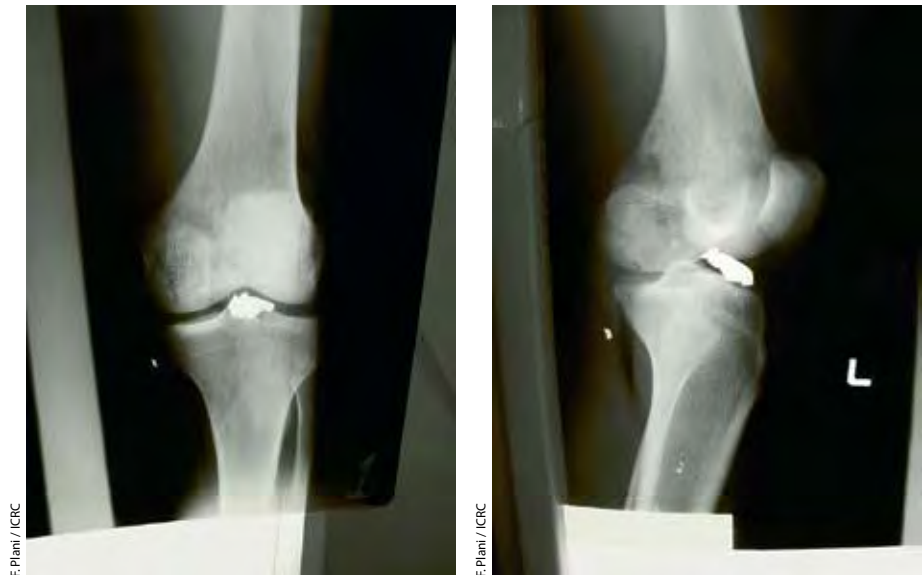Flat bones include the scapulae, sternum, iliac fossae and the skull. They are mostly diploe cancellous bone with an absence of marrow and therefore suffer no hydraulic pressure effect; a bullet creates a hole with a little fissuration fracture. Injury is due only to direct crush by the projectile. A bullet entry wound is more or less circular, depending on the angle of impact. Its exit is usually a funnel-shaped defect.

**22.2.3 Joints**

A projectile passing into a joint can damage bone, cartilage, ligaments and menisci, largely through direct crush or laceration. Infection can easily cause chondrolysis and destruction of the joint.

Lead fragments in soft tissue are rapidly isolated by avascular scar tissue. In synovial fluid, lead dissolves and can cause plumbism: generalized lead poisoning (see Section 14.3). Lead is also well known for causing a strong chemical arthritis.

**Figures 22.6.1 and 22.6.2**  
Intra-articular metallic fragment.



Furthermore, any metallic fragment inside a joint causes serious direct physical trauma to the articular cartilage because of its shape and volume. This can lead to degenerative arthritis.



## 22.3 Epidemiology

### 22.3.1 Anatomic distribution

Although much has been written about the anatomic distribution of war wounds, there have been only a few studies on the distribution of fractures among the different bones in the limbs. Fractures occur in one-quarter to one-third of all limb wounds and the lower limb is injured about twice as often as the upper. However, the *incidence* of fractures in the upper and lower limbs is relatively equal. This is probably due to the smaller volume and more exposed position of the skeleton of the upper limb.

Fracture	USA: World War II		USA: Afghanistan and Iraq	
	Number	Percentage of total	Number	Percentage of total
Shoulder: clavicle, scapula	–	–	35	5 %
Humerus	545	23 %	106	14 %
Forearm	428	18 %	107	14 %
Hand	–	–	144	19 %
Total upper limb	973	40 %	392	52 %
Femur	668	28 %	107	14 %
Lower leg	775	32 %	173	23 %
Foot	–	–	86	11 %
Total lower limb	1,443	60 %	366	48 %
Total	2,416	100 %	758	100 %

Table 22.1 Comparison of the distribution of open fractures among US forces during World War II and in Afghanistan and Iraq.<sup>4</sup>

### 22.3.2 Type of fracture

The great majority of fractures are open, as is to be expected. Closed fractures in combat are usually due to tertiary blast effect and anti-tank landmines. Vehicle collisions and other accidents are also common non-combat causes.

Fracture	Closed	Open	Total	Percentage open fractures
Clavicle	6	7	13	53 %
Scapula	4	28	32	87 %
Humerus	16	106	122	86 %
Forearm	23	107	130	82 %
Hand	20	144	164	87 %
Total upper limb	69	392	461	85 %
Femur	16	107	123	86 %
Lower leg	45	173	218	79 %
Foot	27	86	113	76 %
Total lower limb	88	366	454	80 %
Total	157	758	915	82 %

Table 22.2 Distribution of open and closed fractures among US troops in Iraq and Afghanistan (Joint Theater Trauma Registry October 2001 – January 2005).<sup>4</sup>

It should be noted that the tibia is the most commonly fractured bone in combat and often the most difficult to treat and the most prone to complications.

<sup>4</sup> Adapted from Owens BD, Kragh JF Jr, Macaitis J, Svoboda SJ, Wenke JC. Characterization of extremity wounds in Operation Iraqi Freedom and Operation Enduring Freedom. *J Orthop Trauma* 2007; **21**: 254 – 257.

### 22.3.3 Joints

Even fewer reports deal specifically with injuries to the major joints. One such study, from the war in the former Yugoslavia, gives an incidence of 18.2% joint injuries (339 patients) out of a total of 1,860 casualties with limb wounds treated in a large military hospital. The knee and elbow were the most common joints injured and also the most common sites of associated neurovascular injury.

Joint injured	Percentage distribution of total joint injuries
Knee	46.6%
Elbow	20.1%
Hip	10.4%
Shoulder	9.8%
Ankle	8.9%
Wrist	4.2%

Table 22.3 Incidence of major joint injury in 339 patients, in the former Yugoslavia.<sup>5</sup>

### 22.3.4 Red Cross Wound Score

The Red Cross Wound Score takes into account the soft-tissue injury as well as the fracture. The degree of bone damage in the version described in Chapter 4 makes a distinction between a simple fracture, hole, or clinically insignificant comminution (F = 1) and severe, clinically significant comminution (F = 2). Basically, these scores correspond to either two bone fragments or more as seen at wound debridement. However, the F parameter does not apply to the bone defect left after wound excision. A refinement of the RCWS serves as a guide to assessing the defect.

#### Defect A : small and circumferentially incomplete bone defects

These drill-hole type, divot or chip-fracture defects heal well after correct debridement. If the soft-tissue injury is minimal, a conservative non-operative approach may be considered.

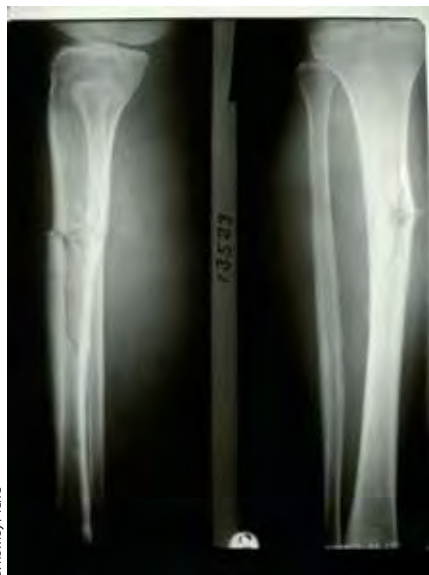

Figure 22.7.1

An F1 Type A fracture of the tibia without bone defect. Once the soft-tissue wound around the fracture has been excised, healing usually progresses smoothly.

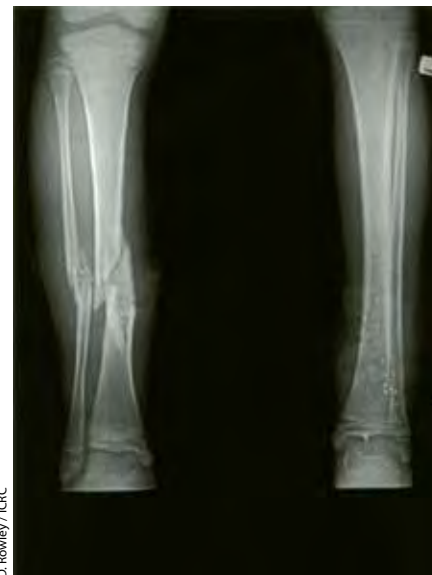

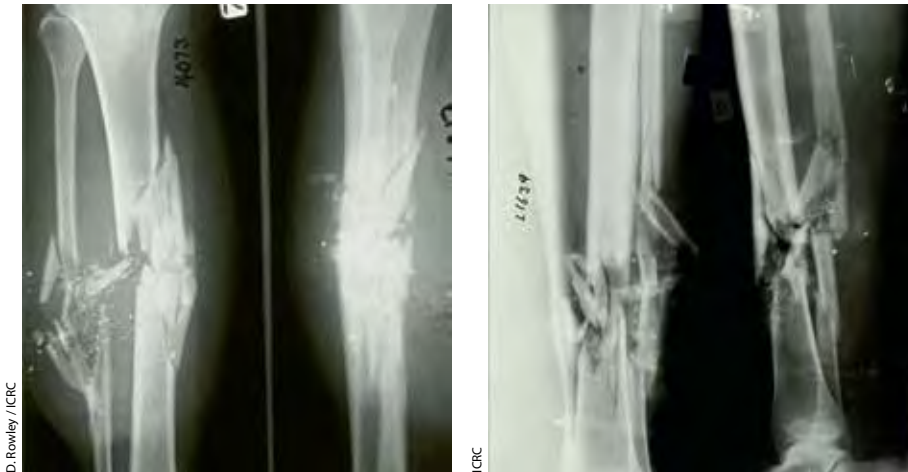Figure 22.7.2

An F1 fracture in a child's tibia with Type A defect. There is overall continuity of the bone despite the defect.

5 Nikolić D, Jovanović Z, Popović Z, Vulović R, Mladenović M. Primary surgical treatment of war injuries of major joints of the limbs. *Injury* 1999; **30**: 129 – 134.

**Defect B: small and circumferentially complete bone defect (<3 cm)**

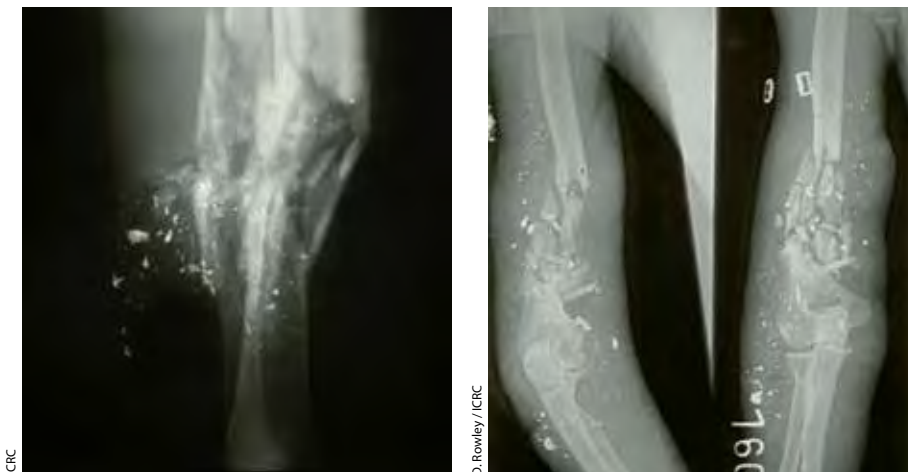
In these cases, the defect may be retained as it is, or the limb permitted to shorten; the patient usually adapts to slight shortening. The extent of soft-tissue injury usually requires debridement.

**Figures 22.8.1 and 22.8.2**

A bullet has produced circumferential bone loss (F2), but the defect is small: Type B. All the periosteum is usually present in such wounds and must be retained during surgery.

**Defect C: large and circumferentially complete bone defect (>3 cm)**

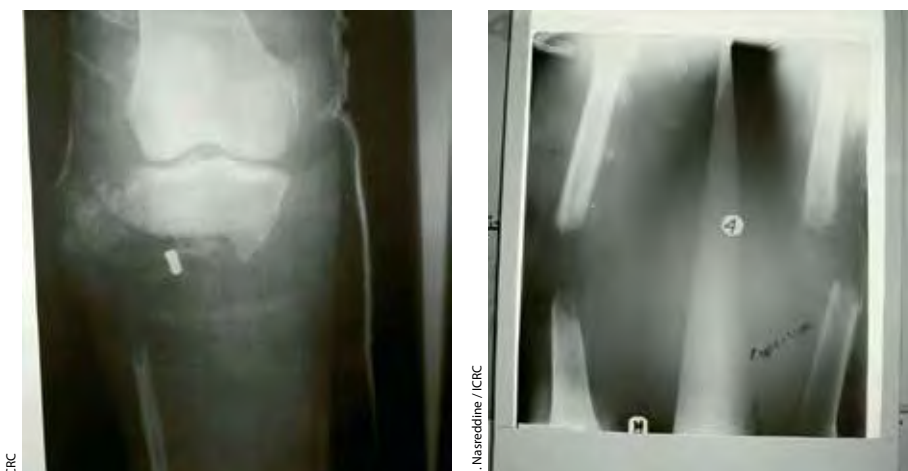Remaining periosteum may ensure some callus formation. If progress is slow as revealed by serial X-rays, a bone graft may be considered later. The associated soft-tissue damage is significant, and wound debridement will clearly have been required.

**Figures 22.9.1 and 22.9.2**

There is gross comminution and bone loss that will lead to a Type C defect. Many of the fragments will be found to be loose, but some will still have good periosteal attachment and should be retained.

**Defect D: large defect associated with circumferential loss of bone and periosteum**

The capacity for bone regeneration in such fractures is limited. Even after a bone graft, healing may take months or years. Management options depend on which bone is injured – and the ultimate compromise of function – as much as on the actual bone defect. A severely mangled extremity calls for a choice between attempted limb salvage or amputation (see Section B.5.1).

**Figures 22.10.1 and 22.10.2**

Two examples of a Type D defect: in this case, the soft-tissue loss is considerable and the extent of bony tissue loss such that the osteogenic potential is very small, even with bone grafting.

## 22.4 Management of war wounds with fractures

The image of the fracture as seen on an X-ray is only one aspect of the wound complex. "Treat the wound, not the weapon" is a well-known aphorism in war surgery (see Section 3.2.1). One may well add: "treat the wound, not the X-ray". The first and essential step to bone healing and the recovery of function is correct treatment of the soft-tissue wound. Furthermore, "cure" is not dependent on the radiological appearance of consolidating bone. The patient is not "cured" until some degree of function compatible with the extent of the wound is restored.

### Old lesson for new surgeons

Treat the wound, treat the wound, treat the wound  
... *then* treat the bone.

The management of war wounds with fractures includes a number of standard steps.

1. Transformation of a contaminated war wound into a clean one by meticulous debridement.
2. Reduction and immobilization of the fracture at the initial wound debridement by the simplest and least invasive method possible.
3. Transformation of a clean wound with an open fracture into a closed one by DPC.
4. Definitive method of fracture immobilization decided at DPC and dependent on many factors, including the specific bone injured and the extent of the soft-tissue wound – and the skill and expertise of the surgeon.
5. Restoration of optimal physiological function possible through physiotherapy and physical rehabilitation.

Initial temporary bone immobilization at primary debridement; definitive bone immobilization at delayed primary closure.

### 22.4.1 Primary wound debridement

The surgeon's essential concern should focus on wound excision, not on the method of fracture immobilization. The extent of soft-tissue excision should not be influenced by the risk of exposing bone; dead muscle and fat do not protect underlying bone and do not preserve function.

As mentioned repeatedly in this manual, all unattached cortical bone fragments should be removed no matter how large. These are all avascular and retaining them in the wound will only result in infection that destroys even more bone. Any fragments still attached to soft tissue should be preserved.

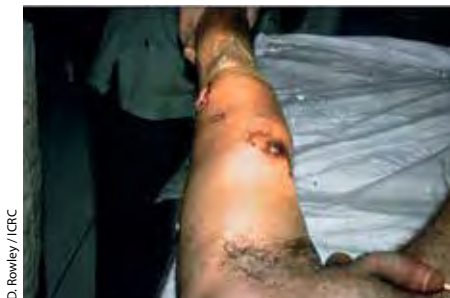### Old lesson for new surgeons

Be radical with bone.  
Be conservative with periosteum.

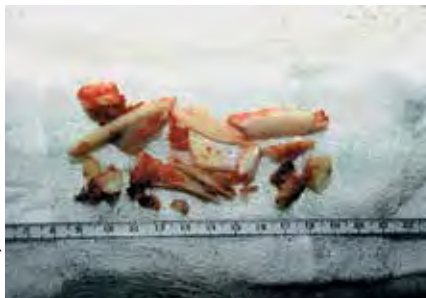The surgeon should inspect the ends of major fragments of cortical bone, while avoiding further stripping and soft-tissue damage as much as possible.

- If *clean and stripped bare*, the bone ends should not be cut back but laid down in the periosteal and muscle bed.

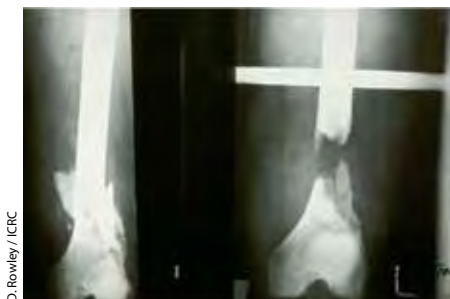- If *dirty and not stripped* of soft tissue, the contaminated bone ends should be scraped and curetted clean.
- If *dirty and stripped*, the dirty cortex is removed with bone nibblers (rongeur) and the medullary cavity gently curetted until fresh bleeding bone and firm marrow appear.



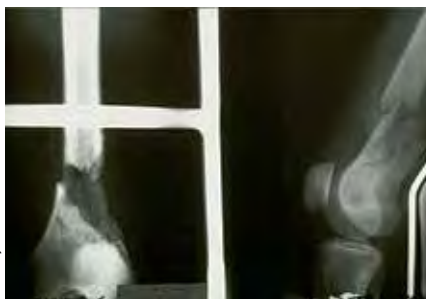**Figure 22.11.1**  
Left thigh with entry and exit wounds.



**Figure 22.11.2**  
Cortical bone fragments without periosteal attachment removed at wound debridement.

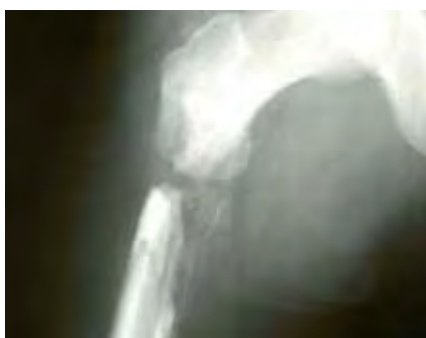
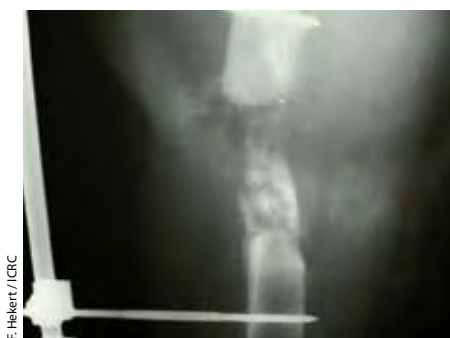
**Figure 22.11.3**  
After wound excision, the skeletal traction over-distracted the bone ends. This was corrected by adjusting the weight.



**Figure 22.11.4**  
Five weeks after wound excision, bone healing has occurred from the intact periosteum and callus is visible.

As much periosteum as possible should be retained, since it is the periosteum that generates new bone. Because projectile trauma to the periosteum is usually very localized, most of the periosteal sleeve can be salvaged in the great majority of patients.



**Figures 22.12.1 and 22.12.2**  
Osteoneogenesis proceeding from the sleeve of periosteum remaining after wound excision.

A case can be made for retaining loose pieces of intra-articular cancellous bone in a low-energy and relatively non-contaminated metaphyseal fracture after curettage of the contaminants. Multiple fragments of the extra-articular metaphyseal bone should be curetted back until firm marrow is reached. These metaphyseal fragments closely resemble a bone graft.

Avoid creating unnecessary bone gaps.

Correct bone excision is difficult: excising too much is as great a risk as too little. In inexperienced hands, the quest for a clean wound may result in an unnecessary bone defect and, consequently, to a lasting loss of function.

Except in wounds presenting very extensive destruction, it is usually possible to reduce the fracture and align approximately the major bone fragments, thus maintaining a semblance of the bony architecture. The first debridement is the optimal occasion to achieve alignment. It becomes more difficult with time because soft tissues adhere to the bone ends as part of the healing process, no matter how the fracture is immobilized.

There is no need to mobilize muscles to cover exposed bone at primary wound excision as it only increases soft-tissue damage and can compromise drainage.

A first temporary method of fracture immobilization is chosen. After initial wound debridement and before attempting DPC, most fractures can safely be immobilized with a plaster-of-Paris posterior slab or by skeletal traction.

A decision about the method of definitive bone immobilization can wait until attempted DPC.

#### 22.4.2 Delayed primary closure

A clean wound is closed by direct suture or skin grafting. Small wounds with a deep cavity, in which direct suture would create tension, may be left to heal by granulation and secondary intention. In some cases, a rotation flap or another reconstructive procedure may be necessary (see Section B.11). If skin closure proves impossible, the fracture may still be covered by nearby muscle at the second operation. This applies particularly to the tibia.

At second operation: close a *clean* wound.

If in any doubt: debride again and leave it open.

An infected wound or one containing obvious necrotic tissue should be redebrided and left open for another five days: primary debridement was clearly insufficient.

In either case – successful DPC or redebridement – the bone and periosteal defect are re-assessed. The sleeve of periosteum is palpated and observed: some continuity should remain except in very extensive injuries. The bone defect is categorized according to the parameters described in Section 22.3.4 and a method of definitive bone immobilization chosen.

### 22.5 Methods of bone immobilization: surgical decision-making

#### Factors to consider for good bone immobilization:

- functional result, not X-ray result;
- choice of method with lowest risk of complications;
- simplicity of technique, taking into account surgical skill and experience;
- simplicity of nursing care;
- reduction of hospitalization time, i.e. early discharge;
- expense.

There is no single and ideal method of fracture immobilization that fits all situations and all patients. The principal methods are plaster-of-Paris, skeletal traction and external fixation; each one has its advantages and disadvantages (Tables 22.4; 22.5 and 22.6). Internal fixation – osteosynthesis – should not be used in the primary treatment of war wounds with fractures. The surgeon must determine the most appropriate method by taking into account several factors:

- the specific bone injured and any possible compromise of function;
- the nature of the fracture and resultant bone defect;
- the extent and nature of the soft-tissue wound;
- the quality of post-operative nursing care and physiotherapy available.

Perhaps the most important factor is the *experience and expertise of the surgeon*.

Advantages	Disadvantages
Inexpensive	Fresh supply necessary
Easy to apply Little or no special equipment necessary	Bulky
Least invasive method Allows for other surgical options	Joints immobilized
Flexible Good temporary measure and definitive treatment	Poor access to wounds Not satisfactory for large wounds or burns
Rapid bone healing	Too tight = tourniquet
Early mobilization of patient on crutches	Too loose = non-union
Early discharge from hospital	Shortening and malunion common with comminuted fractures
	Poor patient hygiene and comfort (particularly in hot and humid climates)

Table 22.4 Advantages and disadvantages of plaster-of-Paris.

Advantages	Disadvantages
Good temporary measure	Not appropriate in absence of good nursing care and physiotherapy Constant monitoring of weights and axis of traction
Possibility to revert to other techniques	Requires special frame
Rapid bone healing	Difficult bone alignment, but more common after closed fractures
Good access to wounds of anterior aspect of thigh	Poor access to wounds of posterior aspect of thigh
Allows for mobilization of joints	Patient immobilized in bed
	Not appropriate in case of military necessity of evacuation (use Thomas splint, POP slab or external fixation instead)

Table 22.5 Advantages and disadvantages of skeletal traction.

Advantages	Disadvantages
Good access to wounds	Invasive technique Risk of injury to neurovascular bundle and tendons Risk of oedema
Secure immobilization for maintaining limb length and for bridging disorganized joint	Requires well-trained staff
Can reduce bone gap if limb shortening acceptable	Time required for application
Early joint movement	Delayed-union and non-union
Early mobilization of patient	Infection of pin sites
Early discharge	Mechanical difficulties with equipment
Possibility of bone grafting after soft-tissue healing	Expensive
Facility of military evacuation	In a civilian context material may be lost if patients are discharged while still fitted with external fixation

Table 22.6 Advantages and disadvantages of external fixation.

The specific bone injured has a particular clinical significance as regards functional outcome when considering fracture reduction and immobilization. The lower limbs require stability and equality of length for proper weight bearing (a small amount of shortening in the injured limb is acceptable). In the upper limb, some shortening, rotation and angulation are acceptable.

*Avoiding complications has higher priority than rapid patient mobilization, especially when severe war wounds are treated by a non-specialized surgeon. Simple methods of treatment are best.*

Whatever the method of bone immobilization chosen, good physiotherapy will give the best results. Mobilization of the patient and the injured limb must be encouraged.

### 22.5.1 Plaster-of-Paris

The use of plaster-of-Paris is a simple non-invasive technique for constructing a moulded support for a limb. The effective use of POP, in whatever form, is a manual skill that must be learnt and practised. A previous generation of general and orthopaedic surgeons was well versed in its use. Today, this is often no longer the case. The basic techniques include the making of a back slab or posterior splint and a complete cylindrical cast and its variations.

The indications for plaster-of-Paris treatment include:

- initial temporary bone immobilization for most patients;
- definitive immobilization after soft-tissue healing for certain bones;
- management of nerve palsies (see Section 25.8.1);
- primary treatment of closed fractures.

In the great majority of cases after the initial wound excision, a POP splint is the most suitable choice for temporary bone immobilization. The exceptions are the femur and most fractures of the humerus.

Once the open fracture has been converted into a closed one, a POP cast best permits controlled weight-bearing for the tibia, and gives good support to the bones of the forearm. The major disadvantage is the immobilization of the nearby joints and the main advantage the rapidity of fracture consolidation.

A POP splint is an excellent method for initial bone immobilization.  
 Exceptions: the femur and most fractures of the humerus.

Details on the use of POP are to be found in Annex 22.A. Different techniques are described in the *Plaster of Paris and Limb tractions – ICRC physiotherapy reference manual* included in the DVD attached to Volume 2 of this manual.

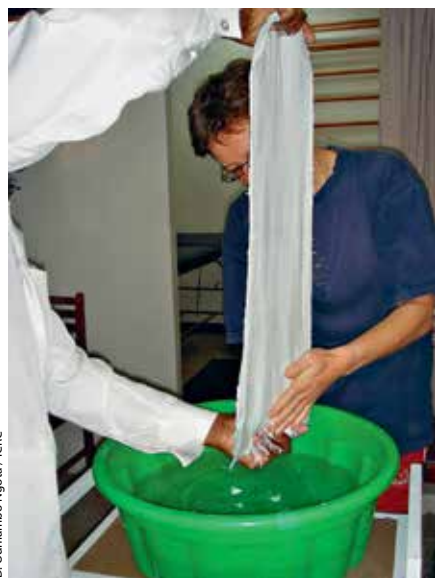### 22.5.2 Traction

Traction can be applied to a limb by various means:

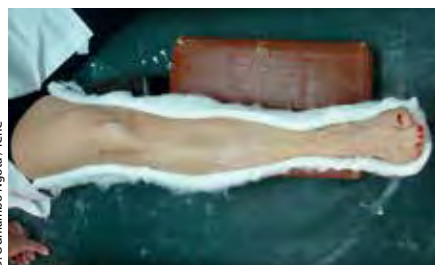- the weight of the body part itself;
- adhesive taping applied to the skin; or
- a pin through a bone.

It is the optimal method for managing most femoral and humeral fractures, especially in the hands of the non-specialized surgeon. The technique is simple and safe with few complications, provided it is carefully supervised by the surgeon or a well-trained physiotherapist. The minimal invasiveness of traction permits resorting to other techniques in the event of complications or difficulty.

Physiological or functional traction is employed for fractures of the clavicle by means of a triangular or figure-of-eight bandage and for the humerus by a cuff-and-collar sling.



D. Odhiambo Ngota / ICRC



D. Odhiambo Ngota / ICRC

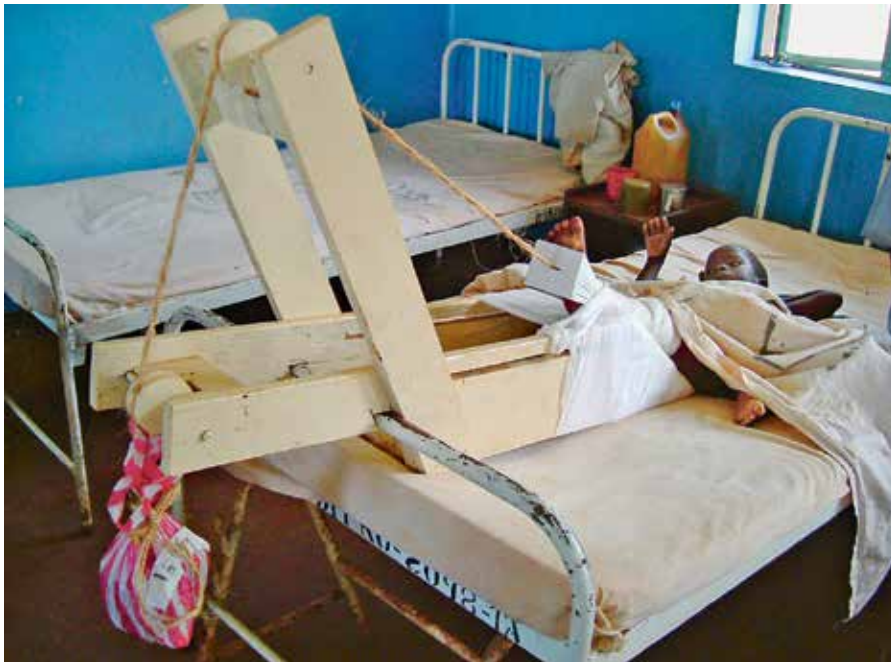

D. Odhiambo Ngota / ICRC

**Figures 22.13.1 – 22.13.3**  
 Fashioning of a POP long leg back slab.

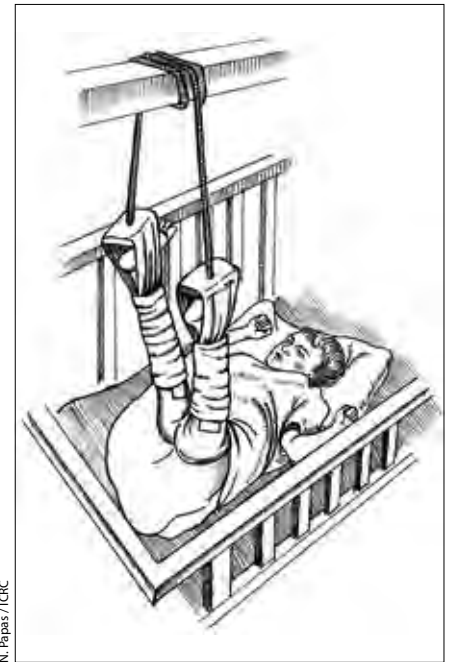

Skin traction is the preferred method of treatment for a fracture of the femur in children and the elderly. When used for femur fractures in adults it is applied in-line and usually supported by some form of splint (e.g. Thomas splint, see Figure 22.B.9).



M. Balkdam / ICRC

**Figure 22.14.1**  
Frame for unilateral skin traction of the femur made out of locally-available materials.



N. Pappas / ICRC

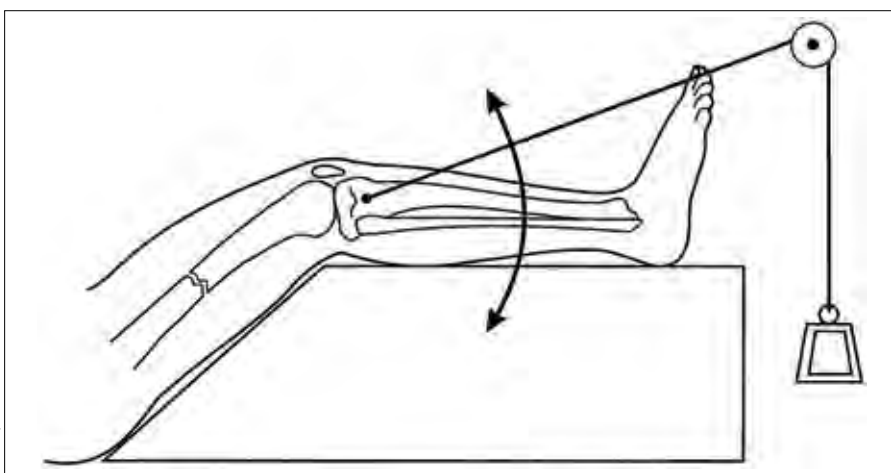
**Figure 22.14.2**  
Gallows traction from a beam.

Skeletal traction is the best choice for:

- initial immobilization of most femoral and some tibial and humeral fractures;
- definitive immobilization of fractures of the femur;
- definitive immobilization of particularly difficult fractures of the tibia near the knee and of the humerus near the elbow.

Skeletal traction is the most suitable method of immobilization for femoral fractures.

The larger force applied in skeletal traction is transmitted along the axis of the limb via a pin, pulley and a weight. The direction of the pull is altered by adjusting the position of the pulley.




D. Rowley / ICRC

**Figure 22.15**

Traction for a femur fracture is applied through a tibial pin with the knee in almost full extension, which acts as a focus for the force applied by a weight. The position of the pin is such that the force is applied in a uniform direction along the axis of the limb irrespective of the position of the leg and is not affected by the position of the knee. The knee can therefore be flexed through 90° by removing the horizontal support under the leg while still in traction (see Figure 22.B.24).

**Figures 22.16.1 and 22.16.2**

Two patients undergoing treatment by skeletal traction with manufactured and improvised frames.



The principal disadvantage of skeletal traction is prolonged confinement of the patient in bed, and the demands put on nursing care and physiotherapy. The main advantage is the rapidity of fracture consolidation.

Application of the different traction techniques is described in Annex 22.B and in the *Plaster of Paris and Limb Traction – ICRC physiotherapy reference manual* included in the DVD attached to Volume 2 of this manual.

### 22.5.3 External fixation

The concept of external fixation is deceptively simple: a rigid frame mounted across the fracture site and attached to the bone with pins. However, it is a specialist technique and presents a number of practical difficulties. Many surgeons have improvised external fixators by using transfixion Steinmann pins embedded in a POP cast or bamboo external bars.

In a resource-poor context, the role of external fixation is limited. Indications for its use do exist, however, and ICRC surgeons have defined them according to the phase of treatment, nature of the injured tissues, and general patient management.

#### At initial wound debridement

In ICRC practice, the indications for application of an external fixator at initial wound debridement are restrictive and fall into several categories.

1. Fixation due to significant soft-tissue injury.
  - Protection of an arterial anastomosis (e.g. fractured femur with concomitant injury of the femoral artery).
  - Fractures with extensive burns.
2. Fixation due to the bony injury.
  - Extensive and unstable bone comminution, usually resulting in a large bone defect (some Type C and most Type D bone defects) where it would be difficult to hold the fracture by any other means. This is especially the case in the absence of a soft-tissue scaffold: the most common occurrence being in the distal third of the tibia. Another example is a humeral fracture with extensive soft-tissue and bone loss where external fixation can be used to shorten the bone since restoration of humeral length is not essential to salvage useful arm function.
  - Severely disorganized joint.
  - Pelvic disruption, if binding with a bedsheet proves unsatisfactory.
3. Fixation for patient care.
  - Patient who has already lost one leg, as part of limb salvage for the severely injured remaining limb.
  - Polytrauma or unconscious patient, to ease nursing care and assist in patient mobilization or movement.

In a non-ICRC context, one can add the military necessity to evacuate the wounded, although the time-tried method of the Thomas splint or simple plaster cast is always an alternative possibility.

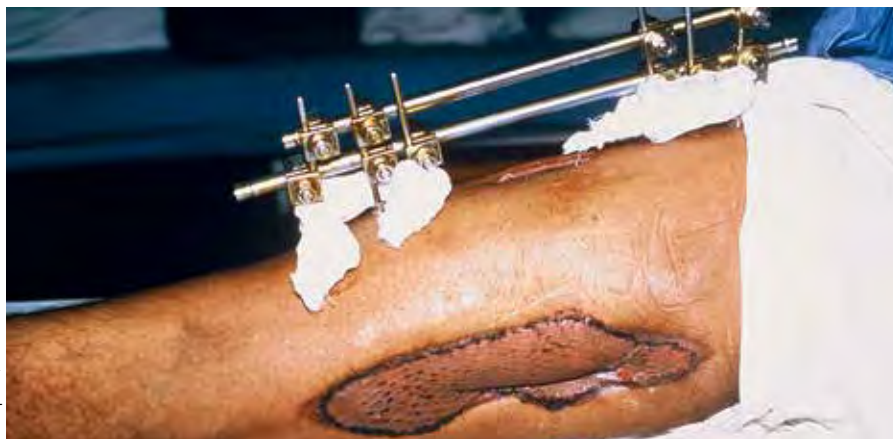**At attempted DPC**

If wound closure by suture cannot be performed owing to an extensive injury that necessitates *further surgical care*, a posterior POP-slab or skeletal traction can be usefully replaced by an external fixator. Important examples are wounds that require:

- skin grafting or a reconstructive flap for closure;
- serial debridements in an effort to save the limb (see Section 10.8.2);
- repeated debridements and sequestrectomies for an infected and unstable fracture, usually the case with neglected wounds presenting late.

External fixation is rarely necessary at initial wound debridement. Further surgical care is by far the most common indication for external fixation in the practice of ICRC surgeons.

Once wound closure has been accomplished and there is no further need to access the wound, the fixator can often be removed and replaced by a POP cast or by traction. This should be done as soon as soft-tissue healing permits, in order to promote fracture consolidation.



**Figure 22.17**

Patient with external fixation to allow for skin grafting of the wound.

22

Remove the external fixator as soon as access to the soft tissue wound is no longer necessary.

**Late indications**

Late indications for the application of external fixation are mostly limited to factors concerning the bone:

- failure of conservative treatment (e.g. interposition of soft tissue at the fracture site of a femur in traction, a rare occurrence in ballistic wounds);
- reduction and positioning for bone grafting;
- operative arthrodesis;
- limb lengthening – a very specialized technique.

The application of an external fixator can be difficult and can lead to many complications when working in an austere environment. Many orthopaedic surgeons used to working in sterile conditions have never seen these complications. As pointed out before, there are *simpler* and *safer* methods of fracture immobilization, especially for the non-specialist surgeon. Furthermore, there is rarely a need to apply external fixation at initial wound excision where the wound has priority over the method of bone immobilization.

ICRC maxim: "The more experienced the war surgeon, the less use of external fixation."

A detailed description of external fixation is to be found in Annex 22.C.

### 22.5.4 Damage-control orthopaedics

In addition to the pathophysiological changes typically seen in the patient treated by a damage-control approach, recent laboratory studies have shown that severe soft-tissue injury initiates a deleterious systemic inflammatory response of its own. This is especially the case in the presence of blood loss, ischaemia, necrosis and/or infection, and prolonged fracture manipulation. As a consequence, the management of major fractures with extensive soft-tissue trauma has adopted a “multi-stage” approach in contemporary practice, rather than an “early total care” one where every bone is definitively fixed at the initial theatre session. Some orthopaedic surgeons have therefore described the use of external fixation as a damage-control approach as compared to internal fixation. However, in a shocked patient going into the lethal triad of hypothermia, acidosis and coagulopathy, immobilization by a POP back slab or skeletal traction takes far less time and effort than placing an external fixator.

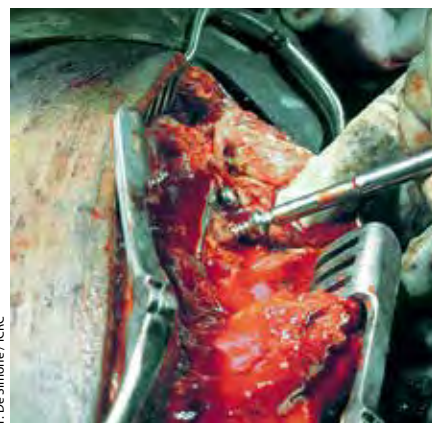Basically the principles of the staged management of injury to bone – “primary, rapid, temporary fracture stabilization ... followed by ... secondary definitive management once the acute phase of systemic recovery has passed”<sup>6</sup> – remain exactly the same as those of the time-tested classical treatment of war wounds with fractures. Indeed, staged management – debridement followed by DPC – is part-and-parcel of the treatment of all war wounds with fractures whatever their severity and whatever the physiological status of the patient.

### 22.5.5 Internal fixation: osteosynthesis

Internal fixation should never be used for initial bone immobilization in war wounds. In the context of ICRC hospitals and wherever resources are scarce and working conditions precarious it is not an option to be considered at any stage, because of the high risk of dangerous bone infection.

Several reports from the US army in Viet Nam and the Soviet army in Afghanistan demonstrated the very high infection rate (50 – 80%) when internal fixation was used as a means of primary treatment. Its use was “categorically forbidden” in one instance.<sup>7</sup>

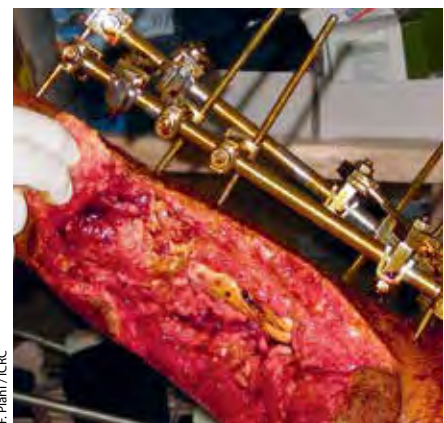Internal fixation should not be used in the primary treatment of war wounds with fractures.



F. De Simone / ICRC

**Figure 22.18.1**

Pus pours out of the wound; the plate and screws should be removed.



F. Plani / ICRC

**Figure 22.18.2**

Infected plate-and-screw fixation of a war wound replaced by external fixation during wound re-debridement.

In selected patients, whose wounds have healed fully without any occurrence of infection, who have been evacuated to a specialized centre with experienced surgeons and where the proper equipment and operative facilities and excellent

6 Hildebrand F, Giannoudis P, Krettek C, Pape H-C. Damage control: extremities. *Injury* 2004; **35**: 678 – 689.

7 Dedushkin VS, Keggi KJ. Orthopaedic aspects of the Afghan War: the Soviet experience. *Tech Orthop* 1995; **10**: 225 – 230.

nursing care are available, internal fixation for war wounds may be successfully used as a *late secondary procedure*. Clinical trials of such conversion to internal fixation of war wounds with fractures treated by splinting for 10 – 14 days are under way. If external fixation has been used, the pins are removed and a two-week “pin holiday” observed before internal fixation. Under these conditions internal fixation does not constitute primary treatment.

## 22.6 Wounds involving joints

The knee and elbow are the most frequently injured major joints, after the hands and feet. Associated injury to the neurovascular bundle is often seen in the shoulder, elbow, hip and knee.

Articular cartilage has no direct blood supply; its nutrition comes from the synovial fluid. An intact and well vascularized synovium is therefore essential for the survival of damaged cartilage.

While diagnosis of a joint injury is usually obvious with a gunshot wound, it can be difficult to establish in patients with multiple small fragment wounds. A fracture of the shaft of a long bone may also have a fracture line that runs into the nearby joint. Radiography is very useful; aspiration producing blood is pathognomonic.

### 22.6.1 Joint debridement

The same principles of bone excision apply to penetrating joint injuries, with one exception: removal of the projectile is an essential part of the debridement. Small, unattached bone and cartilage fragments should also be removed while no effort should be spared to preserve the synovium, just as important as the periosteum in the case of long bones. It is best to operate on joints using a pneumatic tourniquet and with the limb draped in a way that permits mobilization of the joint during operation to facilitate exposure.

If the entry wound is small, the joint should be opened through a separate standard arthrotomy incision. For large wounds, the joint toilet can be done through the wound itself, and extended if necessary. The entry wound should be debrided as usual and the joint washed out thoroughly with saline to remove any foreign material and debris, loose bone or cartilage fragments, and blood clots. All recesses must be carefully explored to make sure that no damaged tissue or foreign body is left behind. Debridement of the synovium itself should be very conservative.

Peri-articular fractures involving a joint surface with comminution and displaced fragments are difficult to treat, especially in war wounds for which internal fixation is contraindicated. Large osteochondral fragments should not be removed, but an attempt made to push them back into place. A “bag of bones” held together by the capsule may gain some joint congruity and useful function, even as a pseudo-arthritis, especially if early active movement is encouraged. Movement helps cartilage nutrition, and some moulding of the osteochondral fragments occurs. If no infection intervenes, the position should simply be accepted. Infection requires removal of the large fragment. Arthrodesis is an alternative for certain joints.

### 22.6.2 Wound closure

In relatively minor injuries, a small entry hole and/or incision in the synovium should be sutured with an absorbable stitch, with or without the placement of a drain, preferably of the closed suction type. If this is not available, a closed system consisting of a catheter and sterile urine bag may be used. The drain should be removed within 24 hours. The joint capsule, ligaments and skin must be left open for DPC.

If the synovium cannot be closed directly, the capsule or muscle around the wound may be mobilized to cover the defect. Again, the rest of the soft-tissue wound should be left open for DPC.

Close the synovium or cover the joint with surrounding soft tissue.

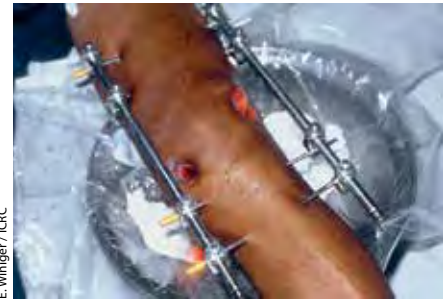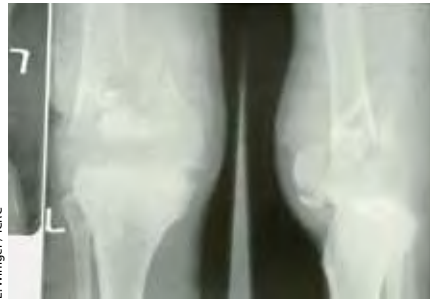
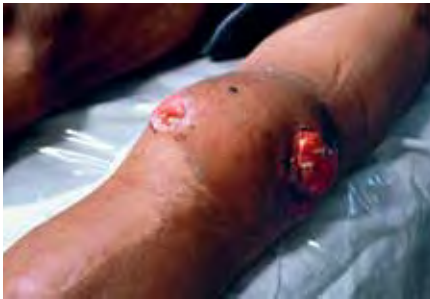In severe wounds with a large amount of contamination, the synovium must be left open and the joint covered with a single layer of moistened gauze. The dressing is completed with fluffed gauze, and an elastic bandage applied without too much tightening. DPC is then performed as usual and the soft tissues mobilized to close the synovium.

Continuous joint irrigation with antibiotics is *not* advised; it only helps to introduce infection.

### 22.6.3 Joint immobilization

After initial debridement, most joints can be immobilized in the position of function using a well-fitting posterior-slab. Some injuries in the knee and most injuries in the hip require skeletal traction.

At the second operation, if immobilization with POP is continued – whether a slab or a split cast – the joint should be mobilized cautiously, both passively and actively, after a week. Certain cases may best be treated by external fixation bridging the joint, or by a continuation of skeletal traction.



Figures 22.19.1 – 22.19.3

Gunshot wound of the knee joint treated by external fixation.

### 22.6.4 Infected joints

If infection ensues, the joint must be re-operated. Dead tissue and debris are removed and the joint copiously irrigated and left open for drainage. The antibiotic cover should be reviewed and, since cartilage imbibes the synovial fluid, the local instillation of antibiotics may prove useful, but not in the form of continuous irrigation. Old and neglected wounds of a joint with established infection should be treated in the same way. Control of infection can be difficult.

A severely infected joint may threaten the life of the patient if a large joint is involved and its removal may be the only way of achieving healing. Pseudo-arthritis arthroplasty may be performed later (see Section 22.6.7).

### 22.6.5 Pelvi-abdominal injuries and the hip joint

Injuries to the abdomen or pelvis may involve the hip joint and cause contamination with intestinal contents or urine. After laparotomy, exploration of the joint through an arthrotomy is called for. The joint is irrigated, debrided and drained, and skeletal traction applied. Attention must be paid to the vascular supply of the head of the femur.

### 22.6.6 Arthrodesis

Normal limb function might be irretrievable following a serious wound of a joint because of instability or severe pain; surgical fusion is an effective way of countering both. The decision to perform arthrodesis is made only after complete healing of the

soft tissues and consolidation of the remaining bone so that the full extent of tissue loss can be determined.

The joint must be opened and any remaining cartilage cleaved off with an osteotome so that two flat bony surfaces oppose each other in order to fuse. The joint is held in the appropriate position by means of an external fixator applied across the joint so as to press the bones together. Compression arthrodesis takes about eight weeks for consolidation. A simpler but less controllable alternative is to encase the joint in a cylindrical cast.

Operative arthrodesis is quite suitable for the ankle or knee where stability is of paramount importance, and for the wrist and joints of the fingers, but technically very difficult at the shoulder, elbow and hip, where it should be avoided if at all possible.

### 22.6.7 Pseudo-arthrosis arthroplasty

In industrialized countries with the necessary facilities, a difficult wound causing disorganization of a joint can be dealt with by replacement with an artificial one. Where such resources are unavailable, the best that can be hoped for is a pseudo-arthrosis arthroplasty: a false joint that affords some movement. The entire joint is excised and raw bone ends opposed; mobilization is started early so that a false joint results and not an arthrodesis.

Creation of a pseudo-arthrosis is a valuable last resort for difficult wounds of the hip, shoulder and elbow and surprisingly good function can be obtained. It is not appropriate for the knee or ankle, where arthrodesis is to be preferred.

## 22.7 Hand and foot injuries

Hand and foot surgery is a subspecialty of orthopaedic surgery and many of the usual techniques are not relevant to war injuries treated by a general surgeon. Nonetheless, patience and time taken for meticulous debridement frequently give good functional results, better than is often expected. Wounds of the feet caused by anti-personnel mines in particular can be very difficult to manage; amputation must often be resorted to.

### 22.7.1 Examination

Injuries to the hands and feet are common in cases of multiple wounds but are often the last to receive attention; other conditions threatening the life of the patient or major fractures take precedence.

When the time comes for dealing with the hand or foot, examination should not be hurried. Proper assessment of the many complex structures demands patience. Thorough examination should be performed for finger or toe movement and sensation. The presence of soft-tissue damage, including tendons, neurological defects and vascular injury must be clearly recorded to allow correct exploration.

### 22.7.2 Surgical exploration and debridement

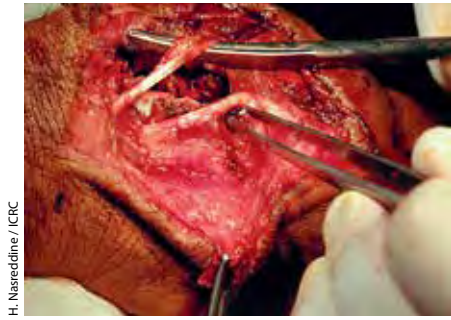
Wound exploration should be performed under adequate anaesthesia, with tourniquet control, and only in the theatre; a minor-looking wound can hide damage to important deep-seated structures. The wound should be thoroughly scrubbed with soap and water and a brush to remove in-driven dirt and debris and then irrigated with saline to clear the operative field.

Severe injuries to the hands and feet are best treated by a regime of serial debridement: a conscious decision on the part of the surgeon to debride as conservatively as possible and return the patient to theatre after 48 hours (see Section 10.8.2). The attempt to preserve delicate structures and function requires time and therefore depends on the hospital workload. A massive influx of casualties does not allow for such individualized and time-consuming treatment.

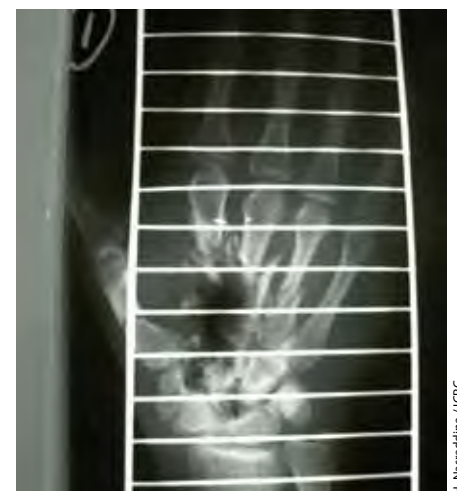

Figure 22.20.1

Gunshot wound of the hand with near total destruction of the second metacarpal.



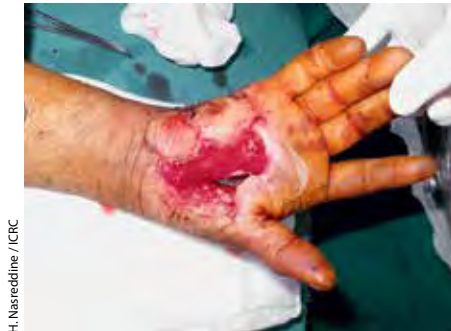**Figure 22.20.2**  
Meticulous serial debridements of the wound.

The hands and feet contain relatively little soft tissue but the vascularization is excellent. Consequently, wound excision should be conservative, maintaining as much soft tissue as possible for closure. A minimal amount of skin edge should be excised and all viable skin saved, including that from an amputated finger or toe, which should be wrapped in a humid gauze compress and kept in the blood bank refrigerator for later use as a skin graft.

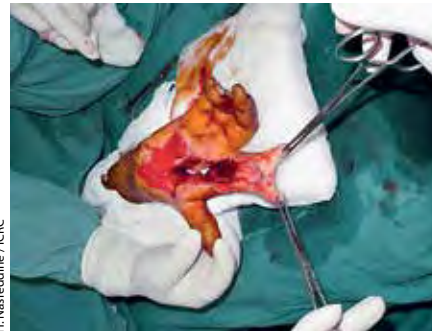Hand incisions should follow skin creases. Fasciotomies (volar carpal ligament, interosseous and lumbricals, etc.) allow better access to deep structures and release tension from oedema; a very important factor in the cramped confines of the compartments of the hand. In the foot, longitudinal incisions between the metatarsal heads are best.

Never try to reach the palm of the hand or sole of the foot from the dorsal side.

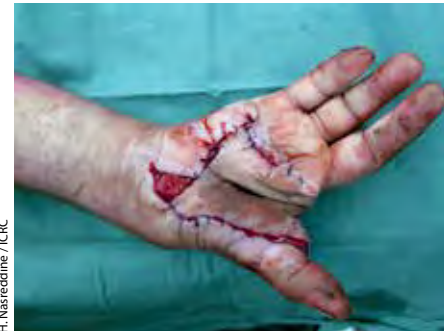Fractured bones are cleaned with copious irrigation, curettage and a bone nibbler; unattached fragments have usually already fallen out of the wound. The bone segments are then aligned and attempts made to retain the length of the second and fourth metacarpals in order to maintain the bony structure of the hand. Only irretrievably damaged digits need be amputated.



**Figure 22.20.3**  
Clean and granulating wound; however, the index finger is non-functional due to loss of bone (see-through hole) and the tendons.



**Figure 22.20.4**  
The non-functional finger has been sacrificed to provide adequate skin cover.



**Figure 22.20.5**  
Final result at DPC.

Through-and-through bullet injuries of the tarsus often require repeated curettage. Anti-personnel mine injuries to the feet contain dirt and foreign material and crushed particles of bone; the wounds readily become infected and frequently require multiple operations. In the end, amputation is often nevertheless necessary.

Severed nerves and tendons should be trimmed, tacked down or tagged, and duly recorded in the operative notes. No attempt at repair should be made at primary operation; rather only once healing of the wound has occurred and there is no evidence of infection.

Damaged nerves should be tagged and recorded but not repaired primarily.  
Injured tendons should be trimmed but not repaired primarily.

At the end of wound excision, the tourniquet is released and the viability of the remaining tissues confirmed. Major bleeding vessels are treated by ligation, small ones by pressure tamponade. The wound is again copiously irrigated.

Wounds should be left open and covered with well-fluffed gauze. The fingers should be splayed apart with compresses or small pieces of sterile sponge.



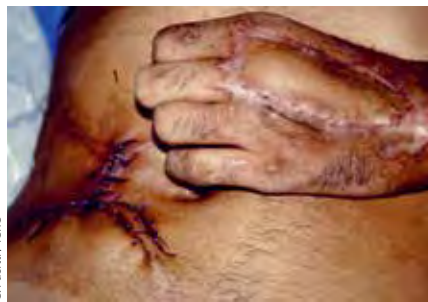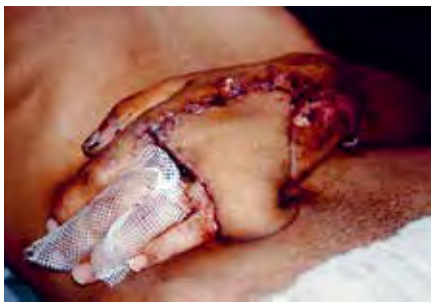### 22.7.3 Immobilization

The hand or foot should be kept elevated and the joints splinted with a POP slab. The ankle should be maintained at 90° of dorsiflexion.

The presence of open wounds in the hand does not prevent immobilization in the “safe position” and a bulky dressing fitted into the palm can help maintain it (see Figure 15.13). Unaffected digits should be left free to move, unless used to “buddy-splint” an isolated injured finger. The tips of all the digits must be left exposed to monitor the adequacy of the circulation.

### 22.7.4 Delayed primary closure

Delayed primary closure of wounds in the feet is performed after 5 days, but for the hands already after 3 – 4 days owing to their good blood supply. Often, the extent of skin loss is such that skin grafting is required. To reduce the risk of graft contraction, a full thickness or pedicle graft is advised.



Figures 22.21.1 and 22.21.2

Reconstruction of the soft tissues of the hand using a pedicle skin graft from the abdominal wall.

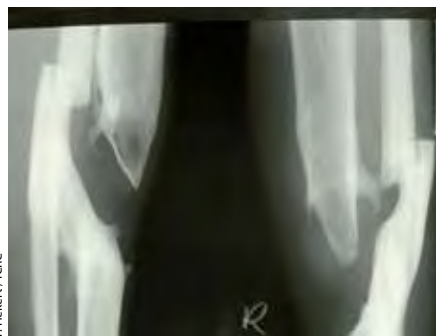
The hand is an *exception* to the rule concerning internal fixation: this is one of the few places where it is permitted to place a metal foreign body: Kirschner wires for immobilization of the metacarpals or phalanges or to bridge a gap while awaiting bone grafting. The hand should be supported in a cock-up splint or cast for 2 weeks and then vigorous physiotherapy begun.

## 22.8 Problematic cases

When working in resource-poor settings, surgeons are often faced with wounds that are weeks or even months old. As a result, complications are common. The major problems encountered are malunion, non-union, chronically exposed bone and osteomyelitis.

Many of the techniques required to deal with these problems belong to specialized areas of orthopaedic and reconstructive surgery and even sophisticated and specialist procedures often fail and result in a worse situation. Only if reasonable function cannot be obtained with conservative treatment should surgery be advised, always taking into account both the surgeon’s expertise and the level of nursing care available. Before embarking on it, the surgeon should ask whether there is any simpler alternative including the referral of a patient to a more adequate facility offering the required expertise. The decision must be made on a case-by-case basis in full consultation with the patient and family.

The more complicated the procedure, the more complicated the complications.



F. Heikert / CDC

**Figure 22.22**

Atrophic pseudo-arthrosis following a gunshot wound of the tibia. The fibula blocks any movement at the site of the pseudo-arthrosis. The functional result is acceptable.

### 22.8.1 Malunion

Most cases of malunion can be prevented by correct reduction of the fracture, whatever method of bone holding is chosen. Some old fractures present with well-established malunion. The question is whether to accept the degree of deformity present or to attempt a correction.

Correction of a malunion involves refracturing of the bone and sometimes requires a bone graft as well. External fixation may be needed for proper alignment of the new fracture.

### 22.8.2 Non-union

Non-union of fractures is common. Infection is a major cause, resulting from inadequate surgery or neglect as seen in old untreated wounds, and must be brought under control before anything else is attempted.

#### Preventable causes

Soft-tissue interposition may occur between fracture ends; in fresh cases, the wound should be explored and the fracture reduced.

Traction may have been too strong and the bone ends distracted; this should have been prevented by proper monitoring and correction of the traction weight.

External fixation is often very rigid and, as a result, delayed union and non-union are common. Conversion to a POP cast with weight-bearing mobilization is a simple and often successful technique.

#### Non-preventable causes

Extensive bone defect due to the original injury and debridement is the major non-preventable cause. Large bone gaps can fill in if a sufficient periosteal sleeve remains and the patient is well fed; malnutrition is common in patients with old, neglected wounds and must be corrected.

#### Management

No radiological evidence of union after three months in the lower limb and two months in the upper, or less than 50% union after six months all qualify as delayed union and call for freshening of the fracture site and insertion of a bone graft.

In most cases, external fixation is required to maintain alignment for bone grafting. To give the graft the best chance of "taking", the wound should be clean with a good local blood supply, and free of haematoma accumulation. In ideal circumstances, the soft-tissue wound has already healed; an open technique (Papineau) can be used for a clean and granulating wound. For the operative details of bone grafting, see Annex 22.E.

### 22.8.3 Chronically exposed bone

The bone often remains exposed in war wounds, particularly if infection supervenes. The most common and problematic example involves the tibia; common because of its subcutaneous nature and problematic because of its vascular supply and the frequent loss of a considerable surface area of periosteum. The patient usually presents with an unhealed fracture and a draining wound; or an exposed dry bone with necrotic periosteum and sequestra.

First and foremost, it is the wound not the bone that must be dealt with. The surgeon must remove all non-viable tissues and sequestra and embedded foreign material, and drain any fluid collections and dead space.

**ICRC EXPERIENCE**

On occasion, a patient with an old wound “performs” a sequestrectomy as an “assistant” to the surgeon. Patients often play and fiddle with their wounds and, sometimes, sequestra are extruded in this fashion. The patient hands over a bone fragment to the surgeon on the morning round and the wound infection clears up soon afterward.

Normal functioning of the limb encourages and improves circulation; muscle action serves as a secondary pump preventing venous stasis and oedema formation and encouraging lymph flow. Physiotherapy, exercises, and weight-bearing are *essential* factors in promoting circulation and healing.

If the patient is well fed and the wound is cleaned up and well vascularized, the wound tends to heal by itself, albeit by secondary intention and after a prolonged period of time.

“Healing cannot be imposed; it must be cultivated.”

P.W. Brown<sup>8</sup>

Many surgeons attempt to speed up this healing process. They resort to a number of techniques to cover exposed bone and close the soft-tissue wound: relaxation incisions; drilling holes in the cortex or shearing off the cortex with a bone chisel to promote the growth of granulation tissue and then skin grafting; and local myo-epithelial and cross-leg pedicle flaps. Some do succeed, but the operations are often complicated and subject the patient to numerous anaesthesias – and the results are often disappointing.

For the tibia, a simple method that has often proven its worth is to enclose the lower leg in a POP cylindrical cast *without a window*: the Orr-Trueta technique.<sup>9</sup> The cast is applied well contoured and in close contact with the limb, with minimal padding since oedema has already subsided. A walking heel is added and weight-bearing begins immediately. Healing occurs by secondary intention under the cast. Any necrotic cortical bone becomes separated and sloughed off and is found embedded in the padding when the cast is removed after six weeks. There is a high incidence of bony union and closure of the soft-tissue wound in a relatively short period of time.

## 22.9 Bone infection

Bone infection complicating fractures is a common problem. War wounds with fractures become infected because they present late, are mismanaged, or because inadequate surgery leaves dead bone in the wound after debridement. Basic principles apply, especially concerning the use of antibiotics. The general topic of neglected or mismanaged wounds and the role of biofilm in chronic infection are dealt with in Chapter 12. The difficulty of controlling chronic post-traumatic infective osteitis or chronic osteomyelitis should not be underestimated.

Antibiotics are of little value when sequestra are present.

<sup>8</sup> Brown PW. The fate of exposed bone. *Am J Surg* 1979; **137**: 464 – 469.

<sup>9</sup> H. Winnett Orr (1877 – 1956), an orthopaedic surgeon with the US Army, pioneered the technique of plaster cast treatment of war wounds during World War I. Josep Trueta i Raspall (1897-1977), a Catalan surgeon, developed a modification of the technique and popularized its use during the Spanish Civil War. Subsequently, as a political refugee in the United Kingdom he became a professor of orthopaedic surgery at Oxford University and contributed through his teaching to fracture management during World War II. The two rank among the giants of modern war surgery. The technique has been adapted by E. Dehne and A. Sarmiento in more recent times, and is often used by ICRC surgeons. See Selected bibliography.

The widespread prevalence of HIV/AIDS in many countries experiencing armed conflict favours the occurrence of infection and complicates its treatment. Needless to say, the overall management of the patient and availability of medical care, especially antiretroviral drugs, must be taken into account when deciding on surgical procedures, namely their number, extent, degree of sophistication, and chances for improved survival. There is no point in putting a patient through multiple anaesthetics and operations at the risk of pushing the patient “over the edge” into a terminal condition.

### 22.9.1 Wound management

The well-established principles of wound management, as often repeated in this manual, also apply to infection of the bone.

- Surgery is essential to remove all foreign material and dead tissue, including devascularized bone, and to disrupt the biofilm of chronic infection.
- Antibiotics alone do not eradicate bone infection.
- Recurrence of infection after initial surgery usually means that a sequestrum remains in the wound.

To overcome chronic bone infection the patient must be well fed and the wound well vascularized.

Immobilization is important. In the presence of infection, external fixation is often the best choice as it allows access to the wound for repeated sequestrectomies and wound care.

### 22.9.2 Antibiotics for established bone infection

Patients who arrive with infected wounds, because of late presentation or mismanagement in a previous facility, require antibiotic protection from invasive streptococcal and clostridial infection in conjunction with wound excision. A distinction should be made between this well-established prophylaxis and the treatment for recurrent, pyogenic infection of bone.

In both cases, antibiotics are only a supplement to surgery; dead bone and biofilm compromise the vascularity of the wound and antibiotics cannot reach the pathogenic bacteria. The combination of benzyl penicillin plus metronidazole in heavy doses, according to the ICRC protocol, is recommended as an inexpensive and safe treatment.

If pyogenic infection persists despite the apparent removal of all dead and foreign material, or if the patient first presents with systemic signs of spreading sepsis, then a good empiric combination is cloxacillin, metronidazole and gentamycin. This is especially the case where bacteriological culture and sensitivity are not available.

Locally applied antiseptics or antibiotics are not of proven value. The usefulness of antibiotic-impregnated beads or cement remains controversial and they are seldom available where resources are limited.<sup>10</sup>

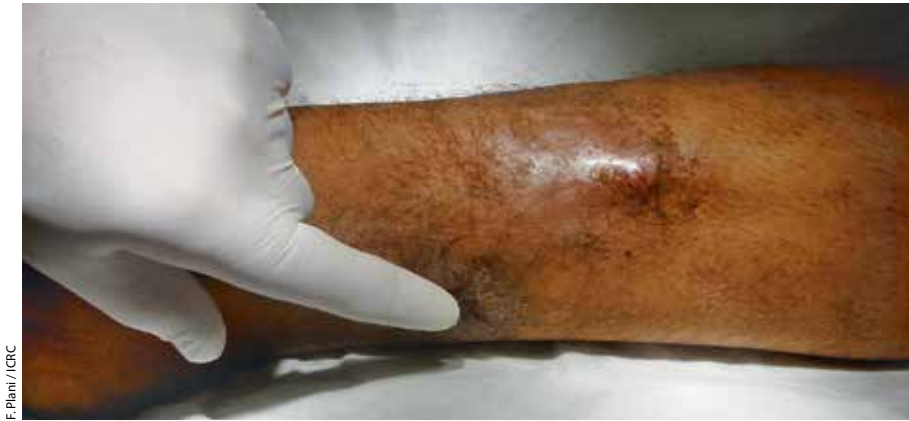### 22.9.3 Surgical treatment

This manual makes a distinction between two clinical presentations.

- Early bone infection in neglected or mismanaged wounds or following the failure of initial debridement for which the patient must undergo several re-excisions is dealt with in Section 12.3.
- Chronic bone infection may present weeks, months or even years after injury and often even after apparently successful treatment: i.e. true chronic osteomyelitis. This usually presents as consolidated bone with a persistent discharging sinus,

<sup>10</sup> Antibiotic beads were originally impregnated with gentamycin. More modern versions, and impregnated bone cement, use vancomycin and tobramycin, apparently with greater success.

and a sequestrum lodged at the bottom serving as a nidus whose removal is required before healing will occur. This condition is the subject of the remainder of this Section.



**Figure 22.23**

Old GSW of the tibia; a chronic sinus has opened and closed and is now "pointing".

#### 22.9.4 Preparing the patient

In low-income countries, patients with a chronically discharging sinus are often malnourished. The haemoglobin must be checked and the nutritional status corrected. An anthelmintic may be indicated in addition to a high protein diet and iron and vitamin supplements. Patient hygiene is important and the burden of potentially pathogenic commensal organisms should be reduced: besides general showering, the skin of the affected limb should also be scrubbed clean with copious soap and water and a brush.

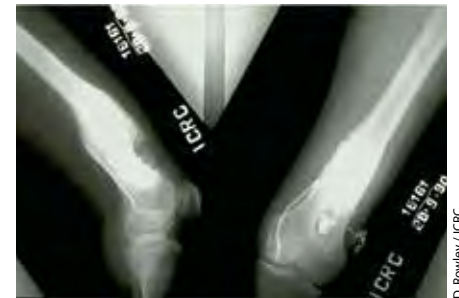#### 22.9.5 Radiography

Appropriate X-rays of the affected bone in two planes are essential; stereotactic localization employing radio-opaque markers is very useful in the absence of sophisticated radiography (see Section 14.4). A sinugram helps outline the cavity that contains the sequestrum properly. The sinus can be surprisingly long.

##### Performing a sinugram

The surgeon must perform the sinugram in person and in cooperation with the X-ray technician. The equipment is simple: standard X-ray cassettes and lead aprons; 50% diluted solution of urological contrast medium; a Foley catheter (CH 8 or 10); and two syringes.

1. The patient and X-ray cassette are positioned and the radiographer sets the exposure appropriately. Once the contrast medium is injected, there may not be time to make adjustments.
2. The surgeon wipes the wound clean and inserts the Foley catheter into the sinus for a few centimetres. The balloon is inflated slightly in the tight confines of the sinus to prevent back-flow of contrast medium.
3. The surgeon then gently but firmly injects a few millilitres of dilute contrast medium through the catheter. No contrast medium should *leak out* onto the skin, dressings or X-ray cassette.  
  
Should the sinus opening be too small for the insertion of the Foley, the surgeon can apply a syringe without the needle to the opening with pressure. The dye is then injected while trying to prevent it from leaking out. The technician takes an antero-posterior picture.
4. The surgeon inspects the X-ray: if it does not show a sinus adequately, a little more contrast is injected and another film taken. When the sinus is shown clearly, the lateral film is taken.



**Figure 22.24**

Patient X: a sinugram showed that the sinus was associated with a cavity containing a sequestrum.

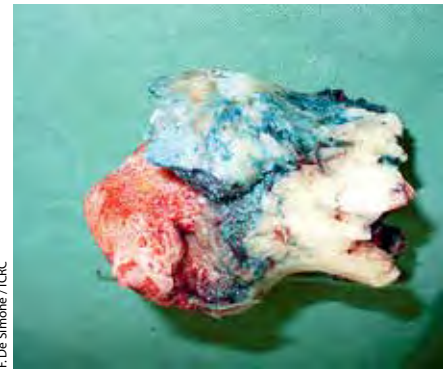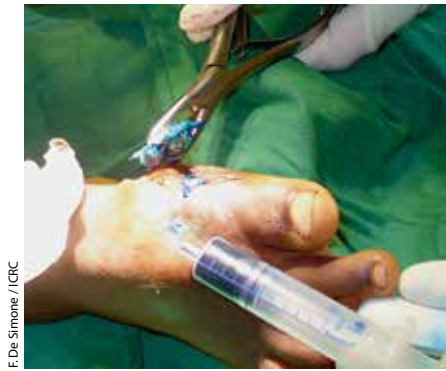### 22.9.6 Excision of the sinus

Sequestrectomy cannot be achieved by simply scraping the sinus with a curette. The piece of dead bone in the depths must be found and removed; the operation should be planned according to the sinugram. The sinus is often very small; to explore the wound properly may involve making a partially healed wound bigger. A secondary incision through healthy tissue may be necessary to reach and remove all the sequestra. The procedure may have to be repeated until all dead bone is removed.

The operation is best performed under a pneumatic tourniquet. The injection of methylene blue into the sinus assists in the identification of the tract and the surgeon should make a mental note of adjacent major nerves and vessels.

Figures 22.25.1 and 22.25.2

Patient Y: methylene blue has been injected into a sinus and has stained the target sequestrum in the metacarpal.



The sinus is dissected out until the bottom is reached, where the bone fragment is to be found. If possible, the sinus tract should be completely excised. If the sinus communicates with a joint, a formal arthrotomy must be combined with sinus excision. The joint capsule is closed at the end of the procedure.

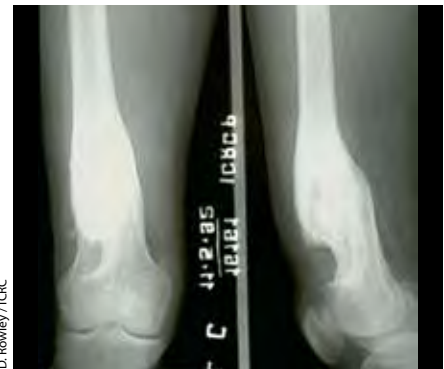
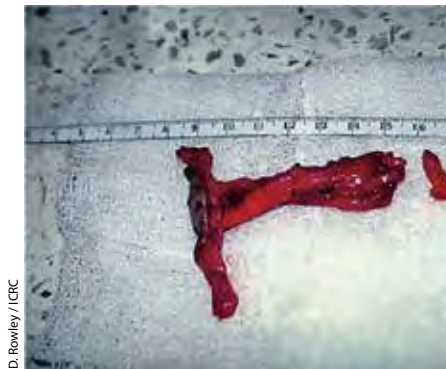
Figure 22.25.3

Patient X: the sinus tract has been excised and the bone fragment removed.

Figure 22.25.4

Patient X: resolution of the infection and consolidation of the fracture has followed.

The wound should be left open to granulate and subsequently accept a skin graft, or be allowed to close spontaneously by secondary intention.

Please note:

Sinus excision with sequestrectomy is not always a simple operation. Frequently, the bone fragment is surrounded by very strong, new cortical bone formation at the end of the sinus. Very good surgical instruments are needed (different-sized sharp chisels) to gain access to the sequestrum. While a bone such as the tibia is easily accessible, the femur is not: ICRC surgeons sometimes recommend not operating on patients suffering from a deep sinus of the femur because of the difficulty and trauma associated with sequestrectomy, unless acute symptoms are present.

If a wound continues to discharge pus, dead bone has been left behind and another attempt at sequestrectomy is called for. Repeated dressings and changing antibiotics will not suffice.

## 22.9.7 Dressing the wound and follow-up

The ideal ward dressing for a deep cavity left after excision of a sinus is cheap, non-toxic, antibacterial and easy to apply. A daily sugar dressing after rinsing with saline fulfils these criteria; honey is even better, but more expensive and not always available. This method effectively cleans wounds and promotes the formation of granulation tissue. When the exudate has stopped, a simple dry dressing changed every 3 – 4 days is all that is needed.

Once infection has been eliminated around an unhealed fracture, there may be rapid in-growth of callus, especially around small defects. Therefore, bone grafting should not be envisaged until four to six weeks after complete healing.

### ICRC EXPERIENCE

Over a number of years, ICRC delegates noted a specific clinical problem in the eastern region of the Democratic Republic of the Congo. Many patients with chronic osteomyelitis, either haematogenous or post-traumatic, spent months or even years in hospitals, operated on or not, and received various antibiotic cocktails. The prolonged disability and social cost of such patients were a tremendous drain on their families.

A simple protocol was instituted to confirm the management described in the ICRC brochure *War Wounds with Fractures* by Professor David Rowley:

- short-term peri-operative antibiotics;
- proper and aggressive sequestrectomy;
- daily sugar dressings;
- good nutrition;
- early physiotherapy.

At a mean post-operative follow-up of 13.7 months, 71 patients out of 168 admitted to the protocol could be traced (patient tracing is very difficult in conflict-affected areas). Thirty-six of these patients (50.7%) had excellent to good overall results with regard to their pre-treatment disability. Forty-six (63.4%) had excellent to good results in terms of clinical cure of the infection. A full description of the clinical protocol is to be found in Annex 22.D.

22

## 22.10 Bone grafting

As with soft-tissue reconstruction, there are simple basic techniques for bone grafting that are well within the competency of a general surgeon, and other more specialized ones that should be left to the expert.

### 22.10.1 Indications for bone grafting

1. Non-union and primary bone defects.

Some Type C and most Type D bone defects, according to the RCWS, require a graft. This is just as true for the metacarpals as for the tibia or femur, in order to regain as good a function as possible.

Timing is important. For Type D defects, the requirement for a bone graft is usually obvious from the very beginning and can be performed as soon as the soft-tissue wound is well healed. In cases of non-union, the need for grafting is apparent once sufficient time has elapsed to confirm insufficient progress in fracture consolidation.

The bone ends must be refreshed with bone nibbling forceps until red specks appear (Haversian vascular system) and any fibrous tissue at the fracture site excised. Care should be taken to preserve any remaining periosteum. A bone graft then fills in the fracture site.

## 2. Correction of malunion.

The fracture site must be exposed; this is often a bloody procedure given the growth of dense fibrous tissue during wound healing. The new cortical bone is refractured and then the fragments realigned and a bone graft put in.

## 3. Infected non-union and post-sequestrectomy bone defects.

Infection can result in non-union and the removal of large sequestra required to eradicate the infection can create a sizable gap between bone fragments.

The cleaning of an infected non-union and preparation of a subsequent bone graft is a prolonged exercise. Bone grafting should not be performed earlier than *six months after* infection has been controlled and full soft-tissue healing accomplished.

### 22.10.2 Donor site and types of bone graft

The donor site from which cancellous bone chips are harvested will usually be the iliac crest on the same side as the injured bone. Cancellous bone stimulates bone formation: it is both osteo-conductive (the acellular matrix serves as a scaffold for new bone deposition) and osteo-inductive (cells and substrates carry and produce chemicals such as growth factors that stimulate bone formation). Cortical bone does not have the same properties.

Cortical grafts and bicortical grafts, consisting of cancellous bone sandwiched between two cortices, can also be taken from the ilium. These are required when more complicated surgery such as mandibular reconstruction is involved.

The operative details of bone grafting are described in Annex 22.E.

### 22.10.3 Follow-up of bone grafting

Once the graft has been placed, the patient should be gradually mobilized with increasing weight-bearing to stimulate callus formation.

An X-ray taken soon after grafting gives a better baseline of bone radiodensity than pre-operative films. A successful "take" of the graft shows no radiographic change for the first two weeks; it then becomes increasingly dense. Resorption or infection of the graft, on the contrary, is revealed by loss of radiodensity.

The time required for bone union is variable and should be estimated primarily on clinical grounds, as for a fracture. If after some weeks the X-ray shows that all the graft has simply resorbed without having exerted its stimulatory effect on bone healing, the grafting procedure will have to be repeated.

### 22.10.4 Complications of bone grafting

There are a number of complications related to bone grafting; infection is the most common. When pure cancellous bone grafts become infected, they simply dissolve. Cortical bone grafts, on the other hand, can become the nidus of later infection and require active removal.

If donor site infection is suspected, the surgeon should not hesitate to open the wound, wash it thoroughly and leave it open to heal by granulation. Haemorrhage and haematoma formation at the donor site requires opening of the wound and tamponade to achieve haemostasis.



## ANNEX 22. A Plaster-of-Paris

Bone immobilization techniques using plaster-of-Paris are simple, effective, inexpensive and versatile. Certain basic rules and conditions must be respected and, like all manual techniques, require practice and close attention to detail. POP is particularly suited to surgeons working where resources are scarce.

The reader is referred to standard textbooks and to the ICRC brochure included in the DVD attached to Volume 2 of this manual for the elementary principles of the use of plaster-of-Paris. This Annex covers topics and techniques that ICRC surgeons have found to be useful and appropriate.

### General principles

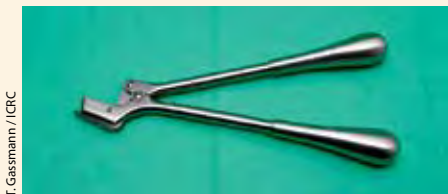In general, a POP splint or cast should include the joints above and below the fracture site, which should be immobilized in their functional position. For the lower limb, the knee is flexed to 15° and the ankle kept at 90°. In the arm, the elbow is kept at slightly more than 90° of flexion and the hand should be immobilized in the safe position. The unaffected fingers and toes should be kept free to allow a full range of movement of metatarso-phalangeal, metacarpo-phalangeal and interphalangeal joints.

Swelling occurs in a limb within the first 24 – 48 hours after a fracture, severe sprain, wound or operation. The bandages holding a POP splint in place should not be wrapped too tightly. Tight bandaging can produce a tourniquet effect and impair circulation, especially over the front of the ankle or the tibia where it can cause partial or full thickness skin loss.

Immediate splitting or bi-valving of a complete cast for a fresh closed fracture is a basic tenet of the use of plaster-of-Paris. The cast and the underlying padding and bandages should always be split down to the skin. Excessive pain, out of proportion with the extent of the wound, calls for the removal of the splint or cast and inspection of the limb. In this chapter, it is taken for granted that the fractures under discussion are open. No complete cast should be applied until oedema and haematoma have resorbed.

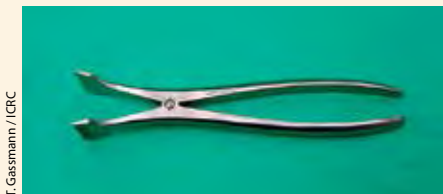### 22.A.a Equipment

The basic materials and tools needed to perform satisfactory POP techniques are simple, easily acquired, and undemanding to maintain.



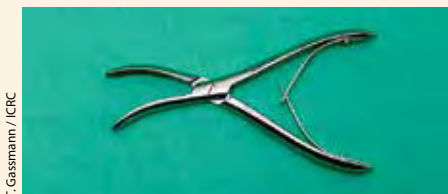
T. Gassmann / ICRC

**Figure 22.A.1**  
Plaster shears.



T. Gassmann / ICRC

**Figure 22.A.2**  
Cast spreader.



T. Gassmann / ICRC

**Figure 22.A.3**  
Cast breaker.



T. Gassmann / ICRC

**Figure 22.A.4**  
Oscillating saw.

1. *Plaster-of-Paris bandages* come in several standard widths: 2.5, 10, 15 and 20 cm. They should be kept in airtight containers because plaster absorbs moisture and quickly becomes crumbly. Wet hands or damp rolls of plaster should not be put into the container. Modern commercial bandages come individually wrapped in waterproof plastic. Some hospitals produce their own using POP powder in bulk, and gauze bandages.

2. *Stockinet* of various widths corresponding to the sizes of the limb.
  3. *Plaster wool*, also known as cellulose padding, or unbleached cotton wool (10 and 15 cm widths).
  4. *Adhesive and non-adhesive orthopaedic felt*.
  5. *Kramer wire splints or strips of wood or metal* for reinforcing plaster and for making a POP bridge-cast over wounds that need to be dressed.
  6. *Walking heels*: either commercially manufactured or improvised from old vehicle tyres, hard wood or plaster shaped as a 5 cm cube. The axis of the walking heel should be just in front of the intermalleolar plane.
  7. *Plaster knives, shears, scissors and spreaders, a scalpel blade, and a large screwdriver*, useful for spreading, opening and levering plasters.
  8. *Electric oscillating plaster saw*: theoretically, the oscillating blade does not cut soft matter that vibrates and, therefore, should not cut skin. However, skin closely pressed to the cast or adherent to hardened dressings soaked in blood *can be cut* quite severely. It should also be used with great caution over bony prominences. It cannot be used on plaster that is not yet dry.
  9. *Smooth metal or rubber strips* 5 cm wide are useful for splitting a complete cast following application. The strip is placed along the length of the limb before the cast is applied. The cast is then split with a knife cutting down on the strip without danger of cutting the skin. The strip is pulled out after the plaster is cut.
- If strips are not available, the simplest method to split a wet cast is to cut through the plaster with a scalpel blade, then complete the cut through the cotton wool padding and bandages with shears.

The techniques used for POP can also be employed using newer materials, such as fibreglass, polyurethane, etc.

### 22.A.b Initial temporary immobilization

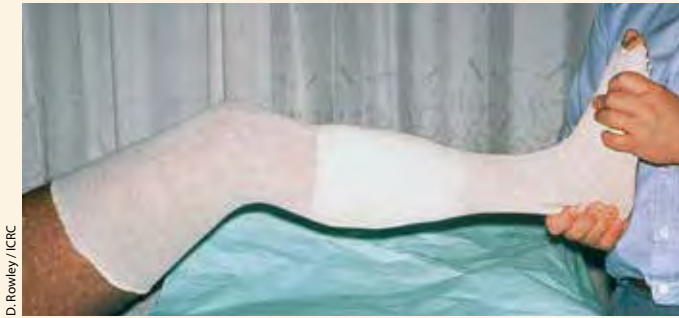
A POP splint is most useful as the initial temporary holding method after wound excision. In the upper limb, it can be applied for fractures of the forearm and hand and, when combined with a sling, for some cases of the humerus. In the lower limb, it can be used for the tibia and the foot. The only long bone not suitable for plaster splinting is the femur.

The application of a POP posterior splint for the tibia is described here; the same principles and basic technique apply to the upper limb. There are two simple methods for fashioning a posterior splint. The first employs a single multilayered slab that is applied posteriorly from gluteal crease to the tips of the toes. The “figure-of-eight” technique using two slabs that cross behind the knee or elbow joint uses less material, and creates a splint that is lighter and stronger, and is described in the following series of photographs.

**Figure 22.A.5**

Materials: four 15 cm rolls of plaster; stockinet or cotton padding; and gauze or elastic bandages. Two slabs – each eight layers of plaster thick – are prepared. The length of the slabs is measured on the patient’s good limb, from the tip of the toes to just below the greater trochanter.





D. Rowley / ICRC

**Figure 22.A.6**

The stockinet is applied to the leg over the wound dressing.



D. Rowley / ICRC

**Figure 22.A.7**

Padding is applied over the stockinet to pressure points at risk: the malleoli, heel, patella and head of the fibula.



D. Rowley / ICRC

**Figure 22.A.8**

The first wetted plaster slab is applied so that it encloses the fifth toe and lateral border of the foot, passes posteriorly over the heel and is moulded over the calf. It continues behind the knee to end on the medial aspect of the thigh.



D. Rowley / ICRC

**Figure 22.A.9**

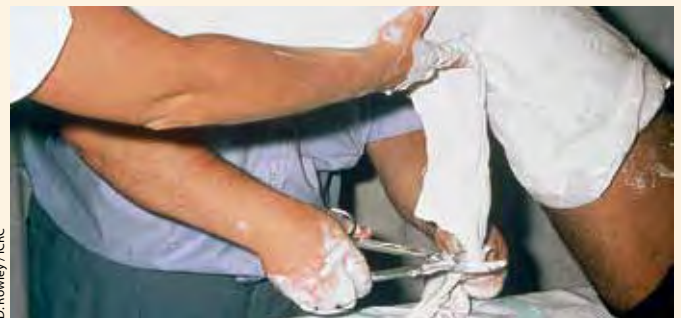The slab should take the configuration shown.



D. Rowley / ICRC

**Figure 22.A.10**

The second slab is applied in the same fashion, but starting over the first toe and medial border of the foot, crossing over the first slab in the popliteal fossa, and finishing on the lateral aspect of the thigh. The figure-of-eight or X-crossing of the two slabs in the popliteal fossa is the key to giving this lightweight posterior splint its strength.



D. Rowley / ICRC

**Figure 22.A.11**

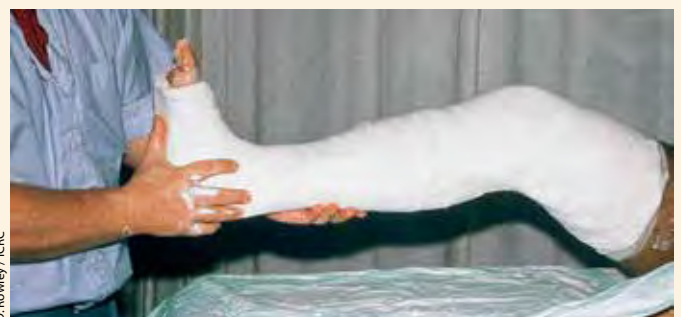Any excess plaster is trimmed; simply folding it back results in an uncomfortable, lumpy cast.



D. Rowley / ICRC

**Figure 22.A.12**

Gauze or elastic bandage is gently but firmly applied to keep the slabs in position; it should not be too restrictive.



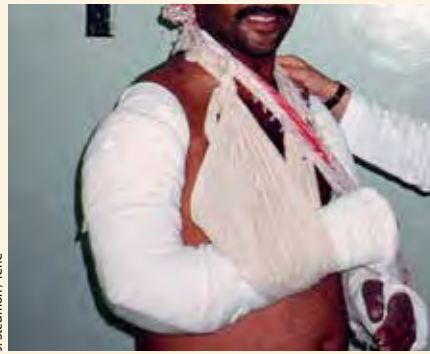D. Rowley / ICRC

**Figure 22.A.13**

The back slab is held until the plaster has set with the knee flexed to 15° to prevent rotation: the easiest way to ensure this is by placing a one-litre plastic bag of i.v. fluid under the knee. The ankle joint is immobilized in the neutral position: 90° to the axis of the tibia to avoid plantar flexion. The finished edges should be smooth and not dig into the skin. The limb and finished back slab are raised on a pillow. A POP-calendar is written on the bandaging with a felt marker-pen to record dates of application and further treatment: DPC on such and such a day, etc.

### Initial splinting of specific fractures

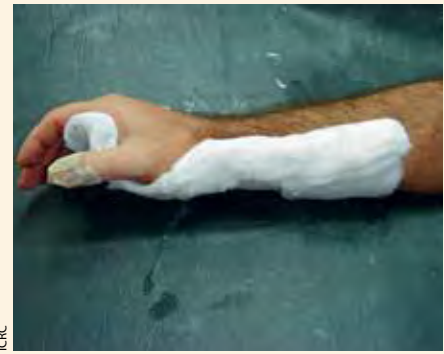Similar slabs are employed for other bones. The reader is referred to standard orthopaedic texts for the details.



J. Steadmon / ICRC

**Figure 22.A.14**

Long arm slab for fractures around the elbow joint or of both bones of the forearm: elbow in slightly greater than 90° flexion, forearm in neutral pronation-supination, wrist flexed depending on level of fracture.



ICRC

**Figure 22.A.15**

Forearm slab for fractures of one bone in the forearm, or for the wrist or hand. Injured fingers should be included in the splint in the "safe position" (Figure 15.13). Unaffected fingers are left free to allow a full range of movement.

### 22.A.c Definitive immobilization

After DPC, the limb can continue to be immobilized with a POP splint if oedema is still present or visual inspection of the wound is required. If the splint is retained, it can be taken down after 10 days for suture removal and replaced with a cylindrical cast.

The use of POP for definitive fracture holding entails the use of a cylindrical cast, bridge cast, or spica. This definitive cast requires no more padding than absolutely necessary, namely to protect the pressure points, since oedema should have settled by then and the cast does not need to be split since no further swelling is to be expected.

A special case: external fixation of the tibia should be replaced with a POP cylindrical cast as soon as possible, especially if access to the wound for further surgical care is no longer necessary. The cast permits mobilization of the patient with load-bearing on the fracture site, which is a potent stimulus to bone consolidation.

External fixation of the tibia should be converted to a cylindrical cast as soon as soft-tissue coverage has been accomplished.

As a general rule, the skin should be thoroughly washed and dried before the application of a permanent cast. Plaster bandages should be applied by rolling them out, without tension, each bandage covering one-half of the previous bandage. The palm of the hand, not the tips of the fingers, should be used to hold or mould wet bandages, to avoid creating pits that can create pressure sores.

#### Methods of definitive POP immobilization

A complete cylindrical cast or spica can be applied to both the upper and lower limbs. Other modifications can also be usefully employed.

- Foot: boot-cast.
- Tibia: full-length leg cast from the gluteal crease to the toes.
- Tibia: Sarmiento patella-tendon-bearing (PTB) cast – a special type of walking cast.
- Femur: "Chinese splints" or a functional brace with knee hinges to be applied after traction and once bone consolidation has reached the stage of allowing partial weight-bearing aided by crutches.

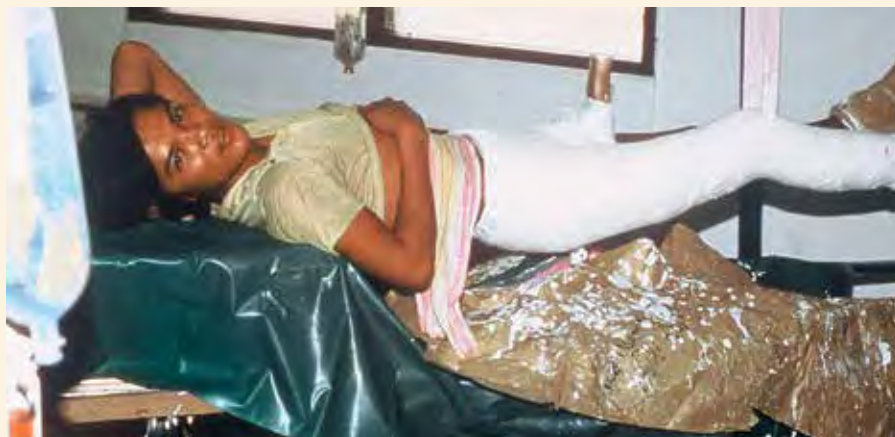- Hip spica: applied once the soft-tissue wound has healed and the fracture is “sticky”. Also a useful method in infants over the age of six months and as an alternative to gallows traction.
- Hand or the forearm: especially if only one bone is fractured.
- Shoulder (thoraco-brachial) spica: useful if the shoulder is likely to be ankylosed, for arthrodesis, or for proper alignment of fragments in a fracture of the humeral neck. It is not easy to fashion, and a simple alternative if alignment can be ensured is a back slab extending from the acromion to below the flexed elbow and held in a cuff-and-sling.



Figure 22.A.16

Shoulder or thoraco-brachial spica: shoulder in abduction, flexion and rotation; elbow in 90° flexion; forearm in full supination.

H. Nasreddine / ICRC



ICRC

Figure 22.A.17

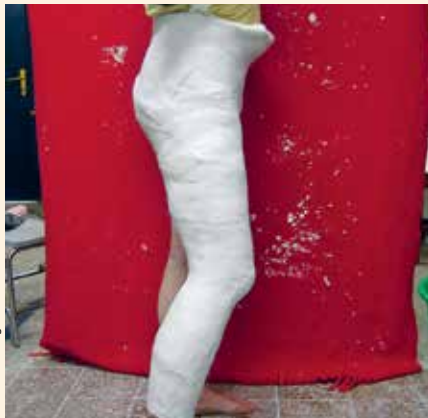Application of a hip spica on a locally-made table using a bicycle seat and aluminium tubing.



D. Odhiambo Ngota / ICRC

Figure 22.A.18

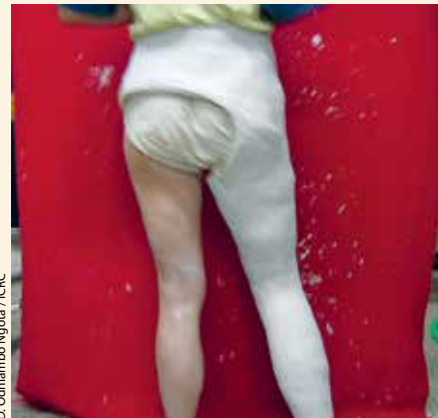Locally-made spica table.



D. Odhiambo Ngota / ICRC

Figures 22.A.19 and 22.A.20

Hip spica: hip in 30° flexion, 10° abduction and 10° external rotation; knee in 15° flexion.



D. Odhiambo Ngota / ICRC

### 22.A.d Tibia: Sarmiento tibial cast<sup>11</sup>

Casting of the tibia is by means of either a long leg cast, from the groin to the toes, or the Sarmiento patella-tendon-bearing cast. Rather than the immediate application of a Sarmiento PTB-cast, a long-leg cast can be applied for the first two weeks and then replaced with a Sarmiento cast, which is preferred because it permits knee movement.

The Sarmiento PTB-cast is moulded around the patellar tendon, distal patella and upper third of the tibia, where it is closely shaped to the tibial condyles anteriorly and slightly flattened in the popliteal fossa.

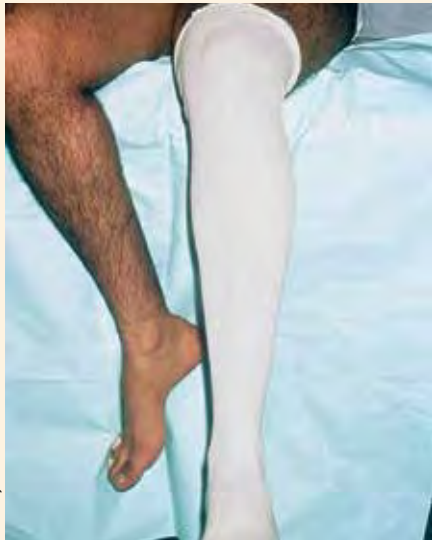

T. Gasmann / ICRC

Figure 22.A.21

Materials: five 15 or 20 cm and two 10 cm plaster bandages; two rolls of padding and stockinet.

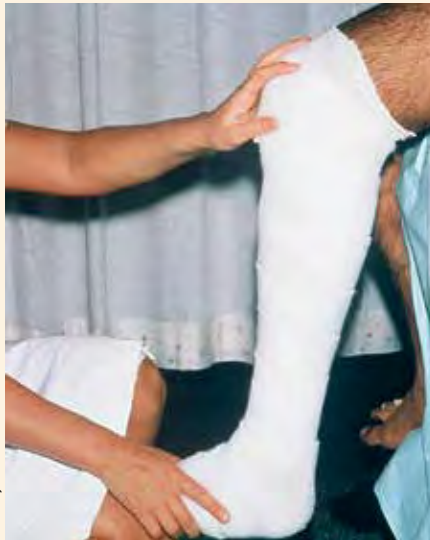11 Dr Augusto Sarmiento, orthopaedic surgeon at the University of Miami School of Medicine, has specialized in fracture healing by non-operative methods and functional fracture bracing.



D. Rowley / ICRC

**Figure 22.A.22**

The patient sits on the end of the bed with the leg hanging vertically, the foot not touching the floor, thus allowing gravity to align the bones and relaxing the quadriceps muscle. Stockinet is put on from the toes to 15 cm above the knee.



D. Rowley / ICRC

**Figure 22.A.23**

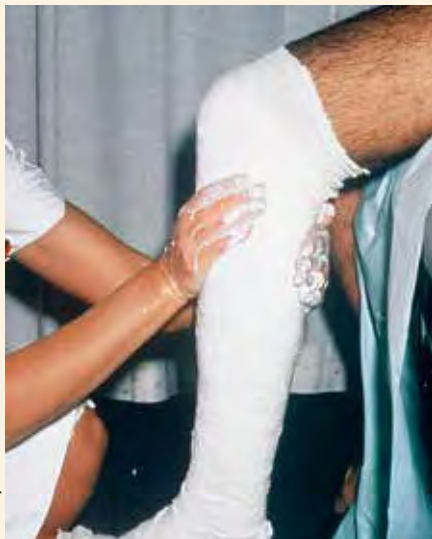The stockinet is covered with padding, paying special attention to the vulnerable bony pressure points.



D. Rowley / ICRC

**Figure 22.A.24**

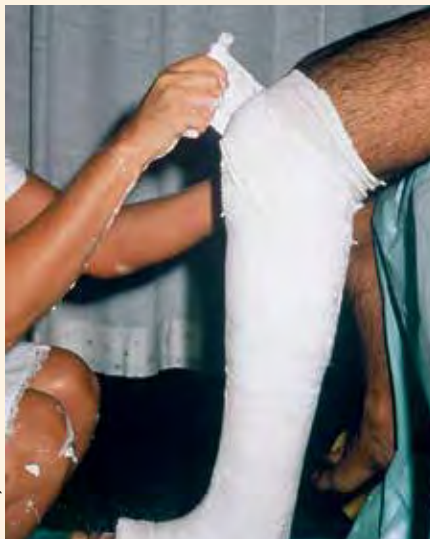The central part of the cast over the tibia is fashioned first by applying two 15 or 20 cm plaster bandages.



D. Rowley / ICRC

**Figure 22.A.25**

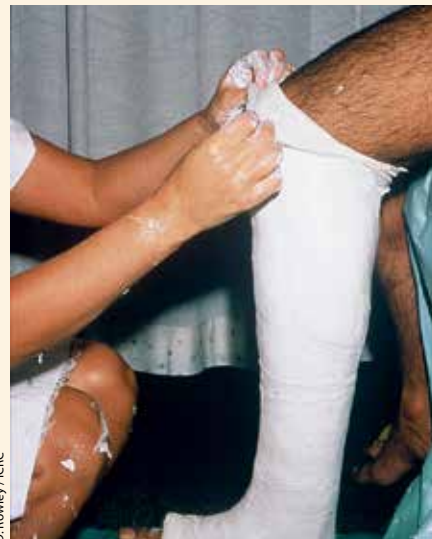The upper third of the central part is moulded around the tibia in front and indented by both thumbs into both sides of the patellar tendon. It is flattened at the back in the popliteal fossa.



D. Rowley / ICRC

**Figure 22.A.26**

The cast is left to set enough to retain the moulded shape with the ankle kept at 90° flexion. The two 10 cm plaster bandages are then applied up to the superior pole of the patella and moulded over it.



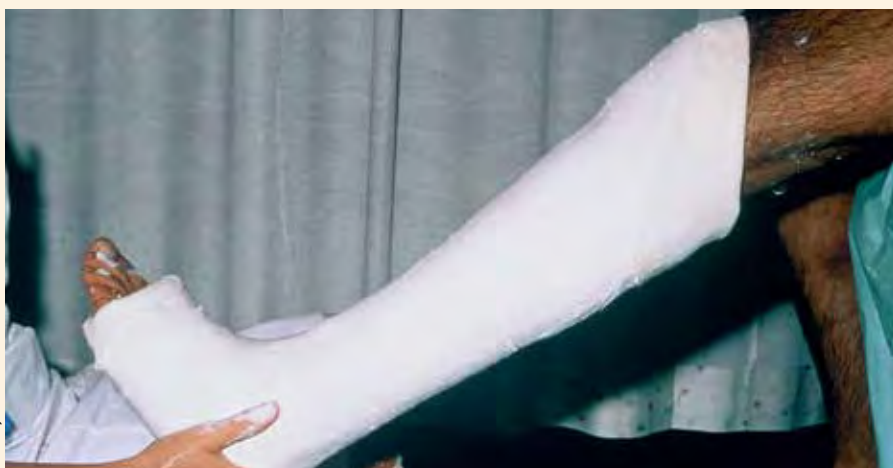D. Rowley / ICRC

**Figure 22.A.27**

While the plaster is still wet, the stockinet is turned down so the patella remains covered. The plaster in the popliteal fossa is trimmed to two finger-breadths below the level of the popliteal flexion crease, low enough to allow 90° of knee flexion without the edge of the cast rubbing on the tendons. The finished shape should encompass the femoral condyles when the knee is flexed.

**Figure 22.A.28**

The plaster is allowed to set.



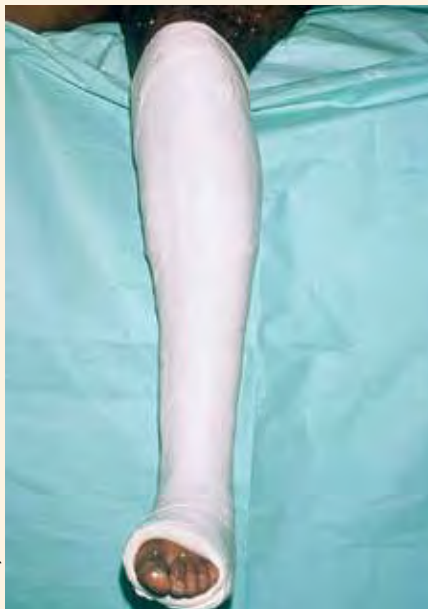D. Rowley / ICRC



D. Rowley / IGRC

**Figure 22.A.29**

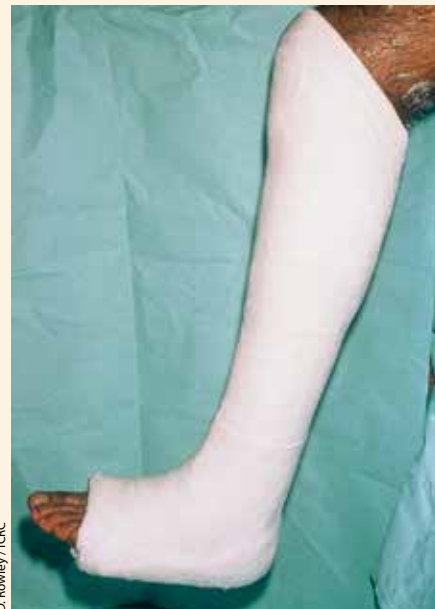The sole is reinforced; a rubber walking-heel may be added.



D. Rowley / IGRC

**Figure 22.A.30**

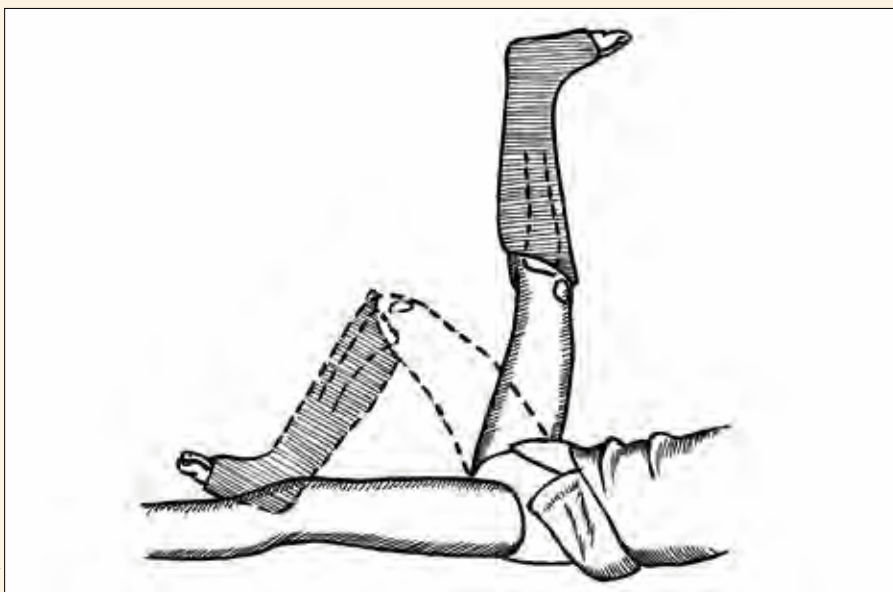
The finished Sarmiento PTB-cast seen from the front.



D. Rowley / IGRC

**Figure 22.A.31**

The finished cast seen from the side. The knee should flex to 90° and fully extend.



N. Papas / IGRC

**Figure 22.A.32**

Principle of the Sarmiento PTB short leg cast: the knee can be fully flexed and extended while the cast provides good support to the tibia.

22

### 22.A.e Post-traction support of the femur

Many patients who have undergone skeletal traction as a definitive holding method for fracture of the femur require no further support once they are out of bed and moving on crutches. Some, however, do better with the physical and psychological support provided by “Chinese splints” or a hinged brace.

#### “Chinese splints”

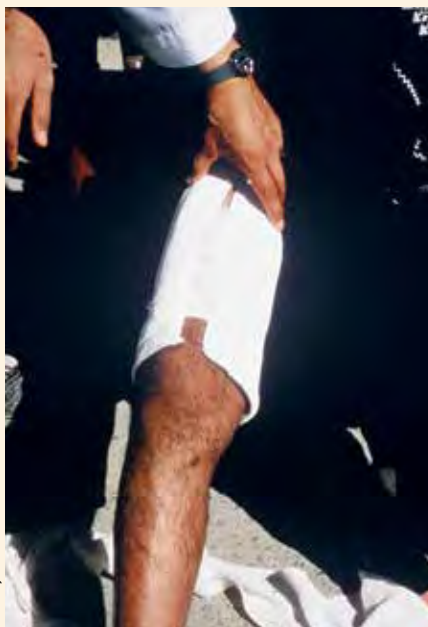“Chinese splints” – named after traditional bamboo splints – offer the simplest method. Two straightforward plaster shells which do not overlap are held onto the leg by bandages. They provide comfort and soft-tissue support, and a small degree of positional control. They also give useful proprioceptive feedback to the contracting muscles during exercise, thus making physiotherapy more effective. The “Chinese splints” are worn until the fracture becomes immobile on firm stressing.



D. Rowley / ICRC

**Figure 22.A.33**

Two simple slabs are moulded to the thigh while the plaster is setting.



D. Rowley / ICRC

**Figure 22.A.34**

The slabs are held in place by bandaging.



D. Odhiambo Ngota / ICRC

**Figure 22.A.35**

Locally-made knee hinges join a simple below-knee POP cylinder to a thigh cylinder. See Appendix.

### Femoral hinged brace

The alternative is a femoral cast brace with hinges at the knee. The bi-pivotal hinge permits normal movement of the knee, controls rotation and angulation of the fracture, and provides vertical support.

There are two components to a femoral brace: 2 circular casts and 2 hinges. A standard below-knee walking cast and a well-moulded plaster thigh piece are fashioned and then connected by means of hinges, medially and laterally. The moulding of the plaster to the soft tissues is the most important part of the procedure; the casts are applied without padding. Hinges may be bought or made locally out of aluminium or plastic. The centre of rotation of the hinges should be in the same plane, and in line with the joint line.

### 22.A.f Definitive immobilization with an open wound

A complete cylindrical cast may be applied before the wound has fully healed. For small wounds some surgeons cut a window in the POP to allow for dressings (Figure 22.A.36). However, the soft tissues tend to bulge out and rub on the edges of the window creating "window oedema". To prevent this, the removed piece of plaster should be put back in place and secured with an elastic bandage to diminish swelling. Indeed, small wounds can be enclosed in a complete cast *without any window* or dressing changes and allowed to heal by secondary intention, and this method is to be preferred (Orr-Trueta technique, see Section 22.8.3). Larger wounds that do require dressing changes will benefit from a bridge-cast.



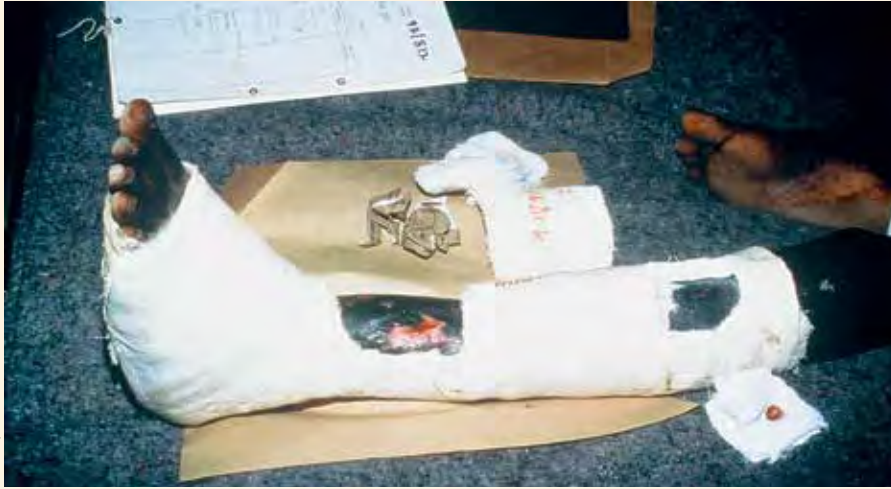

Figure 22.A.36

A below-knee cast with windows cut out so that wounds can be dressed. Note the “window oedema”. The size of the wounds does not justify the creation of a window.

D. Rowley / ICRC

### Tibia bridge-cast

A variation of a cylindrical cast is a bridge-cast, which allows access to the wound while maintaining bone immobilization: a low-technology alternative to external fixation for the tibia. It is most useful for the tibia, but can also be used for the humerus or elbow joint.

1. One circular plaster cast is applied to the lightly-padded thigh, knee and leg to just above the wound with the knee at 15° of flexion.
2. A second circular cast is applied from just below the wound down to the foot, with the ankle at a right angle.
3. With the upper and lower fragments thus under control, traction or correction of any angulation can be carried out easily, if necessary.
4. The two circular casts are then joined together by two or three Kramer wire splints or metal bars, which are secured to the POP casts by circumferential turns of a plaster bandage.

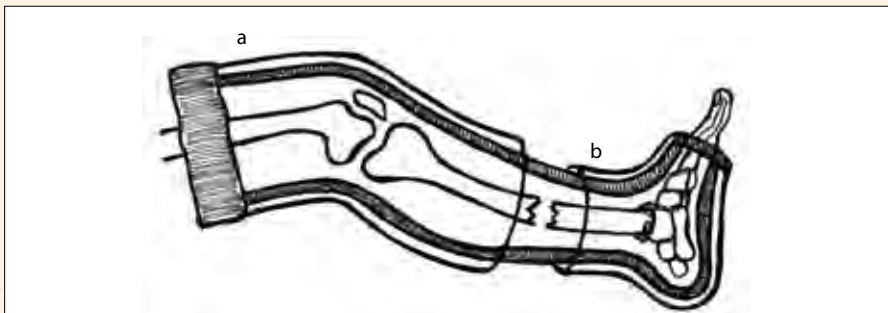


Figure 22.A.37

Constructing a bridge-cast:  
a. upper cast placed first;  
b. lower cast placed second.

N. Papas / ICRC

An ICRC physiotherapist, Fernando Vega, developed a sliding-sleeve mechanism as a bridging piece that can be manufactured locally. The sliding sleeve allows for distraction or compression or slight alteration of the fracture site and is locked in place with a simple nut and bolt.



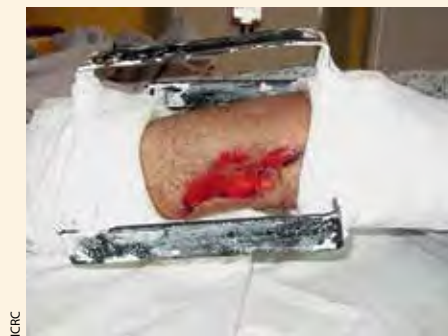Figure 22.A.38

A Vega bridge-piece can be manufactured locally. See Appendix.

ICRC

Figures 22.A.39 and 22.A.40

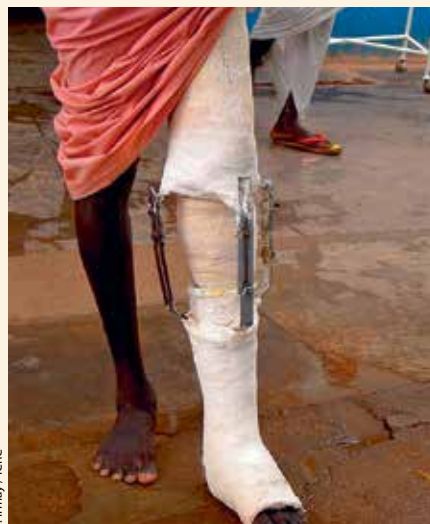Bridge-cast applied to the leg with a wound that still requires change of dressings and skin grafting.



ICRC



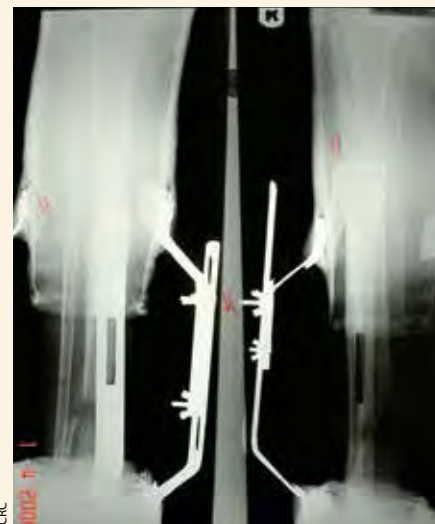F. De Simone / ICRC



F. Irmay / ICRC

Figure 22.A.41

Patient walking with a Vega bridge-cast.



ICRC

Figure 22.A.42

Radiograph showing a Vega bridge-cast in place.

## 22.A.g Managing patients in POP

Initially, any limb immobilized in POP should be elevated when the patient is sitting or lying down and the state of the limb carefully monitored to detect compromise of the distal circulation that might lead to compartment syndrome and ischaemia (see Section B.10). Even a dressing stiff with dried blood may be sufficient to restrict the circulation. Any complaint of pain or numbness should be taken seriously and any suspicion of circulatory problems requires immediate opening of the splint or splitting of the cast, cutting the bandaging, padding and dressings down to the skin and levering the cast open. If there is no improvement, fasciotomy and decompression of all compartments are called for.

Check the distal circulation.

An X-ray should be taken to check the alignment of the fracture after the application of a cast. If it is satisfactory, weekly films should be taken for two weeks and then monthly to union. Malposition of bone fragments must be corrected in order to avoid malunion; the cast must be removed, the fracture reduced correctly, and a new cast applied. X-rays are only an adjunct to good clinical examination of the patient, however. Clinical union of a fracture is defined as X-ray evidence of progressive callus formation *and* clinical evidence that healing is taking place. Radiological union takes longer than clinical union and the patient does not have to wait for this to start weight-bearing.

In fractures of the lower limb, weight-bearing results in rapid bone healing and patients should be encouraged to get out and about with crutches as soon as possible; mobilization should begin after the POP is completely dry, which takes about 40 hours. In addition, the patient should fully mobilize the free joints and undertake isometric exercises to maintain muscle tone while wearing a cast. Active and passive movement of the joints and development of muscle tone should also be encouraged after removal of the plaster cast. Without motivated physiotherapy the physical rehabilitation of an injured limb is very slow and the functional result poor.

Move the patient and the joints as soon as possible  
– and encourage the patient to do the same.

## 22.A.h Complications of POP

### “Plaster disease”

The application of a plaster cast with the joints immobilized invariably results in joint stiffness, muscle wasting and osteoporosis. Isometric exercises while wearing the cast, early weight-bearing and the use of functional braces, and post-removal physiotherapy reduce these phenomena to a minimum and promote a rapid retrieval of function.

### Malunion and non-union

Malunion and non-union never result from the proper use of a POP cast. They are due to poor technique. Malunion is caused by inadequate reduction of the fracture. Non-union is due to excessive movement at the fracture site because of too much padding, an insufficient quantity of plaster bandages, or poor quality bandages.

### Skin problems

Patient hygiene is an important consideration and the presence of a splint or cast prevents washing. The skin under the plaster becomes dry and scaly since shed epithelium cannot be washed off and may become a focus for dermatitis, maceration of the skin, rash and infection. Thorough washing of the limb prior to wound excision and again before application of a cast can diminish if not entirely prevent skin problems. Patients discharged wearing a cast and managed on an outpatient basis also suffer these problems when the cast becomes wet and breaks down. The patient should be instructed on how to protect the cast at home and on how to ensure personal hygiene of the rest of the body while wearing it.

A sensation of burning or rubbing under the cast might indicate the development of a sore. The cast should be removed, the skin condition dealt with, and a cast reapplied. Correct technique with adequate padding over bony pressure points (heel, malleoli, head of the fibula and olecranon) is essential to prevent the formation of sores. Excessive padding does not compensate for poor technique, but rather results in an ill-fitting cast with lack of immobilization and undue movement.

APPENDIX

These items may be manufactured locally or ordered from an ICRC operational delegation in a country which is the scene of an armed conflict.

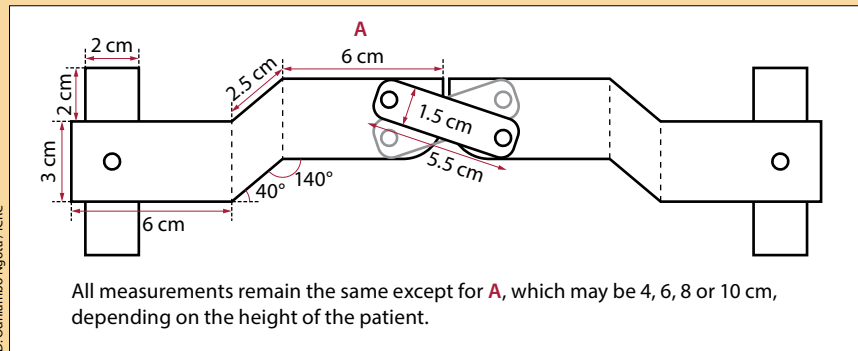


Figure 22.A.43  
Polycentric joint for a knee hinge.

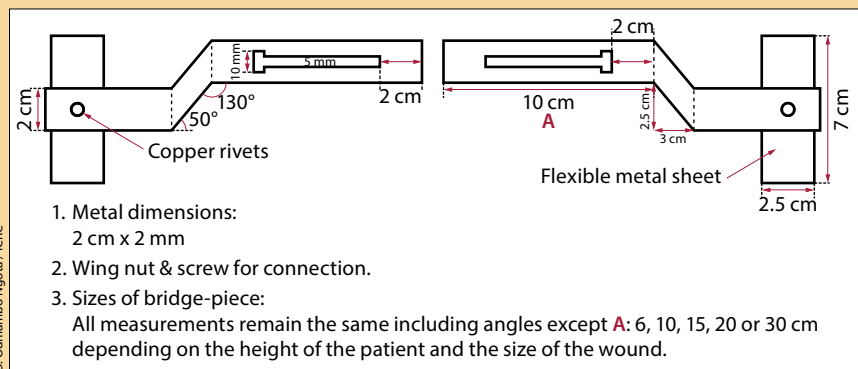


Figure 22.A.44  
Vega bridge-piece.

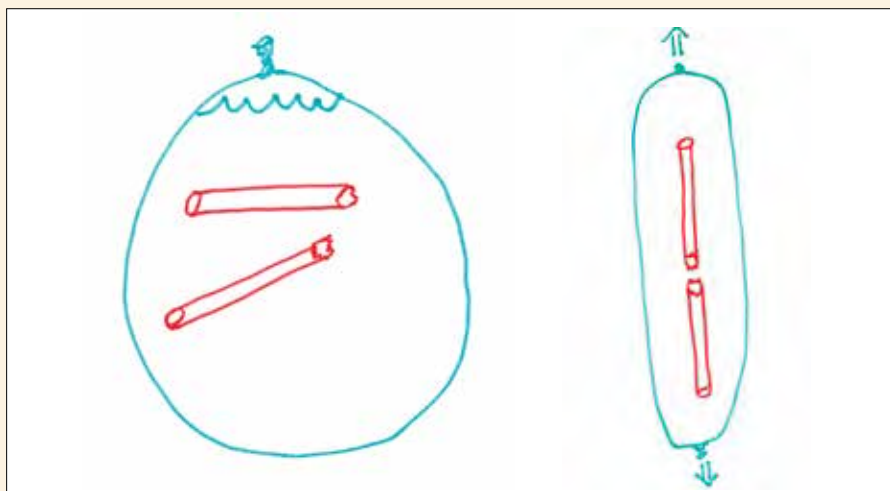
## ANNEX 22. B Traction

Traction is an ancient technique: a simple sling has been used for fractures of the humerus since time immemorial. Skin traction by means of a Thomas splint was the standard care for fractures of the femur during World War I. Skeletal traction proved to be the safest and simplest method for mass treatment of femur fractures in World War II. A noted advantage was that the technique was readily mastered by the extra-medical personnel recruited to serve and who had had no previous experience of orthopaedics in their civilian practice: general practitioners, obstetricians, paediatricians, etc.

Traction may be applied in several forms: physiological, cutaneous and skeletal.

### 22.B.a Biomechanical principles of traction

The basis for traction treatment lies in the concept of *ligamentotaxis*. The limb can be visualized as a cylinder of soft tissues pulled and elongated by the traction force, which then pulls and moulds the bone fragments into place until callus has formed and is sticky enough to maintain length.



R. Gosselin

Ligamentotaxis: traction applies a force to the soft tissue of the limb, not to the bone.

The elongating force opposes the tone in the muscles surrounding the fracture site, thus enabling the bone fragments to be slowly pulled into alignment as the muscle tone is overcome. The elongating force may be applied either via a physiological force (weight of the limb), adhesive tape (skin traction) or a pin (skeletal traction) depending on how much force needs to be applied.

### 22.B.b Traction techniques

#### Physiological traction

Physiological or functional traction is used for fractures of the clavicle or humerus and relies on the weight of the arm and gravity to reduce and immobilize the bone within its soft-tissue sleeve. For the clavicle a simple triangular or figure-of-eight bandage is sufficient. For the humerus, the arm is kept suspended in a narrow wrist cuff-and-collar sling; the elbow should not be supported in the sling, only the distal part of the forearm. A very light POP U-slab may be added for extra protection. Physiological traction suffices for both initial and definitive fracture immobilization.

Figure 22.B.1

Ligamentotaxis: the leg can be compared to a balloon with solid fragments in it. Pulling the balloon by traction moulds the fragments into place.

22

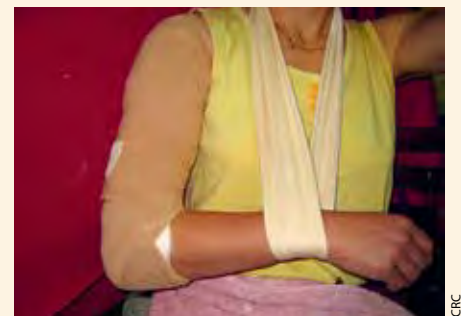
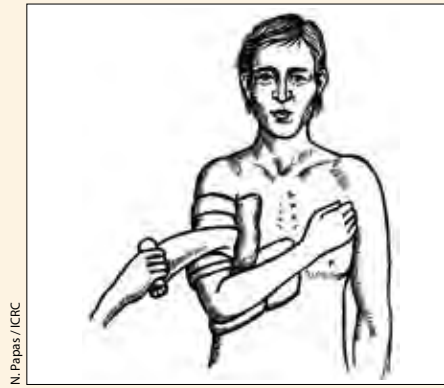
Figure 22.B.2

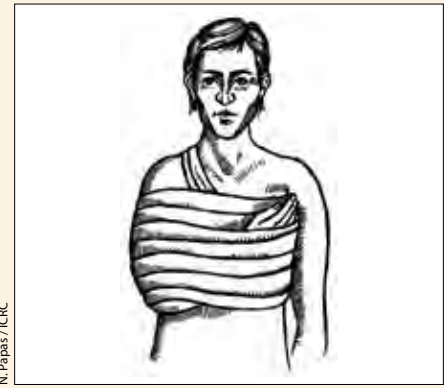Physiological traction of the humerus.

ICPC

Figures 22.B.3 and 22.B.4  
Strapping of the humerus.



N. Papas / ICRC



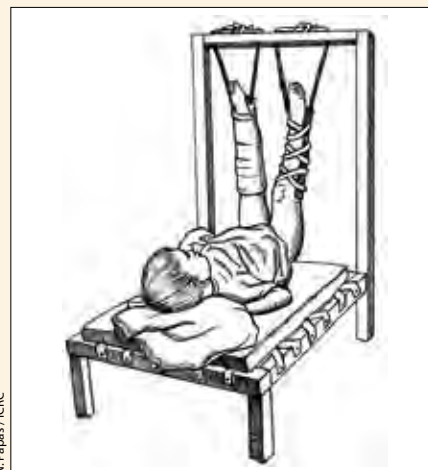N. Papas / ICRC

**Skin traction**

Skin traction is indicated for fractures of the femur in infants and children and frail elderly patients requiring a small amount of traction. Application of adhesive strapping requires proper degreasing of the skin with tincture of benzoin or ether. Both initial and definitive immobilization can be ensured.

For infants below 12 – 15 kg of body weight (usually less than three to four years of age), it is applied in the form of “gallows traction” on *both legs*, which are hung up above the patient with hips in 90° flexion, allowing ease of bowel toilet and nursing care (Figures 22.B.5 and 22.B.6). For older children and the elderly, the lower limb is left lying flat on the mattress: *in-line extension* Figure 22.B.7. Up to 5 kg of traction can be applied, provided the patient has healthy skin.

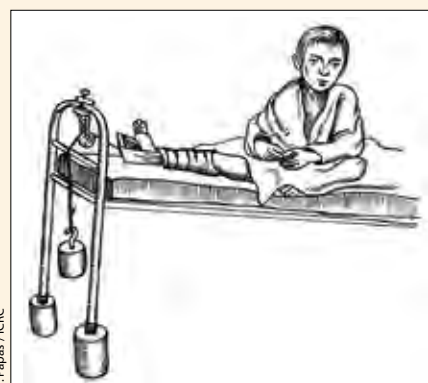Figures 22.B.5 and 22.B.6  
Gallows traction in a frame.



N. Papas / ICRC

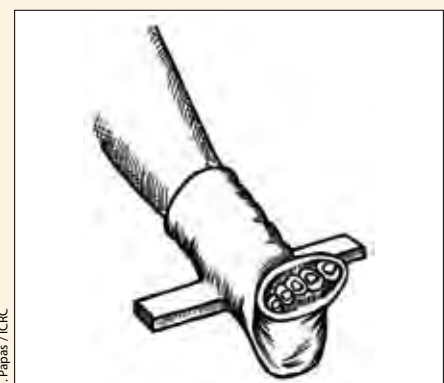

J. Stedmon / ICRC



N. Papas / ICRC

Figure 22.B.7  
In-line extension skin traction.



N. Papas / ICRC

Figure 22.B.8  
“Airplane-wing” splint to prevent rotation of the limb during in-line extension.

Skin traction can also be used for fractures of the femur in adolescents and young adults, usually in conjunction with a Thomas splint or one of its modern variations. Adding a POP back slab and plaster bandaging around the sidebars of the Thomas splint created the “Tobruk splint”. It is an inexpensive and useful technique for evacuation and transfer of patients if external fixation is not used.

### Skeletal traction

A pin is placed in the bone to act as a focal point for the application of traction.

Skeletal traction is used for:

- fractures of the femur;
- some fractures of the distal humerus around the elbow;
- fractures of the tibia, particularly around the knee joint or in the distal third.

Skeletal traction is the most common method of fixation used for the femur when working with limited resources, both as initial and as definitive bone holding. The leg is supported by means of a Braun-Böhler frame or one of its modifications; always a golden opportunity for surgeons and physiotherapists to test their inventiveness. It can be converted to external fixation if required. Subsequent to skeletal traction, "Chinese splints" or a POP functional hinge-brace may be applied.

### 22.B.c Pin placement

The limb should be washed, prepped and draped as for any operation. Local anaesthesia can be used to place the pin or, if a debridement is to take place at the same time, general anaesthesia.

The pin should always be placed from the side most at risk, dissecting out the neurovascular bundle to protect it. This means the lateral aspect for the tibia, and the medial for the femur, calcaneus and olecranon.

For the femur, the best site is the upper tibia, 2.5 cm distal to and 2.5 cm posterior to the tibial tubercle. There is minimal muscle insertion at this site and the knee can be bent without distorting the traction force. If skeletal traction is used when the patient's growth plates are still open, the pin should be placed in the distal femoral metaphysis and inserted from medial to lateral, 2.5 cm proximal and anterior to the epicondyles (Figure 22.B.12). If possible it should be done with the knee in flexion so that the fixation of the tendons of the vastus lateralis and fascia lata is in the stretched position, thus allowing easy extension. If not, active flexion is very difficult.

1. A skin incision 1.5 cm long is made on the lateral side of the lower leg.
2. The muscles of the antero-lateral compartment are gently pushed down with an artery forceps to expose the bone, thus avoiding injury to the common peroneal nerve.
3. Using a hand drill and a 3.2 mm bit with a guard to protect the soft tissues, the tibia is perforated from lateral to medial. To counteract the natural tendency of the leg to turn inward, the drilled hole should be angulated to exert a slight external rotation

Bone drilling should be done slowly and gently; excessive speed produces heat and compression causing thermal bone injury and making the pin site prone to infection. The use of a power drill should be avoided.

4. A 4 or 5 mm Steinmann or Denham pin on a hand chuck or "T"-handle is slowly inserted down the predrilled hole until it emerges.
5. The medial incision is performed where the tip of the pin appears under the skin. The skin incisions are extended if necessary to relieve any tension around the pin. They should never be sutured.
6. A bow or stirrup is positioned over the pin. The bow rotates freely on an oiled bearing avoiding any rotation of the pin itself in the bone, which would lead to pin loosening and subsequent infection.



Figure 22.B.9  
Thomas splint.

T. Gassmann / CFC

22

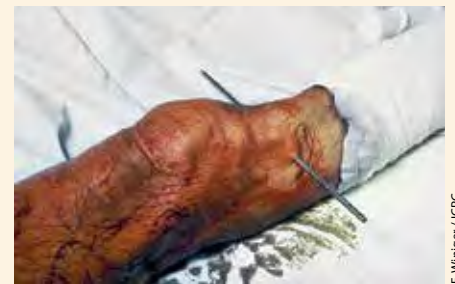

Figure 22.B.10  
Steinmann pin in position in the tibia. It has been inserted from the lateral side.

E. Wniger / CFC




Figure 22.B.11  
Böhler-Steinmann stirrup.

T. Gassmann / CFC

H. Nasreddine / ICRC



**Figure 22.B.12**

Traction pin placed in the femoral metaphysis and an empty vial used as a pin guard.

7. A pin guard fashioned from a cork or an empty medicine vial – the pointed tip pushed through the rubber diaphragm – is placed to protect both patient and staff from injury. Gauze impregnated with a dilute antiseptic solution is placed over the pin sites and covered with a bandage to prevent the patient from fiddling with the pins.

The pin site should be checked every day for tenderness, firmness in the bone and inflammation of the surrounding skin. The gauze should not be allowed to adhere to the pin or skin and the dressing should be changed every two or three days unless the gauze becomes soaked with exudate. The site should be cleaned with normal saline or a dilute antiseptic and kept free of any encrustation that prevents exudation around the pin.

A power drill or hammer should not be used for pin insertion.

Please note:

Two sorts of pins are available: the smooth Steinmann pin is stronger but has a tendency to slide in the bone, which is not the case with the threaded Denham pin. If the Denham is used, it should be colour-coded so that on removal the surgeon remembers to *unscrew and not just pull*. In addition, since pins are reused when working in a resource-poor setting, the tips need to be sharpened regularly.

**22.B.d Managing traction of the femur**

In war wounds reduction of the femur fracture is relatively easy because the damaged muscles around the fracture site have been excised resulting in a loss of soft-tissue volume. The pulling effect of the muscles on the proximal and distal bone fragments is therefore decreased and there is rarely any interposition of muscle between the bone fragments as frequently occurs after blunt trauma. Also unlike blunt trauma where the femur is often stripped of periosteum, in projectile injuries the damage to the periosteum remains localized and a sleeve is usually retained; consolidation time of the fracture in well-treated war wounds is usually shorter than with blunt injury.

As a general rule, traction of the femur should begin with 1 kg per 10 kg body weight. This force counteracts muscle contraction and, after a few days, the muscles relax. Consequently, the traction weight can quickly be decreased accordingly. Monitoring of the fracture site is important to avoid distraction of the bone ends due to excess weight.

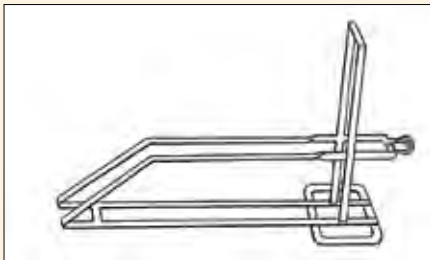
A counterforce must be applied to prevent the weight simply pulling the patient down the bed and is achieved by raising the foot of the bed so that friction and gravity resist the pull. Measures must be taken to prevent the development of bedsores.

**Position of the leg in traction**

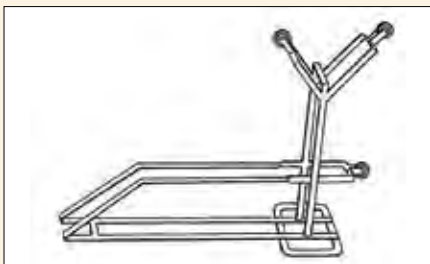
In any fracture, different forces are at work on the proximal and distal bone ends. The proximal fragment takes up a position determined by the balance of forces of the muscles that remain attached to it. The distal fragment takes up a position determined by gravity if not held in check. For traction to succeed, the distal fragment must be aligned with the proximal fragment and then the two held in this position.

A Braun-Böhler frame is most suitable for fractures of the *lower two-thirds* of the femur. The position of the traction cord can be varied through a system of pulleys to maintain the traction force along the axis of the limb. The frame elevates the limb and fine adjustments can be made by placing padding under the thigh. Foam pads are excellent; they are versatile, cheap and washable. Care must be taken to correct posterior sagging, a common occurrence in these fractures. The femoral component of the frame should be adjustable to take into account differences in patient height and therefore length of the femur.

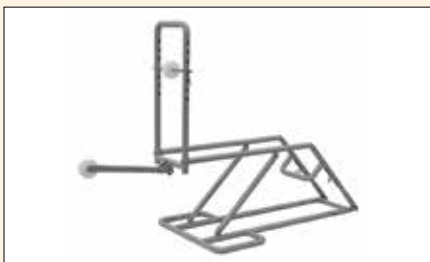ICRC



ICRC



ICRC



**Figures 22.B.13 – 22.B.15**

Classical and modified Braun-Böhler traction frame; improvisation by ICRC physiotherapists.





Figure 22.B.16  
Preparation of a Braun-Böhler frame.

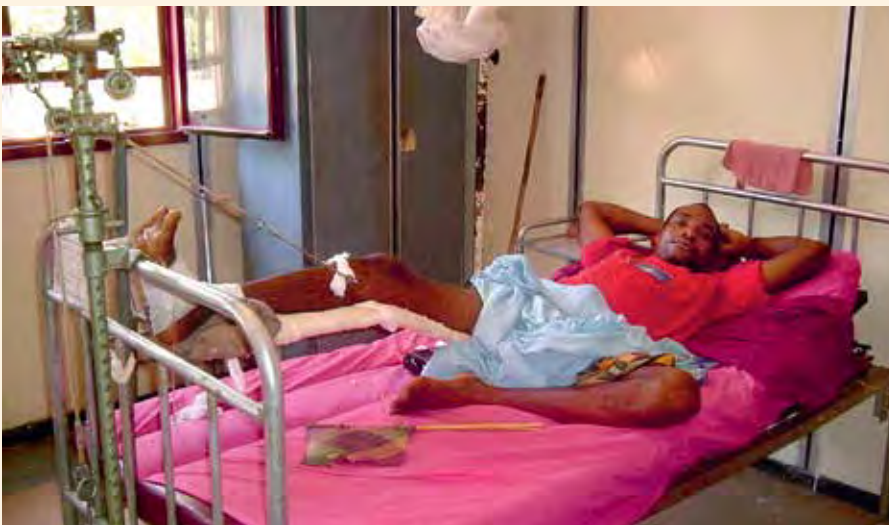

Figure 22.B.17  
Patient on skeletal traction.

The Braun-Böhler frame is not very well adapted to holding a fracture of the *upper third* of the femur. In such fractures, the powerful psoas and gluteal muscles flex and abduct the proximal fragment. To align the distal fragment with this flexed proximal fragment both the hip and the knee are flexed to 90° as shown in Figure 22.B.18, thus minimizing the effect of the muscles on the proximal fragment. The position need only be maintained for four to six weeks and presents the advantage that the knee and hip can easily be mobilized when the limb is lowered onto a standard traction frame. This consideration applies particularly to closed fractures of the femur and is much less relevant with projectile wounds. A standard Braun-Böhler frame should be used first and, if found to be inadequate, changed to the position described.

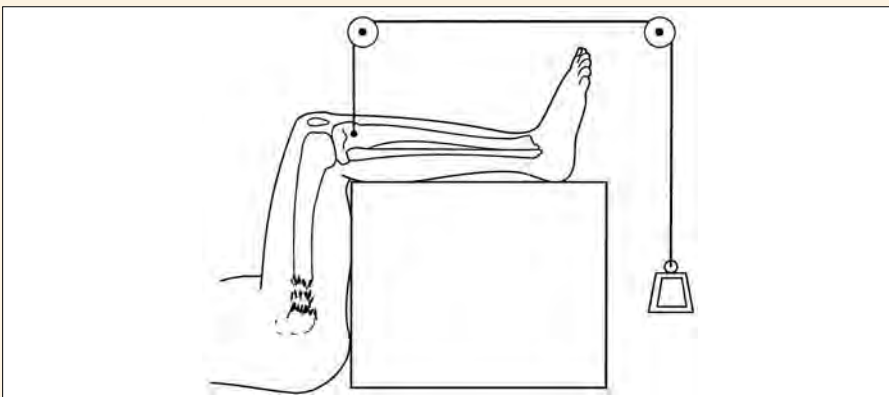


Figure 22.B.18  
A modified traction frame with a series of pulleys to treat a high femoral fracture. The hip is flexed 90° permitting the alignment of the distal fragment with the flexed proximal fragment. The position of the knee, flexed to 90°, allows the joint to be fully exercised.

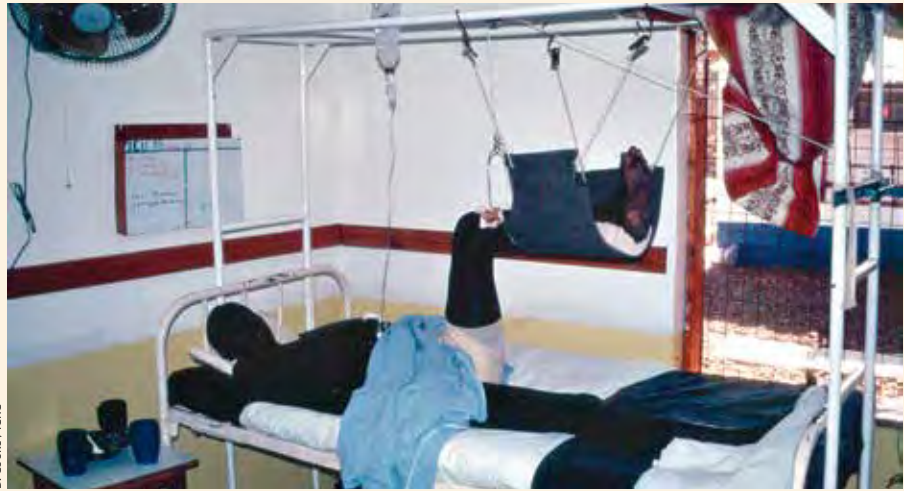ICRC

V. Sasin / ICRC

D. Rowley / ICRC

**Figure 22.B.19**

Alternative method to a Braun-Böhler frame for a proximal femur fracture.



D. Cooke / ICRC

**Monitoring of the patient and nursing care**

Management of a patient in traction is an active process. Dedicated nursing and physiotherapy staff are important; understanding what traction can achieve is essential for its successful management.

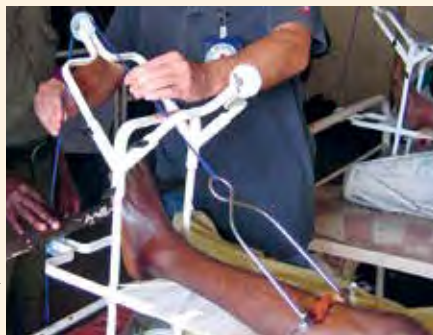A special “traction ward” can be created and is usual practice in ICRC hospitals. Ideally, a mobile X-ray machine is available. If not, a bed on which wheels and a traction system can be fixed is of great assistance in moving patients about and bringing them to the X-ray department, which should be situated close to the traction ward to allow easy access without having to alter the position of the limb. If radiography is unavailable or proves too onerous, monitoring should be pursued by clinical palpation of the fracture site.

**Figure 22.B.20**

Traction ward in an ICRC hospital.



ICRC



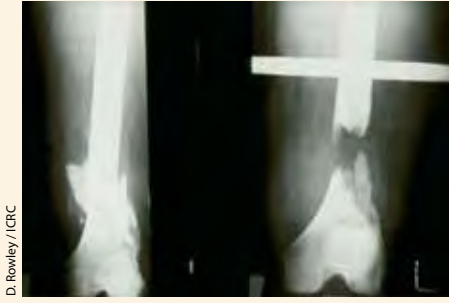I. Mecalis / ICRC

**Figure 22.B.21**

Controlling the traction and position of the patient.

The position of the patient and the limb in traction should be checked several times a day for the first two weeks, as alignment may easily alter. The overall alignment of the limb should be verified while looking from the foot of the bed: the mid-inguinal point, the knee and ankle joints, and the second toe should all lie in the same plane.


X-rays should be taken within 24 hours of traction application to act as a baseline, and repeated weekly thereafter for the first three weeks. Good position and alignment should be obtained as early as possible because as the wound heals the soft tissues adhere to the bone fragments thus preventing later adjustment of the position. After one week the muscle pull will have been overcome and the X-ray will show whether the bone fragments are properly aligned. If not, traction weight may be added or removed and padding under or around the limb applied. The position must be checked and adjusted repeatedly until a satisfactory outcome is achieved. After the first month, it is sufficient to take films once a month until union.



D. Rowley / ICRC

**Figure 22.B.22**

Post-debridement X-ray with over-distraction of fracture ends.



D. Rowley / ICRC

**Figure 22.B.23**

The weight was corrected. Proper alignment and good osteoneogenesis at five weeks.

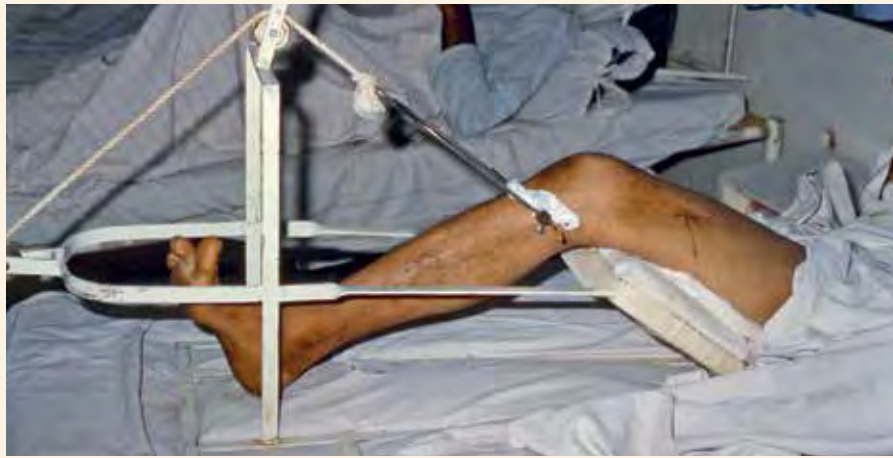Radiography verifies the position of the fracture. Weekly clinical assessment checks bone healing; the weight is temporarily removed and the fracture site palpated and stressed.

Cleaning and dressing of the pin site should be basic nursing care, as is attention to the skin and bowels, and are all a vital part of the treatment of a patient in traction.

### Mobilization of joints

Early exercises to maintain muscle tone and movement of joints are important. Movement of the joints by temporarily removing the weight should be encouraged as soon as patient comfort permits, usually after one week. However, if the soft-tissue wound is large, active physiotherapy can be painful and may hinder wound healing.

Good analgesia assists good physiotherapy.



ICRC

**Figure 22.B.24**

Mobilization of the joints of a patient in skeletal traction.

### Mobilization of the patient in bed

The patient must be monitored for the development of bedsores and kept mobile while bedridden; at the same time the alignment of the limb must be maintained. The foot of the bed should be kept raised on blocks to avoid the shearing force of the patient sliding down the bed and the bed linen should be kept as wrinkle-free as possible.

An overhead ring or bar or sling attached to the foot of the bed helps patients lift themselves up off the bed, assists in the use of the bedpan and relieves pressure zones. The patient can sit up after a few days. As part of the exercise routine, patients should raise their bodies up from the bed on straightened arms.

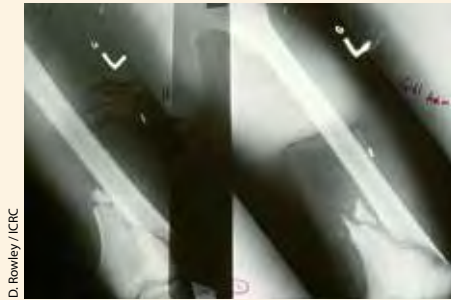### Removal of traction and mobilization out of bed

Radiological consolidation always follows clinical consolidation and should not be a determining factor.

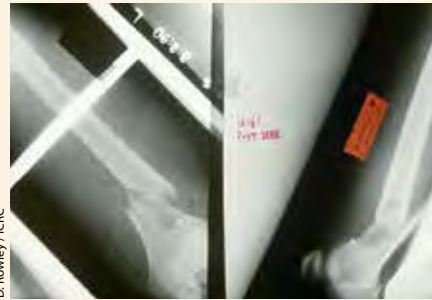There is no need to wait for full radiographic continuity before mobilizing a patient out of bed.

Removal of traction and mobilization of the patient out of bed can start as soon as the fracture is “sticky”, usually after four to five weeks; it is not necessary to wait for clinical union. The decision to withdraw traction should be made solely on clinical grounds, and only confirmed by X-ray evidence of progressive callus formation.

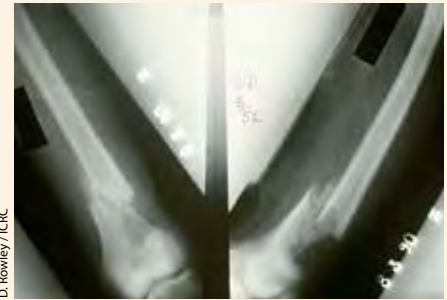The weight is temporarily removed from the traction cord and the surgeon rotates the limb to see if it moves all in one piece, and then passively raises it to check whether such movement causes any pain. The fracture site is gently palpated for discernable callus formation and stressed by gentle pressure and bending. Finally, the patient is asked to actively raise the limb. If this can be achieved without pain, the examination has proven positive and the traction can be discontinued. In the absence of radiography facilities, this careful clinical examination alone must suffice.



**Figure 22.B.25**  
GSW to the thigh. X-ray on admission, before debridement. Note the loose bone fragments.



**Figure 22.B.26**  
X-ray after debridement.



**Figure 22.B.27**  
X-ray at five weeks: good calcification was present and the traction removed.

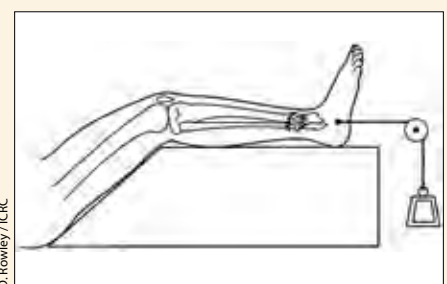
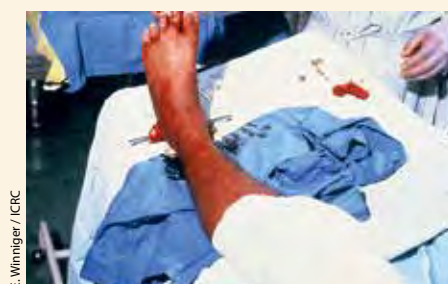The patient should stay in bed for one more week after discontinuation of traction, during which time the joints are mobilized and muscles strengthened. The patient sits on the edge of the bed and flexes the knee up to 90° (compared to the 30° on the Braun-Böhler frame) and reinforces the quadriceps by raising the leg against gravity. When muscle tone has recovered, the patient can get out of bed supported on crutches, but without weight-bearing. In principle this would mean keeping the foot off the ground; in practice some degree of weight-bearing always occurs once the patient puts the foot down. This is not important since the pain feedback mechanism prevents putting too much weight on the limb. Gradually, more and more weight is shifted onto the limb as the patient’s confidence builds up and pain recedes with increasing consolidation of the fracture.

Certain fractures may need some form of POP support, for example a transverse fracture developing a small and fragile callus. “Chinese splints” or a functional brace will help. The earlier the mobilization, the more likely the need for some form of external support.

**22.B.e Skeletal traction of the tibia**

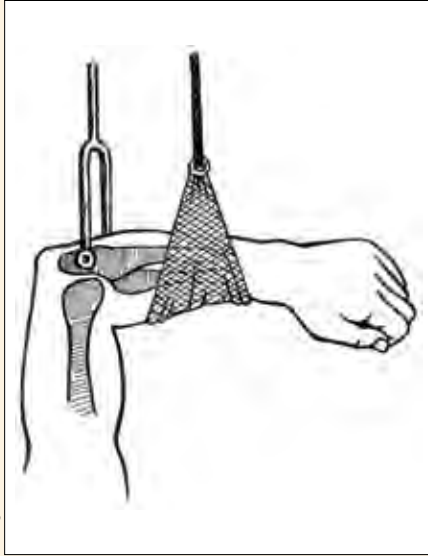
A 3 mm Steinmann pin is inserted through the calcaneus, the entry site lying 2.5 cm below the medial malleolus. The soft tissues are carefully and bluntly dissected with a haemostat to avoid injury to the posterior tibial artery. Strict adherence to the protocol for pin insertion is particularly important since infection in the calcaneus is difficult to eradicate. The traction weight is 0.5 kg per 10 kg body weight. Patient management continues as for the femur.

**Figures 22.B.28 and 22.B.29**  
Calcaneal pin and traction of a tibial fracture with the level of the pulley ensuring that the line of pull is along the axis of the limb.

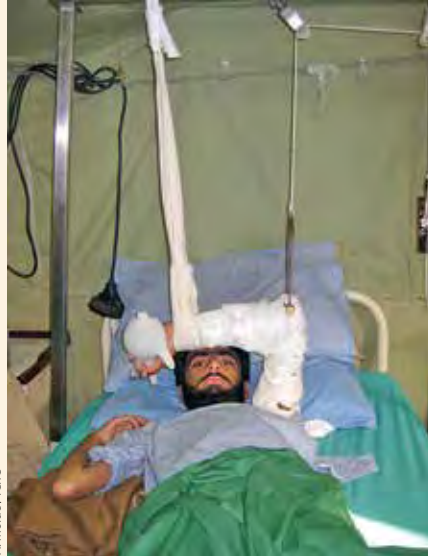

## 22.B.f Skeletal traction of the humerus

Some fractures of the humerus, particularly around the elbow, are difficult to reduce and hold by physiological traction through a cuff-and-collar sling. Skeletal traction is an alternative to external fixation for these patients. A thin Steinmann pin or Kirschner wire is introduced into the olecranon from the medial side, dissecting out the ulnar nerve. Traction weight should begin with 2 kg in an adult and reduction checked twice during the first week by radiography; the weight should be adjusted accordingly.



M. King / Volume 2



A. Modde / CRC

Figures 22.B.30 and 22.B.31

Skeletal traction of a fracture of the humerus.

## 22.B.g Complications of traction

Poor results associated with skeletal traction itself, rather than due to the severity of the original wound, are the result of poor technique and failure of proper supervision or adequate physiotherapy.

### Delayed union and non-union

There is no simple answer regarding when a femoral fracture is "united" and estimations are always approximations. A fracture is usually "sticky" after 4 weeks and clinically united at 7 – 8 weeks. Full radiological union before 10 weeks is unusual. In penetrating injury these timeframes are usually shorter than the ones the surgeon sees in blunt trauma; this is largely due to the difference in the extent of periosteal stripping.

The monthly radiographs usually show progressive callus formation from four weeks onwards; no callus after eight weeks is a bad sign. Undue fracture mobility after eight weeks associated with lack of callus progression on the X-ray, qualifies as delayed union. This is a rare occurrence in projectile fractures of the femur and is usually the result of infection.

If the fracture is "sticky" but not progressing, the patient should be mobilized in a functional brace or cast to provide the stimulus for bone healing.

### Malunion

Fractures of the upper third and lower third of the femur are the most common sites for malunion while under traction treatment. In the proximal third, flexion exerted by the psoas muscle has usually not been overcome, although this is more common with closed fractures than with war wounds. In the case of the lower third, the fracture sags into the traction frame creating a posterior angulation because of the pull from the gastrocnemii; this can be lessened by knee flexion and padding.

Such malunion can be prevented by careful supervision and regular control X-rays. In general, 10° angulation in any direction is acceptable in adults, although it is usually possible to obtain a better result than this. Valgus deformity in the lower limb is more serious than varus because the leg is normally oriented inwards.

**Pin track infection**

Pain around the pin often indicates deep infection; it should be taken seriously. By contrast, inflamed skin around a firm and painless pin is only a superficial infection.

If the pin is *firm* but the skin red, tender and adherent, the pin site should be opened with a knife and forceps to provide for drainage and irrigated daily with a dilute antiseptic solution. The pin must be kept free from the skin. Antibiotics are only necessary if there is a spreading cellulitis.

If the pin is *loose*, the pin track is infected and the pin must be removed. Under anaesthesia in the operating theatre, the pin is taken out and any pus released. The track should be curetted. If there is evidence of a ring sequestrum, indicated by a circle of dense white bone around the pin on the X-ray, the track should be over-drilled and curetted. If dead bone is retained, chronic infection will follow.

Infected pins must be removed.

A new pin should be inserted if traction is to be continued. For the femur, if the tibial tuberosity is lost as a site, a femoral or calcaneal pin is the next best choice. As a last resort a pin can be inserted into the distal tibia, taking care to avoid the lateral malleolus of the fibula and passing behind the tibialis anterior tendon.

**Muscle wasting and bedsores**

As with "plaster disease", lean body mass is lost during the immobility in bed imposed by skeletal traction. Exercises help maintain muscle mass and attention should always be paid to nutrition.

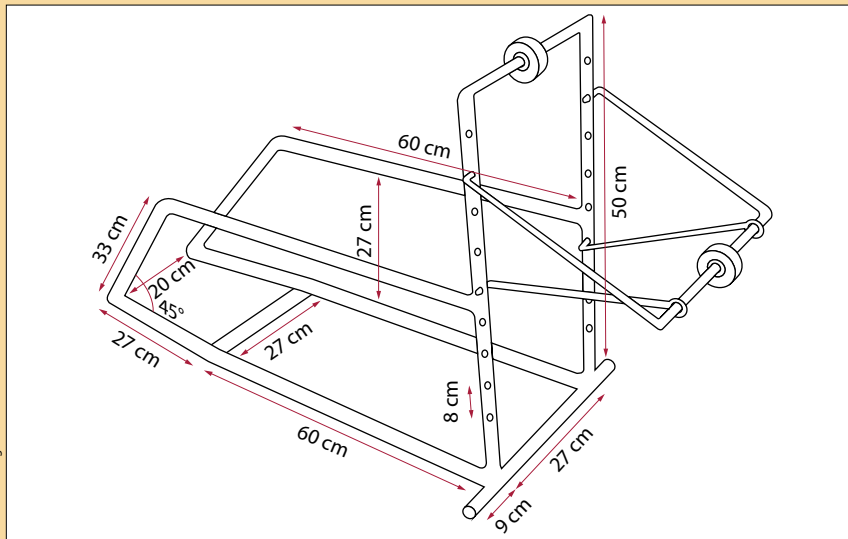
Bedsores are caused by prolonged immobility coupled with shearing forces between bone and the overlying skin and subcutaneous fat, and exacerbated by loss of body mass. The patient must be kept mobile while in bed and taught to raise the body frequently. The development of bedsores indicates the need to change the method of bone immobilization.

**Depression**

Psychological support of the patient is also essential. Many people, especially the young, do not easily tolerate bed confinement for weeks on end.

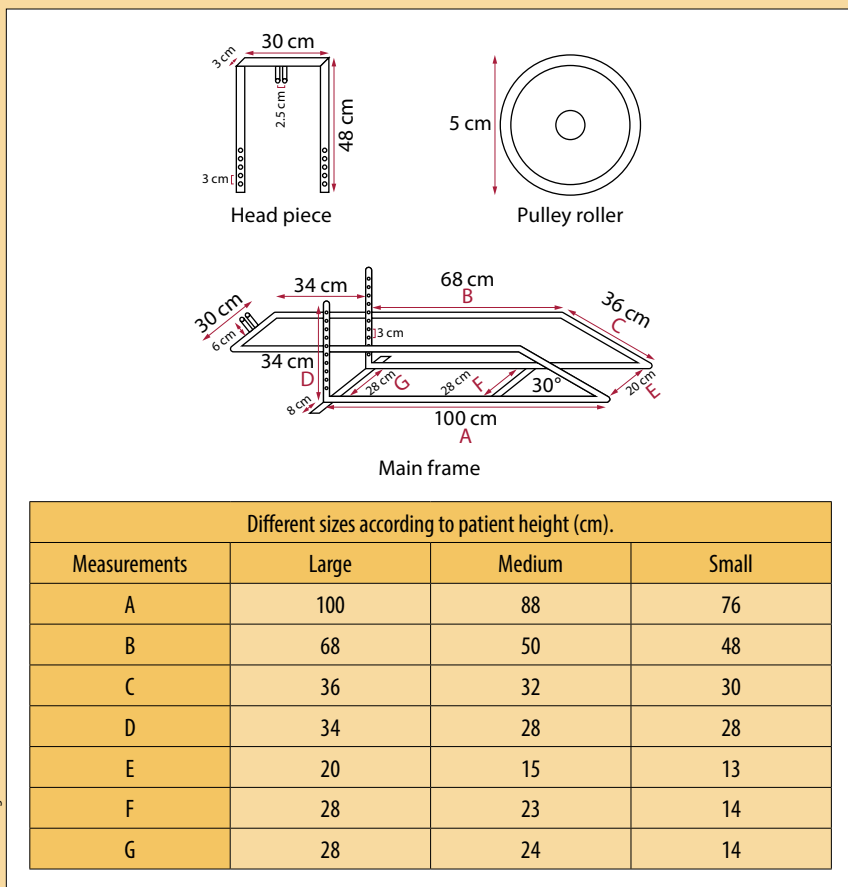
APPENDIX

Two examples of Braun-Böhler frames that can be manufactured locally.



D. Odhiambo Ngota / ICRC

Figure 22.B.32



D. Odhiambo Ngota / ICRC

Figure 22.B.33

## ANNEX 22. C External fixation

The concept of an external fixator is relatively simple and straightforward. Screws or pins are placed into the bone proximal and distal to the fracture site, which are then joined together to create a metallic “exoskeleton” that bridges the fracture and maintains the length and position of the bone.

External fixation is a specialist’s technique, although it is implemented by general surgeons in ICRC practice. The technique requires considerable skill and experience on the part of the surgeon both to make the constructs *and* to follow up the patient. A rather wide range of elements is necessary, although a basic set of instruments can be defined. The best system is one that is easy for the non-specialist to use and includes the smallest number of components.


### 22.C.a Equipment

A number of commercial systems of different sizes are available. Many surgeons have incorporated Steinmann pins in a plaster cast; others have improvised simple systems using wood, bamboo or metal components joined with plaster bandages or bone cement. The easiest system to apply for the non-specialist is one that allows free placing of the pins, the positions not being determined by the frame.

Many other elements exist for the specialist surgeon.

Figures 22.C.1 – 22.C.6

Basic elements of an external fixator set.



T. Gassmann / ICRC

**Figure 22.C.1**  
Schanz screws or Steinmann pins, all commonly referred to as “pins”: either self-drilling (pictured here) or requiring pre-drilling by a smaller-sized bit.



T. Gassmann / ICRC

**Figure 22.C.2**  
External tubes or bars, the length depending on the bone to be held.



T. Gassmann / ICRC

**Figure 22.C.3**  
Pin-to-tube clamps.



T. Gassmann / ICRC

**Figure 22.C.4**  
Tube-to-tube clamps.



T. Gassmann / ICRC

**Figure 22.C.5**  
Instruments needed to place the screws or pins: soft-tissue guard.

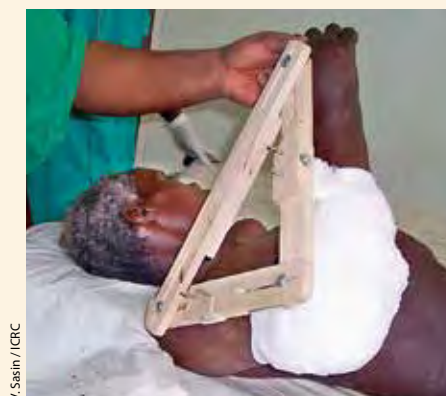

T. Gassmann / ICRC

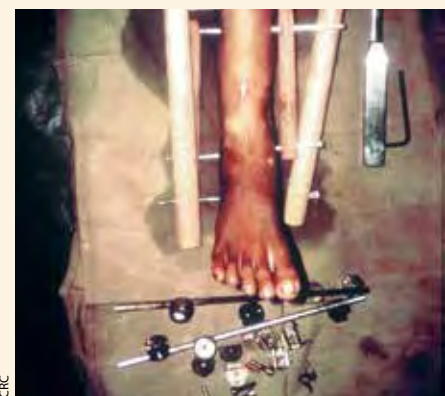**Figure 22.C.6**  
Hand chuck.

Figures 22.C.7 and 22.C.8

Improvised external fixators.



V. Sasin / ICRC



ICRC



## 22.C.b Pin placement and insertion

The wound should be carefully studied beforehand to decide on the sites for placement of the pins in order to obtain both axial and rotational alignment of the fracture. The tibia, humerus and bones of the forearm require at least two pins proximal and two distal to the fracture site; the femur requires three and three.

Pins should be inserted at right angles to the long axis of the bone and should not pierce muscle or tendons. They should not be inserted into the wound itself; if this cannot be avoided, another method of bone immobilization should be chosen.

Pins should not be inserted into the wound itself.

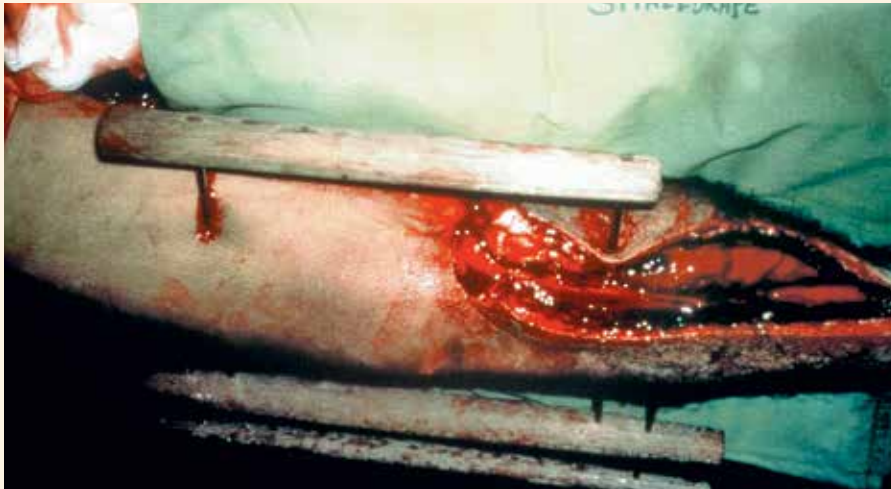

Figure 22.C.9

Incorrect placement of pins using an improvised fixator; the skin is under tension and the pin is going through the wound.

Each pin must traverse both cortices of the bone to ensure the stability of the fixator. However, the distal cortex must only just be perforated; if pins penetrate too far beyond they may cause muscle tethering, damage to nerves, or even injury to an artery.

The placement of external fixation pins follows a similar protocol to that for a traction pin. For each pin the following steps are taken.

1. A 1.5 cm incision is made in the skin parallel to the long axis of the limb.
2. Using a hand drill and a small calibre drill bit, both cortices are drilled through while using a special guard to protect the soft tissues. The depth of the pin hole – thickness of the soft tissues superficial to the bone plus the diameter of the bone – can be measured using a special gauge, thus giving an indication of the length of pin required.

Please note:

A power drill should be avoided, because of the risk of overheating and compression (see 22.B.c).

3. A Schanz screw of a calibre larger than the drill bit is screwed into the bone by T-handle or hand-chuck until the measured depth has been reached.

The surgeon should pay attention to the *resistance* felt as the Schanz screw passes through the bone: initial resistance of the first cortex, yielding as the pin passes through the marrow; and resistance again when the second cortex is reached. Once this second resistance is felt, *three half-turns* of the T-handle are usually sufficient to pierce the second cortex.

Please note:

A self-drilling Schanz screw exists that does not require pre-drilling. The same principles for its insertion apply, except that the pin-hole depth cannot be accurately estimated and the surgeon must pay particular attention to feel the change in resistance when traversing the cortices.

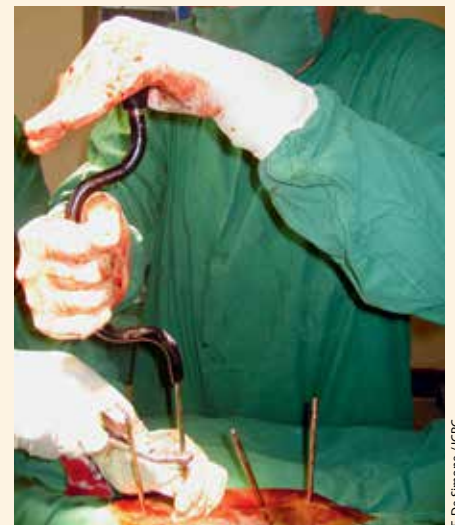

Figure 22.C.10

Placing the pin with a hand drill.

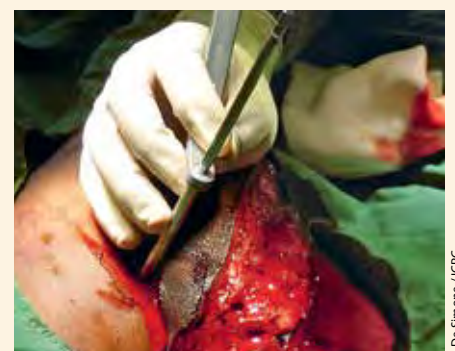

Figure 22.C.11

Using a special guard to protect the soft tissues.

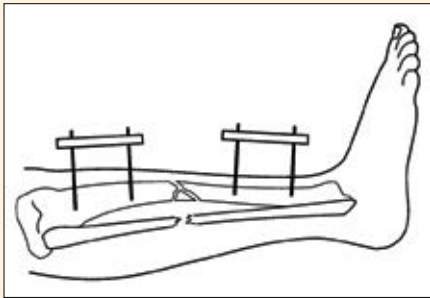
4. The procedure is repeated for each Schanz screw. Any skin tension around the pins must be released by extending the incision.
5. The Schanz screws are joined to side tubes by pin-to-tube clamps. The tube frame should be close to the skin but allow sufficient room for access to the wound.
6. The pin sites are covered with separate gauze compresses. The “dead space” between the skin and tubes is filled with fluffed gauze dressing held in place with an elastic bandage.

**22.C.c Construction of the frame**

Two possible constructs of an external fixation frame are possible depending on the expertise of the surgeon.

**Modular technique**

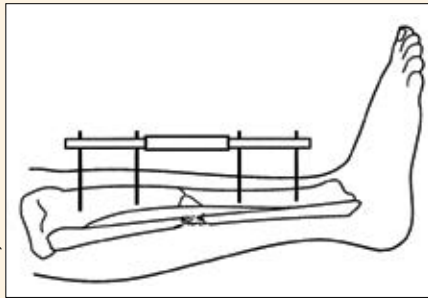
Two pins joined by a tube are placed in each major bone fragment creating two separate modules. The two tubes are then joined by a third cross-tube, loosely held. The two modules are manoeuvred, the tubes serving as handles, to reduce the fracture and the cross-tube tightened in position. A second long tube may be added between at least the most proximal and most distal pins to assure greater rigidity of the device; sometimes three or all four of the pins can be held by the second tube.



D. Rowley / ICRC

**Figure 22.C.12**

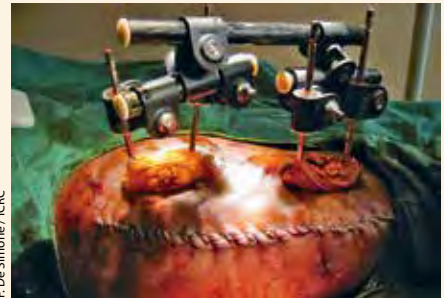Modular technique: two pins are placed in each major fragment and the pins joined with short tubes creating two separate modules.



D. Rowley / ICRC

**Figure 22.C.13 and 22.C.14**

Modular technique: the two modules are manoeuvred into position aligning the bone, both axially and rotationally, and the two short tubes joined together with a cross-tube. A second tube may then be applied to make the device more rigid.



F. De Simone / ICRC

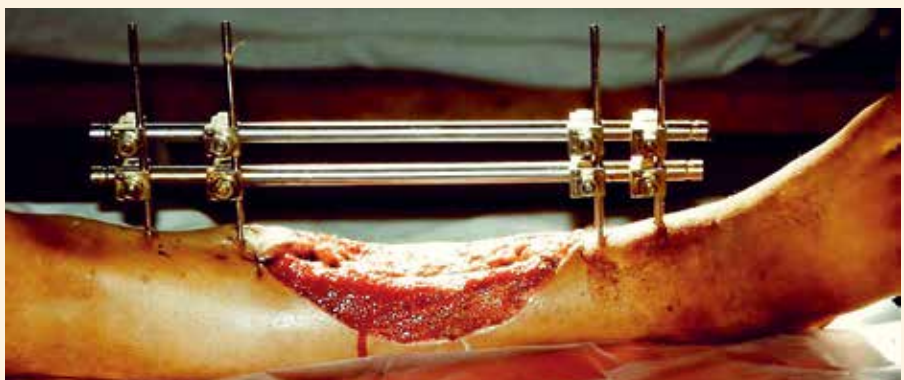
**Mono-axial side-tube method**

The pins are placed well aligned in a row and all the pins held by a single long tube. This method requires experience on the part of the surgeon.

The tube is prepared with four pin-to-tube clamps. The first Schanz screw is inserted into the main bone fragment, 2 – 3 cm from the proximal joint, and then passed through a pin-to-tube clamp. A second screw is similarly placed through a clamp into the second main fragment, also 2 – 3 cm from the distal joint. Slight traction by an assistant will distract the fracture allowing complete manual reduction. The pin-to-tube clamps are tightened to secure the reduction. The axial and rotational alignment of the main bone fragments is checked. The remaining two screws are now inserted through the remaining clamps, one in each fragment. Another pin-to-tube clamp is attached to each screw and a second tube may then be added if required.

**Figure 22.C.15**

Mono-axial side-tube method: the four Schanz screws are well-aligned in a row.



C. Paetzi / ICRC

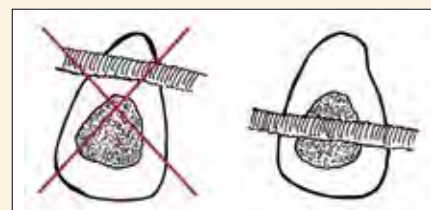
**External fixator applied to the tibia**

Being a subcutaneous bone the tibia is readily accessible and application of a fixator is relatively uncomplicated. At least four pins are required: two above the fracture site and two below. A single pin on one side cannot provide adequate stability; if there is not room for two, a pin may be placed in the tarsus or an alternative method of bone holding should be chosen.

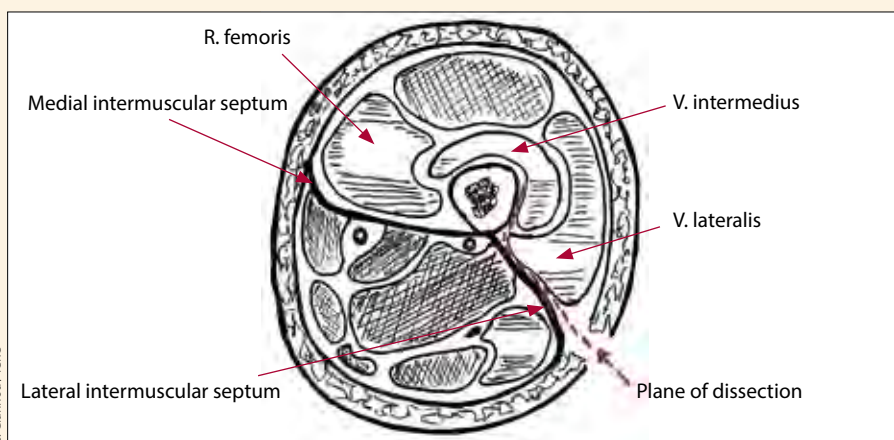
The anterior crest of the tibia is the ideal site for pin placement as there is little soft tissue and the fixator does not catch the other leg during walking. The pin should engage two-thirds of the bone shaft; more superficial placement can lead to the pin tearing out of the bone. The fixator should not be applied from the lateral side through the antero-lateral compartment.

**External fixator applied to the femur**

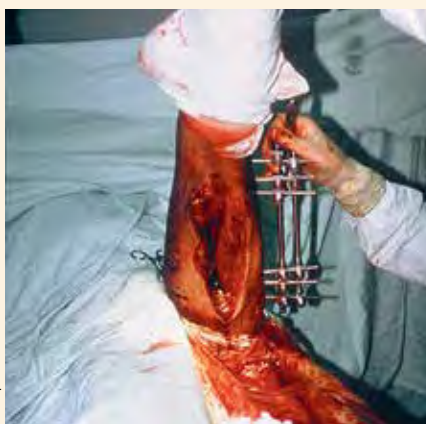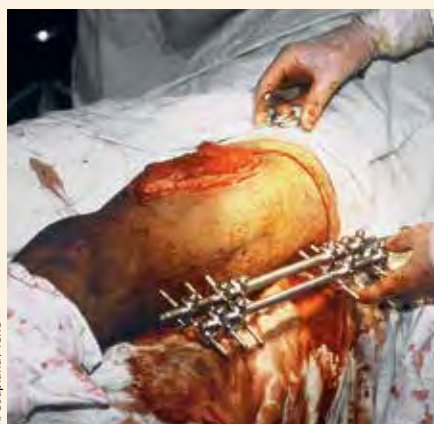The femur is surrounded by a voluminous muscle mass and dissection down to the bone for pin placement is far more difficult than for the tibia. Proper posterolateral placement of the pins is important to avoid tethering any muscles and impeding joint movement. Three pins are required proximal to the fracture site and three distal.



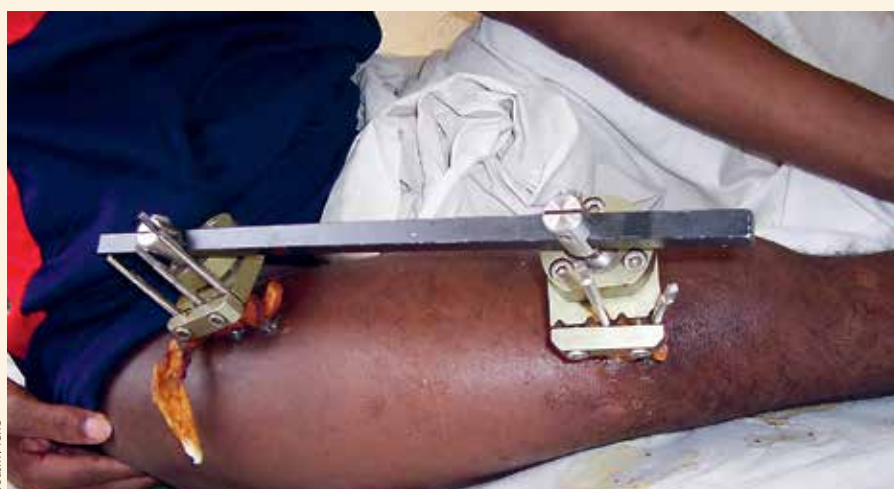**Figure 22.C.16**  
Incorrect and correct engagement of the pin in the anterior crest of the tibia.



**Figure 22.C.17**  
Correct plane of dissection for the placement of pins in the femur.



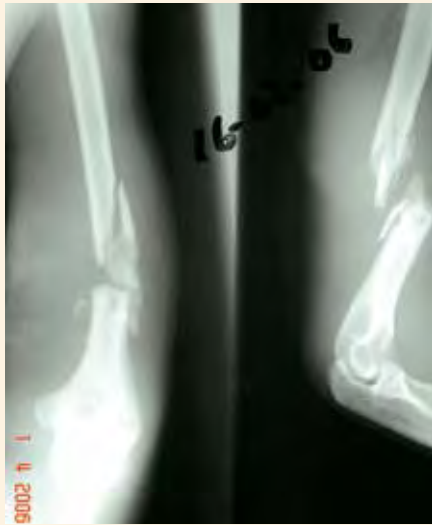**Figures 22.C.18 and 22.C.19**  
Correct pin placement postero-laterally.



**Figure 22.C.20**  
Incorrect pin placement tethering the quadratus femoris muscle.

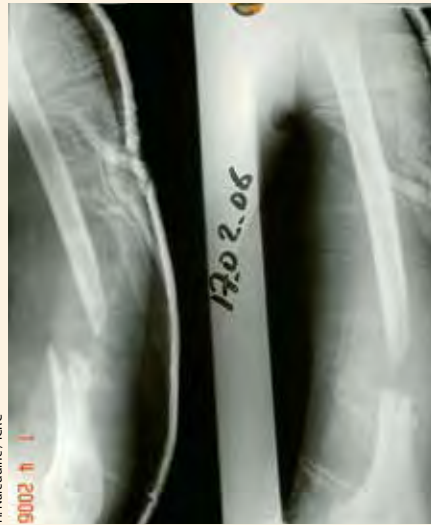**External fixator applied to the humerus**

The humerus is readily accessible in the lateral groove between the biceps and triceps muscles. Two pins are required proximal and two distal to the fracture site. Care must be taken not to injure the radial nerve that passes around the bone or go too far beyond the second medial cortex where the brachial artery lies.



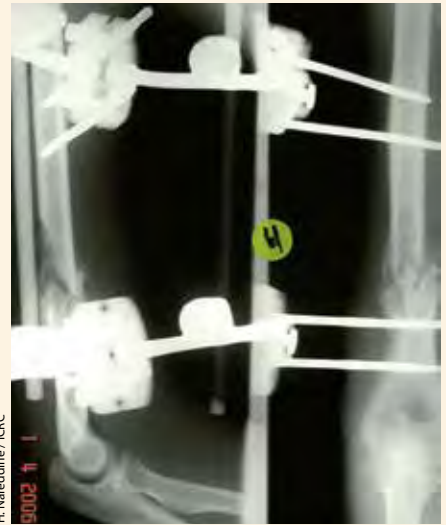H. Naredidine / ICRC  
9002

**Figure 22.C.21**  
Gunshot wound of the humerus: X-ray on admission prior to debridement.



H. Naredidine / ICRC  
9002

**Figure 22.C.22**  
Post-debridement radiograph; the fracture was held in a POP back slab and cuff-and-collar sling.

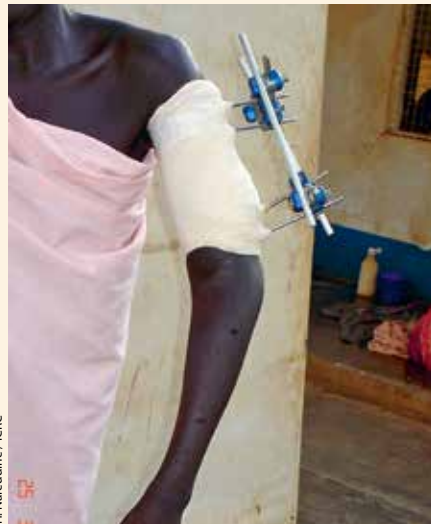

H. Naredidine / ICRC  
9002

**Figure 22.C.23**  
Correction of the alignment by means of external fixation; healing in progress.

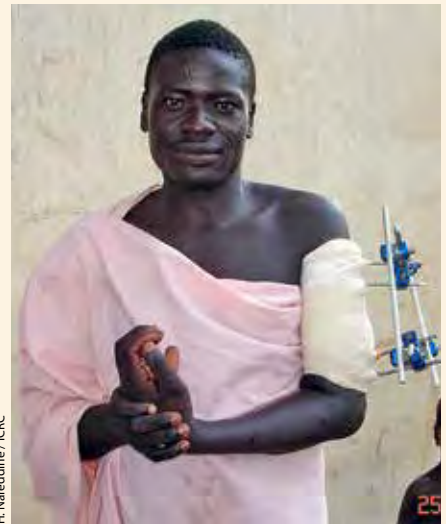**Figures 22.C.24 and 22.C.25**

Application of external fixation to the humerus.



H. Naredidine / ICRC  
9002

**Figure 22.C.24**  
Functional result: extension.



H. Naredidine / ICRC  
9002

**Figure 22.C.25**  
Functional result: flexion.

**22.C.d Management of the patient in external fixation**

After application of an external fixator the limb should be elevated.

A control X-ray is taken as soon as possible to confirm bone alignment. Malunion can be avoided by early adjustment of the construct under light anaesthesia, if necessary. Adhesions around the fracture site and oedema render late adjustment much less effective. Accepting poor alignment defeats much of the purpose of applying an external fixator.

The pin sites should be cared for as described for a traction pin, an essential aspect if the fixator is to be maintained for a lengthy period of time. Mobilization of the joints should start as soon as possible, soft-tissue wound permitting. Weight-bearing is usually painful at first, but should be encouraged nonetheless.

As a general rule, once the soft tissues have healed and the open fracture has converted to a closed one, the fixator can be removed and a POP cylindrical cast applied. This concerns the tibia in particular and usually means removal of the fixator after two to five weeks, depending on the method of soft-tissue closure. Early removal of the pins can be painful and should be carried out in the operating theatre under short general anaesthesia; the pin tracks should be curetted and dressed.

External fixators should be removed and replaced with plaster casts as soon as possible.

### 22.C.e Complications

As with any invasive technique using specialist technology, complications are many. The more serious and frequent are described here.

#### Infection of pin tracks and pin loosening

Most early infections of pin tracks are secondary to residual contamination or infection in the wound itself. Lymphatic drainage from the area of the wound often adversely affects the proximal pins. The other major cause is poor technique of pin insertion leading to damage to the bone and surrounding soft tissue. Meticulous technique and pin site care are essential. Infection leads to loosening of the pin, and is revealed by discharge and pain at the pin site and undue discomfort on weight-bearing. Radiotranslucency around the pin is a late sign. A possible late sequel is pin-induced osteomyelitis and a "ring" sequestrum of the bone around the pin site.

An infected pin site is managed according to whether the pin is firm or loose (see 22.B.g). A loose pin means bone track infection and it should be removed. Under anaesthesia the track should be curetted and a new pin inserted in a new site. Whether pin repositioning is possible depends on the fracture site and the design of the construct; the whole fixator may have to be reapplied. Multiple infected and loose pins call for a different method of immobilization.

Eventually, all pins loosen and become infected as a normal consequence of weight-bearing; another good reason for removing the fixator as soon as possible.

#### Delayed union and non-union

The rigidity of bone immobilization with external fixation has a negative influence on the speed of fracture consolidation.

A potent stimulus for periosteal osteoneogenesis is multi-axial micromovement at the fracture site. Any inhibition of this movement also inhibits callus formation. A special frame to stimulate callus formation must be installed if the fixator is to be left in place for a prolonged period. The frame can be partially destabilized along the axis of the bone ("dynamization") to provide axial compression and micromovement at the fracture site, but places great stress on the bone-pin interface and the pins often become infected and loosened. Dynamization requires much more sophisticated equipment and expertise; again highlighting the importance of early conversion to a weight-bearing plaster cast.

External fixation is most useful in those wounds where non-union is likely anyway because of severe comminution associated with a large bone defect and loss of periosteum. Such fractures usually require a bone graft in any case.

#### Injury to nearby structures

Proper placement of the pins involves a good knowledge of the anatomy of the limb. Proper technique will avoid injury to major nerves and blood vessels. A pseudoaneurysm, presenting late, is one well-known complication.

Tethering of tendons and muscles by the pins prevents joint movement, thus defeating one of the main advantages of external fixation.

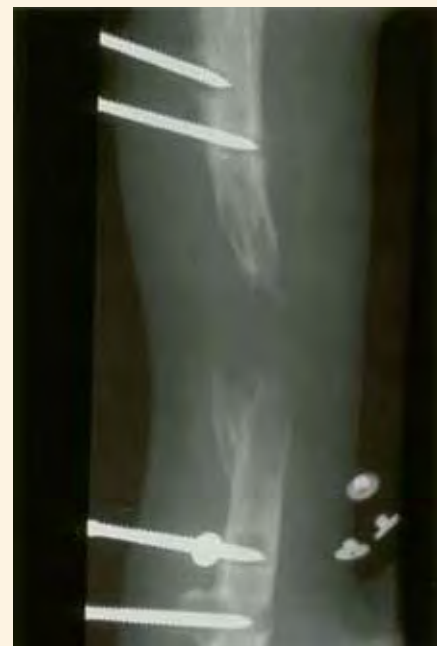

Figure 22.C.26

All four pins are loose as indicated by the bone resorption around them. The periosteal reaction around the lowest pin is most probably associated with infection.

Figure 22.C.27

Correct positioning of the pins and complete flexion of the knees.

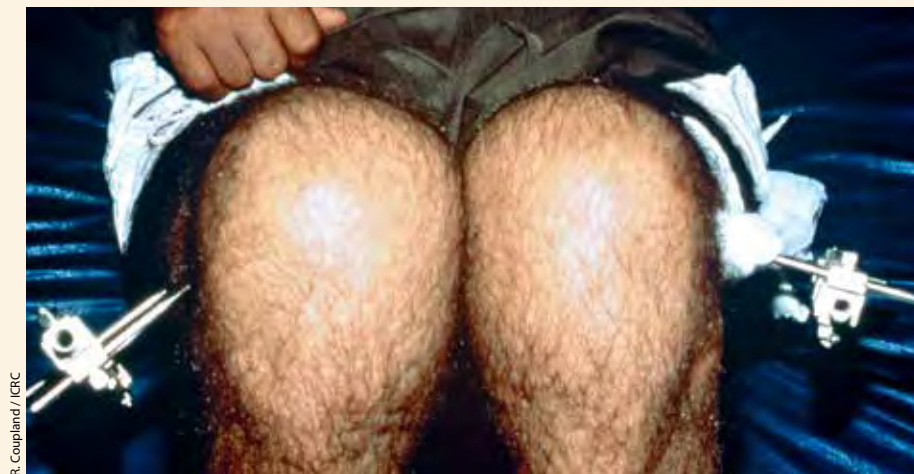

Figure 22.C.28

Incomplete flexion of the knee: incorrect positioning of the Schanz screws.



#### Mechanical problems with the device

As with any apparatus consisting of numerous elements, with time and use some components may no longer function properly. These should be discarded and replaced; often a very expensive exercise.

#### ICRC EXPERIENCE

In the 1980s and early 1990s, there was widespread use of external fixation by ICRC surgeons who spent an average of three months on mission. This rapid rotation did not allow for a correct follow-up, and most surgeons were unaware of the complications that their successors had to deal with. After a clinical study demonstrated the high rate of complications and failure of treatment, the use of external fixation was radically reduced.

In conclusion, external fixation is not an easy option in conditions of war surgery. It should only be used when there is no reasonable alternative.

## ANNEX 22. D ICRC chronic osteomyelitis study

In the province of South Kivu in the Democratic Republic of Congo, after many years of warfare, ICRC delegates noticed the presence of hundreds of patients suffering from chronic osteomyelitis; most of them had old war wounds. The majority had languished for months and years in hospitals or at home, receiving various antibiotic cocktails and dressings; some underwent surgical operations from time to time, whenever they could afford treatment. Neglect and mismanagement were the rule rather than the exception.

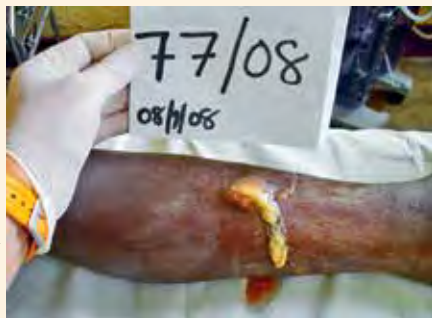Conducting clinical studies in the precarious conditions of an active war zone is difficult and, at times, dangerous, both for the patients and hospital staff. The ICRC surgical department recognizes and admits the many shortcomings in this study and report. Nonetheless, simple means and appropriate technology helped improve the lives of some of the victims of this conflict.

### Material and methods

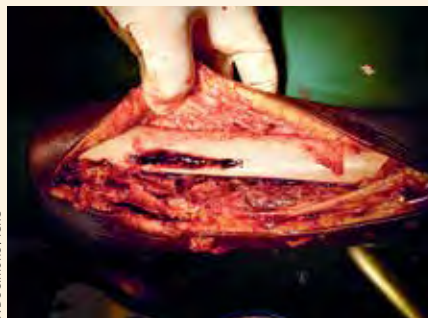Between March 2007 and December 2008, an ICRC surgical team treated 168 patients suffering from either haematogenous or post-traumatic osteomyelitis according to a standard protocol based on a previous ICRC study and publication.<sup>12</sup> Inclusion criteria included symptoms for more than three consecutive months, active purulent discharge or abscess collection in an extremity, and X-ray changes compatible with chronic osteomyelitis (sequestration, cavitation, presence of a foreign body). Patients requiring an amputation as primary or delayed treatment were excluded. Seventy-one patients were available for follow-up.

### Surgical protocol

The aim of surgical debridement was to remove all necrotic bone and saucerization down to bleeding bone ("paprika sign") when required, but not necessarily with a 5 mm margin of healthy bone, in an attempt to minimize bone destabilization. Special attention was paid to removing all biofilm by curettage and irrigation of the wound with saline solution under moderate pressure.



**Figure 22.D.1**  
Pus pouring out of the sinus.



**Figure 22.D.2**  
Sequestrectomy and excision of the sinus.

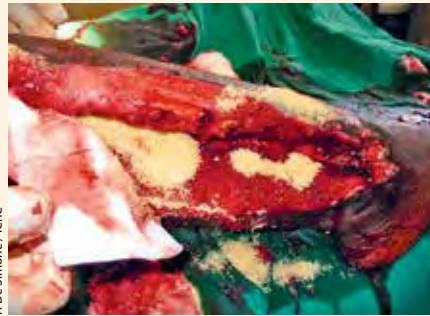Manifest or possible bone instability was managed conservatively by a POP cylindrical cast and joint spanning hinges or a Vega bridge-cast where indicated. External fixation was used only on patients coming back for bone grafting. No internal fixation was employed.

Available healthy muscle tissue was mobilized to cover as much of the exposed bony bed as possible and to fill in any dead space. The wounds were left open and dressed.

12 David I. Rowley. *War Wounds with Fractures: A Guide to Surgical Management*. Geneva: ICRC; 1996.

### Dressing protocol

The operative dressing was removed on post-operative day 2. The wound was dressed using generous amounts of granulated brown sugar and dry compresses. Sugar dressings were repeated on a daily basis after thorough rinsing of the wound with normal saline to remove the previous day's sugar. This routine was continued until the wound healed by secondary intention or a split-thickness skin graft was applied.



F. De Simone / ICRC

**Figure 22.D.3**

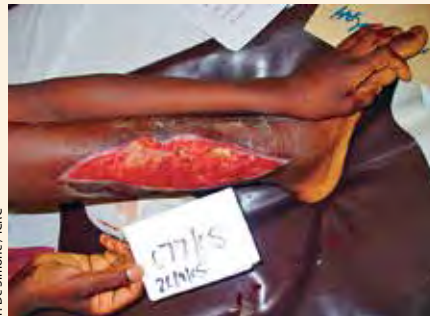Granulated sugar dressing of the wound.



F. De Simone / ICRC

**Figure 22.D.4**

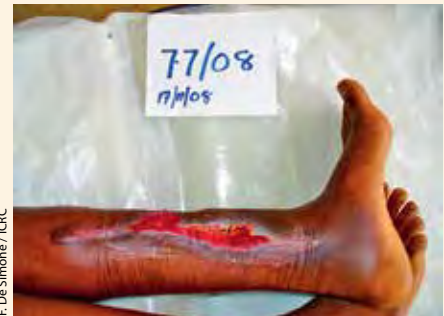Granulated sugar fills the wound.



F. De Simone / ICRC

**Figure 22.D.5**

Healthy granulation tissue.



F. De Simone / ICRC

**Figure 22.D.6**

Healing wound after 8 weeks of sugar dressings.

Most early complications were mild and transient and possibly related to the chemical activity of the sugar: itching or burning sensation around the wound. More rarely, a true contact dermatitis was observed, which always subsided after the sugar treatment was discontinued; or a fungus colonization of the surrounding skin developed and was successfully treated by an antimycotic cream.

### Antibiotic protocol

Intra-operative cultures of superficial and deep tissues and also of sequestra if present were routinely obtained. The initial antibiotic protocol consisted of parenteral gentamycin and cloxacillin for 24 hours, followed by 4 weeks of oral cloxacillin. Culture results showed a high level of multiple-resistance, so the protocol was simplified to a 24-hour course of parenteral benzyl penicillin and metronidazole aimed only at controlling any bacteraemia related to the surgical trauma.

Only patients showing poor progress were given additional antibiotics according to laboratory culture and sensitivity. However, in general, it was found that bacteriological studies were seldom of clinical usefulness. Many bacteria had developed *in vitro* multiple-resistance that had little consequence on clinical results *in vivo*. The duration of treatment was not systematic but based on the clinical response, as was the choice of second-line antibiotics.



**Post-operative care**

Early physiotherapy sessions were established for all patients, to maintain or increase joint mobility and muscle tone and progressively load the affected limb. Patients were fed a calorie- and protein-rich diet, for the first time in months in many cases.

**Follow-up results**

Average length of hospital stay was 12 weeks (range 1 – 48 weeks) and no patient was discharged with active infection. Mean follow-up was 13.7 months (range 5 – 28 months) for the 71 patients who could be traced. Isolated geography and security constraints made follow-up of more patients impossible.

Forty-six patients (63.4%) had excellent to good results in terms of clinical cure of their infection at follow-up. Thirty-six (50.7%) had excellent to good overall results with regard to their pre-treatment disability.

The association between functional outcome and the following variables were found to be statistically significant: age (the younger, the better), aetiology (haematogenous better than penetrating injury), and Cierny-Mader type (A host better than B host).<sup>13</sup> There were no statistically significant associations between clinical cure of the infection and any of the variables.

13 The Cierny-Mader classification of long bone osteomyelitis is based on the anatomy of the bone infection and the physiology of the host. Cierny G, Mader JT, Pennick H. A clinical staging system of adult osteomyelitis. *Contemp Orthop* 1985; **10**: 17 – 37.

## ANNEX 22. E Bone grafting

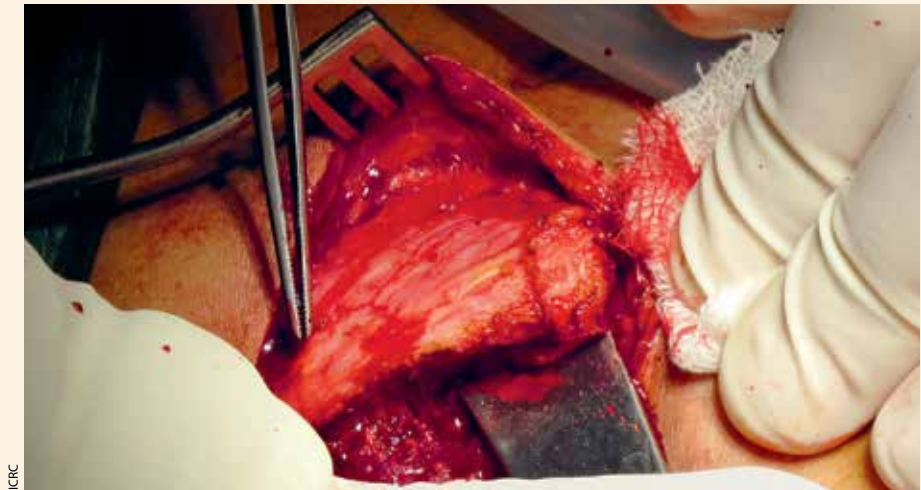
The iliac crest is used as a donor site because a generous amount of cancellous bone can be harvested and it is easily accessible. The exact site depends on how much bone graft is required. For defects smaller than 4 cm, the anterior iliac crest may be used. Where larger quantities are needed the posterior iliac crest is preferred. And, for a very large quantity, both sides of the pelvis can be used. Each cancellous bone chip should be about the size of a fingernail, 1 cm<sup>3</sup>.

### 22.E.a Harvesting the graft

The patient is placed in a lateral or prone position.

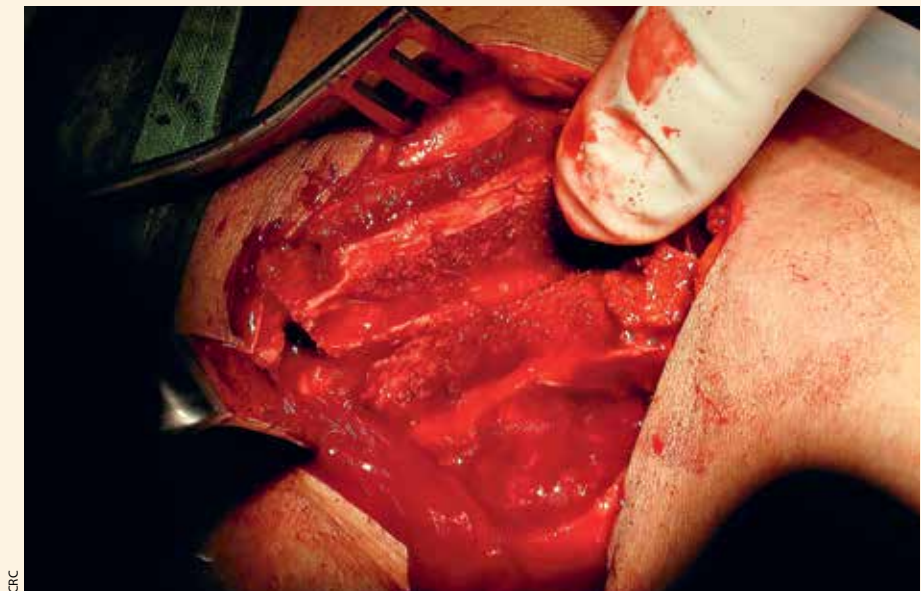
1. For a small graft, the incision goes backwards from the anterior superior iliac spine for 6 – 8 cm. For larger grafts, the incision begins at the posterior iliac spine and proceeds forwards along the crest for 8 - 10 cm.
2. The muscles on the external surface of the crest are cut by knife. With a periosteal elevator, 1 cm of muscle is gently scraped from the bone.
3. A sharp osteotome is inserted parallel to the crest and the outer cortex cut through along the entire length of the incision.

Figure 22.E.1



4. The osteotome is then placed perpendicular to the crest and both outer and inner tables are cut through creating a small flap of cortical bone along the entire length of the exposed crest. Elevating this flap gives access to the cancellous bone and marrow between the two bony tables.

Figure 22.E.2



- Using a narrow bone gouge or osteotome, cancellous bone chips are removed from above downwards. Smaller bits can be harvested with a bone curette. Excessive force should be avoided to prevent breaching the inner table and sacroiliac joint.

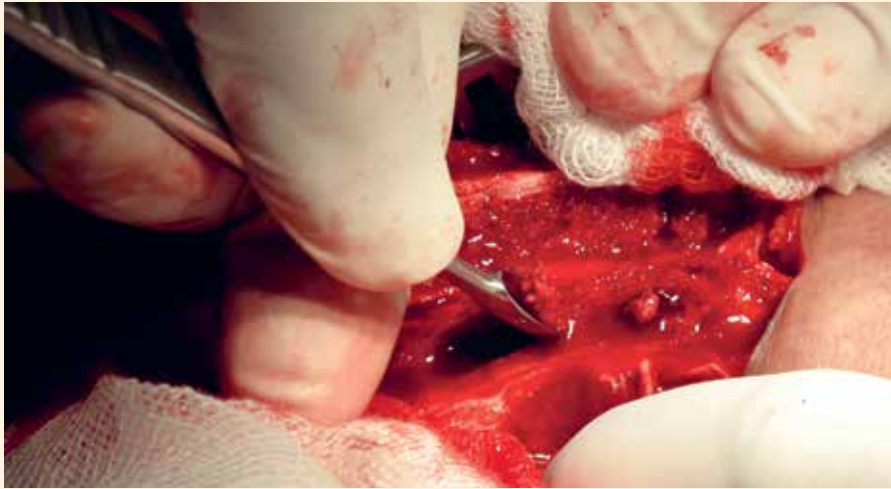
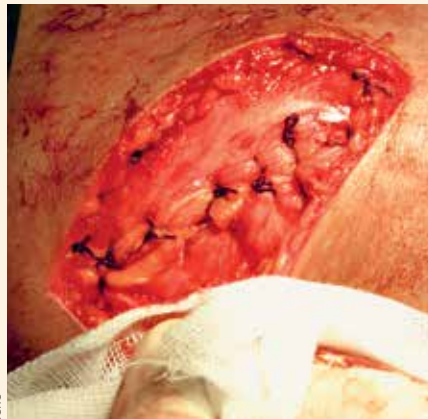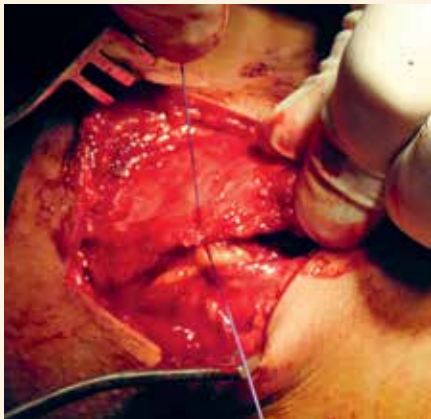


Figure 22.E.3

- The harvested chips are kept in a swab *soaked with blood* and not immersed in saline, which kills bone cells and may remove humoral stimulating factors.
- The wound in the iliac crest is closed by “shutting the flap”: the lid is sutured back to the periosteum with absorbable sutures.



Figures 22.E.4 and 22.E.5

- A drain, preferably of the suction type, is placed in the subcutaneous tissues for 24 hours and the skin incision closed.

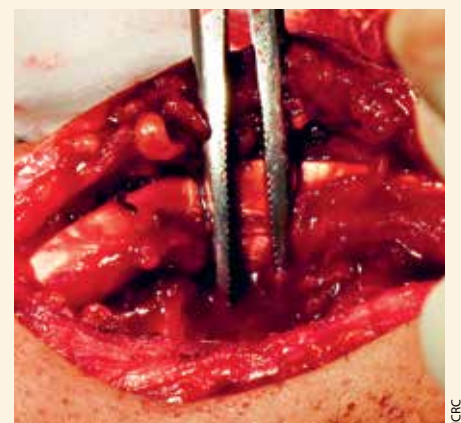These wounds are always painful post-operatively.

### 22.E.b Placing the graft: closed wounds

The patient's position is re-arranged and a pneumatic tourniquet placed on the limb and inflated.

It is preferable to approach the fracture site through a new incision away from the original wound; this carries less chance of infection and avoids the fibrous tissue of wound healing. Once the fracture is exposed, the bone ends are freshened by excision of adherent fibrous tissue and nibbling by a rongeur. Care is taken not to remove periosteum. The bone fragments are aligned and an external fixation device is best placed at this time, if necessary.

The site is then irrigated and the tourniquet released and haemostasis secured. The harvested bone chips are firmly packed in and around the defect. In case of continuous oozing of blood, the wound is closed over a suction drain that should not be left for more than 24 hours. Usually the wound is simply closed without drainage.

Figure 22.E.6  
Placing the graft.

**22.E.c Placing the graft: open wounds**

The same techniques are used for harvesting and applying the graft, but in an open wound. This method is most relevant to grafting the tibia.

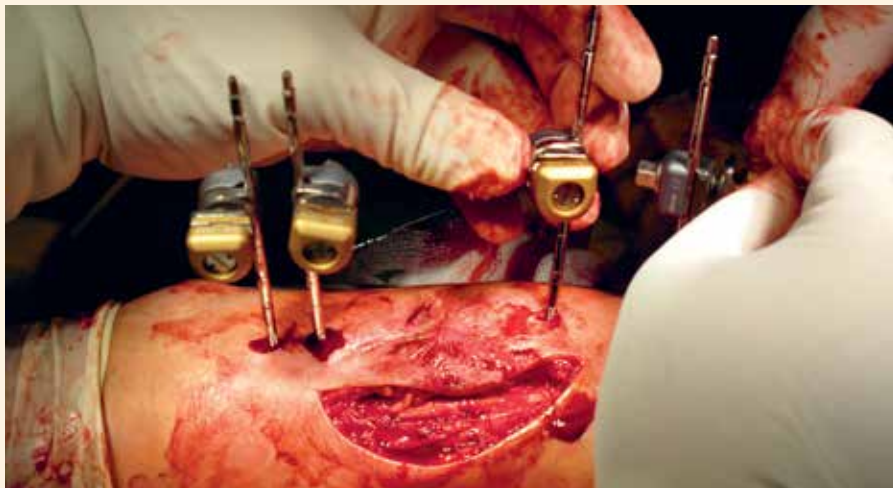
The graft site may be covered by a muscle or skin-and-fascia flap if available, by far the preferred technique. Otherwise the limb is encased in a complete cylindrical cast, *without a window*, and kept away from prying fingers and eyes (Orr-Trueta technique, see Section 22.8.3). Under the cast, the graft site remains moist.

An alternative is the Papineau technique: leaving the wound open and the graft exposed. To be accepted, the graft must be kept clean and moist and regularly cleared of encrustation and any rejected chips. This involves a great deal of very good nursing care and careful wound dressings. As the wound heals, the bone chips are incorporated into the granulation tissue and eventually the surface may close spontaneously by secondary intention or accept a skin graft.

**22.E.d Bone immobilization**

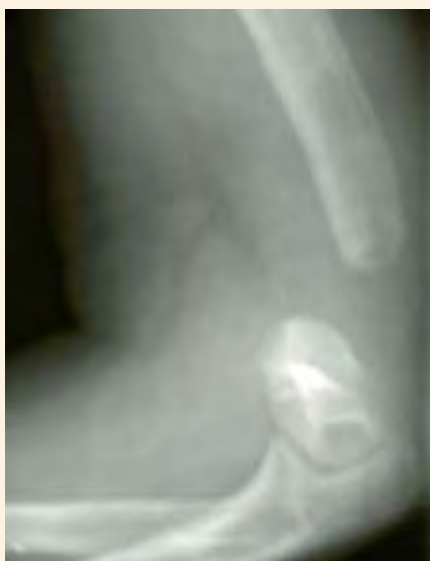Whether an open or a closed technique is used, the grafted fracture must be held by an appropriate method for at least four weeks. This is an important indication for external fixation. Depending on which bone is grafted, the Orr-Trueta method of encasing the limb in a complete cast can also be of benefit.

Figure 22.E.7  
Immobilization using external fixation.

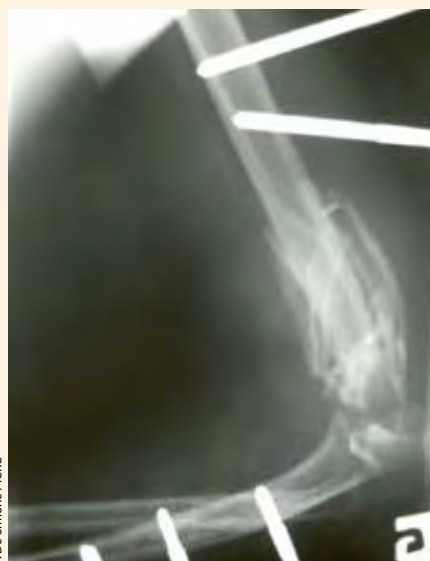

ICRC

Figures 22.E.8 and 22.E.9  
Example of a successful take of bone grafting.



F. De Simone / ICRC



F. De Simone / ICRC





## Chapter 23

# AMPUTATIONS AND DISARTICULATIONS<sup>1</sup>

---

<sup>1</sup> This Chapter should be read in conjunction with the relevant sections of Chapter 21 on anti-personnel landmine injuries. Parts are based on: Coupland RM. *Amputations for War Wounds*. Geneva: ICRC; 1992.

23.	AMPUTATIONS AND DISARTICULATIONS	
23.1	Introduction	173
23.2	Epidemiology	174
23.3	Surgical decision-making	175
23.3.1	Permission to surgically amputate	175
23.3.2	Indications for amputation	175
23.3.3	Clinico-pathological types of “vascular injury and severe tissue damage”	176
23.3.4	Damage-control procedures	176
23.3.5	Level of amputation	176
23.4	Classical surgical procedure: initial operation	177
23.4.1	Preparation of the patient	177
23.4.2	Soft tissues	177
23.4.3	Bone	178
23.4.4	Blood vessels	178
23.4.5	Nerves	179
23.4.6	Haemostasis, irrigation, dressing	179
23.4.7	Post-operative care	179
23.5	Delayed primary closure	180
23.6	Myoplastic amputations	181
23.7	Guillotine amputation	188
23.7.1	Management of an open guillotine stump	188
23.8	Specific amputations and disarticulations	189
23.8.1	Foot amputations	189
23.8.2	Transtibial amputation	190
23.8.3	Knee disarticulation	191
23.8.4	Transfemoral amputation	193
23.8.5	Hip disarticulation and hemipelvectomy	194
23.8.6	Arm amputations	194
23.9	Post-operative care	195
23.10	Patient rehabilitation	195
23.11	Complications and stump revision	197
23.11.1	Painful neuroma	198
23.11.2	Phantom limb sensation and pain	199



## Basic principles

Keep the patient and family informed – obtain consent to amputate.

The soft-tissue injury usually determines the level for amputation or disarticulation.

Debride all dead and contaminated tissue; salvage as much viable tissue as possible.

Leave enough muscle to cover the bone and produce an appropriate stump.

Perform delayed primary closure without tension.

Physiotherapy should begin immediately post-operatively.

Physical rehabilitation and socio-economic reintegration are the ultimate aims of patient treatment.

## 23.1 Introduction

The surgeon must take into consideration a number of factors when deciding whether to amputate and at what level the amputation should be performed. Local rehabilitation services may offer only a small variety of prostheses; limited availability of intensive nursing care may dictate earlier amputation so as to save life; imperfect surgical experience and lack of proper suture material and vascular instruments may make vascular repair ill-advised. In some cultures, amputation will not be accepted at all even if the patient's life is at risk; or not at the appropriate level: the surgeon must "negotiate" centimetres of stump length with family, friends and clan members, or the local military chief.

Surgical judgement is particularly delicate when trying to salvage a severely injured limb; repeated and complicated operations, prolonged hospitalizations, sepsis, and even fatal complications can be the outcome. On the other hand, an amputee is a patient for life; not only must artificial limbs be replaced on a regular basis, but a high percentage of patients develop anatomic complications in the stump and psychological problems that must be dealt with. Furthermore, most amputations during armed conflict affect young and healthy adults in the prime of their productive life. The resulting impairment, especially in a country without the resources to offer efficient physical rehabilitation and produce affordable prostheses, is a burden on the patient, the family and society at large. Physical rehabilitation and socio-economic integration programmes and vocational training are sorely lacking in many low-income countries.

Consultation with a colleague is essential to reach the decision to amputate; a second opinion is invaluable. This can create a dilemma for the lone surgeon working all on his own.

Under the best conditions, not only is the surgeon *not* alone but he works together with a "team" including a physiotherapist, a prosthetist, a prosthetic technician and social worker when dealing with an amputee patient. This team should assist the surgeon, not only in deciding on the optimal hospital amputation policy but also on the optimal type of amputation or disarticulation for each kind of patient. The available technology and skills of the local physical rehabilitation centre are fundamental considerations. Needless to say, these considerations apply to all amputations whatever the cause, and the hospital should have a predetermined "amputation policy". If the nearest centre is in a far distant capital city, then the surgeon must consult the prosthetic team there to establish such a policy.

The surgeon has three aims when performing a primary amputation for war wounds.

1. Excision of all dead and contaminated tissue.
2. Preservation of a stump suitable for the performance of delayed primary closure.
3. Fashioning of a stump appropriate for the fitting and prolonged use of a prosthesis.

An "ideal" stump should meet a number of criteria in order to fulfil the third objective:

- end-bearing, so that little weight is transferred to the prosthetic socket;
- sturdy and well padded with ample muscular soft tissue to distribute the shearing stresses of weight bearing evenly;
- balanced, so that agonist and antagonist muscle groups counteract each other to prevent joint deformity or contracture;
- painless.

Please note:

The DVD that accompanies this manual includes the ICRC film *Anti-personnel Mine Injuries: Surgical Management*. It describes the general principles of amputation for war wounds and for mine injuries in particular.

## 23.2 Epidemiology

The incidence and frequency of amputation for war wounds varies greatly and is dependent on a number of factors.

- Widespread use of anti-personnel mines: numerous patients suffer pattern 1 and pattern 3 injuries.
- Long delay in evacuation of casualties with little or no first aid: patients with projectile wounds often arrive at hospital with a putrid and gangrenous limb.
- Use of modern body armour: the limbs are disproportionately exposed to injury.
- Follow-up period: in certain contexts where limb salvage can be attempted, the incidence of late amputation after failure of reconstructive surgery or because of other complications (chronic infection or pain) can be considerable.

Until the last century amputation was the most common treatment for open fractures in war wounds. In some very austere environments where only very limited medical means are available, this is still the case.

During World War II, US, German and Soviet troops fought on different terrain and under different tactical considerations, with varying capacities for the rapid and efficient evacuation of the wounded to proper hospitals. The causes of all major amputations performed highlight the consequences of these differences.

	Severe trauma	Vascular injury	Gas gangrene and other infections
USA	68.6%	19.5%	11.9%
Germany	64.3%	6%	29.7%
Soviet Union	16%	5%	79%

**Table 23.1 Cause of all major amputations during World War II in different armies.<sup>2</sup>**

The majority of amputations, as with simple wounds, concern the lower limb; transtibial amputations account for about 50% of the total.

<sup>2</sup> Adapted from DeBakey ME, Simeone FA. Battle injuries of the arteries in World War II. *Ann Surg* 1946; **123**: 534 – 579.

## 23.3 Surgical decision-making

### 23.3.1 Permission to surgically amputate

Different societies take differing views of body integrity and the image of the self. Patients may prefer to keep a useless limb or even to die from their wounds rather than suffer amputation. In some cultures the patient alone does not decide on operation. As mentioned, the extended family or clan must be consulted and the amputation, and even the stump length, discussed with them.

### 23.3.2 Indications for amputation

In a number of patients, the pathology and decision are obvious: traumatic amputation. These are more frequent during conflicts where weapons that combine blast and projectile effects, such as anti-personnel mines and sophisticated improvised explosive devices, are widespread.

Other cases call for surgical judgement regarding whether or not to amputate. The following indications are based on the experience of ICRC surgeons and only offer guidance. The surgeon's decision must take into account the actual working circumstances, including availability of blood for transfusion, level of post-operative and physiotherapy care, accessibility of prostheses and physical rehabilitation: in short, the hospital's "amputation policy".

The following are general indications for amputation for war trauma.

1. Severe tissue damage: mangled, grossly contaminated wounds (see Section B.5.1). The great majority of all cases proceeding to amputation concern open fractures of the tibia.
2. Vascular injury: cases with established ischaemic gangrene; unrelieved compartment syndrome with necrosis of the muscles affecting two or more compartments of the limb (see Section 24.5); or vascular injury in addition to severe tissue damage (see Section B.5.1).
3. Multiple injuries: patients with other wounds that are life-threatening and have priority for treatment before any consideration of limb salvage, especially if this involves vascular repair even if temporary shunting is used. Amputation or disarticulation can be considered damage control surgery in these patients.
4. Secondary haemorrhage: patients for whom bleeding is uncontrollable by other measures.
5. Overwhelming infection: pyrexia, toxaemia, anaemia and a putrid, gangrenous limb. However, anaerobic cellulitis or myositis confined to a single muscle group can sometimes be managed by excision and extensive decompression of muscle compartments.
6. Continued chronic infection: a limb that is persistently painful and functionally useless. The wound itself is not life-threatening but repeated attempts at corrective surgery fail and "heroic efforts" may actually cause the patient harm. Some patients even prefer an amputation and prosthesis for a limb that is *painless* and functionally useless.

### 23.3.3 Clinico-pathological types of “vascular injury and severe tissue damage”

The expression “vascular injury in addition to severe tissue damage” above is very general and ambiguous, as is a “mangled, grossly contaminated wound”. All war wounds are contaminated and many can be described as mangled, but not all are candidates for amputation in modern surgery.

The scheme below provides a guideline to aid decision-making, based on a clinico-pathological description of various war wounds using the Red Cross Wound Score. These injuries can all be described as:

- V = H, vascular injury;
- Grade 2 or 3;
- with extensive fracture comminution (F2);
- and bone defect Type C or D.

#### Guidelines for the management of “vascular injury and severe tissue damage”

1. If there is also transection of major nerves, then amputation is advised.
2. Even if the nerves are intact, other life-threatening injuries (V = N, T or A) that rule out proper attention to vascular repair also require amputation.
3. However, if in the presence of other injuries reperfusion of the limb can be readily ensured by temporary shunt and fasciotomy, and immobilization of the fracture easily accomplished, and close observation of the limb is possible over the next 24 – 48 hours, then limb salvage is worth trying.
4. Even if reperfusion can be assured, if soft-tissue loss is so severe that it precludes relatively simple procedures for closure, then the surgeon is probably best advised to proceed to amputation.
5. If revascularization fails or severe sepsis occurs, then amputation is the best course.

### 23.3.4 Damage-control procedures

In patients with multiple severe injuries the setting of correct priorities for the various operations is essential. The precarious physiological state of the patient may require a damage-control approach. This may involve disarticulation through the knee joint rather than a transfemoral amputation; abbreviated laparotomy and washing and dressing only of a traumatic amputation stump after ligation of the major vessels pending proper debridement after stabilization, etc. Again, the ABCDE paradigm of life-threatening injuries should serve as a guide (see Section B.4.1).

### 23.3.5 Level of amputation

Length in an amputation stump is most important in the lower limb: the longer the bone stump, the less effort is required when walking. Energy expenditure and oxygen consumption increase as the level of amputation rises in the limb.

The most severe soft-tissue injury, not the bone injury, usually dictates the level of amputation, which should be at the lowest possible level of viable tissue compatible with good and durable prosthetic fitting. Although the longest stump level is best for the patient’s gait, length should not be gained at the expense of poor stump healing. The best length should be decided in consultation with the prosthetist and physiotherapist.

Moreover, a fracture proximal to the amputation level is not an indication for a more proximal amputation; the fracture should be immobilized and amputation carried out at the level of soft-tissue injury, as would be the case in a fracture of the femur and a transtibial amputation, for example.

### General principles for amputations and disarticulations

- In general, the longer the stump, the better.
- Good muscle coverage of the cut bone end is essential.
- When possible, it is always preferable to preserve a joint.
- Disarticulations create end-bearing stumps and should be preferred to more proximal transosseous amputations, *if* the prosthetic technology is available.
- Disarticulations are much preferred to more proximal amputations in the young, when the growth plates are still open.
- A fracture in a bone proximal to the site requiring an amputation should be fixed with available methods; the amputation should not be performed through the fracture site as an expedient.
- Skin grafts work on stumps that are well-padded with soft tissue: not when placed directly over bone or thin fibrous tissue.

## 23.4 Classical surgical procedure: initial operation

The aim at the initial amputation is to excise all dead and contaminated tissue in preparation for DPC. Some mangled extremities require several debridement-amputations, often because of infection; this is especially the case after APM injury. Two surgical approaches are possible: the classical procedure as described in this Section and myoplastic amputations described in Section 23.6.

### 23.4.1 Preparation of the patient

Ketamine is the preferred anaesthetic. Spinal anaesthesia may be used in a haemodynamically stable patient. *In extremis*, amputations can be performed under infiltration of a local anaesthetic.

The initial amputation should be performed under a tourniquet. However, muscle retracts back in relation to the skin and bone after removal of the tourniquet and this should be kept in mind when deciding on the level of bone section. It should be released prior to the end of the operation for proper haemostasis.

Use a pneumatic tourniquet for surgery.

### 23.4.2 Soft tissues

The surgeon must usually resort to “flaps of opportunity” as determined by the injury rather than standard amputation flaps; no attempt should be made to define formal flaps at the initial operation. This entails excision of all damaged soft tissues first and then planning the bone section as distal as feasible. To allow as much leeway as possible to accomplish DPC and fashion a sturdy and painless stump fit for a prosthesis, the surgeon should save all viable skin and muscle distal to the bone section, however irregular the remaining tissue. Excess bone and soft tissue can always be excised at DPC.

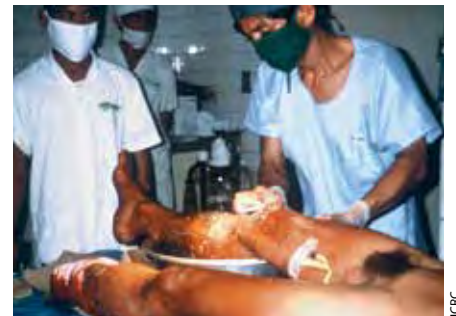
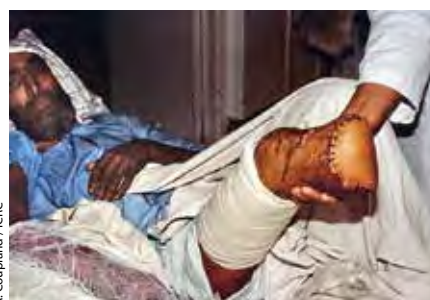
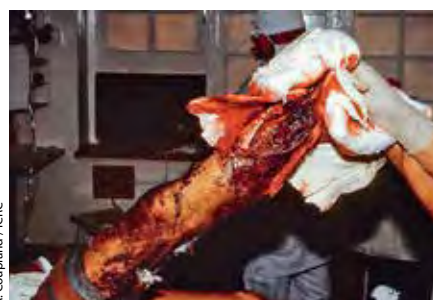Figure 23.1

The limbs are scrubbed with soap and water and a brush.

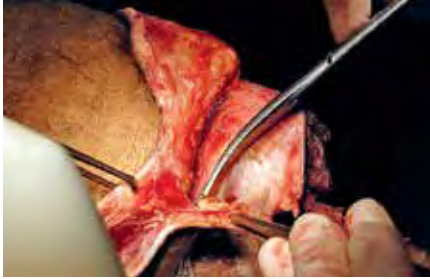

Figures 23.2.1 and 23.2.2

The injury often determines the anatomy of the skin flaps.

Do not attempt to fashion definitive flaps at the first operation.

Salvage as much viable tissue as possible; any excess can be removed at DPC.



H. Nasreddine / ICRC

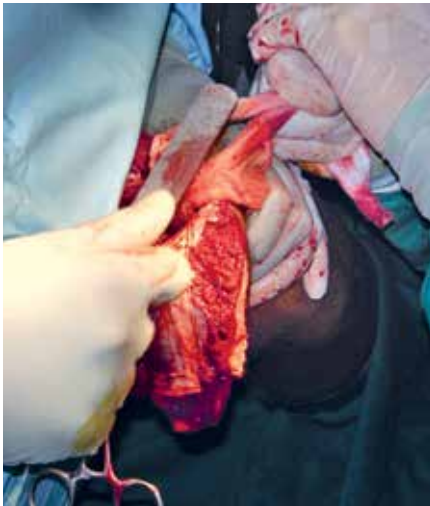
**Figure 23.3**

The skin flap has been raised and excess subcutaneous fat is being trimmed.

The skin flaps are raised and the edges and subcutaneous fat trimmed. Muscles are cut back obliquely across their fibres. If a specific muscle can be retained in its entirety, this is preferable and the muscle should be detached at its distal tendinous insertion.

Please note:

A muscle that is cut *across* its fibres swells considerably during the next few days owing to simple inflammatory oedema. Flaps that approximate at the primary operation may only do so under tension at DPC. Should the soft-tissue wound then break down, it will leave the bone end exposed and require further bone shortening. This swelling does not occur if the muscle is dissected out *intact*; hence the rationale underlying myoplastic flaps (see Section 23.6).



F. Phani / ICRC

**Figure 23.4**

The surgeon is filing down the edge of the cut bone. Note that the muscles have been cut obliquely across the fibres.

**23.4.3 Bone**

Bone section is planned as distal as possible *after* excision of the damaged soft tissues and should be compatible with the remaining quantity of viable muscle to cover the bone end after the 4 – 7 day delay to DPC. At the end of the operation, the skin and muscle should approximate easily, without tension, over the bone end.

Bone is cleared of muscular and fascial attachments and periosteum up to 1 cm proximal to the level of transection. The bone is sectioned preferably with a Gigli saw and the wire cooled by rinsing with normal saline during the procedure. Cutting a thin bone (fibula, radius or ulna) with a bone-cutting forceps or rib cutter tends to splinter the edges and causes proximal spiral fractures. All cut bone ends must be filed down and rounded, leaving no sharp edges or bone spurs. Bone wax must *not* be used as it favours infection in these contaminated wounds. In children, covering the cut end of the bone with a periosteal flap is recommended, to prevent exuberant bone growth.

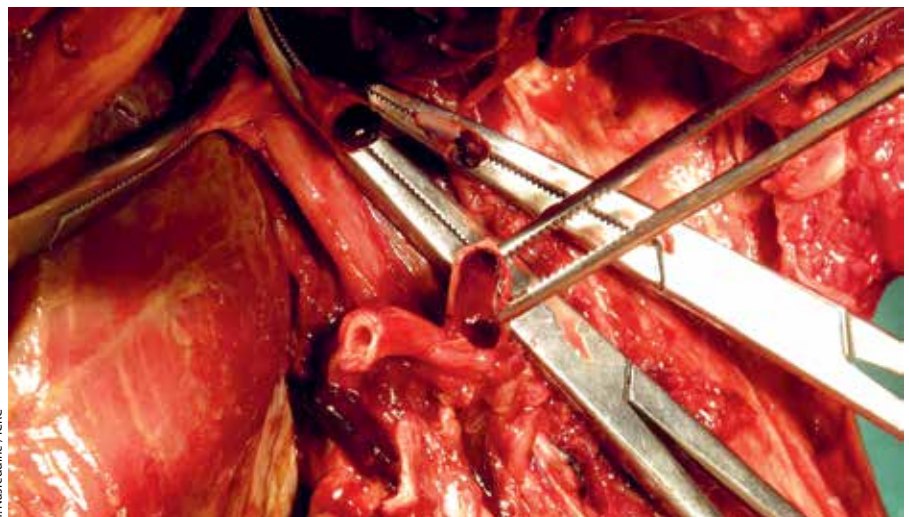
The sharp anterior border of the tibial crest should be bevelled and the fibula cut at least 1 – 2 cm shorter than the tibia. The radius and ulna are divided at the same level, if possible.

**23.4.4 Blood vessels**

Named vessels are transfixed and doubly ligated and the artery and vein ligated separately.

**Figure 23.5**

The major vessels are separated out and ligated individually.



H. Nasreddine / ICRC

### 23.4.5 Nerves

The technique of “traction neurectomy” is applied to all named nerves and to any obviously visible cutaneous nerves. To reduce the risk of a painful neuroma, gentle traction is applied to the nerve, which is divided as high up as possible with a fresh scalpel blade. The end is then buried in a muscle so situated that it is not subjected to pressure from the prosthetic socket.

Nerves should be neither crushed, nor ligated, nor injected; the surgical trauma is more likely to favour the production of a painful neuroma. Neither should an accompanying artery be ligated or cauterized; simple gentle pressure applied with a compress for a few minutes – not rubbing and swabbing – usually suffices to control any bleeding. The exception may be a relatively large vessel accompanying the sciatic nerve in some patients; the artery should be carefully dissected free and ligated at a different level than the section of the nerve.

### 23.4.6 Haemostasis, irrigation, dressing

The tourniquet is removed and haemostasis assured. The wound is irrigated with copious amounts of normal saline or potable water under the simple pressure of squeezing an i.v. bag, or gravity-flow by hanging up the bag. The stump is then dressed as usual with a bulky absorbent dressing to soak up the exudate. Bandaging should be firm, but non-constricting.

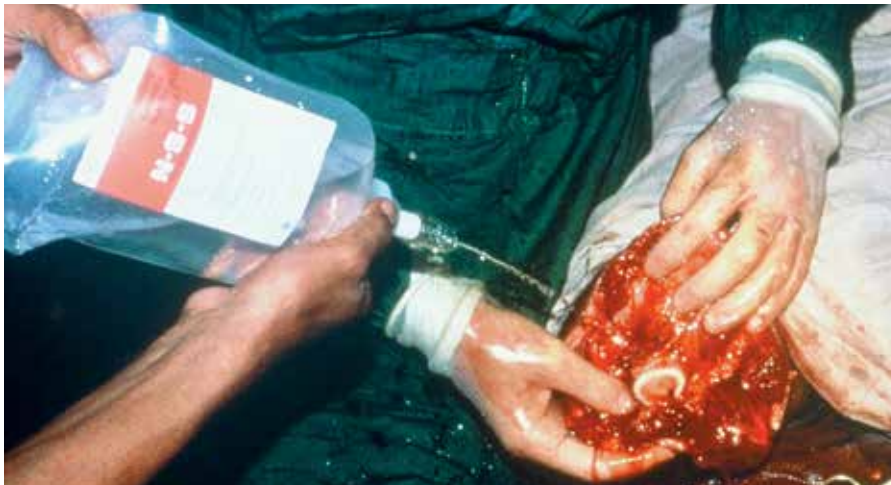

Figure 23.6

Copious irrigation of the amputation stump.

23

It is not advisable to insert a few tension sutures to hold a large compressive tamponade between the flaps to prevent retraction of the skin. This only impedes drainage and promotes strangulation of muscle and skin that will always become oedematous.

The stump should not be closed primarily.

### 23.4.7 Post-operative care

The limb should be kept elevated in bed to reduce oedema and the stump kept in a position to prevent joint contractures (see Section 23.9). Great attention should be paid to post-operative pain and adequate analgesia administered. This helps initiate appropriate physiotherapy to maintain muscle tone and keep remaining joints mobile, which should be commenced immediately, before delayed primary closure.

The original dressing should not be changed until delayed primary closure. If it becomes excessively soaked with exudate or blood, it can either be “over-dressed” with more absorbent cotton and a bandage, or have the outer layers taken down – *without exposing the wound itself* – and a new bulky dressing applied.

However, any signs or symptoms of infection require taking the patient back to theatre for wound revision, not simply a change of dressing on the ward. Amputations due to APM are particularly susceptible to wound infection and multiple debridements.

### 23.5 Delayed primary closure

Attempted DPC takes place on the fifth post-operative day, as per routine. A good amputation wound presents a healthy, bleeding muscle surface that contracts as the last compress is removed.

The aim of DPC is not merely to close the wound but also, and especially, to fashion a suitable stump with a sufficient padding of muscular soft tissue. Although the surgeon may be constrained by whatever soft tissues remain and have to make do with “flaps of opportunity”, long posterior flaps give the best possible stumps.

If good judgement has been used during the initial operation, and infection has been avoided, shortening of the bone will not be necessary. Otherwise, it may have to be sectioned until soft-tissue cover can be assured.

The remaining muscles are approximated and fixed over the cut bone end, using one of several methods. Of these, the simplest and most commonly used procedure is to pull a muscle over the bone end and suture it securely to the periosteum or muscle and fascia on the opposite side. Another method – particularly good for the thigh, upper arm or forearm – is to suture residual muscles to their antagonists over the bone end, thus creating a physiological tension in the stump: *physiological myoplasty*.

The skin flaps are then fashioned, cutting away any excess, and sutured. “Dog ears” and redundant, excess skin should be removed entirely. The fascia may be closed separately with interrupted sutures, to provide a mobile flap of skin over subcutaneous fat at the end of the stump.

Haematoma collection must be avoided. This is best accomplished by meticulous haemostasis and the placing of drains if necessary, suction or simple Penrose, in the intermuscular spaces and subcutaneously. Drains should be removed after 24 – 48 hours.

Skin grafting over the exposed muscle may be necessary if the remaining skin is insufficient or retracts after the initial operation and the bone cannot be shortened without impairing prosthesis fitting. It should never be attempted over bare bone or cartilage. Otherwise, surgical revision of the stump is preferable.



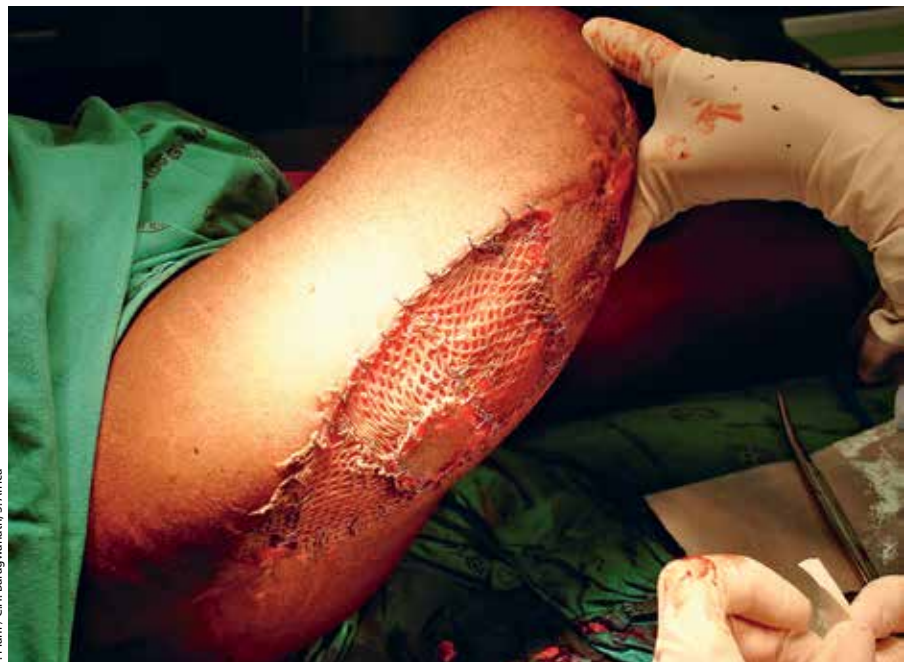R. Coupland / JCR

**Figure 23.7**

Delayed primary closure by suture of an amputation stump.

**Figure 23.8**

Delayed primary closure by skin grafting of an amputation stump.



F. Plati / C.H. Baragwanath, S. Africa



### Basic principles of amputation technique

- Operate under a tourniquet.
- Salvage all viable soft tissue at the initial amputation.
- Raise the skin flaps separately.
- Clear muscular and fascial attachments up to 1 cm proximal to bone section.
- Cut all bones with a Gigli wire saw, not with bone-cutting forceps.
- File smooth cut bone ends.
- Do not use bone wax.
- Suture-ligate all major vessels; arteries and veins separately.
- Transect major nerves under gentle traction with a sharp new blade.
- Do not ligate or cauterize vessels accompanying major nerves.
- Always perform delayed primary closure.
- Drains should be placed during DPC only if necessary and removed within 24 – 48 hours.
- Physiotherapy should begin as soon as possible, even before DPC.
- The limb should be positioned so as to prevent joint contractures.

## 23.6 Myoplastic amputations

As mentioned, muscle that has been cut across its fibres swells greatly before DPC. This is especially the case in young men with bulky muscle groups. An intact muscle belly is relatively unaffected by oedema and swells little, if at all; it is soft and pliable and readily holds sutures. The muscle is dissected out in its entirety and the distal tendinous insertion cut. If mobilized along with its fascio-cutaneous covering, the result is a myoepithelial flap. The flap is pulled over the cut bone end at DPC and fixed in place.

Three common myoplastic amputations use the following muscles:

- soleus (Figures 23.9.1 – 23.9.9)
- medial gastrocnemius (Figures 23.10.1 – 23.10.11)
- vastus medialis (Figures 23.11.1 – 23.11.9).

They are particularly well-suited to the “umbrella effect” of APM traumatic amputations (see Sections 21.5 and 21.7.4) and are recommended by ICRC surgeons in any weapon-related amputation.

Figures 23.9.1 – 23.9.9

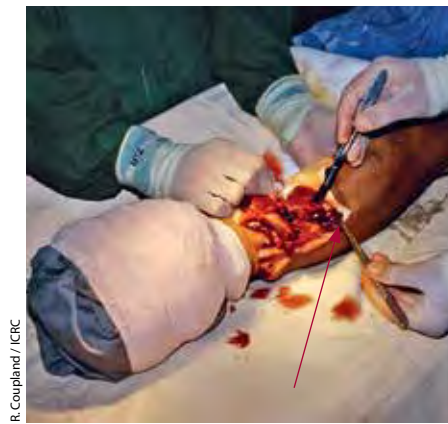Soleus myoplastic amputation.



R. Coupland / ICRC

**Figure 23.9.1**

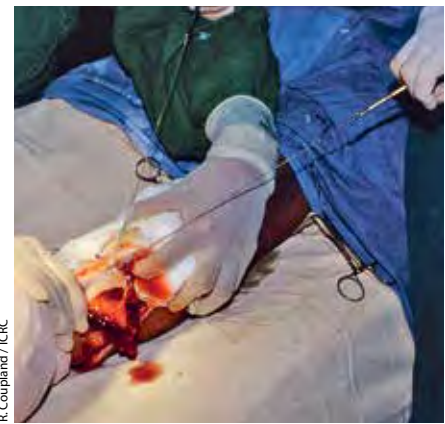A patient with traumatic amputation of the left foot by APM. There appeared to be little damage to the rest of the leg.



R. Coupland / ICRC

**Figure 23.9.2**

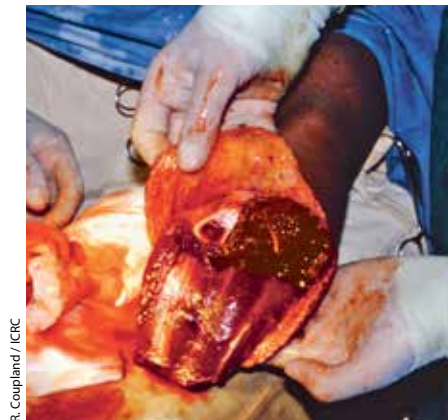Equal anterior and posterior skin flaps have been raised. The muscles of the anterolateral compartment were contused (the dark muscle held in the forceps). The muscle section was made proximal to this.



R. Coupland / ICRC

**Figure 23.9.3**

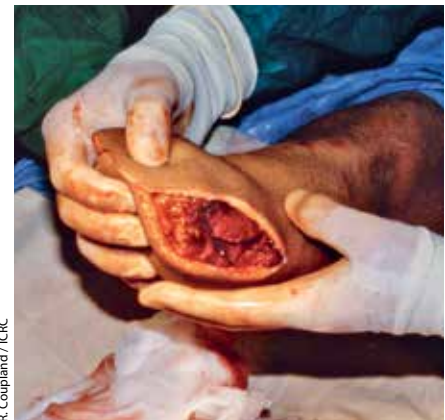The tibia section in process, a little below the level of muscle section. Note the cutting angle of the Gigli wire saw to produce beveling of the anterior edge, which was then filed smooth. The fibula was cut 2 cm shorter, again with a wire saw.



R. Coupland / ICRC

**Figure 23.9.4**

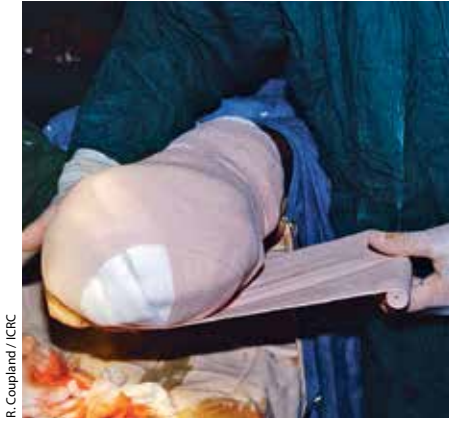The amputation at the end of primary surgery. The intact soleus was the only muscle remaining distal to the tibial section.



R. Coupland / ICRC

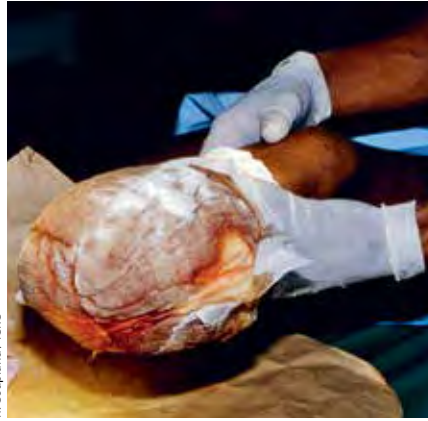**Figure 23.9.5**

The soft tissues approximated easily at the end of initial surgery, but were not sutured closed.



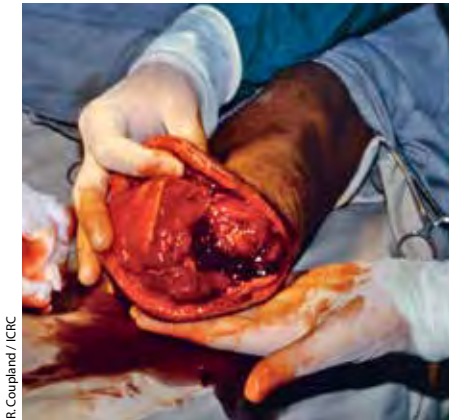
R. Coupland / ICRC

**Figure 23.9.6**  
A bulky gauze and cotton wool dressing was applied.



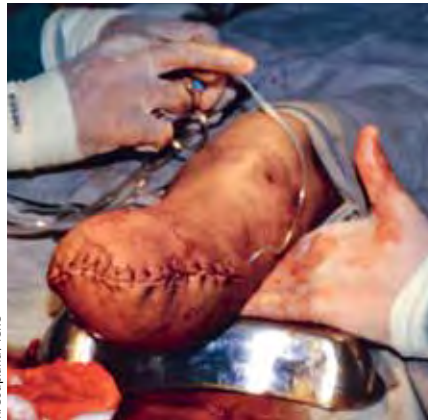R. Coupland / ICRC

**Figure 23.9.7**  
The original operative dressing during removal showing the gauze with dried exudative serum.



R. Coupland / ICRC

**Figure 23.9.8**  
The stump was clean and ready for DPC and the soleus myoplasty was sutured to the periosteum of the anterior tibial edge.

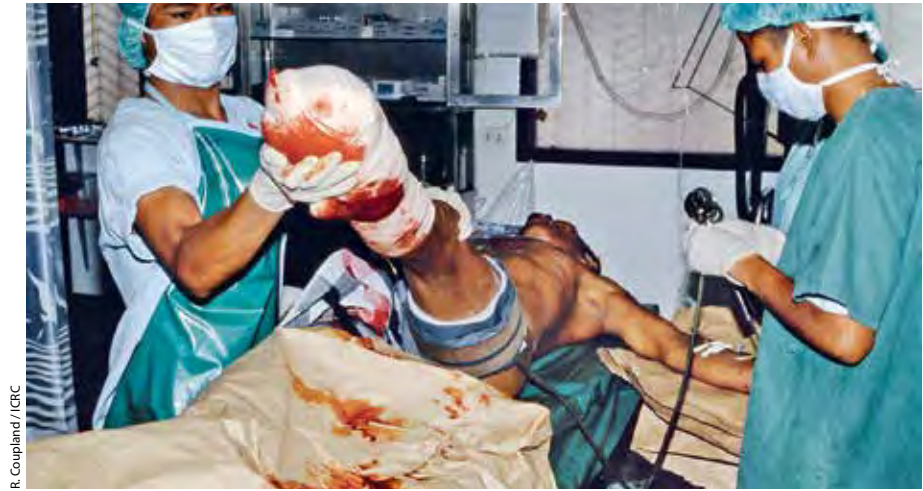

R. Coupland / ICRC

**Figure 23.9.9**  
The skin flaps were closed independently. A bulky dry dressing was applied over the closed stump. The sutures were removed after 12 days.

Figures 23.10.1 – 23.10.11

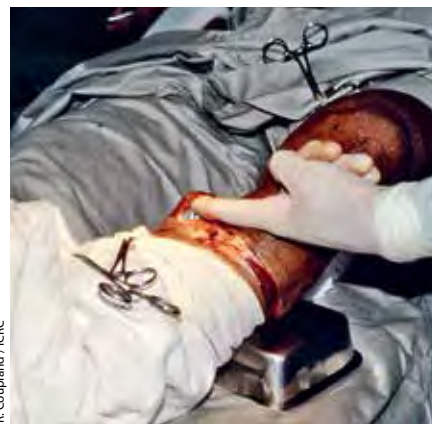Medial gastrocnemius myoplastic amputation.



R. Coupland / ICRC

Figure 23.10.1

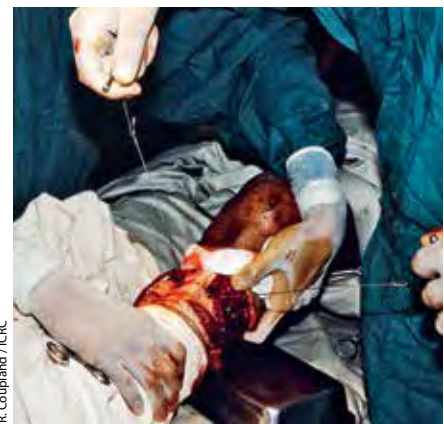A patient with an APM traumatic amputation of the left leg.



R. Coupland / ICRC

Figure 23.10.2

The medial gastrocnemius was intact and undamaged (indicated by the surgeon's left index finger bluntly dissecting the muscle free). The soleus and muscles of the anterolateral compartment were contused.



R. Coupland / ICRC

Figure 23.10.3

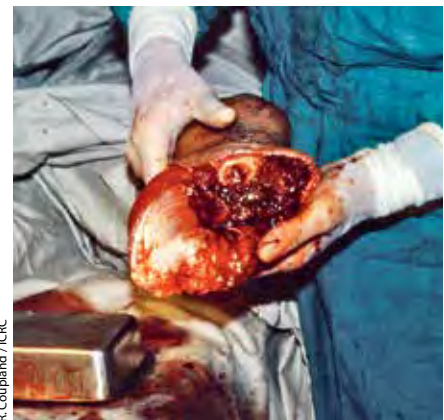The tibia and fibula were sectioned by Gigli wire saw, bevelled and filed smooth.



R. Coupland / ICRC

Figure 23.10.4

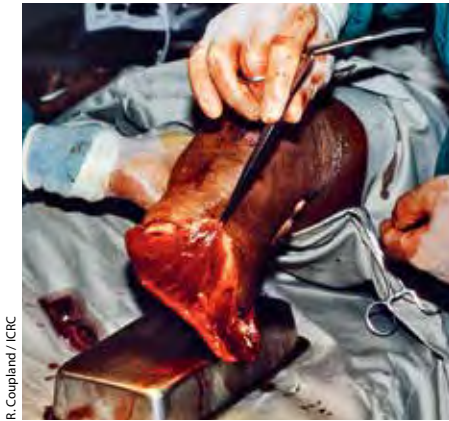The soleus and anterolateral muscles were divided just above the level of the bone section and separated from the intact medial gastrocnemius.



R. Coupland / ICRC

Figure 23.10.5

The medial gastrocnemius has been sectioned at the Achilles tendon and the remainder of the limb removed.



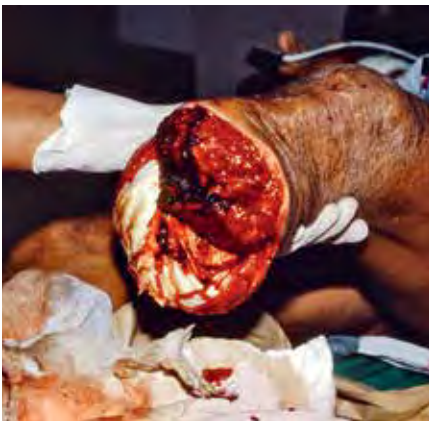R. Coupland / ICRC

**Figure 23.10.6**  
The belly of the gastrocnemius easily covered the end of the tibia.



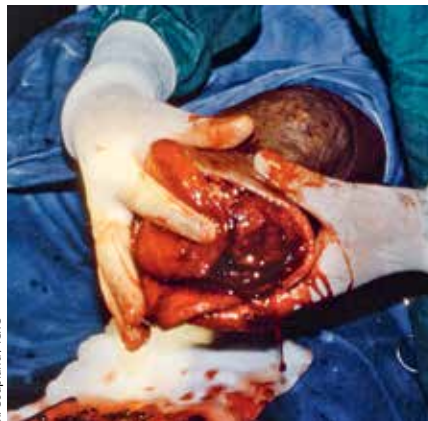R. Coupland / ICRC

**Figure 23.10.7**  
At DPC the gauze dressing adhered to the fibrin coagulum on the surface of the muscle, which contracted and bled.



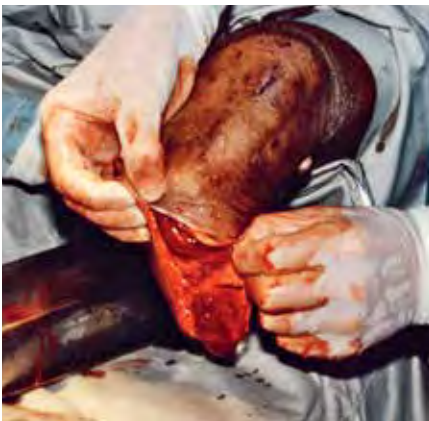R. Coupland / ICRC

**Figure 23.10.8**  
The transected muscles have swollen, yet the intact gastrocnemius belly has swollen much less.



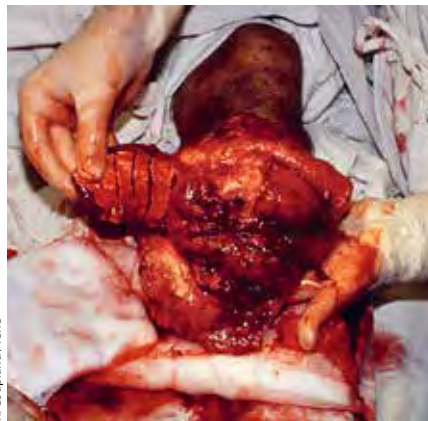R. Coupland / ICRC

**Figure 23.10.9**  
The gastrocnemius myoplasty easily covered the tibial section from medial to lateral. It was sutured to the anterolateral periosteum.



R. Coupland / ICRC

**Figure 23.10.10**  
The skin flap readily covered the myoplasty.

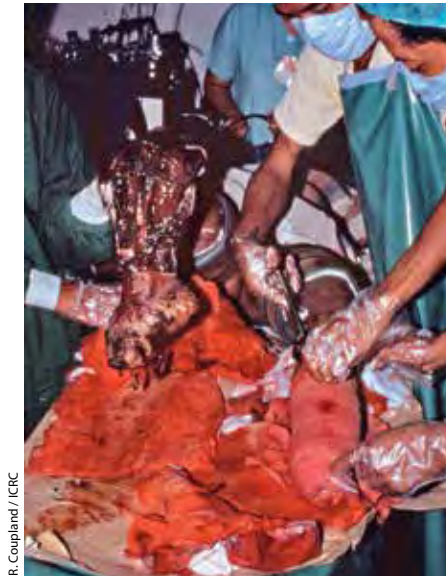

R. Coupland / ICRC

**Figure 23.10.11**  
The fascial undersurface of the muscle may be scored if necessary to allow for its elongation and to release any tension.

Figures 23.11.1 – 23.11.9

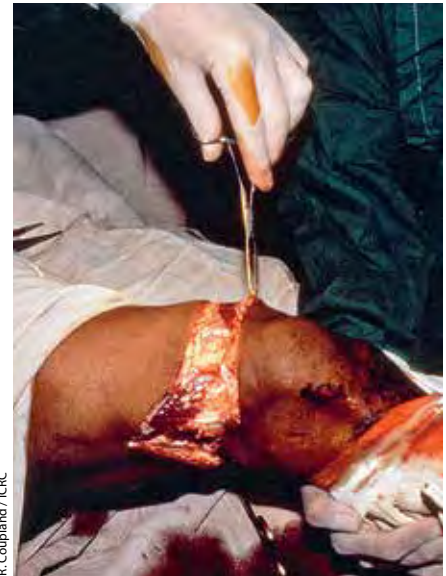Vastus medialis myoplastic amputation.



R. Coupland / ICRC

**Figure 23.11.1**

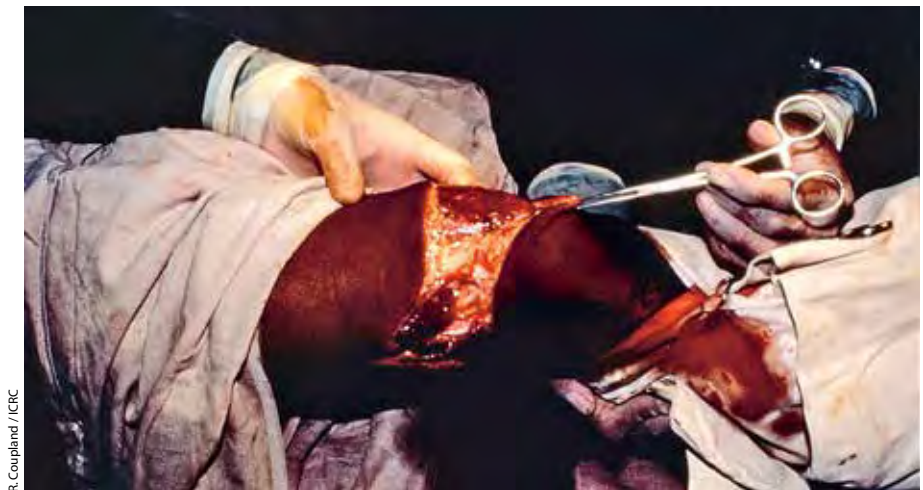A patient with traumatic amputation of the left leg (field dressing) and a mangled right limb from an APM explosion.



R. Coupland / ICRC

**Figure 23.11.2**

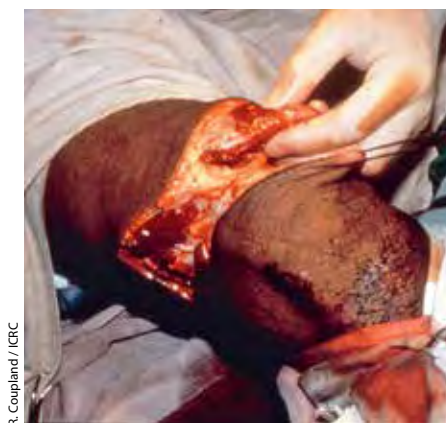Damage to the mangled limb was so severe that an above-knee amputation was decided in addition to the amputation of the left leg. Standard equal "fish-mouth" skin incisions were made commencing at the upper border of the patella. Care was taken not to extend the incision into the vastus medialis muscle.



R. Coupland / ICRC

**Figure 23.11.3**

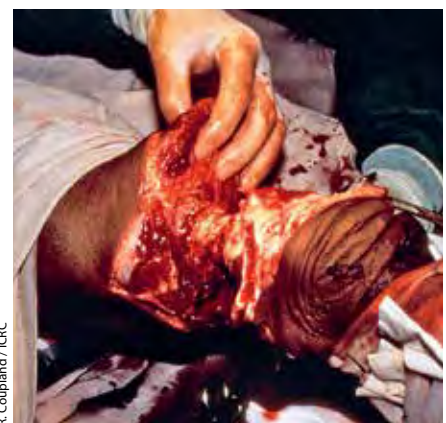Dissection reveals the round belly of the vastus medialis.



R. Coupland / ICRC

**Figure 23.11.4**

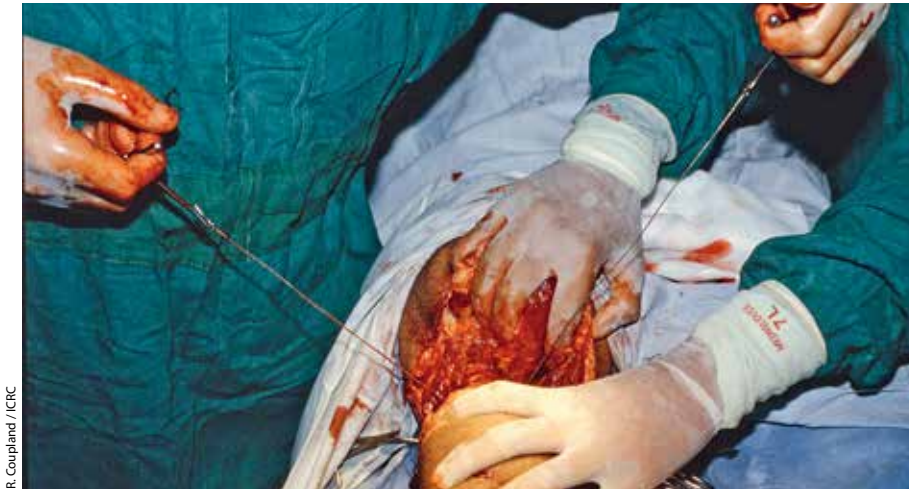The V. medialis was separated from its insertion into the quadriceps tendon by reflecting down the distal skin. The surgeon's left index finger is shown here deep to this muscle.



R. Coupland / ICRC

**Figure 23.11.5**

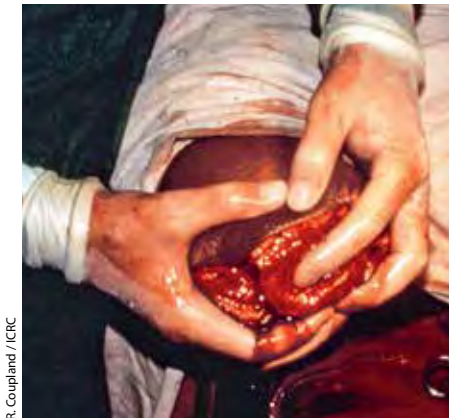The intact V. medialis has been reflected up, the other muscles having been cut slightly below the proposed level of bone section.



**Figure 23.11.6**

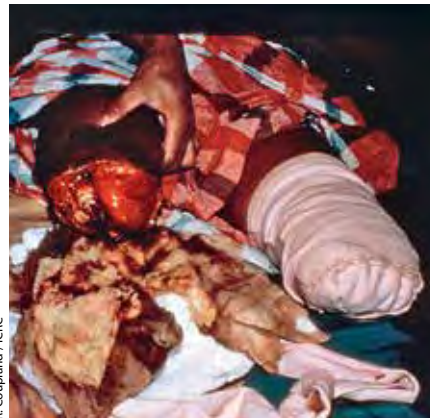The femur was sectioned by Gigli wire saw where the shaft begins to flare into the condyles, while the assistant kept the soft tissues clear of the saw.

The femoral vessels were clamped and transected individually and the sciatic nerve gently pulled and cut with a fresh blade. The intercompartmental fat around the sciatic nerve and vessels was excised because it contained contaminants.



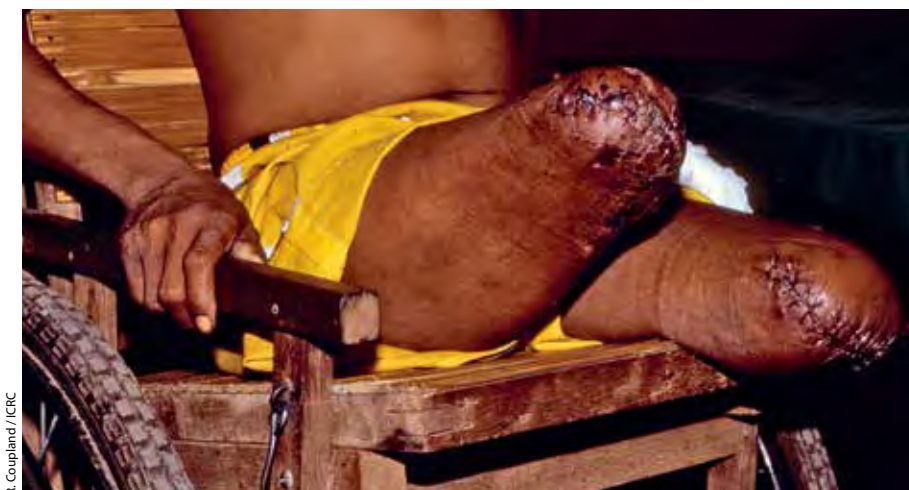**Figure 23.11.7**

The tourniquet was released and haemostasis achieved. The intact V. medialis easily covered the bone section. The open stump was irrigated with saline and dressed.



**Figure 23.11.8**

The patient returned to theatre after five days for DPC. Some exudate had reached the dressing surface but was dry by this time. The stump was clean and ready for closure.



**Figure 23.11.9**

The vastus medialis myoplasty was sutured to the lateral thigh muscles and fascia in both limbs. It could also have been sutured to the periosteum. The skin flaps were sutured closed. The dressings were changed after six days and the skin sutures removed after 12 days.

## 23.7 Guillotine amputation

Guillotine amputation is only indicated as a last resort and in extreme situations such as emergency extraction of a victim under rubble or in a vehicle wreck. In a critically ill patient, a disarticulation is preferable as a more rapid and less bloody damage-control procedure.

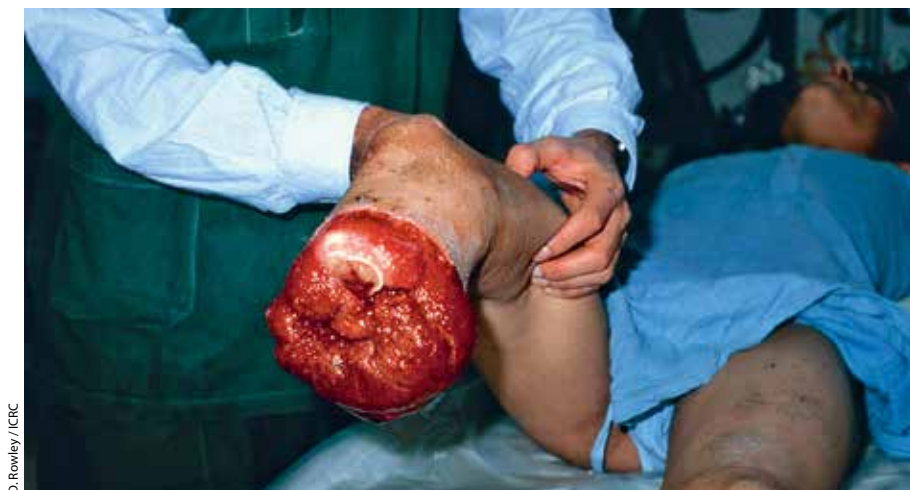Guillotine amputation should not be performed as a routine operation.

The skin, fascia and muscle are cut in one fell swoop: "*coup de maître*"; the old-fashioned amputation knife was used for this purpose. The bone is cut at a slightly higher level, vessels and nerves dealt with as usual but at the same level.

If performed too low, the guillotine amputation may miss dead muscle; if too high, it usually results in an amputation that is more proximal than necessary. Retraction of the blood vessels makes control of bleeding more difficult. In addition, wound closure is rendered more complicated because of retraction of the skin, particularly if amputation takes place through a muscular mid-calf or mid-thigh. The resultant significant oedematous swelling of the muscles always requires revision of the stump after healing in order to fit a prosthesis. This procedure is to be avoided as much as possible.

Figure 23.12

Oedematous guillotine amputation stump.



D. Rowley / ICRG

### 23.7.1 Management of an open guillotine stump

If, for whatever reason, the surgeon is faced with an open guillotine stump, further management will depend on timing and the state of the wound.

1. If received within 48 hours, a clean stump should be re-amputated at the correct level, salvaging all viable soft tissue. The stump is left open, and DPC performed 5 days later.
2. If later than 48 hours and still clean, the stump should be left as it is. Dressings are performed every 2 – 3 days and the limb kept elevated. The patient will require secondary amputation after 2 weeks, once inflammatory oedema has subsided. Again, the stump is left open and DPC performed another 5 days later.
3. If the guillotine amputation stump is infected, the patient should undergo re-debridement of the wound to remove the remaining necrotic tissue. This may have to be repeated several times. The wound is left open, and delayed primary closure performed when clean.



## 23.8 Specific amputations and disarticulations

For the technical operative details of different amputation levels the reader is referred to standard textbooks of orthopaedic surgery. The following Section deals only with those aspects relevant to the management of war wounds where resources are limited.

### 23.8.1 Foot amputations

A few patients suffer trauma limited to the forefoot, the calcaneus and its soft-tissue covering being preserved. Several levels of amputation-disarticulation are described.

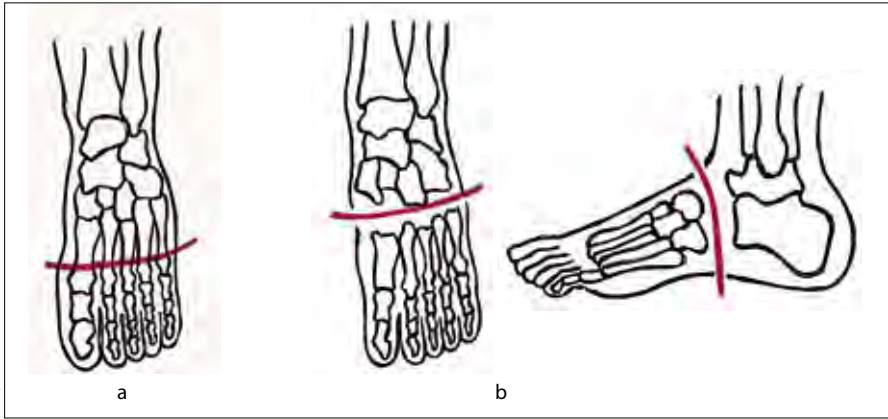


Figure 23.13.1

Partial foot amputations.

- a. Amputation across the metatarsal shafts.
- b. Tarso-metatarsal disarticulation.

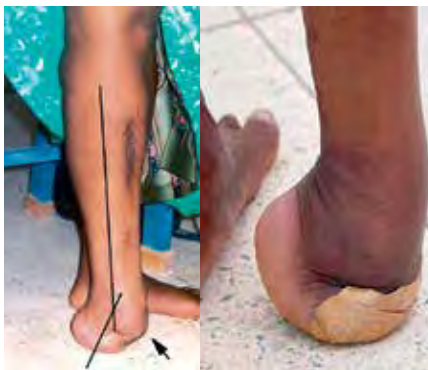

Figure 23.13.2

Partial foot amputation and some common problems: skin trauma and calcaneus tilt due to muscle imbalance.

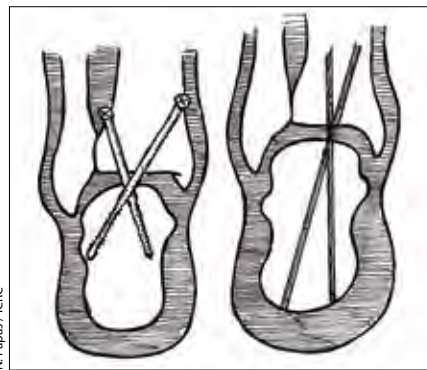


Figure 23.13.3

Possible solution for correction of the calcaneus tilt: arthrodesis of the ankle by means of screws or Steinmann pins.

In communities where many people still go barefoot or farmers work in muddy fields and rice paddies, a Syme amputation, which is an end-bearing stump, is often much preferred by the patient. Amputation at a higher level involves the use of footwear or crutches or a prosthesis. The operation preserves limb length and the epiphyseal growth plate, and good simple prostheses can be fitted to a Syme's stump for protection and aesthetic reasons.

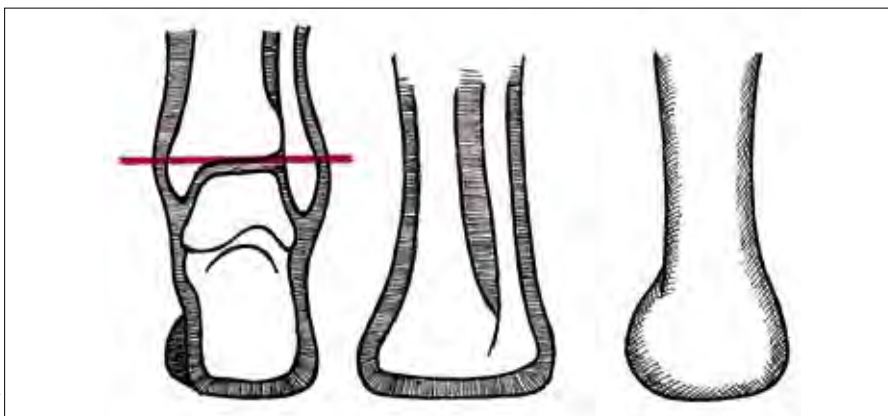


Figure 23.14.1

Syme's amputation.

Figures 23.14.2 and 23.14.3

Syme's amputation and a simple improvised repair of the prosthesis.



V. Sasini / ICRC

V. Sasini / ICRC

**ICRC EXPERIENCE**

The Syme amputation was extensively used in Cambodia and Viet Nam owing to the widespread use of small blast mines that damage the forefoot, and because most patients were farmers working in rice fields, unhappy with artificial limbs that would get stuck in the mud.

Patients with these various foot amputation-disarticulations are often able to walk short distances without a prosthesis. Many, however, cannot bear full body weight on the stump; transtibial amputation is an alternative that may give better functional results.

**23.8.2 Transtibial amputation**

Transtibial amputation is by far the most common amputation performed for war trauma. With a good but simple prosthesis, it allows the patient a high degree of physiological function.

The level of bone section is very important for the proper biomechanics of walking: 12 – 14 cm below the tibial tuberosity, with a minimum of 5 cm, is the classically defined level. In reality, this equates to 2.5 cm of bone length for every 30 cm of body height. Most transtibial amputations are through the proximal third of the tibia, but midshaft amputations can also be fitted easily and correctly. Consultation with the prosthetist allows the surgeon to choose the most appropriate level for the available prosthetic technology.

Figure 23.15.1

From the prosthetist's point of view, these are overly-long and -short stumps.

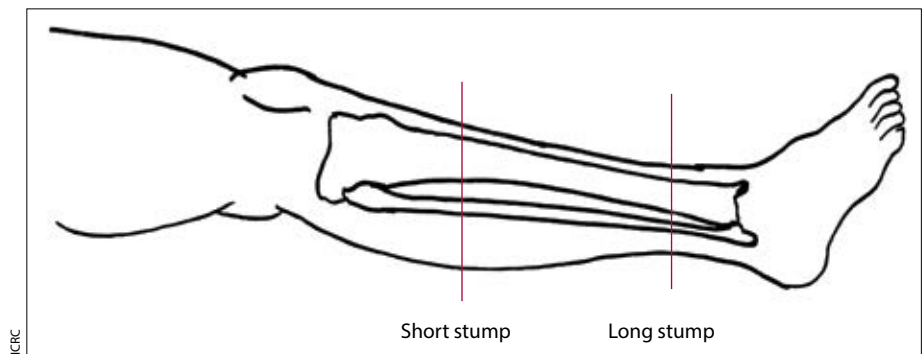
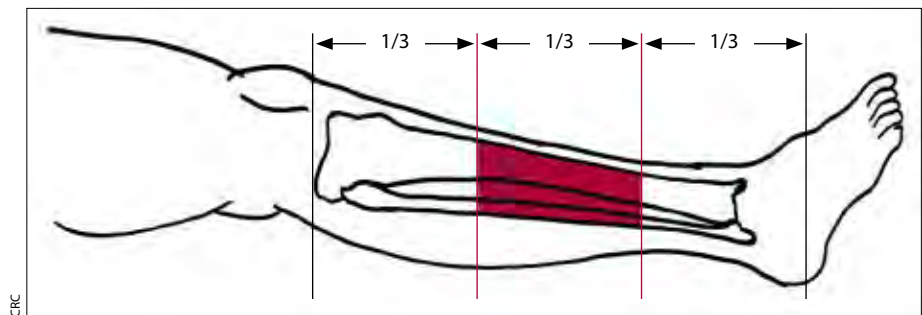


Figure 23.15.2

The ideal stump length: somewhere in the middle third.



The anterior crest of the tibia must be bevelled and the fibula cut 1–2 cm shorter than the tibia. All sectioned bone ends must be filed smooth.

The availability of soft-tissue flaps depends on the original trauma, of course, and the surgeon may have to improvise with whatever tissues remain in order to cover the weight-bearing surfaces properly. The muscles of the anterolateral compartment usually suffer the greatest damage and close attention should be paid to their viability. The surgeon should not hesitate to cut them back as they are of little use for covering the bone ends.

A long posterior flap including the gastrocnemius muscle mass is best for covering the bone end. Excess soleus should be pared back obliquely, or removed entirely, to avoid a bulbous stump. Too much soft tissue is almost as common a surgical error as too little; it results in an overly long stump, the so-called “elephant trunk” stump. As mentioned, a myoplastic amputation – myoepithelial flap of the intact medial gastrocnemius, dissected out from the muscle mass by sacrificing the soleus – offers excellent coverage.

#### Very short tibial stump

In some patients with an amputation high through the upper third of the tibia the remaining tissues are inadequate to cover the stump properly. In addition, the short fibular stump is no longer held in place by the interosseous membrane attaching it to the tibia and the strong pull of the lateral collateral ligament tilts the fibular head, which sticks out in abduction. ICRC prosthetists advise removing the head of the fibula in such cases. Removal of the head solves this problem and also reduces the bony volume that requires muscle cover, permitting easier closure of the stump without tension. No increased instability of the knee has been observed, once a prosthesis has been fitted.

#### Post-operative positioning and physiotherapy

After a transtibial amputation, the normal tendency is to flex the knee; measures must be undertaken to prevent the development of a flexion contracture. The limb should be kept elevated on a pillow or Braun-Böhler frame to decrease oedema, but with no flexion of the knee. A POP back slab may assist in achieving this in the immediate post-operative period if a Braun-Böhler frame is not used and may then be applied only at night later on, if necessary. The patient is instructed to keep the knee in extension on a pillow, to lie prone in bed as often as possible, and to avoid hanging the leg over the side of the bed or over the hand-piece of the crutches.

### 23.8.3 Knee disarticulation

Primary knee disarticulation can be performed at the initial operation as a damage-control procedure, to minimize surgical trauma and blood loss in haemodynamically unstable patients. It can be performed quickly and without any sectioning of bone and be converted to a transfemoral amputation at a second operation.

Whether a knee disarticulation should be a permanent and definitive procedure depends almost exclusively on the prosthetic expertise and technology available. For many years, ICRC surgeons have performed transfemoral amputations rather than through-knee-disarticulations and it is only recently that the ICRC has developed the specific components for the proper fitting of such a prosthesis.

#### Advantages and disadvantages

Much controversy surrounds the recourse to disarticulation where there are no adequate prosthetic services. If such services are available, then the through-knee disarticulation offers a better functional outcome compared to an amputation. On the other hand, cosmetic concerns may arise – and they are common – given the resulting prominence of the femoral condyles and the different height of the centre of the knee in the intact limb when compared to the artificial one. This can also affect physiological function. In children, conservation of the lower epiphysis is a definite advantage.

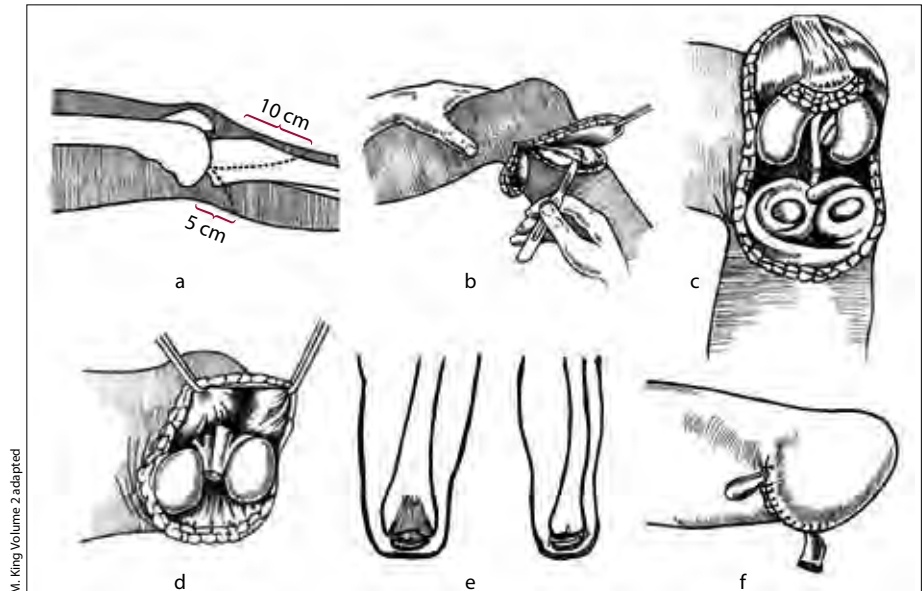
The great difficulty in a knee disarticulation is to maintain sufficient soft-tissue coverage. A flap of skin and subcutaneous fat alone is not adequate for an end-of-stump weight-bearing prosthesis unless a sort of padding can be provided by the prosthetic socket using a special foam liner.<sup>3</sup> If this is not available, the surgeon should contemplate the procedure only if the trauma permits the fashioning of a posterior muscle flap that is fixed anteriorly to the periosteum.

**Operative technique**

Various techniques have been described for the through-knee disarticulation. They all cause a certain extent of surgical trauma.

**Figure 23.16**

- Operative technique for knee disarticulation.
- Outlining the anterior and posterior flaps.
  - The anterior flap has been raised exposing the patellar tendon, which is cut through.
  - The cruciate ligaments have been sectioned.
  - The patellar tendon has been sutured to the remainder of the cruciate ligaments; the menisci have been removed.
  - Anterior and medial view of the stump.
  - The stump has been closed and a drain put in place.



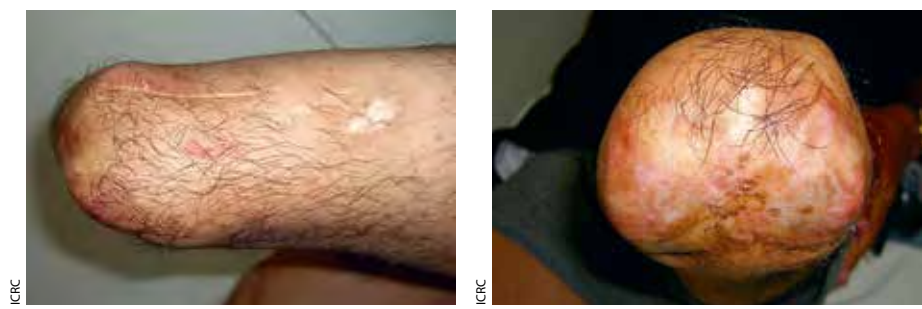M. King Volume 2, adapted

It is not necessary to remove the articular cartilage.

The ICRC experience of both surgeons and prosthetists suggests using the simplest technique. If the wound allows for it, an anterior skin flap is raised, providing stronger skin than that of the popliteal fossa. The best soft-tissue padding is provided by a gastrocnemius flap, again the wound permitting; otherwise the calf muscles are cut at their proximal insertions. The patella is kept but the menisci removed. The remaining articular cartilage is left as it is. For delayed primary closure it is essential to prevent drying of the exposed cartilage by applying a wet compress dressing. Closure is accomplished by suturing the patellar tendon to the cruciate ligaments and posterior capsule; the posterior muscle flap is sutured to the anterior periosteum; and the skin is closed.

Knee disarticulation should only be performed if the surgical expertise exists and after discussion with the prosthetic team.

**Figures 23.17.1 and 23.17.2**  
Typical knee disarticulation stump.



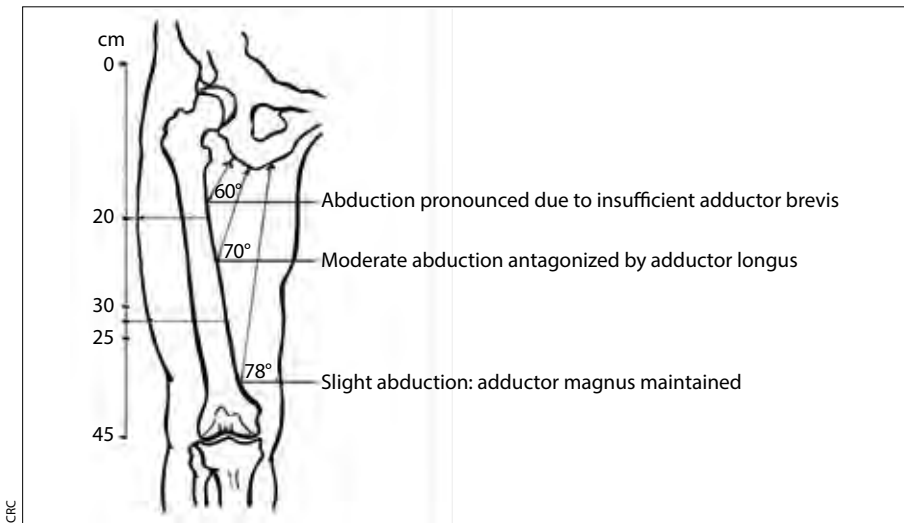
ICRC

ICRC

<sup>3</sup> ICRC prosthetic workshops use ethyl-vinyl-acetate.

### 23.8.4 Transfemoral amputation

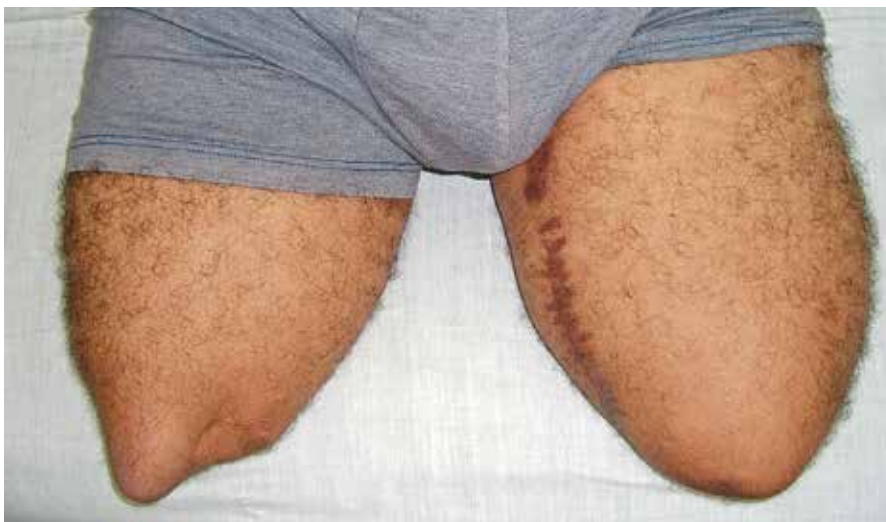The loss of the knee results in much more effort and expenditure of energy and oxygen consumption in walking because the prosthesis bears the weight in the groin instead of the stump. The femoral stump should be kept as long as possible, with a minimum of 10 cm from the greater trochanter. Managing a very short stump requires close consultation with the prosthetist.



**Figure 23.18.1**

The longer the transfemoral stump, the better the functional result. The shorter the stump, the greater the abduction force and the energy required for walking.

Oedematous swelling of the transected muscles can be considerable. As many intact muscles should be retained as the trauma permits, especially a vastus medialis flap in amputations near the knee. Physiological myoplastic stumps with suturing of the fascia of antagonistic muscle groups to each other is standard.



**Figure 23.18.2**

Good left stump, poor right stump: not enough soft tissue covering.

In amputations of the proximal third of the femur, the surgeon must attempt to salvage whatever can be kept of the antagonistic muscle groups and try to create a residual limb dynamically balanced between adductors and abductors. There might not be sufficient muscular mass to achieve this. The surgeon should aim at least for a good, firm soft-tissue padding of the bone end.

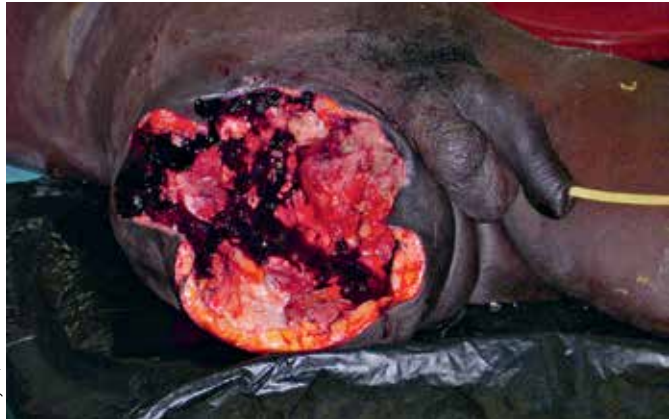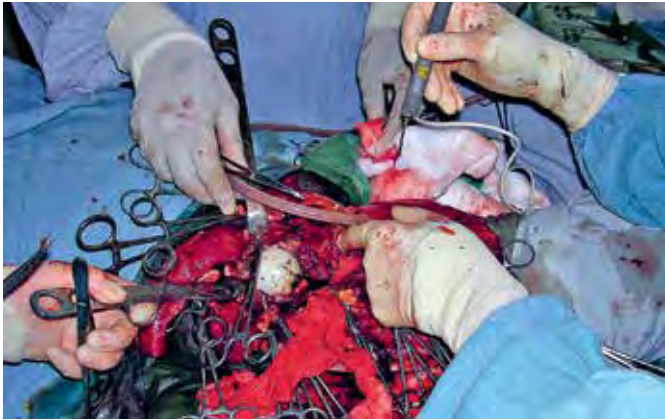
As mentioned in the case of an APM injury, fat surrounding the sciatic nerve should be excised if contamination is present.

#### Post-operative positioning and physiotherapy

After a transfemoral amputation the natural tendency is to flex, abduct and externally rotate the hip. To counteract this as much as possible a pillow should not be placed under the stump; a lateral cushion helps prevent abduction. The patient must be instructed in the proper positioning in bed (extension and adduction) and should be encouraged to adopt the prone position for as long and as often as possible. The loss of adduction capacity calls for specific exercises to reinforce the remaining musculature.

### 23.8.5 Hip disarticulation and hemipelvectomy

These mutilating operations are fortunately rarely encountered in war trauma. Associated injury to the pelvis and abdomen is usually so severe that most patients succumb. If it does need to be performed, usually because of severely infected and unsuccessfully managed more distal amputations, sufficient soft-tissue cover is required and as much of the pelvic bone structure retained as possible.



Figures 23.19.1 and 23.19.2

Hip disarticulation: a mutilating procedure.

### 23.8.6 Arm amputations

The general rule is to keep the upper-limb stump as long as possible, to provide the longest possible “paddle” that is stable and painless. A short below-elbow amputation is better than an above-elbow stump. The radius and ulna are sectioned at the same level and antagonistic muscle groups sutured together. Of greatest importance is the functional position of the remaining part of the limb: 90° flexion of the elbow and supination of the forearm to enable whatever manipulation of objects is possible. In the upper arm, no effort should be spared to salvage the head of the humerus, which serves as a support for a prosthesis.



Figure 23.20

The Krukenberg procedure: rehabilitation exercises are a first step towards socio-economic reintegration of the patient.

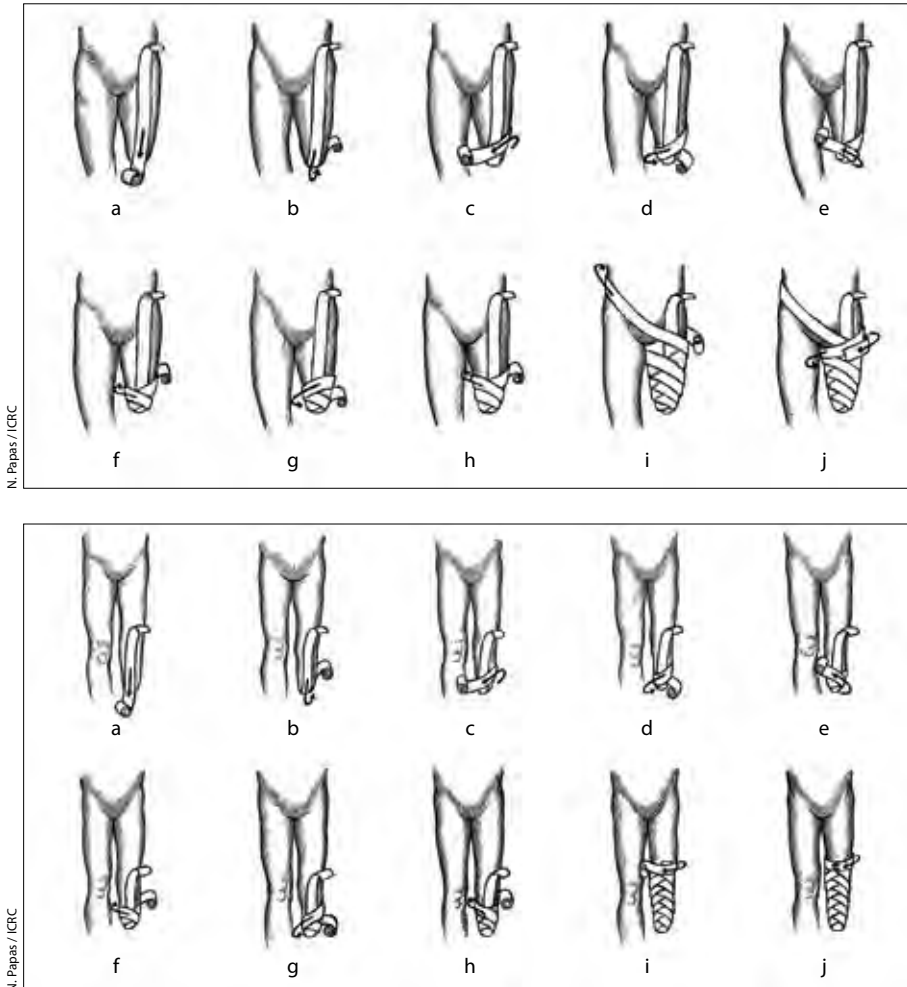
#### ICRC EXPERIENCE

During the civil war in Sierra Leone in the 1990s, a number of people suffered bilateral amputation of the hands. Specialized ICRC surgical teams performed a sophisticated reconstructive operation, the Krukenberg procedure, on 11 individuals. The operation was originally described by a German surgeon shortly after World War I to deal with patients involved in mine clearance who had lost both hands and were blinded by the explosion. The radius and ulna are separated to form a pincer or “chopsticks” mechanism for holding small objects. Flaps of skin are mobilized on the lateral and medial aspects of the forearm and then rotated to face each other on the separated bones, providing better sensation so that the blind patient can read large Braille script. The patients in Sierra Leone were not blind, but the procedure allowed better proprioception in the holding mechanism. The patients were able to hold objects, feed themselves and attend to their personal hygiene on their own after the operation, as well as wear a simple prosthesis. Prolonged pre-operative physiotherapy and psychological preparation proved to be essential.

Whatever the amputation, close consultation between surgeon, prosthetic technician and physiotherapist is mandatory to ensure the best result for the patient.

### 23.9 Post-operative care

Overly constrictive bandaging of amputation stumps can easily compromise the blood supply to the skin over the anterior surface of the tibia. Gentle but firm compression helps control oedema and decreases pain.



Figures 23.21.1 and 23.21.2

Figure-of-eight elastic bandaging of amputation stumps.

The size of the elastic bandage should be adapted to the stump: for a transtibial stump 8 – 10 cm wide, and for transfemoral 10 – 15 cm wide.

The bandage should be wrapped from the tip of the stump to always end at the lymph nodes proximal to the oedema (popliteal fossa or groin) and pressure should be greater distal than proximal.

The layers should overlap about half of the bandage width at each turn, with the bandage staying smooth and free of wrinkles.

The bandage can be worn even in the presence of a small wound on the stump.

Measures should be taken to counter the reflexive position taken by the stump to avoid the development of joint contractures. Physiotherapy of residual joints should begin immediately to keep them free from contractures and retain full movement, even before DPC is performed. General exercises should also begin to prepare the patient for walking, and specific exercises taught to strengthen the remaining muscles of the amputated limb.

The level of immediate post-operative pain is apparently related to the prevalence of chronic pain later on. Good analgesia not only results in greater patient comfort, but also permits earlier and more effective physiotherapy.

Sutures can usually be removed on the twelfth post-operative day.

### 23.10 Patient rehabilitation

Treatment of the patient is not over until rehabilitation is complete. This may entail reconstructive surgery involving specialist techniques, which are beyond the scope of this publication; physiotherapy continuing long after surgery; the fitting of a prosthesis; and subsequent vocational training to help the patient regain as active and independent a role as possible in the community.

Treatment is not complete until the patient is fitted with a prosthesis and achieves socio-economic reintegration.



W. Krasowski / ICRC

**Figure 23.22**

The importance of physical rehabilitation: mine victim at the Cúcuta prosthetic limb-fitting centre (Colombia).

Once healing has been established, firm bandaging helps decrease oedema and maintain the shape of the stump. The physiotherapist is the person closest to the patient and best placed to determine if the stump is ready for fitting. This was usually considered to be after three months, but fitting of a prosthesis can be performed much earlier (6 – 8 weeks after skin closure), depending on the prosthetic centre's workload and expertise. This has become the routine practice in ICRC centres. An immediate temporary prosthesis fitted within a few days of operation is seldom available where resources are really limited.

The manufacture of prostheses requires a specialized workshop and trained technicians. The fitting of a prosthesis and the coaching of the patient in its use and maintenance are essential elements in physical rehabilitation and are among the major reasons for the economic burden that a prosthetic centre represents for the health system of a low-income country. On the other hand, a fitted patient is less of a socio-economic burden than an unfitted one.

Each prosthesis must be individually fitted and replaced every three years or every two years for persons living in rough terrain; every 6 – 12 months for a growing child. Prostheses are expensive items and the cost of the technology used in rich countries is beyond the reach of most people. A child injured at the age of 10, with a life expectancy of another 40 to 50 years, will need 25 appliances during his or her lifetime. Even with simple technology, at approximately 100 US\$ per transtibial and 250 US\$ per transfemoral prosthesis, this amounts to a prohibitive sum in countries where average *per capita* income may be 15 to 30 US\$ a month. It is easy to understand why most people can only afford crutches.

Producing sufficient numbers of prostheses, crutches and wheelchairs, to meet the needs of thousands of war amputees, yet not create long-standing dependence on imported materials, is a challenge. The ICRC has focused its efforts on polypropylene: a synthetic product that is inexpensive, easy to handle and store, does not require chemical additives, can be recycled, and is produced in many low-income countries. In addition, the material is impervious to water and ambient humidity, an important factor in many tropical countries. It has proven well adapted to the fitting of thousands of amputees in countries with only limited resources.

For a description of ICRC physical rehabilitation programmes and prosthetic workshops please refer to the brochure on the DVD.

Regular follow-up is necessary to monitor the evolution of the shape of the stump and the occurrence of any complications. Patient compliance with the use of the prosthesis and his or her psychological state and socio-economic integration must also be attended to. Chronic pain and depression and substance abuse are common problems and require appropriate interventions.

In spite of significant efforts, many problems persist: prostheses break; the technology for local repair is often not available and city-based workshops are far away and transport expensive. Furthermore, working and living aids developed for industrialized societies are frequently not appropriate for poor rural settings and even simpler locally-developed ones are sorely lacking.<sup>4</sup>

In addition to the physical trauma of the loss of limb, the psychological trauma of a radical change in self-image, especially for young adults, can seem unbearable to the individual involved. It often elicits a kind of grief response, analogous to that which occurs after the death of a close relative or friend.

Amputees often have to provide for their family, or suffer from social stigmatization for being disabled. Unemployment, divorce, poor marriage prospects, and social ostracism are just some of the afflictions that follow the original physical insult. Much remains to be done in terms of psychological and socio-economic support of war amputees around the world.

<sup>4</sup> See: Hobbs L, McDonough S, O'Callaghan A. *Life After Injury: A Rehabilitation Manual for the Injured and Their Helpers*. Kuala Lumpur, Malaysia: Third World Network; 2002.



There are a number of simple and efficient measures of psychological support that can be implemented in the hospital and the rehabilitation centre: rehabilitated amputees can be asked to visit new hospital arrivals, preferably from the same village, clan or group, depending on the social context. The amputee can be invited to the centre while still in the early post-operative stage to be informed about socio-economic reintegration and shown others in training. In many ICRC centres, a large percentage of the technicians and workers are themselves amputees, demonstrating by example the possibility of gainful work and employment.

### 23.11 Complications and stump revision

Many patients suffer from a number of complications, early and late, from minor skin irritation to wound infection and necrosis. The most common include a painful neuroma, phantom and residual pain, redundant soft tissue, bone spurs and heterotopic ossification; and later the occurrence of low-back pain and degenerative joint disease due to faulty gait.

Patients should be examined by the surgeon together with the prosthetist and physiotherapist. What might appear to be an “inadequate” stump to the surgeon may only be a small difficulty in the fitting of the prosthesis for the prosthetist, certainly not worthy of submitting the patient to further surgery. Revision surgery should *only* be contemplated if the prosthetist requests it in order to provide a functional prosthesis satisfactory to the patient’s needs.

Examination should be systematic and begin with the history of the trauma, use of a prosthesis if any, and assessment of the general condition of the patient. Examination of the stump should also be systematic and include a plain X-ray.

Stump status	Length	
	Shape	
	Mobility of joint(s); contractures	
	"Choke" syndrome, i.e. tight proximal fit of a prosthesis and loose distally, creating venous obstruction	
Skin	Irritation, infection	
	Blisters, ulcers	
	Callosity	
	Epidermal cyst	
	Other	
Scar	Free and supple	
	Adherent, sensitive	
	Pressure point	
	"Dog ears"	
Soft tissue	Muscle and subcutaneous fat	Too much ("elephant trunk")
		Too little
		Atrophy, fibrosis
		Other
	Presence of neuroma	
Heterotopic ossification		
Bone	Length	
	Bevelling of anterior edge of tibia	
	Length of fibula	
	Osteomyelitis	
	Osteophyte	
	Other	

Table 23.2 ICRC protocol for the examination of an amputation stump.

Figures 23.23.1 – 23.23.8

Examples of some common complications.

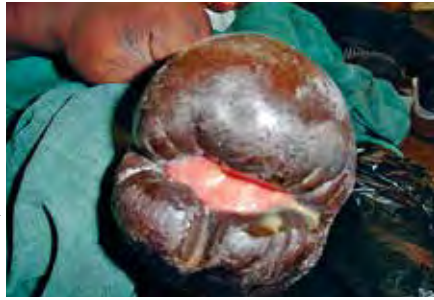

Figure 23.23.1  
Infection of the wound.

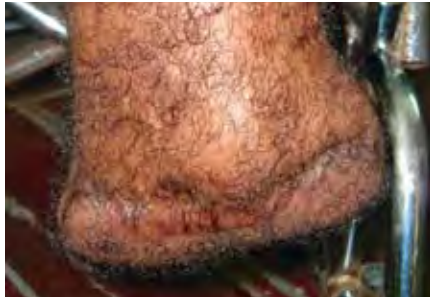

Figure 23.23.2  
Globular stump and "dog ears" of the scar.

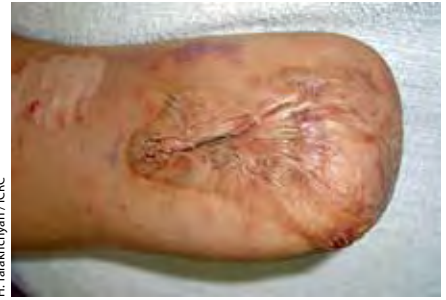

Figure 23.23.3  
Invagination of the scar.

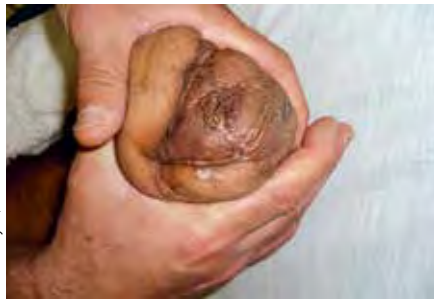

Figure 23.23.4  
Adherent scar.

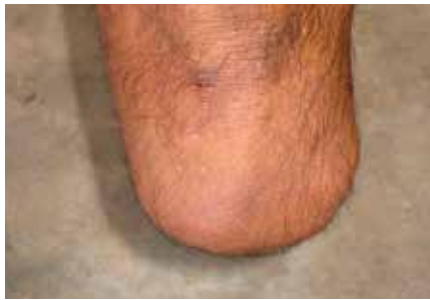

Figure 23.23.5  
Very short stump.

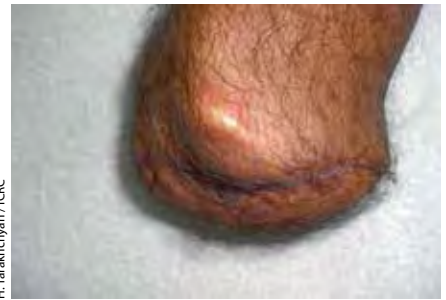
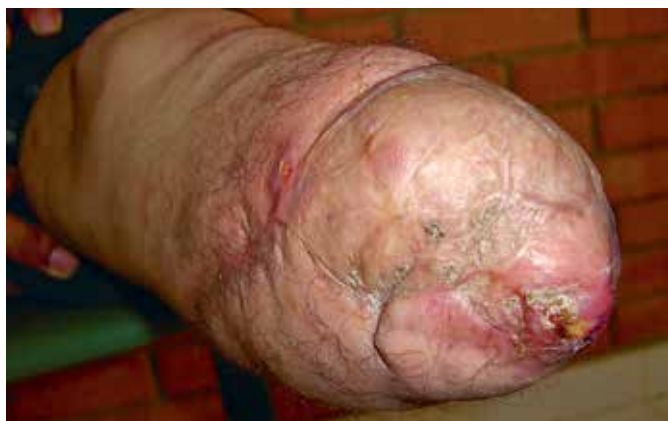
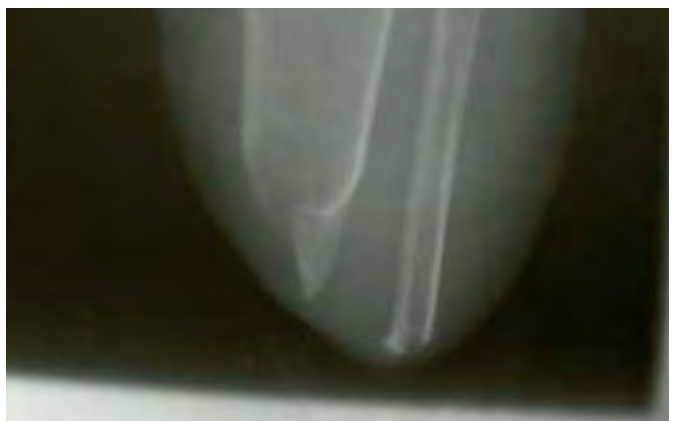Figure 23.23.6  
Non-bevelling of the anterior crest of the tibia.



Figures 23.23.7 and 23.23.8

The fibula is longer than the tibia and shows an osteophyte formation at its tip that is eroding the skin and causing local infection of the scar. In addition there is an osteophyte of the tibia causing pain.



Simple surgery can often resolve many problems that inhibit the proper use of a prosthesis, such as a painful neuroma, an osteophyte, or a poor scar requiring revision. Other conditions may require a revision of the bone section or length, or complete revision of the stump to provide adequate muscular cover of the bone ends.

### 23.11.1 Painful neuroma

A painful neuroma is probably the most common surgical complication after amputation; it is entirely organic in origin. The patient complains of a sharp, clearly localized pain, like an electric shock, caused by pressure at a specific point of the stump. On gentle palpation a hard, mobile swelling is identified, at times the size of an olive. Palpation of the swelling exacerbates the pain, which is described as the one the patient feels with the prosthesis.

The treatment: under local, regional or general anaesthesia, depending on the patient's age and the presence of any other pathologies requiring surgical care, the swelling is dissected out and the nerve stump cut shorter by a fresh scalpel blade. The nerve end should be implanted in a muscular mass away from the pressure exerted by the prosthetic socket.

### 23.11.2 Phantom limb sensation and pain

The loss of a limb radically changes the psychological self-image of the patient, but a great deal of the physiological and anatomic image remains intact, so much so that the patient perceives the continued presence of the amputated limb. The person maintains a complete "body map" imprinted in the higher brain centres. Many phantom sensations are not painful and their occurrence should be explained to the amputee as a normal reaction post-injury. Persons with a congenital absence of a limb or amputation occurring in early childhood do not experience phantom limb sensations and pain.

The incidence of phantom limb pain varies greatly among published reports. Much confusion arises from a poor diagnostic definition; it must be carefully distinguished from residual limb pain due to definite organic causes. Phantom limb pain is a multifactorial condition; peripheral, spinal and psychological elements all play a part. The intensity of the pain also varies widely from simple discomfort to incapacitating. Some patients complain of a form of causalgia with feelings of burning and throbbing.

Treatment first and foremost involves the elimination of organic causes of residual limb pain such as a neuroma, nerves entrapped in the surgical scar, or an osteophyte. The results of treatment of true phantom pain have been disappointing and many approaches have been tried, some with measured success in a number of – but by no means all patients. These include tricyclic antidepressants (amitriptyline), anticonvulsants (carbamazepine), opiate analgesics and tramadol, and various anaesthetic blocks and local counter-irritants. No surgical interventions have proven effective. Some positive results have been reported with acupuncture and hypnosis. Psychological support from family, friends and prosthetists, and the attending physician plays an important role.



## **Chapter 24**

# **VASCULAR INJURIES**

24.	VASCULAR INJURIES	
24.1	Introduction	203
24.2	Wound ballistics and types of arterial injury	203
24.3	Epidemiology	205
24.3.1	Relative incidence of peripheral vascular injuries	205
24.3.2	Combined arterially-associated injuries	205
24.3.3	Amputation rate after vascular injuries	206
24.3.4	Amputation versus limb salvage	206
24.3.5	Missile emboli	207
24.3.6	Red Cross Wound Score	207
24.4	Emergency room care	208
24.4.1	Pneumatic tourniquet	208
24.4.2	Paraclinical investigations	208
24.5	Diagnosis and surgical decision-making	209
24.6	Surgical management	210
24.6.1	Preparation of the non-specialist	210
24.6.2	Preparation of the operating theatre	210
24.6.3	Preparation of the patient	211
24.6.4	Surgical techniques for arterial trauma	211
24.6.5	Repair, anastomosis and grafting	214
24.6.6	Operative technique	215
24.6.7	Finishing the operation	216
24.7	Post-operative care	217
24.8	Damage control and temporary shunt	217
24.9	Complex limb injuries: concomitant arterial lesion and fracture	219
24.10	Specific arteries	219
24.10.1	Axillary and brachial arteries	219
24.10.2	Inguinal region	219
24.10.3	Popliteal fossa	220
24.11	Venous injury	220
24.11.1	Specific veins	221
24.11.2	Combined arterial and venous injuries	221
24.12	Arterio-venous fistula and pseudoaneurysm	221
24.13	Complications	223
24.13.1	Infection	223
24.13.2	Thrombosis	223

## Basic principles

The basic principles for the management of injury to peripheral blood vessels are straightforward and emphasize a number of points made throughout this manual. In addition to pre-hospital control of haemorrhage and rapid evacuation, they include:

- definitive haemorrhage control;
- resuscitation;
- early arterial repair;
- coverage of the arterial repair with appropriate soft tissue;
- repair of venous injury when possible;
- fasciotomy in most cases;
- proper wound care, stabilization of any fractures, and physiotherapy.

### 24.1 Introduction

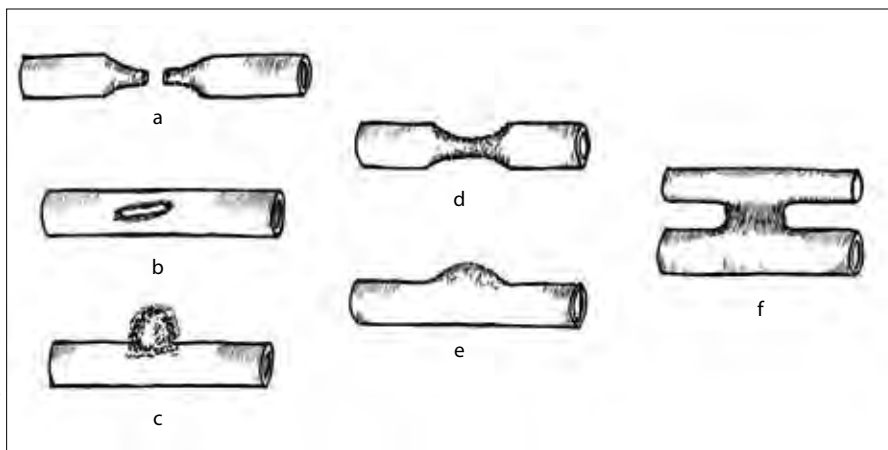
Exsanguination from wounds in the limbs is the most frequent cause of preventable death on the modern battlefield. Although this primarily concerns the pre-hospital first-aid phase, its importance in hospital surgical care cannot be underestimated. Major vascular procedures in the limbs have become commonplace in modern surgical practice; however, when faced with an influx of mass casualties, vascular repair may consume an inordinate amount of theatre time. Simple ligation and accepting the risk of amputation may be the most appropriate clinical decision.

### 24.2 Wound ballistics and types of arterial injury

In most cases, the elongated elastic structure of arteries causes them to “flee” a projectile. It is not uncommon for the surgeon to find that the only intact structures traversing a large wound cavity are the neurovascular bundle and/or tendons.

Wound ballistics can be translated into several different pathological types of arterial injury:

- transection or avulsion;
- lateral laceration or punctate wound;
- contusion, with or without intimal disruption and thrombosis;
- isolated vasospasm;
- pseudoaneurysm and arteriovenous fistula.



**Figure 24.1**

Types of arterial trauma.

- Section of the artery with spasm of the cut ends.
- Lateral laceration: the lesion remains open.
- Lateral laceration or rupture of the entire arterial wall: pulsating haematoma leading to a pseudoaneurysm.
- Contusion, intimal damage and spasm leading to thrombosis.
- Contusion and rupture of the media causing a true aneurysm.
- Combined arterial and venous injury: arterio-venous fistula.

### Complete transection or avulsion

Most lesions of blood vessels are due to direct contact with the projectile: i.e. laceration, whether by a low- or high-kinetic energy missile. In addition, a near-miss by a high-energy projectile at the point of temporary cavitation in the shooting channel may cause the artery to be avulsed by the severe stretch to which it is subjected.

A complete transection or avulsion of the artery is accompanied by loss of tissue and microscopic damage to all layers of the arterial wall in a variable length of the vessel, up to 2 cm and more at both cut ends.

A frank transection of the artery provokes a reactive temporary vasospasm of the retracted cut ends. Shortly thereafter, the spasm eases and haemorrhage ensues.

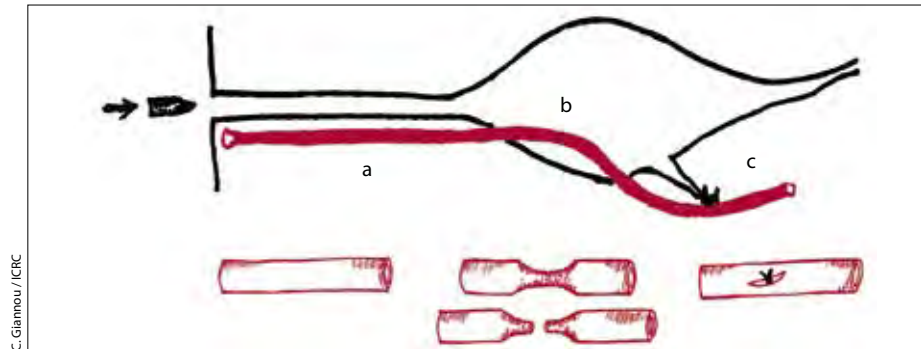
### Lateral laceration or punctate wound

In a lateral laceration or a punctate wound, vessel continuity remains intact but a portion of the wall is torn open or punctured. A small shrapnel fragment, a piece of a fragmented bullet, or a spicule of bone may occasionally puncture and remain stuck in the vessel wall, thereby creating a tamponade effect. In most cases, a lateral laceration stays open: there is no retraction and no spasm and immediate haemorrhage ensues, which may result in a pulsating haematoma and, as the extravasated blood forms an enlarging and slowly organizing clot around the orifice, in a pseudoaneurysm. If there is a concomitant injury to a vein, a communicating channel may be created between the two: i.e. an arterio-venous fistula (A-V fistula).

Figure 24.2

Artery in proximity to the wound channel of a fragmenting FMJ high-kinetic energy bullet.

- Vessel close to straight narrow channel: no lesion, the vessel "flees" the bullet.
- Involvement in temporary cavitation: arterial avulsion or contusion depending on the distance from the centre of the cavity.
- Laceration of the artery by bullet fragment.



### Arterial contusion and intimal detachment

Arterial contusion can be due to temporary cavitation but occurs when the vessel is at a distance from the track of a high-energy missile, in contrast to the near-miss. The artery is stretched and compressed against the wall of the temporary cavity causing adventitial haemorrhage first, then breaks in the tunica media, and finally disruption of the intima with or without the prolapse of an intimal flap. Microscopic changes have been described up to 2 cm in both directions into apparently normal arterial wall. Minor degrees of contusion may give no clinical signs and heal spontaneously.

In symptomatizing lesions, the contused segment may suffer from spasm or intimal damage that provokes deposition of fibrin leading to thrombosis of the vessel over time; it may take several hours for the fibrin to completely obstruct the vessel. Finally, a *true aneurysm* may develop by herniation of the media through a weakened spot in the external tunica elastica and adventitia.

Blast injury, whether from a bomb explosion or an APM, can provoke massive intimal injuries resulting in thrombosis of the vessel. In addition, the zone of injury may not be apparent at primary surgery and only fully declare itself after 24 hours by a blow-out of an anastomotic repair.

Arterial contusion may also be due to blunt crushing trauma with no external wound.

### Arterial spasm

Arterial spasm, a reflex contraction of the vessel wall, may result from projectile-induced cavitation or a blunt injury. The diagnosis can only be made on angiography or surgical exploration to exclude contusion, and on an arteriotomy to exclude an intimal flap. A high degree of suspicion is necessary and the surgeon should not be content with "spasm" as an explanation for ischaemia.



## 24.3 Epidemiology

Hospital mortality after vascular injuries frequently depends on associated trauma to other body regions, hence the maxim: “sacrifice a limb to save a life”. By the time the life-saving laparotomy has been completed, the viability of a limb may have been compromised beyond recuperation by the cumulative time of shock and ischaemia.

### 24.3.1 Relative incidence of peripheral vascular injuries

Although 50 – 75% of major war wounds involve the limbs, only 1 – 2% include injury to major vessels. This figure rises to 5% and more where modern body armour is used extensively, offering greater protection to the torso, and in conflicts where anti-personnel mines are widely deployed. One ICRC surgical team working on the Cambodian-Thai border in 1988 during a conflict that witnessed the widespread use of landmines received 94 war-wounded patients in a three-month period; 13.8% suffered vascular injuries to the lower limb.<sup>1</sup>

In most past studies, the major arteries of the lower limb are injured almost twice as often as those of the upper limb. This is to be expected, given that the surface area of the lower limbs is twice that of the upper limbs. However, the brachial artery is usually the most often or second-most often major peripheral artery injured; probably owing to its very superficial anatomy and the normal activities of a combatant that increase its exposure.

The relative incidence of isolated major venous injuries is not as well documented. Nevertheless, again there is a preponderance of injuries to the veins of the lower limb.

### 24.3.2 Combined arterially-associated injuries

As is to be expected the anatomy of certain regions lends itself more readily to combined injuries to the artery and vein and concomitant fracture of the bone. This is particularly the case for the popliteal artery and vein, the axillary artery and brachial plexus, and the femoral vessels and femur.

Artery	Vein (%)				Nerve (%)		Bone (%)	
	Lebanon N = 550	USA Viet Nam N = 936	USSR Afghanistan N = 194	USA Afghanistan / Iraq N = 585	USA Viet Nam	USSR Afghanistan	USA Viet Nam	USSR Afghanistan
Axillary	41	34	50	35	92	40	27	20
Brachial		19	36	6	71	55	34	38
Iliac	23	42	50	57	12	17	8	33
Femoral	39	45	38	47	19	37	23	55
Popliteal	82	52	74	38	37	45	40	55
All limb injuries	47	38	45	34	44	43	30	47

**Table 24.1** Incidence of arterial lesions in combination with other local injuries. Major peripheral vessels only; forearm and lower leg excluded.<sup>2</sup>

The forearm and lower leg are usually excluded from such analyses since the anatomy is such that combined injury to the vessels, nerves and bone is exceedingly common.

Invariably, in most studies, injuries to the artery together with the vein or nerve exist in almost half the cases, and with fracture of the bone in about a third to almost a half.

1 Fasol R, Irvine S, Zilla P. Vascular injuries caused by anti-personnel mines. *J Cardiovasc Surg* 1989; **30**: 467 – 472.

2 Lebanon: Zakharia AT. Cardiovascular and thoracic battle injuries in the Lebanon War. Analysis of 3,000 personal cases. *J Thorac Cardiovasc Surg* 1985; **89**: 723 – 733.

USA Viet Nam: Bowen TE, Bellamy RF. *Emergency War Surgery NATO Handbook, 2nd US Revision*. Washington D.C.: United States Department of Defense; 1988.

USSR Afghanistan: Brusov PG, Nikolenko VK. Experience of treating gunshot wounds of large vessels in Afghanistan. *World J Surg* 2005; **29** (Suppl.): S25 – S29.

USA Afghanistan / Iraq: White JM, Stannard A, Burkhardt GE, Eastridge BJ, Blackburne LH, Rasmussen TE. The epidemiology of vascular injury in the wars in Iraq and Afghanistan. *Ann Surg* 2011; **253**: 1184 – 1189.

### 24.3.3 Amputation rate after vascular injuries

Several classic studies of vascular wounds in World War II, Korea and Viet Nam, have set the modern standard. Until the Korean War, ligation of a severed artery was the primary treatment, although a few surgeons had already tried to practise vascular repair. The most often quoted statistic is taken from the well-known World War II study by DeBakey and Simeone.<sup>3</sup> Out of 2,471 vascular injuries, only 81 (3%) were repaired primarily, with an amputation rate of 35%. Among the remaining patients treated by arterial ligation, the amputation rate in survivors was 49%. With greater mastery of arterial repair, the amputation rate decreased to 10–13% amongst US troops in Korea and Viet Nam and Soviet soldiers in Afghanistan; current rates stand at about 5%.

The amputation rate for arterial injury has thus fallen drastically in the last 100 years. This has been a function of a number of factors: faster evacuation and earlier surgery; improved availability of first aid and control of haemorrhage; blood transfusion, better resuscitation and anaesthesia; and antibiotics. Particularly noteworthy has been increasing surgical expertise in the accomplishment of vascular repair.

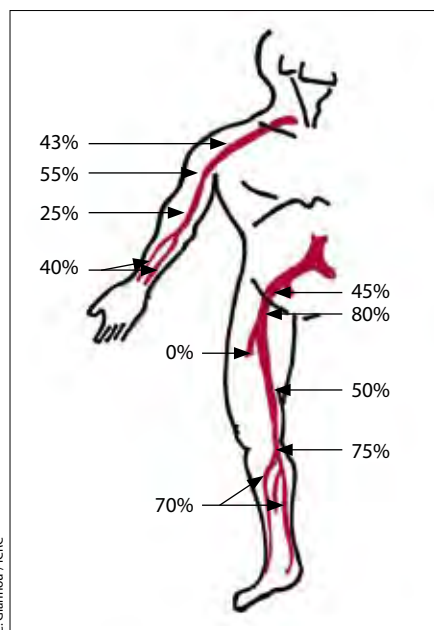


Figure 24.3

Average amputation rates after arterial ligation (combination of sources).

Artery	World War II: ligation	Viet Nam: repair
Axillary	43 %	5 %
Brachial	27 %	6 %
Common iliac	54 %	11 %
Common femoral	81 %	15 %
Superficial femoral	55 %	12 %
Popliteal	73 %	30 %

Table 24.2 Amputation rates of major arterial injuries: “ligation era” versus “repair era”.<sup>4</sup>

Nonetheless, ligation is still a common technique for dealing with peripheral vascular injuries, owing to the large number of lesions of vessels distal to the elbow or knee. In contemporary conflicts, 50% or more of the injuries to all arteries still undergo simple ligation.<sup>5</sup>

### 24.3.4 Amputation versus limb salvage

Shock, the state of the patient’s collateral circulation, and concomitant fracture play important roles in determining the outcome: amputation or limb salvage.

Major clinical reasons for an amputation in patients with vascular injury include:

- delay in diagnosis and revascularization;
- inability to perform vascular repair where extensive soft-tissue damage renders coverage of the vessels difficult;
- infection;
- crush injury, and
- compartment syndrome.

Loss of certain major nerves as well often results in such a degree of functional loss that the patient is better off with a prosthesis than with a debilitating and painful limb (see Sections B.5.1 and 23.3.3).

The critical period before irreversible nerve and muscle damage due to acute ischaemia occurs is 6–12 hours. After 12 hours, reperfusion comes too late in most cases if the collateral circulation has been insufficient to maintain viability. At the ICRC hospital in Peshawar, Pakistan (1989–91), where war-wounded from the conflict in Afghanistan were treated, the amputation rate for patients revascularized within 12 hours of injury was 22%; it reached 93% for those undergoing surgery after 12 hours.<sup>6</sup>

3 DeBakey ME, Simeone FA. Battle injuries of the arteries in World War II: an analysis of 2,471 cases. *Ann Surg* 1946; **123**: 534–579.

4 Adapted from Rich NM, Baugh JH, Hughes CW. Significance of complications associated with vascular repairs performed in Vietnam. *Arch Surg* 1970; **100**: 646–651 and DeBakey and Simeone, 1946.

5 White JM, Stannard A, Burkhardt GE, Eastridge BJ, Blackbourne LH, Rasmussen TE. The epidemiology of vascular injury in the wars in Iraq and Afghanistan. *Ann Surg* 2011; **253**: 1184–1189.

6 Gosselin RA, Siegberg CJY, Coupland R, Agerskov K. Outcome of arterial repairs in 23 consecutive patients at the ICRC-Peshawar Hospital for War Wounded. *J Trauma* 1993; **34**: 373–376.

The importance of collateral circulation is unquestionable. It consists of two elements: pre-existing named vessels in known collateral systems, which are more or less robust depending on the anatomical region; and multiple unnamed muscular branches that proliferate and form anastomoses with one another to create a “midzone” network. If these two systems “open up” sufficiently and early enough, the viability of the limb is preserved. Vascular injuries to the upper limb are associated with a higher limb salvage rate than injuries to the lower limb, probably because of its collateral circulation. The use of a tourniquet cuts off this collateral circulation. If applied inappropriately and if not released regularly during a long evacuation, it compromises the viability of the limb even further.

Numerous authors have reported the difference in amputation rates when the injury comprises a combined fracture and vascular lesion as compared to an isolated arterial injury (see Table 24.2). During World War II, when almost all lesions were ligated, the amputation rate was 60% in combined injuries and 42% in isolated arterial wounds. In Viet Nam when arterial repair was used, the failure rate was 33% for a combined injury and 5% for an isolated arterial lesion. A concomitant bone fracture probably indicates a greater release of kinetic energy locally with increased surrounding soft-tissue damage and disruption of the collateral circulation. A similar tendency has also been observed when there is concomitant venous injury that cannot be repaired.

### 24.3.5 Missile emboli

As discussed in Chapter 14, missile embolism is an exceedingly rare phenomenon that is only ever reported for individual cases. More cases have been described following civilian violence than in the military literature. The Vietnam Vascular Registry recorded only 22 such cases among approximately 7,500 casualties with vascular lesions, representing an incidence of only 0.3%. All but three of these 22 cases had been wounded by small fragments from anti-personnel landmines, mortars or grenades.

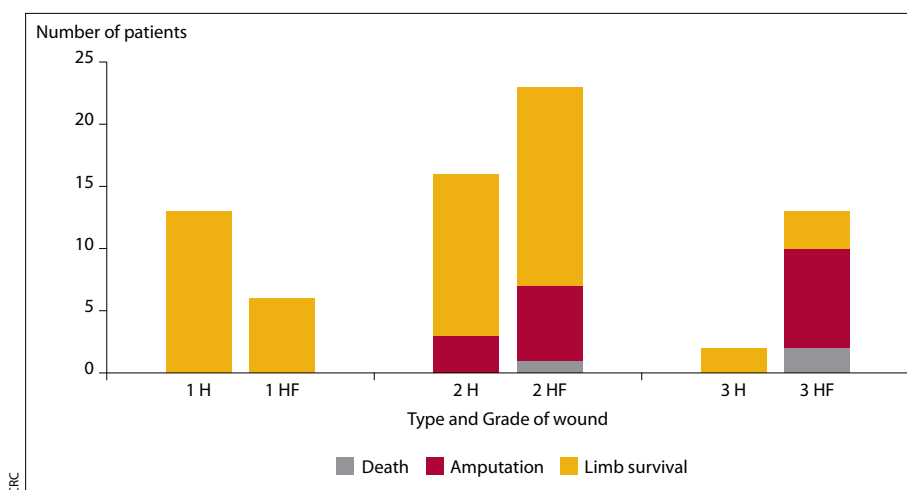
Certain criteria must be met for embolism to occur. The missile must be of small enough calibre – usually a fragment – and its kinetic energy sufficiently low at the point of injury. Furthermore, the affected vessel must be ample enough, or the lesion implicate the heart or an arterio-venous fistula.

The diagnosis is not always obvious and the embolization may occur years after the injury.

### 24.3.6 Red Cross Wound Score

Peripheral vascular injury proximal to the knee and elbow can result in life-threatening haemorrhage. Thus, in the RCWS a lesion in one of these vessels is scored V = H.

The results of an ICRC study on 73 patients with lesions in the femoral or popliteal arteries, with and without a concomitant fracture, are shown in Figure 24.4. Although the numbers do not allow for a statistically significant result, the tendency is obvious and stands to reason. Arterial lesions in large wounds with fractures tend to result in a higher amputation rate and mortality.



**Figure 24.4**

ICRC study of mortality and amputation by wound Type and Grade. Lesions of the femoral or popliteal vessels qualify as a Type H wound. The presence of a clinically significant fracture = Type F wound. Grades are 1, 2 and 3 according to the size of the wound.

## 24.4 Emergency room care

Catastrophic external haemorrhage from peripheral vessels is the first C in the C-ABCDE paradigm but should have been dealt with by first aid in the pre-hospital setting (see Section 7.7.3). Otherwise, the patient does not survive to reach hospital. It should be noted that both arterial and venous haemorrhage may lead to shock.

As specified in Section 8.5.2, blind clamping in the depths of a bleeding wound must never be attempted. Proximal digital pressure, packing of the wound and a compressive dressing, or pneumatic tourniquet can all be used to control haemorrhage temporarily in the ER until the patient is brought to the operating theatre. Only if a bleeding vessel can be *clearly seen* may direct control be obtained with haemostatic artery forceps.

External bleeding can be controlled temporarily, while dealing with the airway or breathing or internal haemorrhage.

In the emergency room, after examination and control of the airway and breathing, and exclusion of internal haemorrhage, the other signs of peripheral vascular injury must be sought. In all limb injuries, a high degree of suspicion regarding vascular damage is essential. A small piece of muscle may block off a wound, preventing blood from exiting and creating a contained haematoma.

Analgesia, antibiotics and tetanus prophylaxis should be administered as per protocol.

### 24.4.1 Pneumatic tourniquet

The use of a pneumatic tourniquet in the ER is of great value in an open bleeding wound, until proximal and distal control can be obtained in the theatre. However, a tourniquet should not be used for a wound with a self-contained haematoma or isolated signs of ischaemia as it cuts off the collateral circulation that may be the only thing maintaining viability of the distal tissues.

### 24.4.2 Paraclinical investigations

If available, arteriography may be performed in a stable patient where the signs of ischaemia are inconclusive or to define more accurately an arteriovenous fistula or pseudoaneurysm. This is best undertaken by the surgeon in the operating theatre with a single injection of 20 ml of full-strength contrast material in the proximal part of the vessel. If the proper X-ray equipment (mobile machine, C-arm fluoroscopy) is not available in theatre, then the surgeon must go with the patient to the X-ray department and make certain that there is no delay. The common femoral artery can be cannulated percutaneously with a fine 18 gauge needle and the contrast material rapidly injected. A plain radiograph is taken after a delay of 2 seconds for the mid-thigh, 3 seconds for the distal thigh, and 5 seconds for the calf.

An ultrasonic Doppler probe, if available, is a useful adjunct to careful clinical examination, especially of more occult vascular injuries. Not only can peripheral blood flow be ascertained, but the *ankle-brachial index* (ABI) can be calculated. A manual blood pressure cuff is slipped around the ankle and a Doppler probe placed over both the dorsalis pedis and posterior tibial arteries, and the highest occlusion pressure is measured. This value is then divided by the highest brachial systolic blood pressure to give the ABI. Any index less than 0.9 in an otherwise healthy patient is highly suggestive of arterial injury. In the absence of a Doppler probe, a simple stethoscope may be used to try to pick up the posterior tibial pulse, after resuscitation of the patient.

## 24.5 Diagnosis and surgical decision-making

Major arterial lesions can be difficult to diagnose in the presence of shock and multiple injuries. On the other hand, the signs of arterial injury may be evident and include the following “hard signs”:

- active haemorrhage;
- large, expanding haematoma;
- pulsatile haematoma with a bruit or thrill (pseudoaneurysm);
- “machinery” murmur (arteriovenous fistula);
- signs of acute distal ischaemia, especially absence of pulses after patient resuscitation.

### The classical six Ps of acute distal ischaemia

- |             |                               |
|-------------|-------------------------------|
| • Pain      | • Paraesthesia                |
| • Pallor    | • Poikilothermia <sup>7</sup> |
| • Paralysis | • Pulselessness               |

The presence of one or more of these evident signs associated with a missile track that passes close to a major peripheral vessel calls for *operative exploration*.

The signs of acute distal ischaemia can be ambiguous. Normal pulses do not exclude vascular injury; the collateral circulation may maintain the distal pulse. In addition and especially subsequent to cavitation effects, intimal disruption and ensuing thrombosis may be delayed. A cold, pulseless limb with mottling of the skin and cyanosis may also be present in a patient after exposure to a cold environment, crush injury or shock – whatever the cause. However, the absence of distal pulses once the patient has been resuscitated is considered a “hard sign” of arterial damage. The clinical indicators of peripheral circulation must always be evaluated by comparing the injured and intact limbs. *Asymmetrical* pulses, capillary filling, skin temperature, etc. are all indicative of compromised peripheral circulation.

It is difficult to make a diagnosis before resuscitation to a systolic pressure of 90 mm Hg and comparison must always be made with the intact limb.

Absence of “hard signs”, or only incomplete signs of ischaemia when the projectile trajectory is close to a major vessel, warrant *observation*, not surgical intervention. So do the “soft signs” of:

- small stable non-pulsatile haematoma;
- motor or sensory deficit of an adjacent nerve;
- shock unexplained by other injuries;
- history of haemorrhage that has ceased.

A patient with an obvious vascular injury should go directly to the operating theatre *without delay*. Although there is no time limit beyond which arterial repair is absolutely contraindicated, the best results are obtained when blood flow is re-established within 6 hours of injury.<sup>8</sup> The existence of good collateral circulation often determines the success rate of arterial repair or the consequences of ligation. The presence of shock is a complicating factor. Another factor is severe tissue damage that may lead the surgeon to decide on amputation rather than vascular repair and limb salvage (see Section 23.3.3).

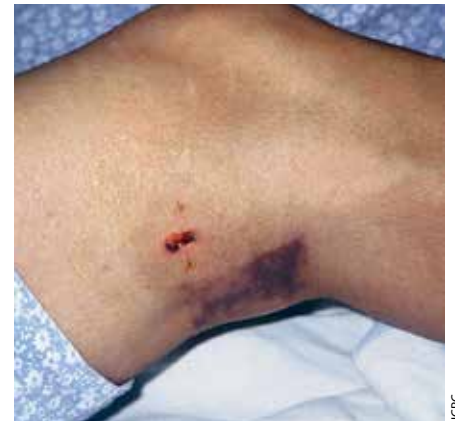

Figure 24.5

Ecchymosis in association with a bullet track close to the popliteal artery.



Figure 24.6

Obvious vascular injury: frank ischaemic gangrene following GSW.

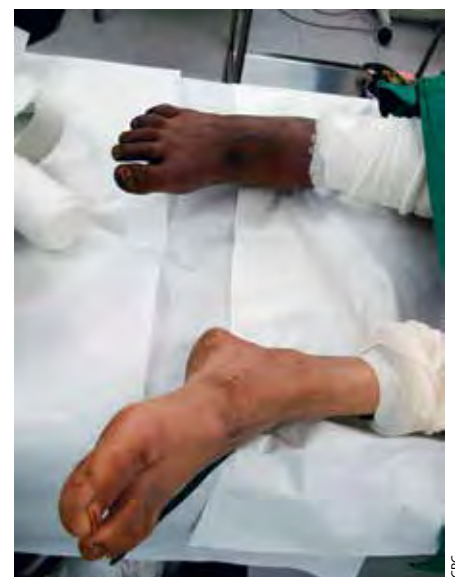
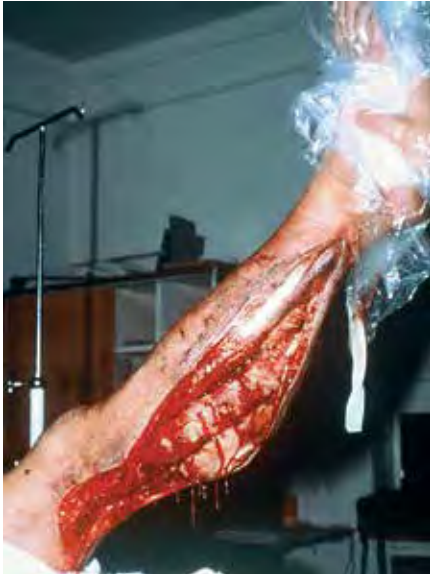
Figure 24.7

Always compare both limbs for signs of ischaemia.

7 Poikilothermia: varying temperature, term used for cold-blooded animals that cannot regulate their body temperature and take that of the surrounding environment. Here, the ischaemic limb becomes cold and the skin temperature approaches that of the ambient air.

8 Burkhardt GE, Gifford SM, Propper B, Spencer JR, Williams K, Jones L, Sumner N, Cowart J, Rasmussen TE. The impact of ischemic intervals on neuromuscular recovery in a porcine (*Sus scrofa*) survival model of extremity vascular injury. *J Vasc Surg* 2011; **53**: 165 – 173.



R. Coupland / ICRC

**Figure 24.8**

The muscles of more than two compartments were found to be necrotic.

It can be difficult if not impossible to differentiate partial ischaemia with some collateral blood flow but developing compartment syndrome on the one hand from complete ischaemia on the other. The clinical evaluation of irreversible ischaemic muscle and nerve damage is usually not possible, except where there has been much delay. In ambiguous presentations fasciotomy should be performed first to assess muscle viability: colour, texture, and contractile response to pinching and electrical stimulation using diathermy. If the muscles are viable, repair is undertaken.

The most difficult situation is to be found below the knee. If only the muscles of the antero-lateral compartment are found to be nonviable, they are debrided and vascular repair performed. If the muscles of two or more compartments are nonviable, amputation should be undertaken.

“Look and see” is wiser than “wait and see”.

Arteries should be repaired whenever possible; however, those of the forearm and lower leg below the popliteal may be ligated if injured in isolation and if the distal limb remains well perfused. Ideally, if both forearm arteries are damaged, at least one and preferably both should be repaired. In the lower leg, at least one of the two posterior arteries should be repaired along with the anterior tibialis.

Major venous injury may be more difficult to diagnose than arterial injury. The only signs may be dark and steady bleeding from a wound or, in a closed wound, a massive haematoma. Acute venous insufficiency usually presents within 24 hours as massive oedema in a cool, bluish limb. Later, chronic insufficiency manifests itself with the signs of venous stasis: oedema, skin discolouration, and even ulceration.

Neurological symptoms must be sought during the examination. However, other neurological signs may be the result of ischaemia, compression of a nerve by an expanding haematoma, or compartment syndrome – not of direct nerve injury.

## 24.6 Surgical management

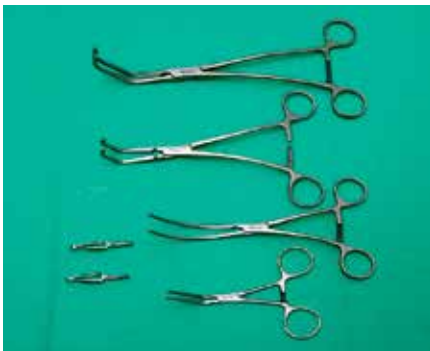The most effective procedure to stop haemorrhage is a ligature around the vessel.

### 24.6.1 Preparation of the non-specialist

Vascular surgery takes time. The general surgeon who does not perform vascular surgery on a regular basis must prepare for it with a thorough revision of vascular anatomy and the incisions for exposure of major vessels. The basic techniques of arterial suture are straightforward, as are simple damage-control procedures.

### 24.6.2 Preparation of the operating theatre

Vascular instruments are special and specific: DeBakey, Blalock and Satinsky vascular and bulldog clamps, etc. They can be improvised to a certain extent: non-crushing intestinal clamps or ordinary haemostatic forceps with plastic intravenous-giving lines placed over the blades can be used. Vascular sutures are monofilament, very fine, and inserted on a non-traumatic eyeless needle. If vascular monofilament suture is not available, fine braided silk passed through subcutaneous fat to lubricate it may be used.



T. Gassmann / ICRC

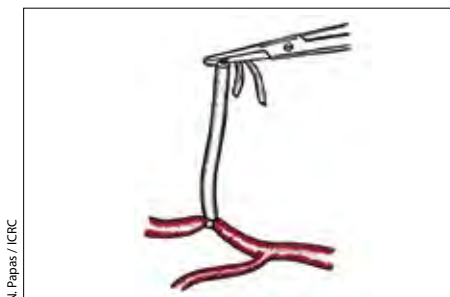**Figure 24.9**

Vascular clamps.


Other appropriate supplies include:

- vascular loops or umbilical tapes or a Penrose drain to improvise a Rummel tourniquet;
- Fogarty or ureteric catheters of different sizes;
- heparin;
- and contrast material if possible.

These should all be prepared by the theatre staff *before* the operation begins. Good lighting and good assistance greatly facilitate the attempt at vascular repair.



N. Pappas / ICRC



T. Gassmann / ICRC

Figures 24.10.1 and 24.10.2

Rummel tourniquet: a tape is passed through a rubber tube or catheter.

### 24.6.3 Preparation of the patient

The positioning and draping of the patient for proper vascular exposure is important; proximal control may require opening the chest or abdomen for “junctional zone” injuries (see Section D. 6). The skin of the uninjured leg should be prepared at the same time for the harvesting of a vein interposition graft if necessary.

Anaesthesia is as usual. The patient must first have been properly resuscitated: vascular surgery is time-consuming and the patient must not be pushed into the lethal triad of hypothermia, acidosis and coagulopathy in the attempt to save a limb. The availability of blood for transfusion can determine the extent of time devoted to limb salvage.

### 24.6.4 Surgical techniques for arterial trauma

Major arteries should be repaired whenever possible. The basic principles comprise:

- control of haemorrhage;
- exposure and control of the vessels, proximally and distally;
- maintenance of the patency of the vascular tree;
- preparation of the vessel;
- repair or reconstruction of the artery;
- covering the artery with appropriate soft tissue;
- wound debridement and stabilization of any fracture;
- fasciotomy.

Please note:

Early fasciotomy may be performed even before vascular repair if there is a delay in limb reperfusion. Some surgeons do this as a routine once haemorrhage has been controlled.

1. Control haemorrhage.

The pneumatic tourniquet is inflated if necessary or distal and proximal digital pressure over the artery is applied by an assistant. A pneumatic tourniquet may be applied even in cases without overt haemorrhage, but should not be inflated until the very moment it is needed.

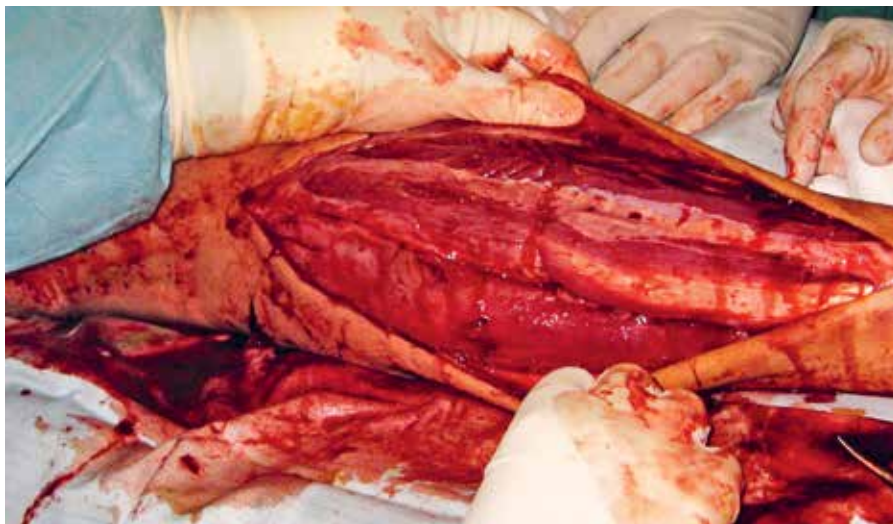
2. Expose the vessel.

Proximal exposure of the major vessels is accomplished through a generous incision safely above the site of injury and preferably through healthy tissue.

Distal exposure can usually be obtained at the site of the injury; otherwise, a separate incision is performed in the anatomic line of the vessel, again through healthy tissue.

**Figure 24.11**

Generous incision for exposure of the vessels.



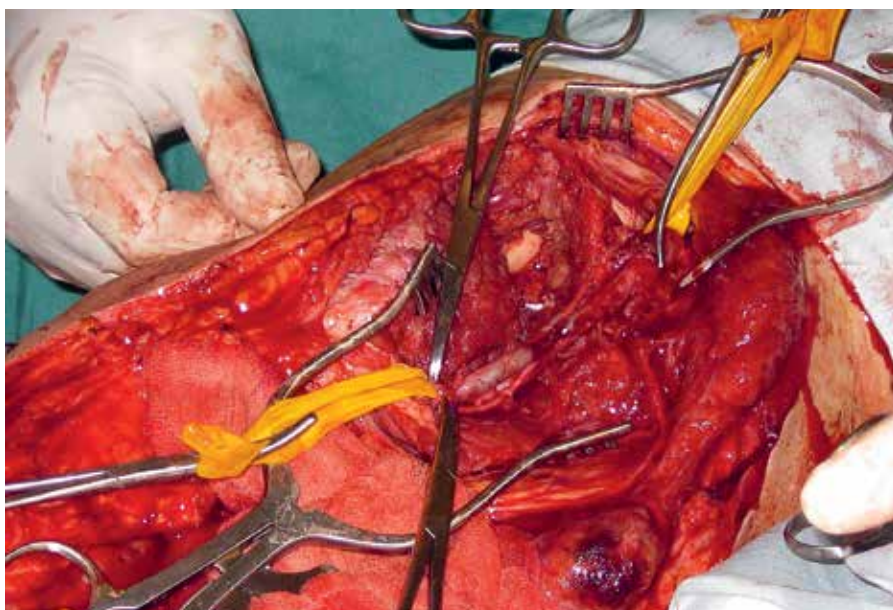
F. Plant / ICRG

3. Control the vessel.

The exposed proximal and distal parts of the vessels are controlled with vascular clamps or Rummel tourniquets. If a pneumatic tourniquet has been applied, it can now be removed.

**Figure 24.12**

Proximal and distal control of the vessel using vascular clamps and improvised Rummel tourniquets using Penrose drains.

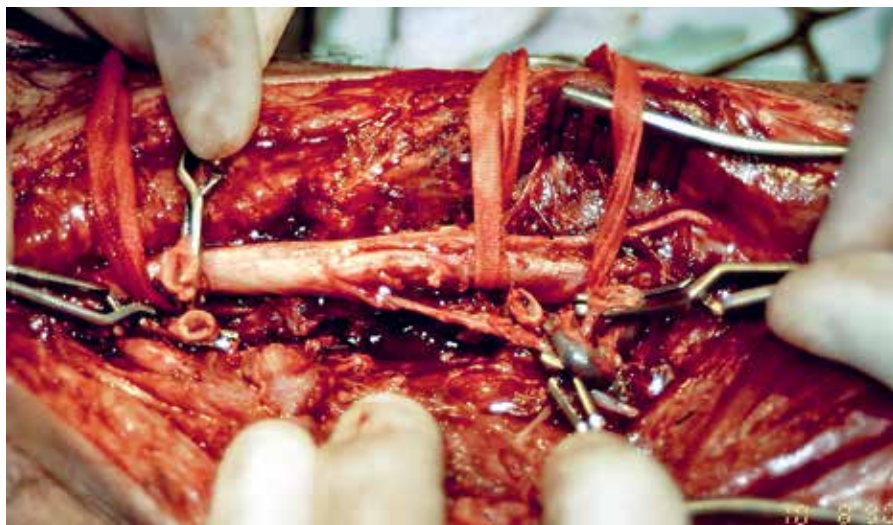


F. Plant / ICRG



#### 4. Isolate the injury.

The site of injury is attacked directly. The vessels are dissected free and their sectioned ends picked up with bulldog clamps or some other non-crushing clamp. Otherwise, a paediatric Foley catheter may be introduced and the balloon inflated to occlude the vessel.



**Figure 24.13**

The sectioned ends are held in bulldog clamps.

#### 5. Maintain the vascular tree.

The proximal end of the artery is checked for free forward-bleeding by releasing the bulldog and vascular clamps. Likewise, adequate back-bleeding from the distal segment is confirmed.

Thrombectomy should be performed by gently passing a Fogarty or ureteric catheter, depending on what is available. The catheter should be inserted carefully as it can easily damage the intima during its introduction or if the balloon is over-inflated.

Heparinized saline (5 – 10 IU/ml saline<sup>9</sup>) is injected proximally and distally: 20 – 30 ml in each end for the lower limb, 10 – 20 ml in the upper. It helps prevent clot formation in the static column of blood while repair is undertaken. In ICRC surgical practice it is not given systemically.

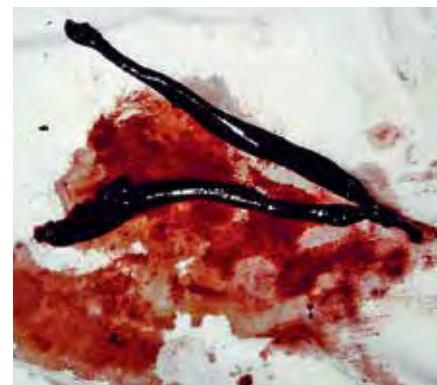In the absence of a Fogarty catheter the vessel should be milked from proximal and distal ends towards the site of injury to manually squeeze out any thrombus. When combined with repeated injections of heparinized saline, or even plain saline, this should dislodge and evacuate any thrombus.

A ureteric catheter may be preferable to a Fogarty. It has a balloon for thrombectomy and can also be used to inject the heparinized solution.

#### 6. Prepare the vessel.

The ends of the injured vessel are debrided back to a level of healthy tissue. For arteries, the debridement must remove a further 2 – 3 mm of adventitia so that the exposed healthy ends show only the elastic tunica media which alone is capable of holding sutures.

Repair, anastomosis, or an interposition vein graft is undertaken, depending on the extent of injury. However, no repair of any sort should be undertaken unless it can be covered by viable soft tissue.



**Figure 24.14**

Thrombus removed from the damaged vessel.

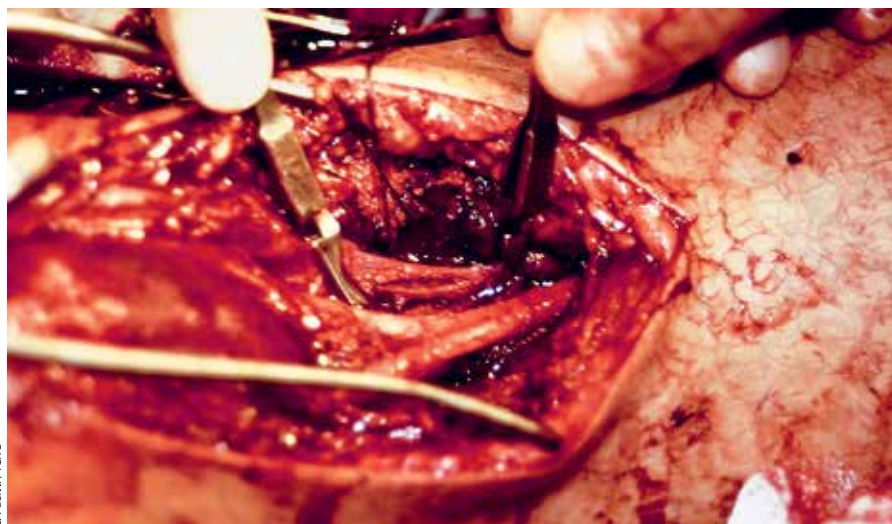
<sup>9</sup> Concentrations of heparin used by different surgeons vary widely, from 5 to 100 IU/ml. There is no universal standard. Even many basic surgery reference texts mention only "heparinized saline" without specifying a concentration. Should heparin be used, protamine should be available as an antidote: 1 mg protamine/100 IU sodium heparin.

## 24.6.5 Repair, anastomosis and grafting

### Lateral laceration

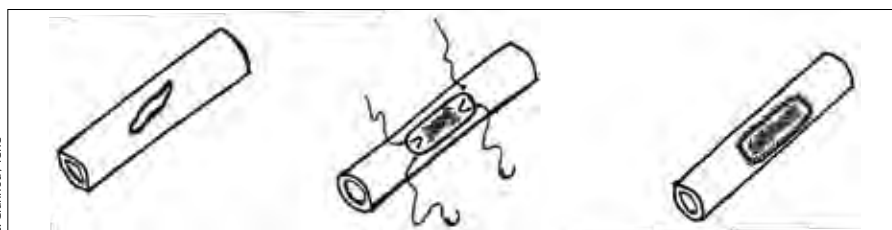
Direct repair by suture is possible only for small, clean-cut lacerations of large arteries, except if there is a risk of stenosis. Sutures should be inserted 1 mm apart and about 1 mm from the wound edge using continuous 5/0 – 6/0 synthetic vascular suture. Lacerations of significant small- or medium-sized arteries or cases where direct suture of a debrided artery would result in stenosis are better repaired with a venous patch graft. Some surgeons prefer resection of the injured segment and anastomosis in all cases, as they find this procedure more expeditious.

**Figure 24.15.1**  
Lateral laceration of an artery.



C. Pacitti / ICRG

**Figure 24.15.2**  
Repair of lateral arterial laceration with a vein patch graft. Two stay sutures may be placed at both ends first for better control of the vessel.



C. Giamou / ICRG

### Complete transection or avulsion

Direct anastomosis is usually possible for low- and some medium-energy wounds (e.g. laceration by a knife, fragment from a hand grenade, some revolver bullets). Defects of up to 2 – 4 cm – depending on the artery – can be treated with direct end-to-end anastomosis by mobilization of the vessel. The injured artery is dissected proximally and distally for up to 10 cm to provide slack and ensure an anastomosis without any tension on the suture line. The surgeon should not sacrifice important collateral branches or pull joints into severe flexion in an attempt to perform an end-to-end anastomosis. Larger defects usually require a vein graft.

### Arterial contusion

Intimal damage is usually too extensive to allow for resection and anastomosis. Resection back to healthy tissue and replacement with a vein graft is the operation of choice.

### Arterial spasm

It is very dangerous to diagnose arterial spasm on simple clinical grounds. The vessel must be inspected directly and an arteriotomy performed to observe and confirm the integrity of the intimal surface, to make certain that no prolapse of an intimal flap has occurred. Local application of warm saline or injection into the adventitia of papaverine or lidocaine may help in relieving the spasm.

Many diagnosed arterial spasms are in reality intimal detachments: the only way to find out is to “open and look”.

## 24.6.6 Operative technique

### Arterial anastomosis

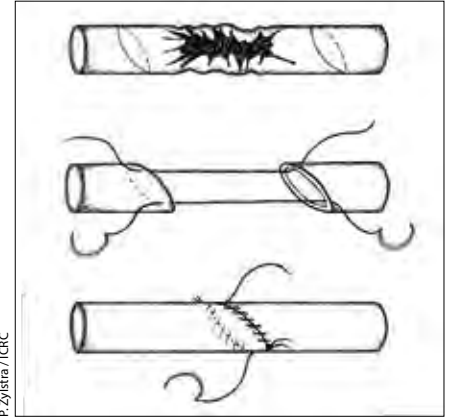
The ends of the artery should be cut slightly obliquely (spatulation) but not as much as for the ureter. A continuous suture of very fine monofilament synthetic material (5/0 or 6/0) is best for the anastomosis. Two or three interrupted lateral stay-sutures may be used to control the proximal and distal ends. Interrupted sutures should be used for smaller calibre arteries such as the radial, ulnar or tibial or in children. There should be no tension on the arterial anastomosis and no stenosis of the arterial lumen.



C. Picetti / ICRG

**Figure 24.16.1**

Direct anastomosis of an artery.



P. Zylstra / ICRG

**Figure 24.16.2**

Excision of traumatized arterial segment with end-to-end anastomosis. Note the spatulation of the arterial ends.

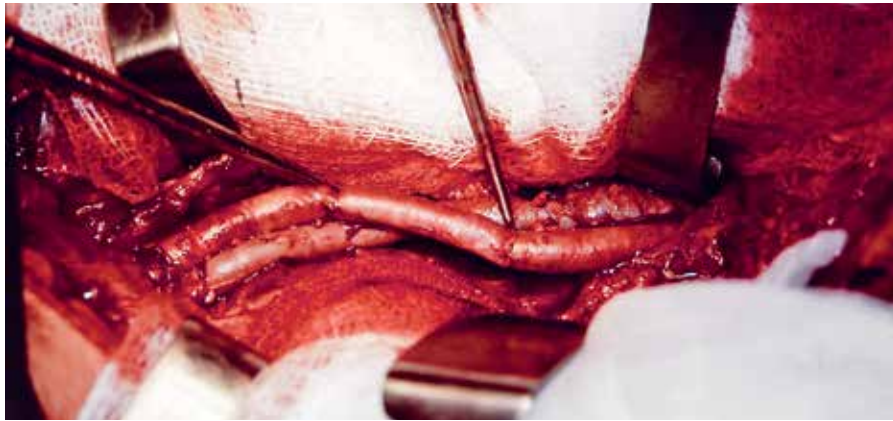
### Interposition vein graft

More extensive damage requires replacement by an interposition saphenous vein graft taken from the opposite limb so as not to compromise venous return in the injured extremity. Most arterial damage associated with missile wounds affects a large segment. Even after proximal and distal dissection, the cut ends still cannot be sufficiently approximated without tension and therefore a vein graft is necessary.

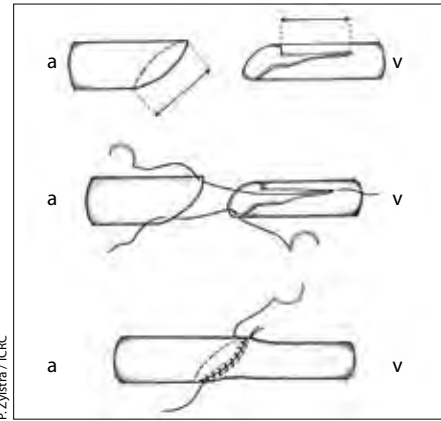
The saphenous vein graft should be harvested from the uninjured limb.

The appropriate length of the long saphenous vein should be dissected cleanly and all branches tied carefully. If this is not available, the lesser saphenous vein or one from the upper limb are second choices.

Spasm of the graft can be reversed by gentle dilatation with saline or blood injected by a syringe. The vein segment must be reversed to avoid obstruction to flow from any venous valves. When put in place the graft must not be twisted, and too long a graft can result in a kink; both can lead to thrombosis. The artery-graft anastomoses are accomplished in the fashion described above for direct anastomosis with a continuous monofilament suture. Spatulation of the vein involves a small longitudinal incision.



**Figure 24.17.1**  
Interposition vein graft.



**Figure 24.17.2**  
End-to-end vein graft anastomosis after resection of the segment of injured artery and spatulation of the ends: a = artery; v = vein graft.

For interposition grafts some surgeons use a synthetic prosthesis. ICRC surgeons believe that in contaminated war wounds it is best to avoid a graft of synthetic material, which in any case is seldom available when working with limited resources. An autogenous vein graft is best.

Please note:

Children grow and so will their blood vessels: it is therefore preferable to repair all transected arteries with an interposition vein graft and to use interrupted sutures rather than a continuous one to avoid stenosis in the long term.

**The final stitch**

Before completing the last stitch of the repair, the distal clamp is removed momentarily to fill the segment with blood and remove any air. Once the final stitch is tied, the distal clamp is released first (lower pressure), then the proximal.

In any arterial anastomosis, bleeding through the suture line after release of the clamps often occurs and should be controlled by gentle pressure packing for up to 10 minutes if necessary.<sup>10</sup> Additional sutures usually only result in more bleeding through the new needle holes. Figure-of-eight or mattress sutures should only be used if the bleeding continues after pressure packing.

## 24.6.7 Finishing the operation

**Debride the wound**

After arterial repair or vein grafting, the wound is debrided and irrigated as usual and left open for delayed primary closure. During debridement, additional vascular and neural injuries should be looked for in the vicinity, especially if the primary damage has been inflicted by fragments which tend to be numerous.

**Provide soft-tissue coverage**

The repaired vessel should be covered with soft tissue: fascia or a muscle rotation flap if necessary (see Section B.11). The latissimus dorsi can cover the axillary and brachial vessels, and the gracilis muscle, among others, can be used for the femoral vessels. The gastrocnemius is suitable for the popliteal. However, to prevent thrombosis excessive compression of the vessel should be avoided. As mentioned, failure of soft-tissue coverage leads to failure: either thrombosis or desiccation of the repair and secondary haemorrhage.

No repair of any sort should be undertaken unless it can be covered by viable soft tissue.

<sup>10</sup> This is the time for a cup of coffee or tea; it is best if the surgeon leaves the table, otherwise most surgeons cannot resist "having a look".

### Fasciotomy

The following are particular indications for fasciotomy:<sup>11</sup>

- delay of more than 4 hours between injury and restoration of flow;
- prolonged period of hypotension or shock;
- obvious oedema pre-operatively or developing during or after the surgical procedure;
- combined venous and arterial injury in major vessels;
- massive associated soft-tissue injury;
- arterial ligation or obvious failure of the repair;
- isolated major venous injury.

#### Please note:

Waiting for the end of the operation to perform a fasciotomy may compromise the repair by allowing venous congestion and poor outflow, or even muscle necrosis, to occur. As mentioned, fasciotomy may be performed once the vessels have been isolated and clamped and before vascular repair.

Based on their experience, ICRC surgeons recommend performing a distal fasciotomy in *all cases of vascular injury*.

### Control the repair

Distal perfusion of the limb – pulses and capillary filling – should be checked before the surgeon leaves the operating theatre. Re-exploration and confirmation of the patency of the anastomosis is best performed *now* rather than hours later. If the facilities are available and a pre-operative on-table arteriogram has been performed, it may be repeated immediately upon completion of primary surgery.

## 24.7 Post-operative care

Circulation peripheral to the vascular repair must be checked regularly. Close observation is necessary for any signs of haemorrhage or ischaemia (denoting thrombosis of the anastomosis), infection, or compartment syndrome if fasciotomy was not performed primarily.

The limb should be splinted and maintained slightly elevated to improve venous drainage. Active isometric muscle exercises should begin on the first day after operation, whilst immobilization in bed is required until delayed primary closure of the soft-tissue wounds.

ICRC surgeons do not administer systemic anticoagulants (heparin or warfarin) or platelet antagonists (aspirin).

## 24.8 Damage control and temporary shunt

In the past, the standard technique for dealing with an exsanguinating patient was simple ligation of the artery. This is still a possibility for an inexperienced surgeon and the safest haemostatic procedure.

Modern trauma surgery makes wide use of a technique that was the basis for the first attempts at arterial anastomosis at the beginning of the 20th century and is very useful for the general surgeon operating with limited resources: a temporary shunt to bridge the gap in a major artery.

11 Adapted from du Plessis HJC, Marais TJ, van Wyk FAK, Mieny CJ. Compartment syndrome and fasciotomy. *S Afr J Surg* 1983; **21**: 193 – 206.

### Indications for a temporary shunt

Rather than performing an anastomosis or vein graft, some situations call for a temporary shunt as a damage-control approach:

- a haemodynamically unstable patient with multiple injuries;
- a large soft-tissue wound where the anatomy renders debridement difficult owing to the position of the neurovascular bundle;
- a wound with a major fracture (see below);
- a surgeon who is simply not confident enough to complete the repair at the first operation.

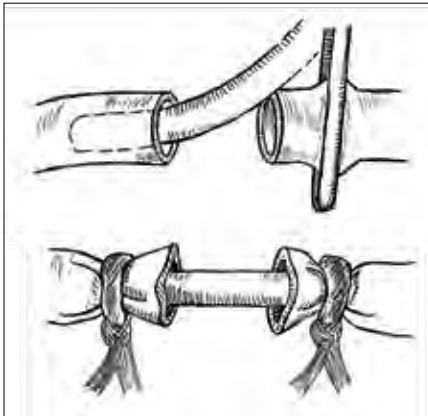
Some surgeons even advocate the routine use of a temporary shunt whenever a vein graft is to be used. Temporary shunting allows immediate perfusion of the limb – and a better appreciation of the viability of the tissues during a long and tedious debridement – before vascular repair is undertaken or while the saphenous vein is being harvested and prepared for grafting.

In addition, during a multiple casualty incident when the rules of triage apply, the use of a shunt may be advantageous. In a true mass casualty influx of patients, with the possibility and even the probability of more casualties arriving the next day, and the next, a temporary shunt may not be the best of choices.<sup>12</sup>

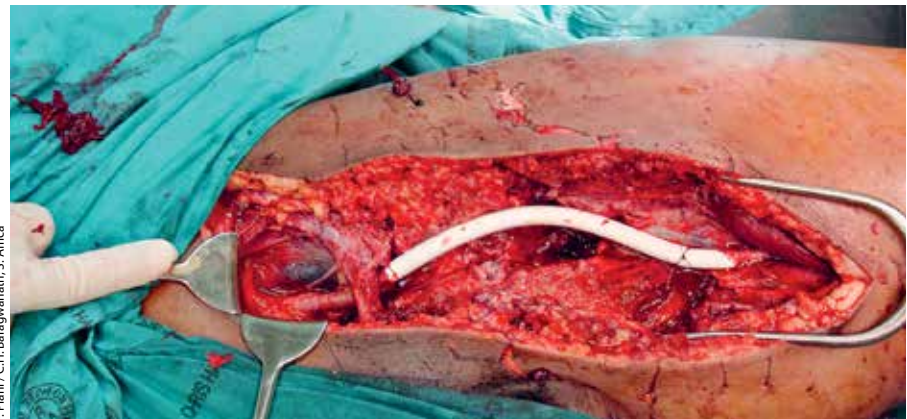### Technique

Distal embolectomy with a Fogarty catheter, the instillation of heparinized saline into the distal vascular tree, and fasciotomy should all be performed beforehand.

To construct a temporary shunt, a sufficiently long piece of i.v. line or other appropriate material (endotracheal suction catheter, naso-gastric tube, paediatric feeding tube, T-tube, etc.) is cut and filled with heparinized saline. This shunt is passed into the proximal and distal ends of the artery, *without debriding the arterial ends*, and kept in place by thick ligatures or Rummel tourniquets. However, when blood begins to flow through the shunt the tube bends and pulsates and simple ligatures often prove inadequate. Therefore, another tie should be placed around the middle of the shunt and fixed to the surrounding tissues. When the time comes for repair, the ligatured ends are debrided appropriately.



N. Papas / ICRG



F. Plani / C.H. Baragwanath, S. Africa

Figures 24.18.1 and 24.18.2

Temporary shunt held in place by ligatures.

A temporary shunt may be left in place for up to 48 hours or more, until definitive repair can be performed at a second operation after stabilization of the patient or once the surgeon feels confident enough to do it; or after transfer of the patient to a better equipped and staffed hospital.

A temporary shunt as a damage-control procedure, rather than ligation, can also benefit a major vein; the shunt permits good outflow of blood from the damaged limb during a critical period.

12 Chapter 9 deals with the triage of mass casualties. However, a distinction should be made between a "multiple casualty incident" where the hospital resources are stretched, but every patient can still be treated to the maximum capacity of the hospital, and a "mass casualty influx" where the hospital facilities are by definition overwhelmed.

## 24.9 Complex limb injuries: concomitant arterial lesion and fracture

Arterial injury combined with a severe fracture presents a therapeutic challenge and leads to a relatively high rate of amputation. Appropriate priorities for surgical treatment must be decided: reperfusion comes before fracture immobilization. In theory, a vascular anastomosis may be disrupted by orthopaedic manipulation and, therefore, the argument has been made to stabilize the bone first. This is a theoretical danger more than a real life one. What is more significant is the tension or slack at the anastomotic line when the limb is finally stabilized at its proper length.

Reperfusion of the limb has priority over fracture immobilization.

Two clinical situations present themselves.

- The first involves relatively stable fractures in which minimal manipulation and discrepancy in limb length is anticipated: immediate vascular repair and a distal fasciotomy before fracture immobilization is not problematic. Afterwards the bone is held either by external fixation, gentle skeletal traction, or a POP posterior splint.
- The second comprises unstable severe dislocations or fractures, which may include segmental bone loss, or massive soft-tissue destruction and contamination. Distal fasciotomy and a temporary shunt to restore perfusion of the limb is a useful first step, to be followed by bone fixation (usually external fixation) and debridement of the wound. Definitive repair of the artery is undertaken when final limb length has been established. These multiple stages may be performed at the same sitting or during different sessions depending on the haemodynamic stability of the patient.

A musculofascial flap should separate a vascular repair from the fracture site. Concomitant nerve injuries are very common, but primary repair is not indicated; tagging of the cut ends is recommended to help identify them later when performing delayed repair (see Chapter 25).

## 24.10 Specific arteries

Junctional trauma is of special concern in that the major artery to the upper or lower limb involves two body regions in a place where proximal digital pressure or the application of a tourniquet is difficult if not impossible: the groin and axilla. A Foley catheter threaded into the missile tract and then inflated may help contain haemorrhage (see Section D.6).

### 24.10.1 Axillary and brachial arteries

The arm is abducted and an infraclavicular incision made from the middle of the clavicle to the distal edge of the pectoralis major along the deltopectoral groove. The dissection is continued between the deltoid and pectoralis major to expose the clavipectoral fascia and pectoralis minor, which are divided to access the axillary vessels and nervous plexus. A temporary shunt is a useful procedure while preparing for the repair. The brachial artery is exposed by an incision in the medial groove between the biceps and triceps.

### 24.10.2 Inguinal region

Rapid laparotomy and clamping of the external iliac artery assures proximal control in the groin. This can also be accomplished by a straightforward vertical incision placed halfway between the anterior superior iliac spine and the pubic tubercle and cutting through the inguinal ligament. Distal control of the femoral vessels does not always stop back-bleeding because of the position of the deep femoral artery. The intact

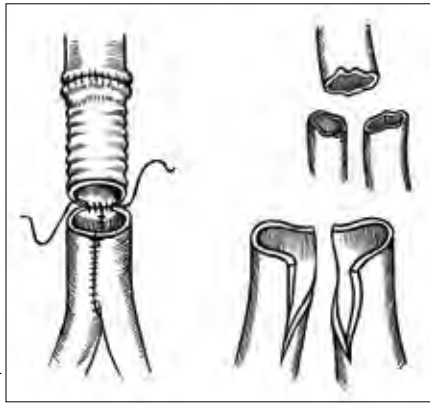


Figure 24.19

Inverted Y-repair at the femoral artery bifurcation.

femoral artery should be dissected proximally up to the site of injury, inspecting the deep femoral along the way.

A temporary shunt is an excellent procedure to control haemorrhage and maintain perfusion of the limb whilst the anatomy is recognized; dissecting out the femoral vessels in the midst of a haematoma is not a simple matter. Ligation of the superficial femoral artery is a possibility, if necessary, since the deep femoral ensures limb perfusion.

Injury at the bifurcation of the femoral artery presents an exceedingly difficult challenge. It is best to join together, side-to-side, the cut ends of the superficial and deep vessels, thus forming a common trunk that can accommodate an interposition graft, known as an inverted Y-repair.

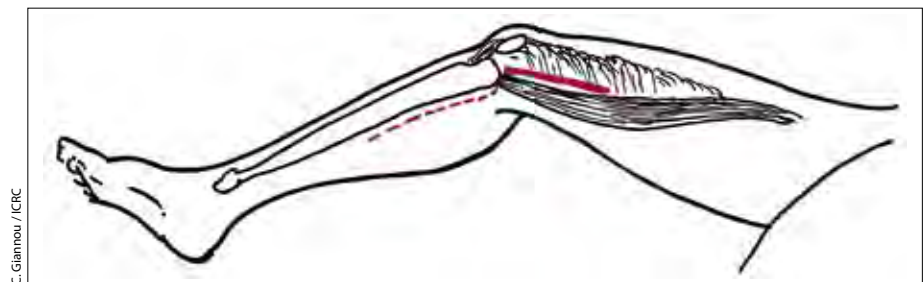
### 24.10.3 Popliteal fossa

The popliteal artery is probably the most difficult to access and repair – and the results of repair the worst. Poor collateral circulation and a cramped anatomy combine to make popliteal injuries the most prone to result in amputation. A fasciotomy should always be performed even as a first step and as part of surgical exposure.

To gain access to the popliteal vessels, two incisions are commonly used: medial and direct posterior. In the first, the knee is flexed 30 – 45°. The incision begins medially in the lower thigh in the groove between the vastus medialis and sartorius and is carried down through the deep fascia behind the femur. It is then continued down as the medial fasciotomy incision to allow for wide exposure of the fossa – if a fasciotomy was performed first, the incision can be extended proximally to expose the vessels.

Figure 24.20

Medial incision for access to the popliteal fossa. The dotted red line is the medial fasciotomy continuation.



The direct posterior approach is a curved S-incision centred on the crease of the knee. However, the anatomy is confining and separate fasciotomy incisions are required.

#### Please note:

If the surgeon has some experience in vascular surgery and as an alternative to direct repair or grafting, the popliteal artery can be ligated proximally and distally to exclude the damaged segment and an extra-anatomic bypass performed using a long saphenous vein graft.

## 24.11 Venous injury

Major veins should be repaired rather than ligated whenever possible in order to re-establish a more normal inflow and outflow of the circulation to the limb. An inadequate venous return increases the peripheral pooling of blood, which results in greater blood loss. In addition, oedema formation and compartment pressure are increased, which in turn readily lead to compartment syndrome.

Seventy-two hours appears to be the critical period for maintaining venous return flow in a major vein, this gives enough time for the development of venous collateral circulation. Failure to maintain it beyond this period is usually of little consequence. Recanalization of a thrombosed vein often occurs spontaneously later on. Both fasciotomy and temporary shunting of the vein are a useful adjunct.



Direct suture of a lateral laceration is often possible because of the large diameter of the main venous trunks; usually only minimal debridement back to viable tissue is necessary. In extensively damaged major trunks, a venous patch graft or an interposition graft is required to avoid excessive stenosis. The ends should be slit longitudinally (spatulation) to allow for a comfortable anastomosis, which need not be as tight as for an artery.

Ligation of a vein is always a possibility.

While ligation presents an increased risk of deep vein thrombosis and pulmonary embolism, reportedly no such risk accompanies repair of a major vein.

### 24.11.1 Specific veins

Certain major veins are particularly prone to complications after ligation: the popliteal in particular, where amputation may prove necessary even after successful arterial repair. The veins of the lower leg below the popliteal, and the forearm, however, may be ligated with impunity.

In veins proximal to the profunda femoris (common femoral, external iliac and common iliac) ligation may lead to *acute venous insufficiency* with massive oedema and the risk of venous gangrene, or the development of chronic venous insufficiency later on. The superficial femoral vein may need to be sacrificed to repair the common femoral or external iliac because the saphenous is usually of insufficient calibre.

Similarly, massive soft-tissue injury of the lower limbs can easily disrupt venous return to such an extent that it compromises the viability of the limb or results in chronic venous insufficiency.

### 24.11.2 Combined arterial and venous injuries

The vein should be repaired or shunted first to allow for free return when arterial flow is re-established. Otherwise there is the danger of venous pooling and stasis with subsequent thrombosis in the capillary bed. The exception is the carotid artery, which can be considered a central artery (see Section 30.8.3).

In combined injuries, repair the vein before the artery.

After repair of a vein and artery, a flap of muscle should be placed *between* the two to prevent the ulterior formation of an arterio-venous fistula.

For a difficult wound, simultaneous venous and arterial shunts may be performed. A fasciotomy is mandatory and best performed early in the operation.

## 24.12 Arterio-venous fistula and pseudoaneurysm

An arterio-venous fistula or pseudoaneurysm may occur acutely, but are more frequently seen in patients presenting late or in cases of missed diagnosis. They tend to occur more often with low-energy small fragment wounds.

### Arterio-venous fistula

If an A-V fistula is encountered, it should be excluded or repaired, although there is a place for conservative non-operative management, depending on the condition of the patient and the experience of the surgeon. Should the limb be viable and show no signs of ischaemia, an A-V fistula may be allowed to "mature", rendering the surgical approach easier and giving time for the full development of collateral circulation; or allowing for referral to a skilled vascular surgeon if possible.

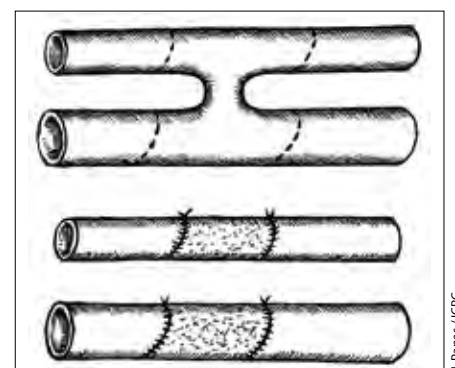
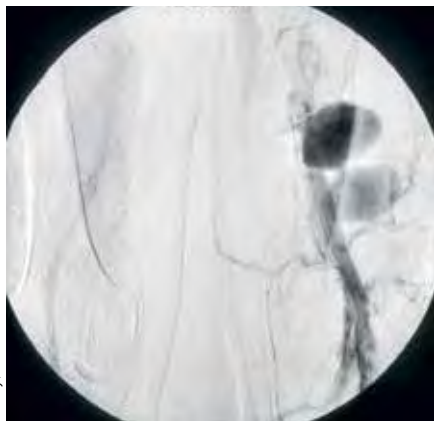


Figure 24.21

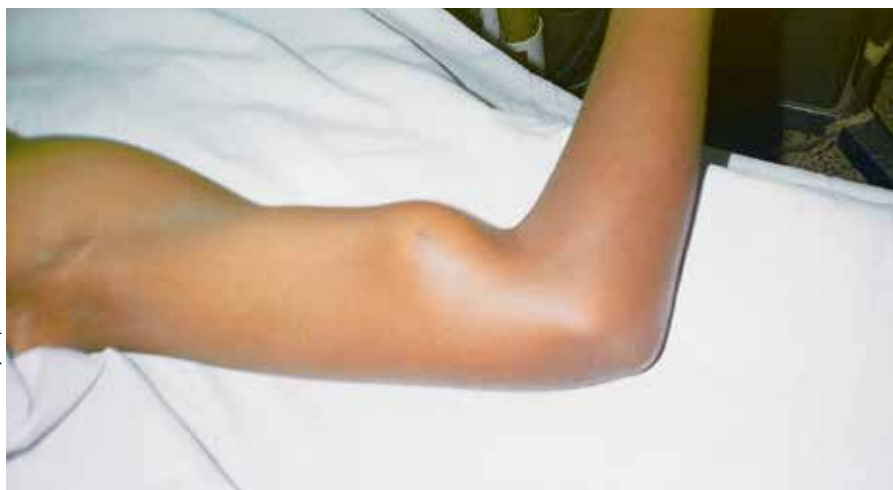Repair of an arterio-venous fistula using double interposition vein grafts.



E. Hmsay / ICRC

**Figure 24.22**  
Contrast scan showing concomitant A-V fistula and pseudoaneurysm.

**Figure 24.23**  
Pseudoaneurysm of the brachial artery just above the cubital fossa.



A. Weidur / General Army Hospital Addis Ababa

Adequate exposure for proximal and distal vascular control is essential.

- An A-V fistula in unimportant vessels can be simply excised and the vessels ligated.
- A small fistula in a more important vessel can be divided and the holes in the artery and vein oversewn, with a vein patch graft if necessary. Quadruple ligation in these cases is an old but effective technique should the vessel walls be too flimsy to hold sutures.
- A fistula in a significant vessel should be excised and the artery and vein repaired by interposition vein grafts; primary anastomosis is seldom possible without tension.

A flap of soft tissue must be placed between the repaired artery and vein.

**Pseudoaneurysm**

A lateral arterial laceration in a confined space may result in bleeding that is contained by the clot, which then becomes organized and transformed into a pseudoaneurysm; the patient presents with a pulsating haematoma.

As always, vascular control above and below the aneurysm must be secured. After clamping the vessel, the aneurysm is opened and the hole in the lumen identified.

- If the hole is small and the wall of the vessel healthy, simple suture or a vein patch can be performed.
- If the hole is big and/or the vessel wall soft, resection of the damaged segment and replacement with interposition of a vein graft is best.
- If resection is not possible, the pseudoaneurysm should be excluded by ligation proximally and distally and an extra-anatomic bypass constructed using a vein graft (Figure 24.24).

Again, initial conservative management to allow the organization of the clot may be the appropriate option, as long as there are no signs of ischaemia.

## 24.13 Complications

The ultimate complications are infection with secondary haemorrhage or thrombosis of the repair leading to ischaemia and amputation.

### 24.13.1 Infection

Infection of the wound is the most common complication and often leads to the breakdown of an arterial repair and haemorrhage or thrombosis. Additional repair should not be performed in the infected site; proximal and distal ligation and resection of the infected arterial segment is mandatory. Occasionally it may be possible to reconstruct the arterial supply in an extra-anatomic location to maintain viability of the limb; otherwise amputation is all too often the only means of achieving haemostasis.

### 24.13.2 Thrombosis

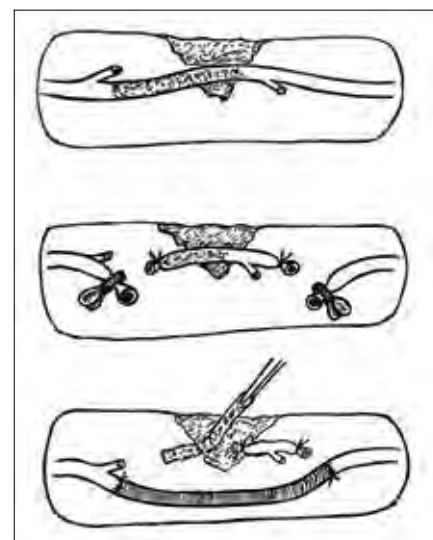
Thrombosis of an anastomotic suture line can be due to infection but is usually due to a technical error that should have been identified before ending the primary operation. Such errors include:

- inadequate arterial debridement;
- residual distal arterial thrombus;
- severe stenosis at the suture line;
- twisting, kinking, or external compression of a vein graft.

The corrective is to re-operate and perform a new repair.

A non-iatrogenic cause is the impossibility to perform a venous repair because of the specific anatomy of the vein, which results in insufficient venous return and acute venous congestion.

A second type of stenosis develops gradually over weeks or months, and is due to intimal hyperplasia at the suture line. A bruit at the site of repair may be heard and the diagnosis is confirmed by angiography. A new anastomosis or graft may be necessary if the stenosis is symptomatizing and producing an ischaemic contracture.



**Figure 24.24**

Extra-anatomic repair after excision of an infected repair.



## **Chapter 25**

# **INJURY TO PERIPHERAL NERVES**

25.	INJURY TO PERIPHERAL NERVES	
25.1	Introduction	227
25.2	Wound ballistics	227
25.3	Pathophysiology	227
25.4	Epidemiology	228
25.4.1	Red Cross Wound Score	229
25.5	Clinical picture	229
25.6	Surgical management	230
25.6.1	Primary surgery	230
25.6.2	Delayed primary suture of a transected nerve	231
25.6.3	Surgical decision-making: delayed operation or not	232
25.7	Surgical technique of nerve suture	233
25.8	Post-operative care	235
25.8.1	Splinting for nerve palsies	235
25.9	Post-trauma sequelae	236
25.9.1	Post-injury pain syndromes	236

## Basic principles

Nerve injuries are often missed in severely injured patients.

Diagnosis is frequently made only during operation, on direct visualization of the lesion.

Primary repair of a sectioned nerve should not be undertaken – ends should be marked with a suture.

Conservative treatment is called for in most injuries – not many require exploration and repair.

Few old injuries are amenable to surgery – proper patient selection is essential.

Physiotherapy is essential to maintain muscle viability and to avoid contractures.

## 25.1 Introduction

Injuries to peripheral nerves occur more often than is commonly realized. Although not life-threatening, they are a major cause of long-term disability. In a low-income country, this will have a particularly adverse socio-economic impact on a person's life. The results of nerve repair are mediocre and few cases are amenable to surgery.

## 25.2 Wound ballistics

Nerves are less fragile than most structures and, like arteries and tendons, tend to “flee” a passing projectile. They are lacerated if struck directly, more frequently by a jagged fragment than by a bullet. It is not uncommon to find a small fragment embedded in a nerve trunk and causing a partial section. However, most lacerations of peripheral nerves in war wounds are caused by the jagged bone ends of fractures.

The effects of temporary cavitation on the other hand are seen more frequently. Cavitation can easily stretch or distort a nerve and provoke neurapraxia or axonotmesis: a “lesion-in-continuity”. Furthermore, the contusion effect on the nerve sheath may lead to softening of the epineurium and longitudinal tears; this is important in terms of surgical nerve repair.

Peripheral nerves are probably the only structure in the body affected by the true sonic shock wave of a high-velocity bullet, as distinct from the pressure wave of the temporary cavity (see Section 3.4.6). Short-lived neurapraxia beginning several hours after injury appears to be the only clinical effect. A similar phenomenon may result from primary blast injury.

## 25.3 Pathophysiology

Projectiles can produce any of the three classical categories of peripheral nerve injury.

### Neurapraxia (nerve concussion or conduction block)

Some demyelination may occur, but the axons remain intact. There is a transient functional loss – physiological paralysis – with spontaneous full recovery. When recovery of nervous conduction takes place, motor and sensory functions return at the same time.

### Axonotmesis (intrathecal rupture of axons)

The nerve sheath remains intact but the axons and their myelin sheath are damaged. Wallerian degeneration of the axons distal to the injury occurs, as well as intraneural fibrosis at the sites of axonal rupture. After an initial period of about ten days, the damaged proximal axons proliferate and grow down into the distal tubules at a very slow rate: approximately 1 – 2 mm per day. Proliferating axons and intraneural fibrosis create a fusiform neuroma-in-continuity in the trunk of the nerve.

Recovery may be full, slow and partial, or may not occur at all. In the last instance, the neuroma completely blocks nervous conduction; recovery is only possible with its surgical removal followed by repair or grafting. Otherwise, recovery occurs in stages: first in the muscle group closest to the site of injury, last in the peripheral skin areas. In all cases, once the axonal fibres reach the motor and sensory end organs there is a three-week delay before their activation occurs.

#### **Neurotmesis (anatomical division of the nerve)**

Division of the nerve trunk may be partial or complete, but all layers – sheath and axons – are affected. The nerve sheath also suffers longitudinal tears extending from the site of division. As with axonotmesis, proliferation of new fibres occurs in the proximal cut end while Wallerian degeneration occurs distally. In addition, the Schwann cells of the distal end proliferate forming a slight bulb. The severed ends retract like those of an artery, while both proximal and distal proliferations try to meet in the plane of division. However, the gap is filled with an organizing haematoma which creates a fibrous tissue obstacle: a neuroma.

In complete division of a nerve, terminal neuroma formation is normal and cannot be prevented. In the particular case of a sectioned nerve in an amputation stump, regenerating axons attempt to re-enter the distal nerve stump, whose absence results in the creation of a terminal neuroma that may prove painful. A partial lesion of the nerve creates a lateral neuroma. In both conditions – terminal and lateral neuroma – spontaneous recovery is just about impossible; surgical resection and repair is the only hope for some recovery of function.

Lesions may exhibit a mixture of neurapraxia, axonotmesis, and neurotmesis.

#### **Recovery and nerve regeneration after repair**

Recovery after nerve repair or grafting is less satisfactory than with axonotmesis; some intraneural fibrosis takes place in the suture line no matter how accurate the surgery, and is increased by any suture-line tension, local inflammation or sepsis. In addition, proliferation of axons into the distal segment is never perfect and creates misallocation between axons and end organs, particularly noticeable in mixed motor-sensory nerves. The rate of nerve regeneration and motor and sensory end organ activation are the same as for axonotmesis.

#### **Perineural fibrosis**

A projectile coming to lie next to a nerve may provoke post-traumatic perineural fibrosis that causes nerve entrapment and compression leading to chronic neurological problems. Entrapment of the nerve in a callus can result in the same conditions. Both may require surgery for relief.

## **25.4 Epidemiology**

Peripheral nerve injuries commonly occur in projectile trauma to the limbs, but do not always involve major trunks. They are rarely isolated but more often found in conjunction with vascular injury and fractures, and more frequently in the upper than the lower limb.

Except when concomitant with vascular injury, the incidence of nerve injuries is poorly documented and the frequency of neurapraxia is usually not recorded. Indeed, a large majority of patients demonstrate “lesions-in-continuity”: contusion due to stretch or compression resulting in neurapraxia or axonotmesis. Spontaneous recovery of function occurs in many of these patients, a recovery often more complete than could be hoped for by surgical management. Thus, experience has taught surgeons to be very conservative in the treatment of these nerve lesions; not many require exploration and repair.



A number of factors influence the results of surgical nerve repair:

- extent of injury (incomplete versus complete transection; need to graft a defect);
- specific nerve involved (mixed or pure motor/sensory nerve);
- aetiology;
- presence of associated injuries (vascular or fracture);
- interval between injury and surgical repair;
- efficiency of physiotherapy before repair;
- age and general condition of the patient;
- type of repair employed;
- availability of diagnostic and operative equipment (electromyography, operating microscope or loupe, etc.);
- skill of the surgeon.

#### 25.4.1 Red Cross Wound Score

The RCWS does not include a category for lesions of peripheral nerves. The Wound Score attempts to correlate ballistic effects with the extent of permanent tissue damage, rather than with physiological parameters.

Nonetheless, one study was carried out on post-operative peripheral nerve recovery following war injuries using the Abbreviated Injury Scale (AIS) and the RCWS. A statistically significant relation was obtained between the functional nerve recovery, the AIS and the scoring for fractures of the RCWS.<sup>1</sup>

### 25.5 Clinical picture

When facing a patient in a life-threatening condition, peripheral nerve injury is of the lowest priority and diagnosis is often missed. The arrival of large numbers of wounded patients and limited personnel, the inability to communicate with a patient in a coma, in shock or in pain and distressed, a lack of reliable diagnostic means, and poor clinical routine are among the other factors leading to a missed diagnosis.

The complete examination of the limb involves a neurological examination, which may be difficult to carry out given the presence of significant soft-tissue and vascular injuries and fractures. The patient's condition permitting, assessment of peripheral nerve function should be performed as accurately as possible prior to initial wound exploration. The distribution of motor and sensory loss should be sought and the degree of loss – partial or complete – assessed, as well as the state of the relevant reflexes. Nerve transection should never be assumed on clinical grounds alone; it can only be correctly diagnosed by direct visualization during operation.

Insufficient perfusion following arterial injury or severe muscle damage may mimic neurological deficit due to nerve injury.

#### Symptomizing extraneural lesions

Volume-occupying lesions such as a pseudoaneurysm or A-V fistula may lead to pressure on or stretching of a nerve resulting in severe pain and progressive loss of neurological function. This is especially the case when they occur in a confined space such as the popliteal fossa or anterior compartment of the lower leg, the axilla, elbow, or volar compartment of the forearm. Similarly, a compartment syndrome creates pressure on a nerve causing local ischaemic changes (see Section B.10).

<sup>1</sup> Mićović V, Stancić M, Eskina N, Tomljanović Z, Stosić A. Prognostic validity of different classifications in assessment of war inflicted nerve injury. *Acta Med Croatica* 1996; **50**: 129 – 132.

## 25.6 Surgical management

Different scenarios must be discussed when dealing with injuries to peripheral nerves: the acute primary surgery stage and the delayed stages, where careful patient selection is of the utmost importance.

### 25.6.1 Primary surgery

Nerve injuries are usually noted incidentally during wound excision. If injury has been diagnosed pre-operatively, an attempt should be made to inspect the appropriate nerve during operation, without however dissecting through healthy tissues. The degree of damage should be recorded.

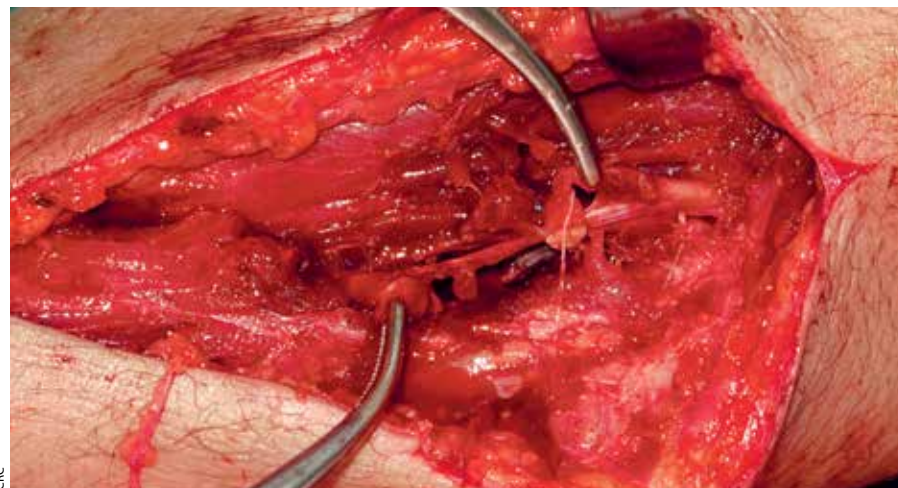
One of two situations will be revealed: either the identified nerve is transected or not.

#### Transection of the nerve: neurotmesis

If there has been complete division of the nerve, the ends are identified but not resected. They should be tacked down with non-absorbable monofilament sutures to *separate* but *adjacent* areas of healthy soft tissue at different levels while maintaining the correct rotation as much as possible. Tacking the severed ends prevents fibrotic retraction of the nerve, thereby maintaining the proper length for eventual repair; and placing them *away* from injured soft tissue and bone helps avoid excessive neuroma formation.

Figure 25.1

Complete division of the radial nerve. Only a thin strand of epineurium remains to join the two severed ends.



An alternative technique is to approximate the cut ends with two non-absorbable stay sutures to maintain the correct rotation of the nerve and then enclose the injured site in an inert tube of some sort (silastic or silicone catheter) to prevent adhesions forming to surrounding damaged tissues.

Primary nerve repair is contraindicated in war wounds.

Nerve repair is contraindicated at the primary stage for a number of reasons.

- There is always a risk of infection in a contaminated war wound, which would render any repair useless and only make subsequent surgery more difficult.
- Extensive dissection to mobilize a nerve for suture without tension may spread contamination and infection.
- The extent of the damage to the nerve is not macroscopically apparent. It is impossible to determine the exact amount of injury with the naked eye; only with time will a proper delineation of the proximal neuroma and distal glioma become obvious.
- The injured nerve sheath is friable: contusion leads to longitudinal tears and softening of the epineurium. With time, fibrosis of the epineurium makes it stronger and better able to sustain suturing.

- Nerve repair is time-consuming and tedious work. When faced with the patient's more severe acute injuries – and other patients – nerve repair is not a priority.

There is one exception: primary repair in the acute phase can be successfully accomplished if the injury is due to a broken shard of glass or a stab wound. This "clean cut" wound can also be closed immediately and not undergo delayed primary closure.

#### **Non-transection of the nerve: lesion-in-continuity**

A contused nerve may exhibit neurapraxia or axonotmesis, which cannot readily be distinguished by observation at operation. A conservative approach is warranted and any decision to repair should be deferred.

#### Please note:

Whether transected or not, exposed nerves should be covered with muscle or fat to avoid desiccation, just like blood vessels and tendons.

#### **Post-debridement and DPC**

Routine follow-up examination of any limb injury after wound debridement should include an assessment of the circulatory and neurological state of the extremity. An injury may have been missed during wound excision. While a vascular lesion may require immediate re-exploration, there is no rush with a missed nerve injury.

Whether or not a nerve lesion was recognized during debridement, a careful examination should be made and the exact sensory, motor, and reflex status recorded, to form a baseline for observation of the evolution of the patient's condition.

The surgeon may seek out a missed nerve injury during DPC, but not by opening up healthy tissue planes. If the injury is located, it should be handled as at wound debridement. The same logic applies to delayed primary closure as to debridement: neither the nerve nor the wound are ready and in an optimal state for repair. Any nerve repair should be deferred until full wound healing.

The aim of surgery at the primary stage – debridement and DPC – is to obtain uncomplicated wound healing with minimum scarring, not nerve repair.

### **25.6.2 Delayed primary suture of a transected nerve**

A nerve known to be transected should be repaired when the wound is healthy and clean and once acute inflammation has subsided, but before irreparable damage has occurred to the motor end plate. Optimally, this is between 3 and 6 weeks post-DPC. However, surgery can wait for up to 3 months, provided certain nursing and physiotherapy protocols are respected.

During this period, the extremity should be kept warm and covered with padding to protect against trophic changes and splinted in a neutral position of relaxation to prevent overstretching of the muscles. Gentle mobilization of the joints and massage of the muscles help prevent contractures. If available, galvanic stimulation of the paralysed muscles by the physiotherapist assists in maintaining their viability.

Contractures must not be permitted to develop.

### 25.6.3 Surgical decision-making: delayed operation or not

Most patients with nerve injuries have suffered a lesion-in-continuity: it is best to wait before deciding on surgical intervention because the majority will recover spontaneously. Some show no improvement at all. Many patients will present with old and healed wounds with a persisting neurological deficit: few cases, however, are amenable to surgery. To a large degree prognosis is determined by the status of the supplied tissues pending nerve recovery or surgery, and the same practices of nursing care and physiotherapy to maintain the tissues healthy apply as for delayed primary suture.

#### The surgeon must remember

- Most lesions-in-continuity do not require surgery: the majority heal spontaneously.
- Very few old injuries are amenable to surgery.
- Correct patient selection for surgery is essential to avoid disappointment when operations are not possible or unlikely to be successful.

The decision to operate on an injured nerve has one of two aims: to improve motor and sensory function or to alleviate neural pain.

#### Restoration of function

Neurapraxia is common and axonotmesis will heal with time. In the latter case, the expected interval before recovery can be estimated by measuring the distance from the likely site of injury to the first muscle group innervated by the nerve: regeneration rate is about 1 mm a day, and the subsequent reactivation of the muscle end plate takes 3 weeks. If no improvement occurs within 6 – 12 weeks with expectant treatment, operative treatment should be considered.

The most widely used diagnostic tool to study motor-fibre injury is electromyography (EMG). This is rarely available when working with limited resources, but in any case it is of no use in the first weeks after injury because Wallerian degeneration requires time to produce the changes of denervation. The primary function of EMG is to help in the selection of patients who may benefit from surgery in the later stages of recovery.

In the absence of EMG, the surgeon should opt for operative exploration. A severed nerve may have been missed; or extensive neuroma formation may have developed. In some cases the nerve may have become entrapped in fibrous tissue, especially adjacent to a repaired blood vessel, or a consolidating callus. Neurolysis, freeing the nerve from the surrounding tissue, may improve the condition and follows the same principle as vascular access: proximal and distal control of a normal part of the nerve trunk and careful dissection down to the abnormal part of the nerve at the site of the fibrous adhesions. The freed nerve is then placed in a new bed of healthy adjacent muscles.

Regular assessment of significant functional impairment after peripheral nerve injury, such as foot or wrist drop, should continue even months after injury. Occasionally, neurolysis, excision of a neuroma, or nerve repair can eventually result in the restoration of some function.

#### Post-injury pain relief

Surgery may be required to alleviate neuropathic pain. Conditions amenable to simple surgery include:

- release of a nerve entrapped in fibrous tissue or a fracture callus
- removal of a bone or projectile fragment lodged in a nerve trunk;
- resection of a painful neuroma, especially in an amputation stump.

Pain may also be iatrogenic, the result of inadvertent nerve ligation or badly applied external fixation.

More complex chronic pain syndromes are initially treated with medication (see Section 25.9.1).

## 25.7 Surgical technique of nerve suture

Nerve repair is properly a specialist technique requiring equipment and materials that are not usually available in resource-poor settings. Whether for primary or secondary repair, it is best to use an operating microscope, loupe or magnifying glasses; sometimes the latter can be improvised. Intra-operative electrophysiological measurements of function – standard in modern neurosurgery – are not often available either. Monofilament nylon suture produces the least foreign body reaction and is best: size 8/0, otherwise the smallest available (6/0 vascular suture material). As for all anastomoses, there should be no tension on the suture line.

Direct anastomosis of cut nerve ends is possible for a gap up to 2 – 3 cm; defects greater than 6 cm require a nerve graft, an even more specialized technique. Defects between 3 and 6 cm can sometimes be overcome by mobilizing the nerve proximally and distally.

Extra length can be gained with some nerves by transposition to a different anatomic position to shorten its course: the prime examples are the ulnar nerve from the back to the front of the elbow and the radial in the upper arm. In addition, the humerus can be shortened to match the radial nerve: this is often possible because the nerve is nearly always injured in relation to a fracture. The head of the fibula may be levelled off to gain length for the peroneal nerve. Slight flexion of the joints helps for the median, radial, tibial and peroneal nerves.

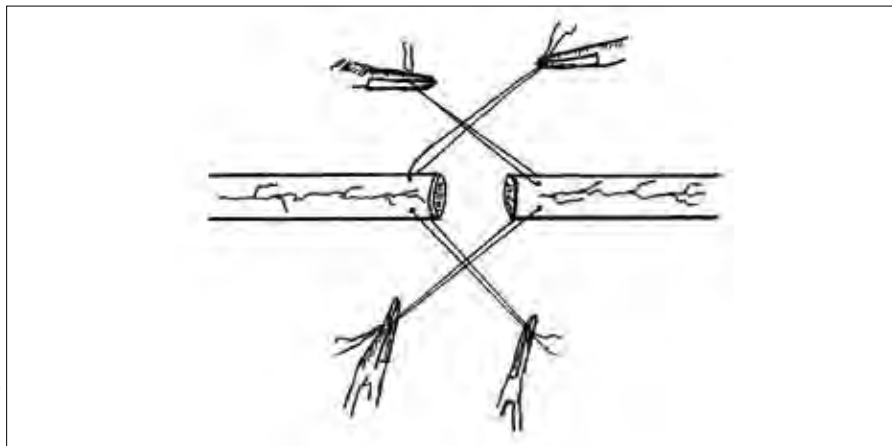
Regional anaesthesia and the use of a tourniquet facilitate the operation.

### Operative technique

1. Access to the healthy nerve trunk proximal and distal to the site of injury usually involves an extended incision through healthy tissue. The nerve should be mobilized by careful dissection following the healthy nerve trunk down through the dense scar tissue that often surrounds the site of injury. Trying to identify the injured nerve in the midst of tough fibrous tissue is difficult and frequently leads to greater damage to the nerve.
2. The proximal neuroma and the distal glioma are trimmed with a new scalpel or razor blade in a “salami slicing” manner – shaving thin slice after slice – until healthy bulging nerve bundles and oozing blood from the cut surfaces appear. Scissors should not be used: besides cutting, they also crush the tissues.

It is best to slice the nerve on a firm flat surface such as that provided by the wooden board used in split-skin grafting. Any excess scarred epineurium is delicately dissected away with fine vascular or ophthalmic scissors.

3. Two interrupted stay sutures (4/0) are placed to approximate the stumps and appose groups of nerve bundles and any small blood vessels on the nerve surface without rotating the nerve.



C. Giannou / ICRC

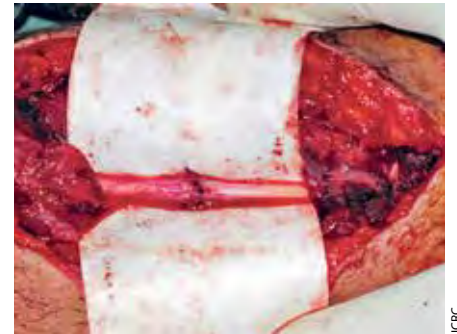

Figure 25.2

Direct suture of a sectioned nerve after mobilization of the two ends.

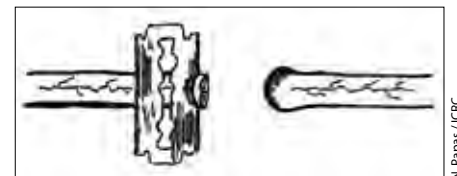


Figure 25.3.1

Trimming the neuroma with a razor blade.

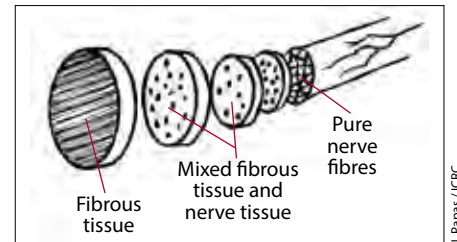


Figure 25.3.2

Successive sections of the neuroma are sliced off until healthy nerve fibrils are reached.

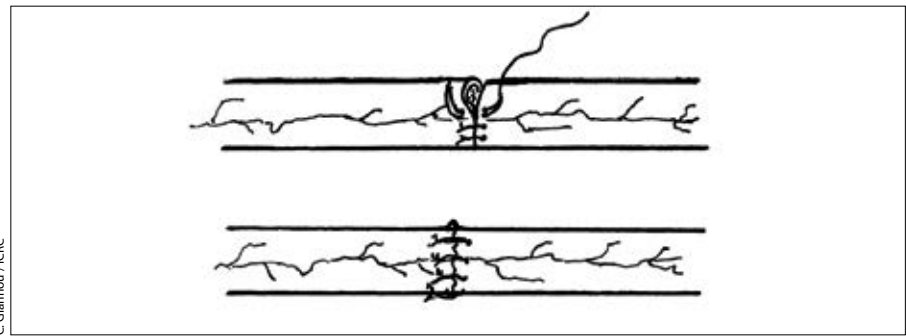
Figure 25.4

Stay sutures should pick up the epineurium only.

- The repair is then completed with the finest sutures available picking up the epineurium only. The number of stitches should be kept to a minimum (3 to 6) as long as the apposition of the nerve ends is accurate.

Figure 25.5

Repair is accomplished with fine sutures taking up the epineurium only.

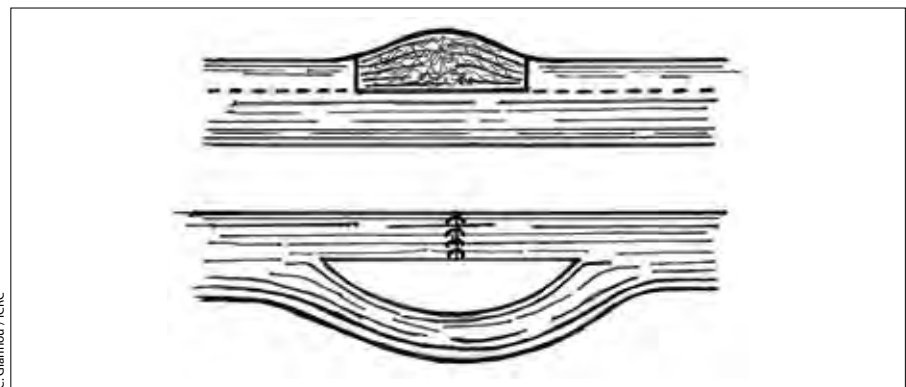


C. Giannou / ICRC

- If a lateral neuroma is encountered, only the injured part should be resected and then repaired as a loop – a difficult and rarely successful procedure.

Figure 25.6

Loop-repair of lateral neuroma.

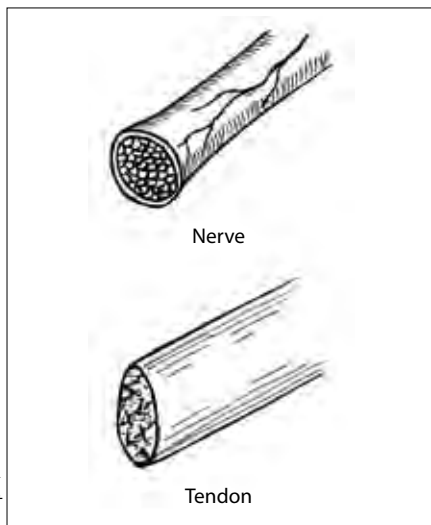


C. Giannou / ICRC

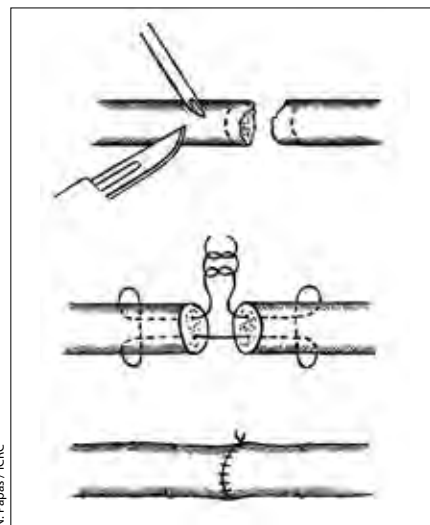
- Finally, the nerve should be positioned in a suitable bed of nearby healthy tissue, usually between two muscles or embedded in a muscle.

Nerves must be differentiated from tendons, at times a difficult task at operation. A nerve is yellowish and more flexible; the cut end bulges out with fibrils and the surface is marked by fine vessels. A tendon glistens a bluish-white and is more rigid and firmer; the cut surface is wood like.

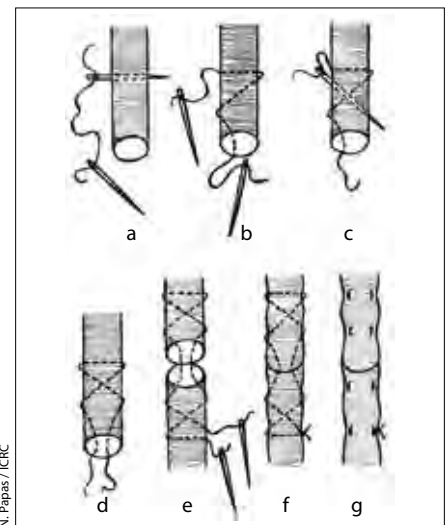
Tendon repair in war wounds should also be a secondary procedure but the operative technique differs from nerve suture.



N. Papas / ICRC



N. Papas / ICRC



N. Papas / ICRC

Figure 25.7

Differentiating a sectioned nerve from a tendon.

Figures 25.8.1 and 25.8.2

Two techniques for repair of a tendon. Use of a hypodermic needle to control the tendon.

## 25.8 Post-operative care

Many long-term pathological changes occur after nerve injuries that influence the management and clinical outcome. The limb must be protected against these changes for nerve regeneration to be successful after the spontaneous recovery from axonotmesis or the repair of neurotmesis. Paralytic disuse of the limb impairs the distal circulation causing the skin to become blue, cold and thin, and the nails brittle. It also results in the formation of peri-articular adhesions around immobile joints. In addition, paralysed flaccid muscles become overstretched owing to the activity of their antagonist muscle groups.

After about three weeks, with the onset of degeneration, the paralysed muscle fibres no longer react to faradic stimulation but still respond to galvanic stimulation. The degenerating muscle fibres are then slowly replaced by fibrous tissue if muscle stimulation is not maintained.

The basis of post-operative care is physiotherapy, to prevent muscle atrophy and tendon shortening and maintain mobility of the joints to prevent contractures. First, the limb should be placed in a padded POP splint for three weeks in a position that relaxes the nerve to a maximum, after which the joints should be gradually extended over a period of several weeks. Active and passive joint movements are then commenced. Limbs held in immobilization for the treatment of a concomitant fracture require mobilization of the proximal and distal joints. Massage of the muscles and galvanic stimulation, if available, should be continued. The limbs must be protected against minor trauma and trophic changes. Patients must be instructed to perform the exercises by themselves and to protect anaesthetized skin.

The patient should be followed up, and an EMG performed if available, every three months until recovery is confirmed. Long-term follow-up is difficult in circumstances of limited resources and a full year is required to know if nerve suture has been a success.

### 25.8.1 Splinting for nerve palsies

Splints to prevent contractures and deformity from nerve palsies can be applied in many situations: when external fixation or traction is used after primary surgery; while awaiting nerve suture or recuperation after repair; and as a palliative measure for irremediable injury.

Splints should be simple:

- a well-padded POP-slab to prevent wrist-drop for radial nerve palsy;
- small improvised aluminium finger-splints to prevent clawing of the fingers in ulnar nerve lesions;
- adhesive tape to hold the thumb in apposition during the night for median nerve lesions;
- night-splint to hold the foot at right angles in sciatic and lateral peroneal nerve lesions.

Splints should be removed several times a day to allow for exercises that ensure a full range of limb movements. Dynamic splints such as a metal cock-up wrist splint or drop-foot spring are particularly useful and may be available at a prosthetic and orthotic workshop.

## 25.9 Post-trauma sequelae

Irremediable neurological deficit is the all too frequent outcome of nerve injuries. Nonetheless, partial compensation often occurs by adjacent muscle groups taking on some of the lost motor function so that the ultimate functional result is better than might be expected. Resorting to nerve grafting is often disappointing: it is a difficult specialist procedure with uncertain results. Tendon transfer operation may be considered in selected patients in case of hand or foot drop after a spontaneous healing period of 18 months. On the other hand, a simpler solution for foot drop is arthrodesis, especially if a dynamic splint is not available.

Sensory trophic changes may lead to chronic leg ulcers, infection and osteomyelitis which, as all such chronic conditions, may best be managed by amputation if a proper prosthesis is available and the patient can be persuaded to accept the operation.

### 25.9.1 Post-injury pain syndromes

Various chronic pain syndromes are frequent after missile trauma to peripheral nerves; more so in mixed nerves than in purely motor ones. Their treatment differs according to cause and type of pain: medication, nerve block, physiotherapy, or surgery. Painful neuromas and phantom limb pain are dealt with in Section 23.11.2. Some forms of neuropathic pain are usually amenable to simple surgery (see Section 25.6.3).

A number of chronic complex pain syndromes can only be diagnosed by detailed clinical examination and various tests, including EMG. The most common is *causalgia*<sup>2</sup> due to incomplete injury or a small fragment embedded directly in a nerve. A reaction may occur within hours to a few days and cause paroxysms of severe burning pain and autonomic changes. At first there is exaggerated skin vasodilatation and hyperhydrosis, followed by vasoconstriction and dryness of the skin, and finally trophic changes in the skin and nails. The pain can become so severe that it causes insomnia and the patient cannot endure the least manipulation of the injured limb. An embedded fragment should be removed, while true *causalgia* is treated medically at first with opiates and then by repeated local anaesthetic injections. The autonomic alterations are relieved by a diagnostic sympathetic block, confirming the need for surgical sympathectomy if resistance to medication grows.

More complex pain syndromes (re-innervation pain, de-afferentation pain, etc.) are mostly treated with medication. Many cases are resistant to treatment. Repeated nerve blocks may be attempted, along with physiotherapy. Depression, insomnia and anxiety may complicate the clinical picture, especially in chronic cases, and are best treated with psycholeptics. Psychological support of the patient is crucial.

2 Also known as complex regional pain syndrome Type II (CRPS II) or reflex sympathetic dystrophy and *causalgia*.







**Part C**

**HEAD, FACE,  
AND NECK**

C. HEAD, FACE, AND NECK

C.1 The general surgeon and the head, face and neck

242

## Basic principles

Head, face, and neck injuries present very different clinical challenges.

The basic principles of head, face and neck surgery are well within the capacity of the general surgeon.

Historically, wounds to the head and neck account for anywhere between 10 and 20 % of war-wounded patients, even though these regions account for only 9 – 10 % of body surface area. A soldier in the prone position exposes only 25 % of the projected body surface area, but the face constitutes a large proportion of this. The wearing of body armour can influence the relative ratios of anatomic distribution, as can the type of combat. Trench warfare and tank battles, where crews expose the upper part of the body to gain better vision, and urban militia warfare with the widespread deployment of snipers, all tend to increase injuries to the head, face, and neck.

The discrepancy in the definition of anatomic regions to be found in much of the surgical literature is described in Section 5.6.2. Wounds in this region are usually grouped together under the general heading “head and neck”. The original ICRC surgical database also used this grouping. Rarely are the categories of head, face, and neck presented separately. Table 5.12 shows two studies concerning fatalities where the categories are distinct.

The distinction is important because head, face, and neck injuries present different clinical challenges. Trauma to the brain kills by several mechanisms: organ destruction incompatible with life; asphyxia due to the comatose state; uncontrolled increase in intracranial pressure; and late infection. Injury to the neck is primarily a problem of the airway, and secondarily of exsanguinating haemorrhage; bleeding in the neck may also compromise the airway if there is external pressure from a haematoma. Lethal face injuries are almost exclusively caused by compromise of the airway, whose obstruction can be due to less than severe haemorrhage.

Recently the distinction between head, face and neck injuries has been made more regularly. US casualties in Afghanistan and Iraq between October 2001 and January 2005 comprised 1,566 patients suffering 6,609 wounds, 30 % of which were to the head, face and neck. Table C.1 gives the anatomic distribution of the wounds. The results demonstrate that the wearing of sophisticated body armour distorts the classical anatomic distribution of wounds.

Body region	Percentage	Accumulated percentage by region
Head	8 %	30 %
Eyes	6 %	
Face	10 %	
Ears	3 %	
Neck	3 %	
Thorax	6 %	17 %
Abdomen	11 %	54 %
Extremities	54 %	

**Table C.1** Anatomic distribution of wounds in 1,566 patients, US armed forces in Afghanistan and Iraq, 2001 – 2005.<sup>1</sup>

<sup>1</sup> Adapted from Owens BD, Kragh JF, Wenke JC, Macaitis J, Wade CE, Holcomb JB. Combat wounds in Operation Iraqi Freedom and Operation Enduring Freedom. *J Trauma* 2008; **64**: 295 – 299.

Wounds to the head, face, and neck not only present very different clinical problems, but also varying degrees of lethality. This is brought out clearly in Table C.2, another study from the US engagement in Iraq covering seven months in 2004, which also separates superficial from vital wounds. Three hundred and thirty-four soldiers suffered a total of 834 battle injuries to the head, face and neck, but only 19 died of their wounds.

Site of injury	Number of wounds (N = 834)	Mortality rate for the site	Died of wounds (n = 60 wounds)	RTD* (n = 296 wounds)
Head	25 % (n = 212)	13.7 %	48 % (29)	23 %
Face	65 % (n = 540)	3.7 %	33 % (20)	68 %
Neck	10 % (n = 82)	13.4 %	18 % (11)	9 %

\* RTD = Returned to duty within 72 hours, the equivalent of a superficial, non-vital injury.

**Table C.2 Analysis of the distribution of head, face and neck battle wounds.<sup>2</sup>**

Most facial wounds received in battle were not significant; the mortality rate was only 3.7% and most patients returned to duty quickly. The few serious injuries, essentially those resulting in an airway that was difficult to control, represented 33% of total deaths; the relatively high percentage being due to the sheer numbers. Head and neck battle wounds both had a mortality rate of over 13%. The head, however, is more exposed to injury than the neck, thus accounting for the much greater absolute number of wounds and of casualties who died of their wounds.

The vast majority of traumatic brain and maxillo-facial injuries worldwide is due to blunt trauma, and mostly the result of motor vehicle crashes. These occur in times of armed conflict as well. For the management of such injuries the reader is referred to standard surgical texts. This Part deals primarily with penetrating injuries and the specific characteristics of the wounds caused by the weapons of war.

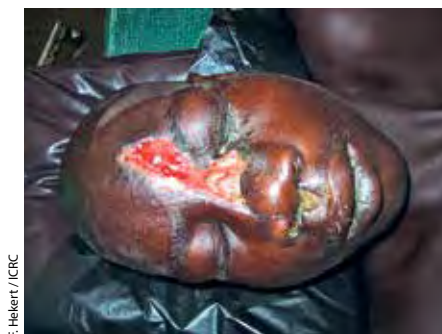## C.1 The general surgeon and the head, face and neck

The general surgeon will usually have only a passing knowledge of the techniques and procedures of neurosurgery, maxillo-facial surgery, ophthalmology, and otorhinolaryngology.<sup>3</sup> Nonetheless, the same solid scientific principles that underlie the treatment of war wounds in general can also be applied to projectile injuries of this region and are well within the competency of the general surgeon. The chapters in this Part describe these principles as adapted to the head, face, and neck and the basic procedures required to treat these injuries.

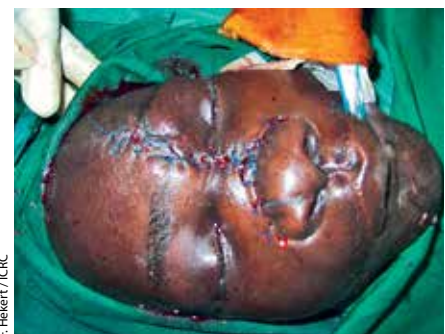The general surgeon working with limited resources must combine the work of a neurosurgeon, ophthalmologist, ENT and maxillo-facial surgeon, at times in the same patient.

**Figures C.1.1 and C.1.2**

Injuries well within the competency of the general surgeon.



F. Heikert / ICRC



F. Heikert / ICRC

<sup>2</sup> Adapted from Wade AL, Dye JL, Mohrle CR, Galarneau MR. Head, neck, and face injuries during Operation Iraqi Freedom II: results from the US Navy-Marine Corps Combat Trauma Registry. *J Trauma* 2007; **63**: 836 – 840.

<sup>3</sup> In this manual both ORL (otorhinolaryngology) and ENT (ear, nose and throat) are used.







## **Chapter 26**

# **CRANIO-CEREBRAL INJURIES**

26.	CRANIO-CEREBRAL INJURIES	
26.1	Introduction	247
26.1.1	The general surgeon and neurotraumatology	247
26.2	Mechanisms of injury and wound ballistics	248
26.2.1	Behaviour of the bone	248
26.2.2	Behaviour of the brain	250
26.2.3	Wearing a protective helmet	250
26.3	Epidemiology	250
26.3.1	Incidence	250
26.3.2	Mechanism of injury and mortality	251
26.3.3	Prognosis	251
26.3.4	Red Cross Wound Score	252
26.4	Pathophysiology	253
26.4.1	Primary and secondary brain injury	253
26.4.2	Cerebral perfusion and oxygenation	253
26.4.3	Intracranial pressure and cerebral oedema	253
26.5	Clinical examination	254
26.5.1	Glasgow Coma Scale	255
26.5.2	Paraclinical investigations	255
26.6	Emergency room management	256
26.7	Decision to operate	257
26.8	Operating theatre	258
26.8.1	Patient positioning and preparation	258
26.8.2	Anaesthesia	258
26.8.3	Theatre equipment and instruments	258
26.8.4	Basic surgical management	259
26.9	Cranio-cerebral debridement: "burr-hole" wound	260
26.9.1	Wound pathology	260
26.9.2	Operative technique	260
26.10	Tangential wounds	263
26.10.1	Pathology	263
26.10.2	Indications for surgery	264
26.10.3	Operative management	265
26.11	Other penetrating wounds	266
26.11.1	Small Grade 1 fragment wounds	266
26.11.2	Transfixing through-and-through wounds	266
26.12	Trepanation	268
26.13	Difficult situations	268
26.13.1	Superior sagittal sinus injury	269
26.13.2	Frontal sinus injury	270
26.13.3	Damage-control neurotraumatology	271
26.14	Post-operative and conservative management	272
26.14.1	Prophylaxis of epileptic seizures	273
26.15	Increased intracranial pressure	274
26.15.1	Management	274
26.16	Cerebrospinal fluid fistula	275
26.17	Infection	275
26.17.1	Neglected wounds	275
26.17.2	Post-operative infectious complications	276
26.18	Primary blast neurotrauma	276
26.19	Post-trauma rehabilitation	277
26.19.1	Patient outcome	277
	ANNEX 26. A Trepanation	278

## Basic principles

Neurotraumatology is not neurosurgery.

Many patients with cranio-cerebral injuries survive with a satisfactory quality of life.

Most cranio-cerebral war wounds are open injuries, which minimizes the risk of intracranial hypertension.

Keeping the airway open is a priority, if necessary by tracheostomy.

Wounds must be debrided to remove dead tissues and bone fragments.

Projectiles found during debridement should be removed; others should be left where they lie.

The dura should be closed watertight after brain debridement, if necessary with a fascial graft.

Care of the comatose patient requires a great deal of effort and is essential for a satisfactory outcome.

## 26.1 Introduction

Head trauma in times of war may be penetrating or closed. Closed head injuries can result from blunt trauma, as seen in civilian life, and after exposure to explosive blast. Penetrating wounds to the head caused by projectiles are the hallmark of war neurotrauma. They produce direct localized brain injury along the missile tract; by contrast, an equivalent release of energy from a blunt blow would provoke diffuse and widespread neuronal injury. Many patients suffering projectile head wounds survive to reach hospital and, after surgical treatment, do very well. This phenomenon has been known since times immemorial.

“And in making the incision you must separate the flesh from the bone where it is united to the membrane (pericranium) and to the bone, and then fill the whole wound with a tent (retractor), which will expand the wound very wide next day with as little pain as possible; and along with the tents apply a cataplasm, consisting of a mass (maza) of fine flour pounded in vinegar, or boiled so as to render it as glutinous as possible.”

Hippocrates (ca 460 – 377 BCE)<sup>1</sup>

It should also be noted, as an introduction, that neurotraumatology is not the same as neurosurgery. The general surgeon with limited resources should not despair and take a fatalistic approach: “the patient has a brain injury and there is not much I can do”. On the contrary, a great deal can be done for many patients with severe head wounds by following a few basic principles of neurotraumatology, which is not the same thing as operating on a brain tumour – the domain of neurosurgery.

### 26.1.1 The general surgeon and neurotraumatology

All too often the blood-brain barrier is not only an anatomic and physiological one in the body of the patient, but also a psychological one in the mind of the surgeon. There is nothing “sacred” or “magical” about the brain, although it is a very sophisticated organ. Some patients survive and live very well even after losing part of their brain following injuries that “appear to render the use of the frontal lobes questionable”<sup>2</sup>, and not only the frontal lobes.

1 *On Injuries of the Head*. Part 14, translated by Francis Adams. Internet Classics Archive, Massachusetts Institute of Technology.

2 Dent CT. Surgical notes from the military hospitals in South Africa: bullet injuries of the head. “A humane war”. *BMJ* 1900; **1** (2043): 471 – 473.

Not too long ago, trepanation for an intracranial haematoma was part and parcel of the normal repertory of operations that a general surgeon could and was expected to perform, and little thought was given about entering the cranium. Surgical training has changed in many countries, such skills now being taught only to the specialist, but the technical competency required to make a burr hole is well within the ability of the general surgeon. Furthermore, most penetrating war wounds that the surgeon encounters among survivors require a *simple debridement of the brain*. The same basic surgical principles that apply to other soft tissues also apply here: once again they are within the technical competency of the general surgeon. There are, however, specific points to take into consideration when debriding the brain, but they are easily learnt.

This chapter deals primarily with cranio-cerebral wounds due to projectiles. There are excellent texts that deal with closed head trauma and, in the present manual, this pathology is mentioned only to make the comparison with penetrating war wounds. Nonetheless, the operative technique of burr-hole trepanation is included (see Annex 26.A). Closed blast neurotrauma is dealt with in detail in Chapter 19; here only a summary of significant clinical points is made.

## 26.2 Mechanisms of injury and wound ballistics

Ballistic research related to cranio-cerebral wounds is particularly difficult because of the lack of an adequate experimental model. Both the skull and the face are constituted of a mixture of heterogeneous bony structures and soft tissues. The juxtaposition of these very diverse tissues means that the same projectile, following different trajectories only millimetres apart, can create lesions that vary greatly.

Survivable injuries are usually caused by low-energy missiles, particularly small fragments, or by bullets at the end of their trajectory or ones that have lost much of their kinetic energy through ricochet. A low-kinetic energy missile results mostly in direct crush and laceration. The development of any temporary cavitation within the cranium causes severe axonal tear and vascular disruption. The ballistic behaviour of foreign bodies mobilized by blast or "rubber-coated bullets", actually steel balls covered by a layer of rubber, is that of fragments.

### 26.2.1 Behaviour of the bone

The skull is a closed box whose walls comprise a vault and a base. The vault is a bony envelope whose thickness varies with site, age, and the individual. The base of the skull has a complex structure with many foramina and air sinuses; in some areas the bone is very thin and delicate and in others very thick and dense.

Different outcomes are possible when a projectile strikes the skull, according to the angle of impact and the bone's elastic reaction.

1. Bone remains intact: tangential wound.

The projectile, almost always a bullet, strikes the head at such an acute angle of impact that it ricochets off the skull producing transitory depression of the bone without a fracture. It is equivalent to a sudden blunt blow to the head and may cause contusion of the underlying brain.

Sometimes, the bullet may remain within the soft tissues of the scalp and proceed circularly, even going right around the head (*le tour du casque*), and then exit or not (see Figures 26.16.1 and 26.16.2).

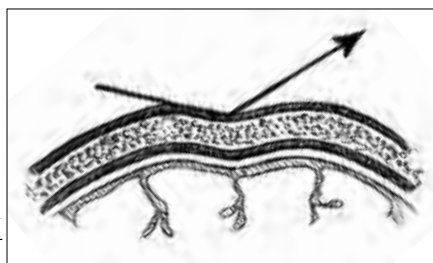
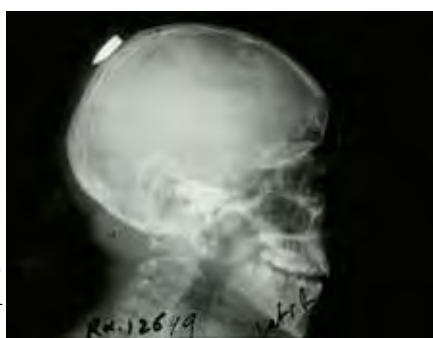
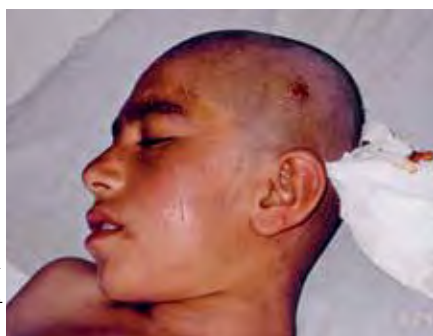
Figure 26.1.1

Low kinetic energy tangential impact.



Figures 26.1.2 and 26.1.3

*Tour du casque*: a bullet has penetrated the left parietal scalp and come to rest at the crown of the skull.

## 2. Fracture of the bone: tangential wound.

If strong enough, the tangential whack on the skull breaks the bone, yet there is still no penetration of the brain substance by the projectile.<sup>3</sup> Splinters of fractured bone may be driven into the brain. The fracture itself is not clinically important – the *underlying* brain injury is.

## 3. Open fracture: tangential wound.

However, an even stronger blow creates an open fracture with a single entry-exit wound; the brain suffers direct laceration and the wound is often “spectacular”, with extrusion of pulped brain substance and haematoma.

Skin, hair, bone fragments, even the cloth from a head covering can be driven into this kind of wound.

## 4. Perforation of the bone and penetration into the brain: penetrating wound.

The projectile perforates the bone and becomes lodged within the cranial cavity because the available kinetic energy is not sufficient for the missile to pass through and exit.

Clinically, the most common presentation is this superficial penetration wound that resembles a “burr-hole” trepanation.

## 5. Perforation of the bone and hemispheric through-and-through wounds.<sup>4</sup>

Unilateral transfixation involves only one cerebral hemisphere; a very severe wound that few people survive.

In bilateral transfixation the projectile crosses the midline affecting both hemispheres; rarely seen by the surgeon because the injury is highly lethal.

Multiple irradiating linear fractures are common with through-and-through wounds because of the propagation of the percussion wave through the diploe of the skull.

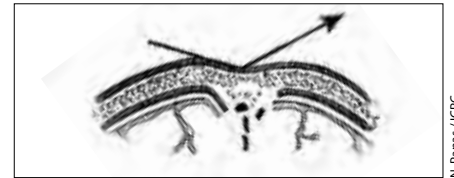

Figure 26.1.4

Higher kinetic energy tangential impact.

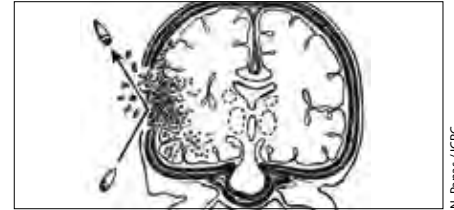

Figure 26.1.5

Tangential penetration: one entry-exit.

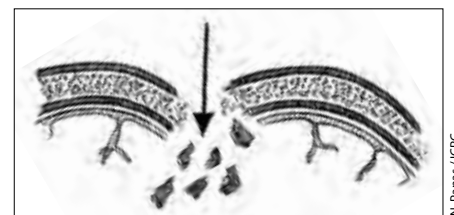


Figure 26.1.6

Perpendicular angle of impact: perforation of the bone and a penetrating injury.

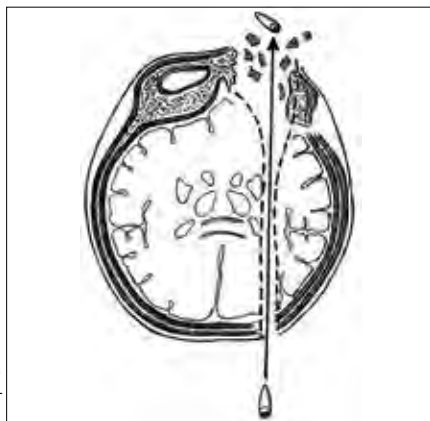

Figure 26.1.7

Unilateral hemispheric transit caused by high kinetic energy bullet: the injury is entirely due to a narrow phase 1 shooting channel, cavitation begins at the exit.

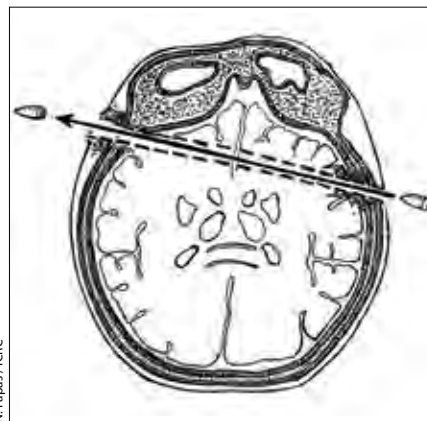


Figure 26.1.8

Bitemporal through-and-through injury: the thin temporal bone offers little resistance to the bullet.

## 6. Penetrating wounds of the base of the skull.

These occur either by a direct hit or by the irradiation of a fracture from an entry wound to the vault. Direct injuries often implicate the upper vertebral column and face.

<sup>3</sup> The energy required to break the skull is 100 – 150 joules; the equivalent of a free fall from 1 – 1.5 m.

<sup>4</sup> The surgical literature can be somewhat confusing. Some authors call these “perforating” wounds, whereas all penetrating injuries have in effect “perforated” the skull. In this manual, the terms “transit”, “transfixation”, or “through-and-through” are used.

### 26.2.2 Behaviour of the brain

The most important prognostic factor is injury to the vital centres, even the smallest lesion of which will bring about rapid death. The cranium can be compared to a closed bony envelope containing a homogeneous fluid medium that does not accommodate any sizeable cavitation. An expansion of the cerebral volume quickly reaches a limit because the elastic displacement of brain tissue is constrained by the rigid skull. When stretched beyond bearing, and owing to what is known as “boundary effect”, the skull literally explodes (see Figure 3.26).

Any temporary cavitation in the limited boundary of the brain results in major damage that is incompatible with life.

Contrary to most arteries elsewhere in the body, the cerebral arteries are held in place relatively rigidly by their surroundings and withdraw little or not at all as the projectile passes by. There are few survivors with direct injury. Slight injury to these can result in the formation of a false aneurysm or an arterio-venous fistula; there are also few survivors.

### 26.2.3 Wearing a protective helmet

A military helmet, even if made of Kevlar®, protects only against low-energy projectiles but high-energy ones will traverse the helmet, become destabilized, and cause more severe injury. Even without penetration, kinetic energy is still propagated into the head and brain as a powerful jolt, like hitting the helmet with a hammer. This is a form of blunt trauma and may cause injury and even death.

## 26.3 Epidemiology

Almost half of all those killed in times of armed conflict have devastating injuries to the head that are incompatible with life. Many, however, have penetrating injuries that are survivable if the airway can be maintained and infectious complications avoided. These wounds require simple procedures and, therefore, the surgeon should first of all focus on these particular cases where a good outcome can be expected with relatively simple measures.

The most common closed injury is a simple brain concussion while the most common penetrating wound amongst survivors is a single low-kinetic energy injury that resembles a burr-hole trepanation. A large number of patients suffer from multiple superficial fragment wounds *and* minor concussion. Explosive blast causes both closed and severe open injuries (see Section 19.5).

### 26.3.1 Incidence

The formula for body surface area exposed to combat trauma gives a figure of 12% for the head and neck, while the historical overall average of head and neck wounds is about 15%, ranging from 4 to 24% (see Tables 5.5 and 5.6). The use of protective head and torso armour by soldiers tends to modify these figures. This is not the case for unprotected civilians and irregular combatants.

In reports from military studies, injuries to the vault vastly exceed those to the base of the skull in patients surviving to reach hospital:

- frontal, temporal and parietal regions 80 – 90%;
- occipital 7 – 18%;
- posterior fossa and base of the skull 0 – 5%.

Although the vault offers much more surface area to injury, these patients are more likely to survive.

### 26.3.2 Mechanism of injury and mortality

Historically, the lethality of penetrating head wounds is close to 80%. Between one-half and three-quarters of those who will die do so within the first 24 hours after injury. However, great progress has been made in reducing post-operative mortality, reflecting improvements in field triage and evacuation, resuscitation and post-operative intensive care as much as operative effectiveness. Hospital mortality rates have fallen from 70% during the Crimean and American Civil Wars, to 28.8% in Harvey Cushing's hands at the end of World War I,<sup>5</sup> to 14% during World War II, and down to 10% for US troops in Korea and Viet Nam.

It was during this last war that a great difference was regularly observed in hospital mortality of patients injured by bullets (presumed to be high-kinetic energy) as compared to fragments (low-kinetic energy). In one study, post-operative mortality was 26.4% for gunshot wounds and 9.5% for fragment wounds.<sup>6</sup> This higher mortality rate (2.5 to 4 times) from military gunshot wounds when compared to shrapnel fragments is confirmed by contemporary studies: 11.5% for gunshot wounds and 5.1% for fragments.<sup>7</sup>

The propensity to increased incidence of fragment wounds in contemporary conflicts, and therefore survivability, is brought out in Table 26.1, while guerrilla or urban warfare (Turkey, Lebanon, and Croatia) tends to increase the percentage of gunshot wounds.

	USA Hammon, 1971.	Lebanon Haddad, 1978.	Iraq Ameen, 1984.	Iraq Abdul- Wahid, 1985.	Iran Aarabi, 1989.	Israel Brandvold et al., 1990.	Croatia Marcikic et al., 1998.	Ethiopia Bogale, 1999. <sup>8</sup>	Turkey Erdogan et al., 2002.
N =	2,187	219	110	500	379	113	197	102	374
Bullet %	16	37	10	3	11	16	27	17	32
Fragment %	82	63	90	97*	72	74**	61	48 mine 35 mortar	68
Other or undetermined %	2	–	–	–	17	9***	12***	–	–

\* Single fragment 86%; multiple fragments 11%.

\*\* Including 3 patients with in-driven stones and one with an in-driven radio antenna mobilized by blast.

\*\*\* Tangential wounds.

**Table 26.1** Wounding agent in penetrating head wounds during a selected number of modern conflicts. References are to be found in the Selected bibliography.

### 26.3.3 Prognosis

The lethal potential of any penetrating injury to the brain is obvious. Nonetheless, certain factors are attended by a worse prognosis as attested by numerous epidemiological studies. These factors can be either general with respect to all brain trauma or specific to projectile wounds. General factors include hypoxia, age, other injuries, complications and comorbidities, which can influence the results of the Glasgow Coma Scale (GCS).

Factors more specific to projectile wounds include the following.

- Injury due to high-kinetic energy projectile.
- Injury of the posterior fossa or the base of the skull.
- A trajectory that involves a bilateral hemispheric transit, the projectile crossing the midline. One exception: bilateral frontal lobe injuries.

5 Harvey W. Cushing (1869 – 1939), neurosurgeon who served with US troops in World War I, often called the "father of modern neurosurgery". His description of debridement of a penetrating war wound is still the basis for contemporary practice.

6 Hammon WM. Analysis of 2187 consecutive penetrating wounds of the brain from Vietnam. *J Neurosurg* 1971; **34**: 127 – 131.

7 Erdogan E, Gönül E, Seber N. Craniocerebral gunshot wounds. *Neurosurg Quart* 2002; **12**: 1 – 18.

8 Bogale, Solomon. Management of penetrating brain injury: experience in the Armed Forces General Hospital, Addis Ababa. Personal communication, 1999.

- A trajectory that involves a unilateral hemispheric transit.
- Lesion of the lateral ventricle.
- Intracerebral haematoma.
- Traumatic aneurysm or arterio-venous fistula.
- Air bubbles disseminated in the brain substance at a distance from the projectile trajectory visible on X-ray. This is usually due to the entry of gas under pressure from a shot at point-blank range or cavitation effects.

**Post-resuscitation GCS**

The pre-hospital GCS score is useful to monitor the adequacy of first aid and the evolution of the patient, but it is the GCS score *post-resuscitation* that is truly prognostic. Poor outcomes are associated with:

1. total score  $\leq 8$
2. motor score  $< 3$
3. eye opening  $< 2$
4. verbal response  $< 2$
5. pupils: dilated or abnormal response to light

The relevance of the prognostic value of GCS after full resuscitation is given in Table 26.2 based on civilian gunshot injuries in South Africa, where CT scan was available.

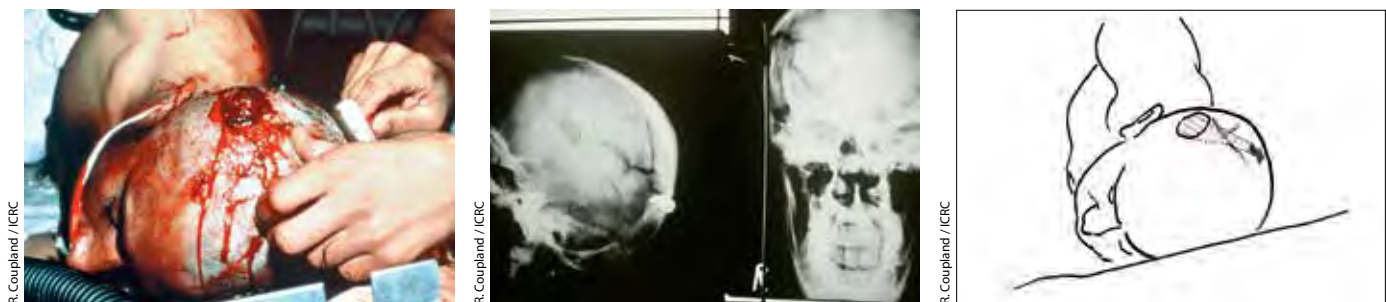GCS	Mortality
3 – 5	98 %
6 – 10	31 %
11 – 15	8 %

Table 26.2 Post-resuscitation Glasgow Coma Scale and mortality rates.<sup>9</sup>

In addition to the GCS score, certain specific pathologies in this study were found to be significantly related to mortality: trans-ventricular injury (100 % mortality); bihemispheric injury (90 %); and diffuse brain oedema (81 %).

**26.3.4 Red Cross Wound Score**

Penetration of the meninges is considered a vital wound putting into jeopardy the patient’s life. The notation in the RCWS is V = N. Fracture of the skull is also noted in the F score. Of course, blunt trauma and blast injury too can be life-threatening, but the RCWS is only applicable to penetrating wounds.



Figures 26.2.1 – 26.2.3

Example of the RCWS applied to a penetrating head wound: E3 X0 C0 F2 VN M1.

<sup>9</sup> Adapted from Semple PL, Domingo Z. Craniocerebral gunshot injuries in South Africa – a suggested management strategy. *SAfr Med J* 2001; **91**: 141 – 145.



## 26.4 Pathophysiology

### 26.4.1 Primary and secondary brain injury

Traumatic injury to the brain is described as being primary or secondary. Primary injury is due to organ damage and can be direct in the case of blunt or penetrating wounds, or indirect when due to acceleration, deceleration, and rotational forces causing brain impacts (counter-coup) on the inner surface of the skull. Both play a part in ballistic wounds.

Secondary injury is the result of various physiological and metabolic factors including hypoxia, ischaemia, disruption of the blood-brain barrier, changes in cellular transport and ionic gradients, etc. Secondary injury, which begins from minutes to days after the primary insult, is responsible for most deaths and most subsequent dysfunction of the central nervous system (CNS) in patients surviving to hospital.

### 26.4.2 Cerebral perfusion and oxygenation

The brain is a soft jelly contained within a solid, closed box. There is a normal physiological balance between contents of the cranial cavity (brain, blood, and cerebrospinal fluid) and the general circulation. Constant blood flow to the brain resulting in good perfusion and oxygenation is critical to life, and is a function of this balance.

$$\text{Cerebral blood flow} = \frac{\text{Cerebral perfusion pressure}}{\text{Cerebral peripheral resistance}}$$

$$\text{Cerebral perfusion pressure} = \text{Mean arterial pressure} - \text{Intracranial pressure}$$

Hypoxia is the most important factor for determining secondary brain injury, whatever the cause of the hypoxia. Numerous studies have shown that the intensity, duration, and number of episodes of hypoxia in the early post-injury period greatly increase mortality and morbidity.

Therefore, the prevention of secondary brain injury by maintaining adequate cerebral perfusion and oxygenation is the key to patient management. The actual level of cerebral ischaemia associated with irreversible brain damage has not been defined.

Hypoxia, whatever the cause, leads to a poor outcome.

It follows that the categorization of a patient during resuscitation according to the Glasgow Coma Scale should only be attempted once the blood pressure has been raised to 90 mm Hg and supplemental oxygen is being administered, if available. In practice this amounts to the patient's *post-resuscitation GCS*.

### 26.4.3 Intracranial pressure and cerebral oedema

Oedema is the normal reaction of the brain to injury of any sort. Increased intracranial pressure is usually associated with closed head trauma; it is rare with penetrating injury, except for wounds with a very small opening.

Significant brain oedema only begins after 6 hours in penetrating wounds. Furthermore, the cranium with an open wound no longer represents a closed box and damaged brain is often extruded, thus decreasing cerebral volume.

A large open wound of the brain drastically changes the physiology of cerebral perfusion pressure and intracranial pressure.

After hypoxia, increased intracranial pressure is the next main factor involved in secondary brain injury.

## 26.5 Clinical examination

“And in addition to the appearances in the bone, which you can detect by sight, you should make inquiry as to all these particulars (for they are symptoms of a greater or less injury), whether the wounded person was stunned, and whether darkness was diffused over his eyes, and whether he had vertigo, and fell to the ground.”

Hippocrates

In the absence of sophisticated diagnostic and monitoring technology, a thorough and systematic clinical examination is essential and remains the basis of patient management.

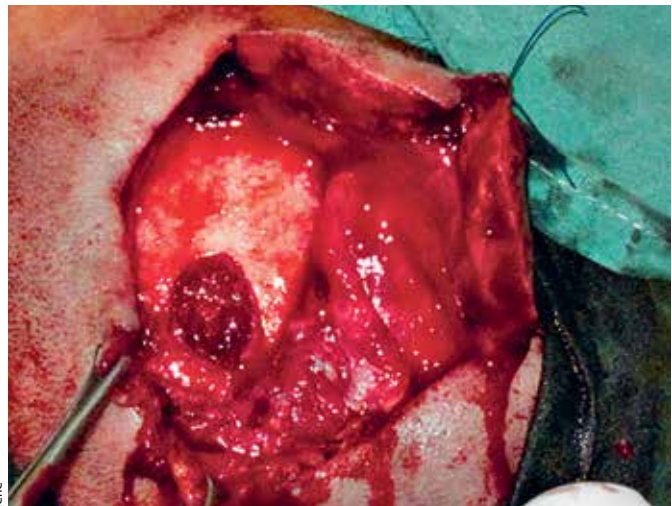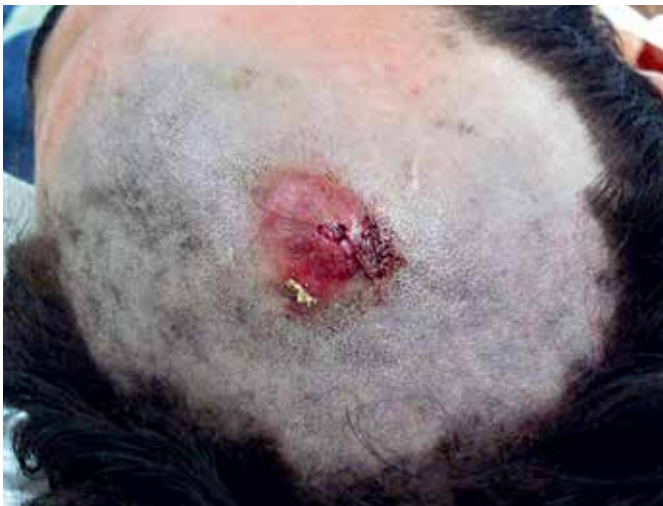The ABCDE sequence of the initial examination is the standard procedure. Any compromise of consciousness immediately becomes an airway problem, with all the dire consequences of hypoxia.

In blunt trauma involving the head, proper care of the cervical spine is necessary; this is not the case with penetrating head wounds (see Sections 7.7.2 and 36.5).

Rarely is blood loss from the scalp sufficient to cause shock, except in children. The superficial temporal artery, nonetheless, can lead to severe haemorrhage; applying digital pressure and placing a simple clamp can be a lifesaving procedure. However, concomitant penetrating spine injury may be the cause of neurogenic shock: normovolaemia with hypotension (see Section 36.3.2).

### Old lesson for new surgeons

Haemorrhagic shock is rarely due to blood loss from the head. Look elsewhere.



Figures 26.3.1 and 26.3.2

This small wound and the underlying depressed fracture were only apparent on close palpation of the skull and after shaving the head.

The complete examination includes a meticulous palpation of the head. The difficulty in diagnosing a small fragment entry wound in the vault has been noted (see Figure 8.6). All lacerations of the scalp should be thoroughly palpated; this may be the only way to discover a depressed fracture of the skull or a small entry hole.

**Old lesson for new surgeons**

Small wounds may conceal severe injury: "bad things can happen through small holes".

Once the patient is stabilized, a more complete neurological examination comprises the parameters of the Glasgow Coma Scale, any lateralizing signs, and the status of the cranial nerves.

**26.5.1 Glasgow Coma Scale**

The Glasgow Coma Scale (see Table 8.4) was originally established for patients with closed head injury, yet it has proven a useful clinical tool for penetrating trauma as well.<sup>10</sup> Although several studies have shown that the inter-rater reliability is poor, the GCS is nonetheless particularly useful for monitoring the *evolution* of the patient's condition, especially if it is repeated by the *same* doctor or nurse. It is the post-resuscitation GCS that should serve as the baseline, and that gives the best prognostic value.

**Categorization of head injury severity<sup>11</sup>**

- Minimal: GCS = 15, with no loss of consciousness or amnesia.
- Mild: GCS = 13 or 15 with either brief loss of consciousness or impaired alertness or memory.
- Moderate: GCS = 9 – 12, or loss of consciousness greater than 5 minutes, or focal neurological deficit.
- Severe: GCS = 5 – 8.
- Critical: GCS = 3 – 4.

It is the patient who presents a post-resuscitation mild or moderate severity injury and who then deteriorates that should be the focus of the surgeon's greatest efforts. The pathology is usually reversible and the outcome is frequently positive.

Please note:

A decrease in the level of consciousness may be due to factors other than the head injury: severe shock, alcohol, drugs, and medications.

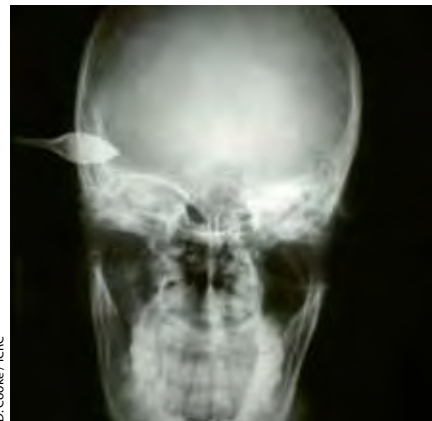
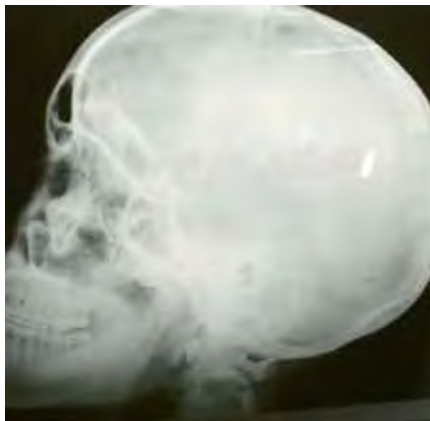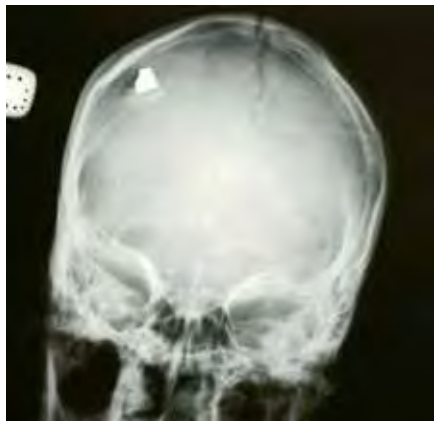**26.5.2 Paraclinical investigations**

Radiographs should be taken of the head and include antero-posterior and lateral views. A CT-scan is rarely available where resources are limited.

When examining entry wounds, the inner table of the skull always appears more fractured than the outer table, while the opposite is the case for exit wounds. Fractures irradiating from the wounds are a sign of severe injury. However, X-rays give little information about intracranial lesions and fractures of the base of the skull. In the absence of an exit wound, X-rays of the head may show the position of the metallic missile/s and thereby help estimate the projectile tract and related damage.

10 Teasdale G, Jennett B. Assessment of coma and impaired consciousness. A practical scale. *Lancet* 1974; **2**: 81 – 84.

11 Adapted from Jarell AD, Ecklund JM, Ling GSF. Traumatic Brain Injury. In: Tsokos GC, Atkins JL, eds. *Combat Medicine: Basic and Clinical Research in Military, Trauma, and Emergency Medicine*. Totowa, NJ: Humana Press; 2003: 351 – 369.



Figures 26.4.1 and 26.4.2

Knowing the location of a fragment can be of assistance in some patients. Here a fragment was found just under the skull.

Figure 26.4.3

In this case, a spear head has penetrated the skull.

However, for the great majority of cases of penetrating trauma, even plain X-ray radiography is not essential for deciding whether or not to operate, and for operating effectively.<sup>12</sup>

## 26.6 Emergency room management

The aim is to minimize secondary brain injury through standard principles of resuscitation. Most of the mortality from head injury, apart from direct immediate organ destruction, is associated with secondary injury resulting from hypoxia and hypotension.

More initial survivors die from secondary brain injury than from primary tissue damage. Many of these deaths are avoidable.

The patient may have to be intubated to maintain the airway and control breathing: severely-injured patients (GCS  $\leq$  8) require a definitive airway. Supplemental oxygen should be administered if available.

Once a patent airway has been assured, the surgeon must ascertain whether the patient is breathing spontaneously or not. Assisted ventilation by “bagging” the patient may be required. The prevailing circumstances will determine how long such manual ventilation can be maintained (see Part F.3). In a situation of triage of mass casualties, a patient requiring ventilation to survive is classed Category IV and is treated “expectantly” (see Chapter 9).

Maintain oxygenation, ventilation and blood pressure: prevent brain hypoxia and ischaemia.

Ensuring optimal cerebral perfusion requires a mean arterial pressure greater than 70 mm Hg, which implies a systolic pressure of 90 mm Hg. This may be problematic if other injuries and blood loss are pushing the surgeon into attempting hypotensive resuscitation (see Section 8.5.4). The surgeon must perform a “therapeutic juggling act” to try to resuscitate and maintain cerebral perfusion without provoking increased haemorrhage in another body cavity, particularly the abdomen.

In an attempt to remedy this, some researchers have used limited quantities of hypertonic saline, with and without dextran, for resuscitation. ICRC surgical teams have no experience of such measures and cannot comment. No dextrose in water should be given; it is hypotonic and increases cerebral oedema.

<sup>12</sup> Many ICRC surgeons have had to operate without the benefit of radiography. Diagnostic imaging is not a prerequisite for performing good war surgery.

The bladder should be catheterized to monitor urine flow and the adequacy of resuscitation, and to avoid irritability. Many patients have been administered sedatives when in fact the problem has been discomfort from a full bladder. True irritability or restlessness, not due to hypoxaemia or an overfull bladder, is treated with diazepam or pentazocine as necessary.

A naso-gastric tube should be placed to empty the stomach and avoid vomiting and aspiration. Care should be taken if there are fractures involving the ethmoid sinuses or base of the skull.

Anti-tetanus prophylaxis and antibiotics should be given as per protocol.

In penetrating projectile injuries, it is rare to have to resort to mannitol or diuretics; these should never be given as a routine in any type of traumatic brain injury and are best administered only to *buy time while awaiting urgent surgery*, and only under proper supervision. Steroids are contraindicated.<sup>13</sup>

## 26.7 Decision to operate

Priority for surgery is given to other life-threatening lesions involving the airway, breathing or circulation. Life-threatening neurological lesions requiring immediate surgery are few: for example a rapidly expanding intracranial haematoma with tentorial herniation, but most frequently seen with blunt rather than penetrating trauma.

More than one injury: control haemorrhage elsewhere first!

As for the management of the penetrating head injury itself, this should be determined by the nature of the injury as well as by the clinical status, but a few general principles apply.

- The initial procedure should be the definitive one to the extent possible. A damage-control approach for difficult bleeding may have to be adopted in rare cases.
- Small, punctate wounds of the vault with no signs of intracranial space-occupying haematoma should not be operated. The patient should be closely monitored for any deterioration of consciousness or CSF leakage.
- Patients with a post-resuscitation GCS of 13 – 15 who deteriorate have first priority for surgery.
- Patients with a GCS > 8 should be treated aggressively with surgery.
- Patients with a GCS of 3 – 5 should receive supportive conservative treatment unless the condition is associated with an operable haematoma.
- Patients with a GCS 5 – 8 are the main focus of therapeutic controversy – and frustration. Some surgeons propose to wait 24 hours, while maintaining an adequate airway and oxygenation, and then “look see” and decide on whether to proceed to surgery or not: improvement means operative intervention; deterioration implies supportive treatment only.
- The nature of certain wounds – clinico-pathological type – allows for greater or lesser degrees of surgical aggressiveness.

The surgeon should focus on patients with GCS 9 – 13.

An open head wound is often awe-inspiring, but might be much less severe than thought at first. Post-resuscitation GCS is the best indicator of prognosis, particularly important in setting priorities during triage of mass casualties. Most survivable wounds are classed Category II: they require surgery but can wait, provided a good airway is maintained.

<sup>13</sup> CRASH Trial Contributors. Final results of MRC CRASH, a randomised placebo-controlled trial of intravenous corticosteroid in adults with head injury – outcomes at 6 months. *Lancet* 2005; **365**: 1957 – 1959.

## 26.8 Operating theatre

### 26.8.1 Patient positioning and preparation

The head should be entirely shaved and draped in such a fashion as to allow extension of the scalp incision and manipulation of the head by the surgeon or anaesthetist.

For wounds of the parietal or temporal regions, the patient should be put in the lateral position; for the occipital region and posterior fossa, lying on the face. Patients can be placed supine; however, excessive tilting or lateral rotation of the head should be avoided so as not to impede blood flow into and out of the brain. It may be necessary to place pillows between the scapulae or under a shoulder.

The table should be tilted so that the head is elevated above the heart to promote venous drainage.

### 26.8.2 Anaesthesia

Except in the most minor and superficial of wounds, it is best to intubate the patient if anaesthesia resources allow. With intubation the anaesthetist must at all times control the patient's ventilation and oxygenation by gentle "bagging". Controlled ventilation prevents coughing, retching and respiratory effort, all of which raise the ICP.

Hyperventilation should be avoided except when visible signs of *brain herniation* or severe *oedema during operation* develop. Short-term mild hyperventilation is the best means to control increased ICP. Mannitol can also be used, provided systolic BP is maintained above 90 mm Hg. However, as mentioned, penetrating war injuries to the brain are open wounds and, especially in large ones, these measures are not usually necessary. Steroids are neither needed nor advisable.

Anaesthesia with intubation can be gas inhalation or ketamine, depending on what is available and in common use in the hospital. Contrary to old reports suggesting the opposite, ketamine is a safe drug for anaesthesia in head trauma (see Section 17.4.1) and can even be used under spontaneous ventilation when intubation is not available, in which case a tracheostomy should be considered to ensure a safe airway and control the respiration.

*In extremis*, local anaesthesia of the scalp, pericranium, and meninges can be employed, aided by a sedative (thiopentone, diazepam, etc.). The brain itself has no pain receptors.

### 26.8.3 Theatre equipment and instruments

A few simple pieces of equipment are of great assistance: an operating table with a head that can be tilted up and down manually; low-power suction, electric if available or otherwise a large syringe (60 – 100 ml); diathermy is "nice to have".

When dealing with open head injuries, the only essential specific instrument is the bone nibbler.

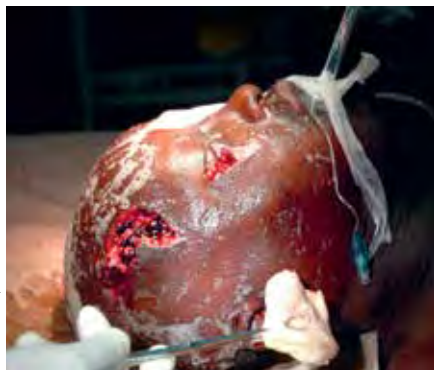
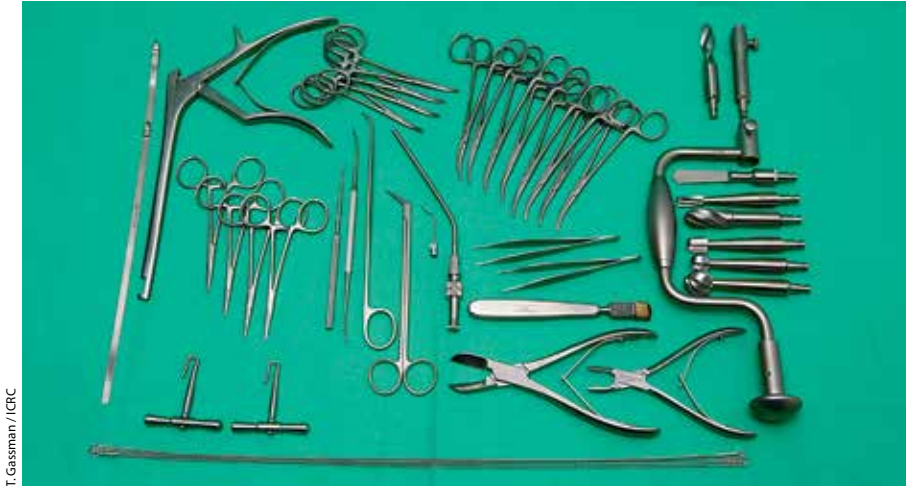
Figure 26.5

The head of the patient has been shaved and is being washed with soap and water before application of povidone iodine.



**Figure 26.6**  
ICRC craniotomy set.

T. Gassman / ICRC

A simple set of essential instruments for neurotraumatology consists of:

- hand drill (Hudson brace)
- cranial perforator or trephine
- burrs of different sizes and shapes: cylindrical and round
- dural elevator
- periosteal elevator
- bone nibbler or rongeur
- Gigli wire saw and handles

#### 26.8.4 Basic surgical management

The discussion on wound ballistics demonstrates the wide variety of projectile wounds to the brain. However, the fundamental surgical techniques are relatively limited and basically the same for all: trepanation, debridement of the scalp, cranium and brain, and primary closure.

“The same principles of *débridement* utilized so successfully for wounds elsewhere have in their essentials been adapted to wounds involving the brain.”

Harvey W. Cushing<sup>14</sup>

Much ado has been made about retained bone and metal fragments. Bone fragments are more important as a cause of infection; far worse is the contamination from skin and hair. Some metal fragments have been reported to migrate, causing more damage, but the occurrence is exceedingly rare. Re-operation to remove retained projectiles or bone fragments should be undertaken only if there is an associated complication: infection, CSF leak, mass effect, or confirmed evidence of lead toxicity (see Section 14.3). Otherwise, as elsewhere in the body, they should be left where they are unless readily accessible.

The “burr-hole” wound is probably the most common projectile lesion of the brain that the surgeon encounters during armed conflict. It also best demonstrates the basic operative techniques required for almost all projectile wounds. Therefore, the following Sections use the debridement of the “burr-hole” wound as a demonstrative example.

14 Cushing H. A study of a series of wounds involving the brain and its enveloping structures. *Br J Surg* 1918; 5: 558 – 684.

## 26.9 Cranio-cerebral debridement: "burr-hole" wound

The prognosis for many such wounds is good. The patient often remains lucid and, depending on the exact location of the cerebral lesion, may even walk into the emergency room. Surgical intervention should always be contemplated.

### 26.9.1 Wound pathology

The ballistic profile is similar to that of a fragment, or deforming or destabilized bullet but with low-kinetic energy. The entry wound is much larger than the diameter of the projectile and the lesion in the skull has the appearance of a punched out burr-hole, hence the descriptive name. There is a "cone" of tissue destruction comprising pulped brain and haematoma, hair and the skin of the scalp and bone fragments. Protrusion of the brain outside the skull is often seen: cerebral hernia or *fungus cerebri*.

The penetration of the projectile into the brain may be as little as 1 cm or far deeper, and is always more distant than any bone fragments. The rounded tip of a bullet tends to push aside the neurons at the end of its trajectory and is therefore to be found more distally within undamaged tissue. Metallic fragments have irregular and sharp edges that lacerate the brain even at the end of the wounding channel as they come to a stop. Bone fragments are always to be found within the "cone".

### 26.9.2 Operative technique

The operative procedure unfolds layer by layer: scalp, bone, dura, brain tissue.

#### Scalp incision

Inspection of the damaged brain requires a wide exposure and two different incisions are described: the inferiorly-based horseshoe flap or "U"-incision with the wound at its centre or the "S"-extension incision going through the wound. Both have advantages and disadvantages. In the practice of ICRC surgeons, the horseshoe incision is usually preferred for large wounds; and the "S"-incision chosen for small wounds and trepanation. The site of the scalp incision can be infiltrated with a dilute adrenaline solution to help control bleeding.

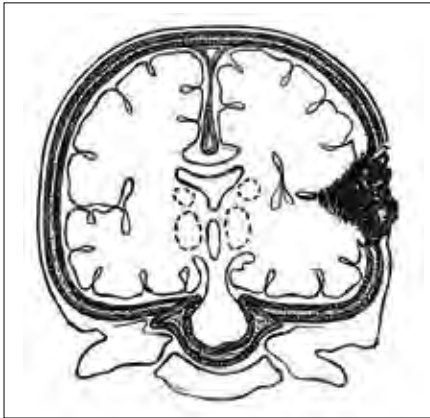


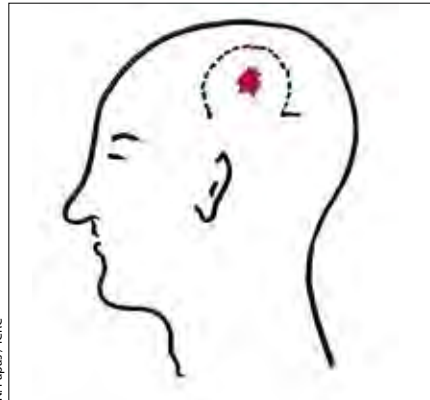
Figure 26.7

Superficial penetration, burr-hole type: note the "cone" of tissue destruction and the presence of the projectile in the depth of the wound.

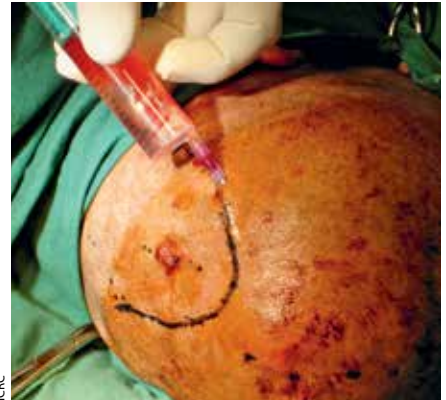N. Papas / ICRC

Figures 26.8.1 and 26.8.2

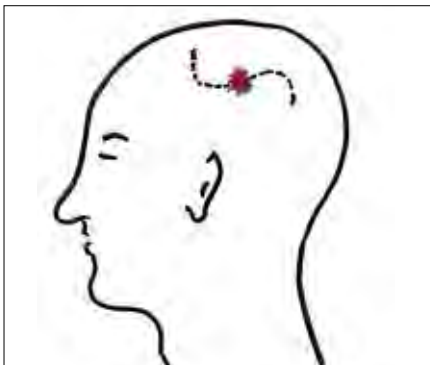
Horseshoe flap or "U"-incision: the incision is carried down through all the layers of the scalp. The wound itself is excised at the end of the operation. The small horizontal cut at one end of the flap is a release incision and permits a slight rotation in order to close the incision without tension. Dilute adrenaline solution may be injected into incision.



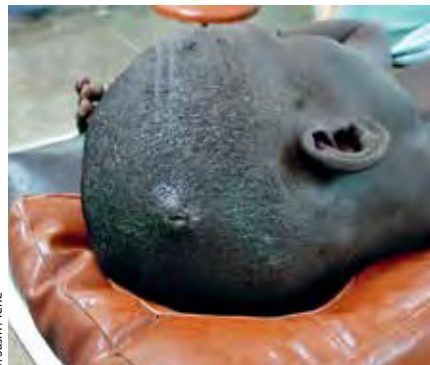N. Papas / ICRC



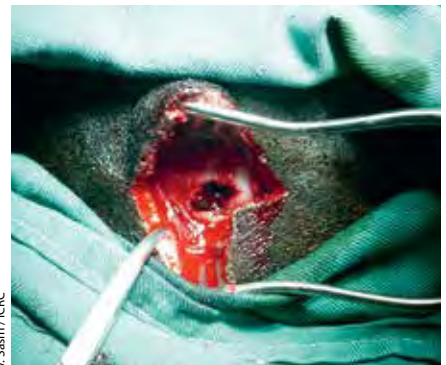ICRC



N. Papas / ICRC



V. Sabin / ICRC



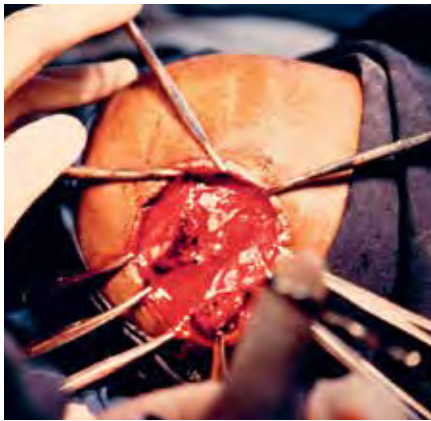
V. Sabin / ICRC

Figures 26.9.1 – 26.9.3

"S"-extension incision: all the layers of the wound are debrided first, to prevent further soiling of the brain from the scalp. The wound is then extended in an "S" fashion and the edges widely undermined.



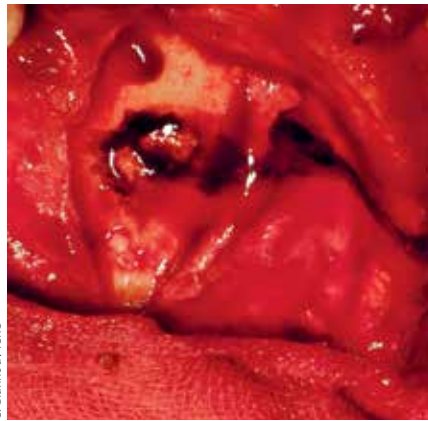
The surgeon now sees a gaping hole in the skull, filled with a pulped mass: haematoma and tissue debris. Sometimes, simply bringing down the skin flap is sufficient to release the tension and cause the damaged tissue to “plop” out as a bloody mass.



C. Giannou / CRC

**Figure 26.10.1**

Haemostasis is procured by seizing the galea aponeurotica – a tough, fibrous layer – with forceps and flipping them over to angulate the vessels.



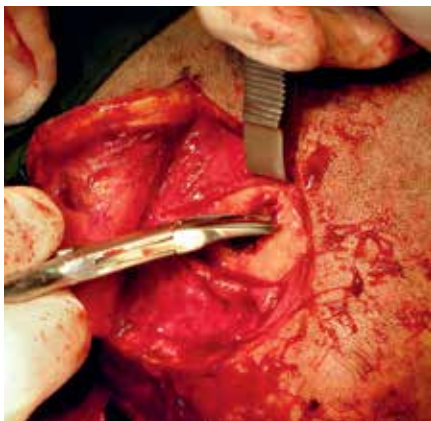C. Giannou / CRC

**Figure 26.10.2**

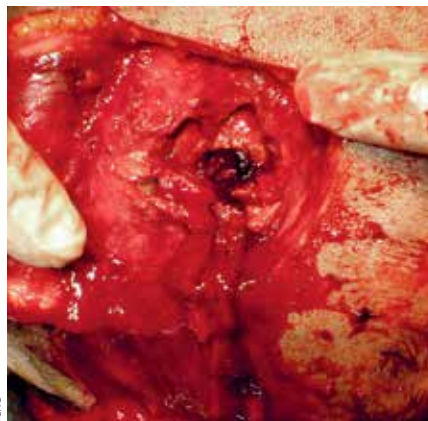
A hole in the skull filled with a haematoma presents itself.

### Bone

The dura is carefully separated from the bone with a dural elevator, since it has often become adherent to the bone edges. Using a bone-nibbling forceps (rongeur), the defect in the skull is carefully enlarged by biting away the damaged bone edges piece by piece until dura is visible all around the circumference of the wound. Any bleeding from the diploe is best dealt with using a crushed muscle patch dipped in the dilute adrenaline solution, and is preferable to bone wax which, being a foreign body introduced into a contaminated wound, favours infection.



CRC



CRC

**Figures 26.11.1 and 26.11.2**

A rongeur is used to nibble away the bone edges to expose dura all around the circumference of the bone defect.

26

### Meninges

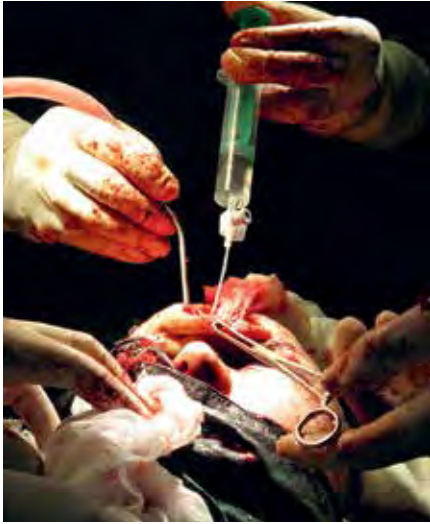The ragged edges of the dura should be trimmed. Dural tears may extend for some distance and care should be taken not to extend them further. They will need to be closed later.

### Brain

Pulped, dead brain has the consistency of yoghurt or porridge; it does not bleed, and does not “beat” in time with the pulse. Living brain is jelly-like; it bleeds and pulsates with the heartbeat.

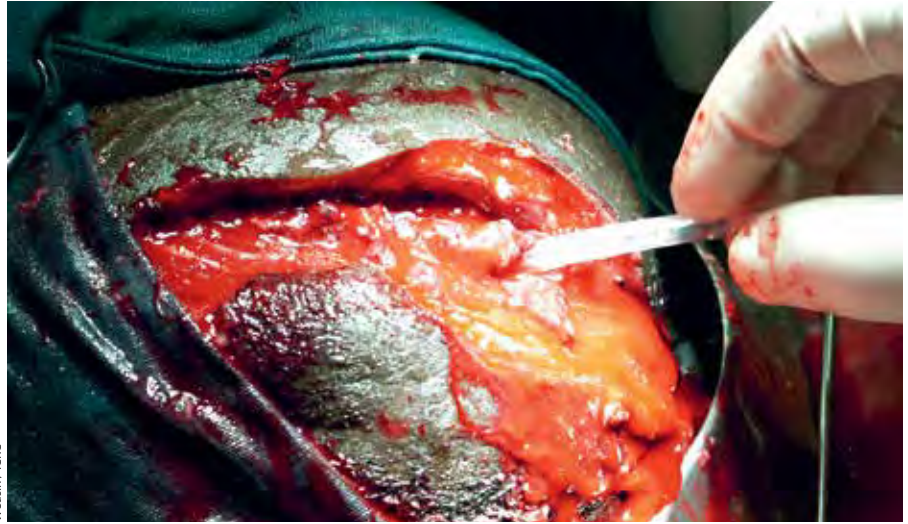
Dead brain is like yoghurt; living brain is like jelly.

Debridement is performed by sucking out pulped brain and haematoma with mechanical low-pressure suction; a large syringe with a soft Foley catheter attached is an alternative – the technique originally used by Harvey Cushing. The wound cavity is then gently irrigated with normal saline. Aspiration and irrigation are repeated until the cavity is clean.



ICRC

**Figure 26.12.1**  
Irrigation using a syringe.



V. Sasin / ICRC

**Figure 26.12.2**  
After irrigation, the wound cavity is then aspirated using low-power suction.

Loose bone fragments, which are always to be found within the cone of tissue destruction, are sucked out or may be picked out with a forceps. A search for readily accessible fragments is performed by gentle finger palpation. No extra effort causing even greater neuronal injury should be made to find and remove bone or metallic fragments; only those that are easily accessible should be extracted.

Bony fragments and metallic foreign bodies should be removed only if easily accessible.

The clean cavity is a glistening white and the brain tissue visibly pulsates with every heartbeat.

### Haemostasis

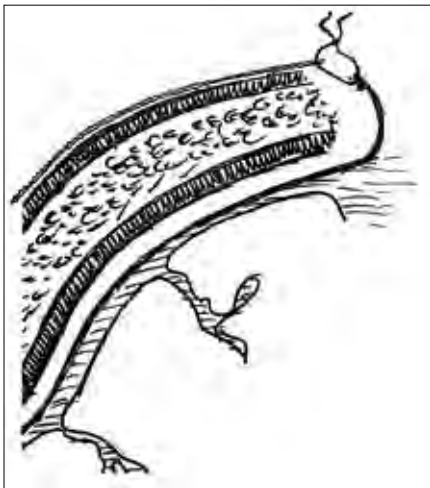
Haemostasis must be meticulous. For the surface of the cerebral tissue itself, which may present capillary ooze, bipolar cautery is best, if available. Because of the folds of the cerebral cortex, cauterization is usually easy at the top of the gyri, and very difficult in the base of the sulci. Otherwise, gauze pledgets soaked in the dilute adrenaline solution or warm saline are placed within the wound cavity and kept there for several minutes under gentle digital pressure. Upon removal, the ooze has usually stopped; if not, the procedure is repeated.

Bleeding from the very thin and delicate pia mater can be controlled by under-running sutures, although these often cut through. It may be more practical to pick up the pia mater together with the dura to better hold the sutures. Bipolar cautery-diathermy or silver clips are useful to control bleeding from individual vessels, if available.

### Closure of the dura

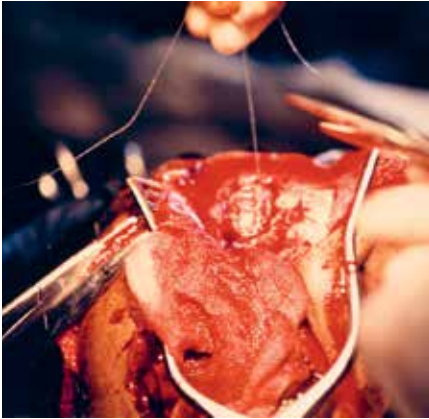
The clean and dry wound cavity is now ready for closure. Direct suture of the dural edges is rarely possible, except in very small wounds and for dural tears. A patch graft is usually necessary and can be taken from the pericranium, temporalis or occipitalis fascia, galea aponeurotica or from the fascia lata if a very large patch is necessary.

The graft patch is fixed to the surrounding dura with a continuous interlocking suture aiming at a *watertight closure* and using 3/0 synthetic absorbable suture or 4/0 non-absorbable. No intracranial drain should be left in place when working with limited resources and less than optimal hygiene.



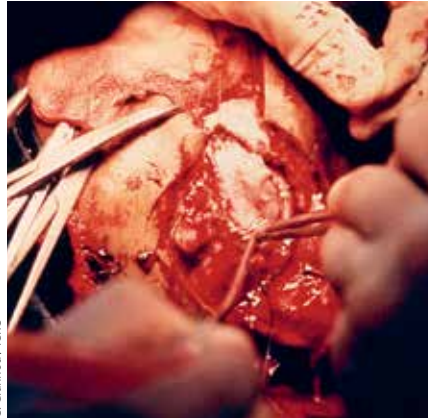
N. Papas / ICRC

**Figure 26.13**  
A tenting suture tacks the dura up to the pericranium to control bleeding.



**Figure 26.14.1**

Small meningeal defect repaired with a graft taken from the temporalis fascia and sewn watertight.



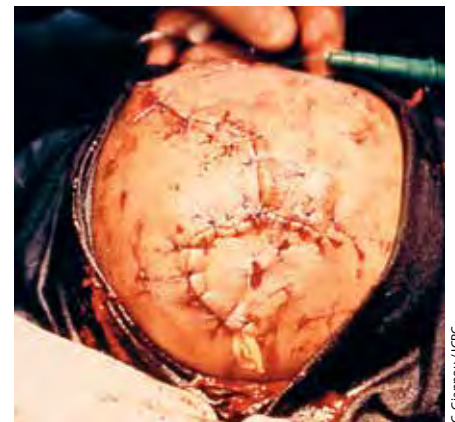**Figure 26.14.2**

Larger fascial graft.

### Scalp closure

Cranio-cerebral wounds are one of the exceptions to the rule of delayed primary closure. At the end of the operation, the scalp wound is excised and sutured. The loss of substance due to the wound debridement may render closure of the scalp incision difficult. A release incision at the base of the horseshoe flap helps to rotate the skin for closure. Further extension and undermining of the "S"-incision to create a rotation flap serves the same purpose. The flap should be raised beneath the galea, which may be scored to reduce tension on the suture line. Any bare area of pericranium due to the rotation flap should be covered with a split-skin graft.

Except for small wounds, closure of the scalp is best performed in two layers. The first picks up the thick and tough galea aponeurotica with absorbable material as a haemostatic suture and to prevent wound dehiscence. The second then closes the skin. Some surgeons close the wound in one layer, preferably using a mattress suture. A subcutaneous drain may be left in place for 24 hours.



**Figure 26.15**

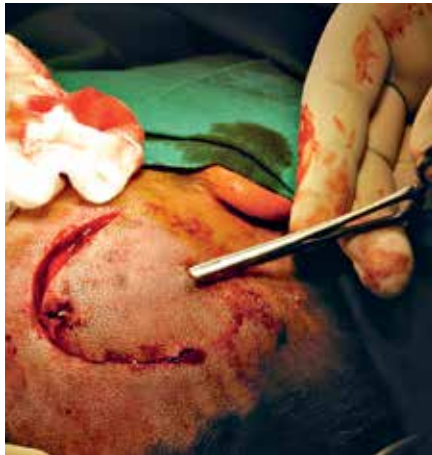Scalp closure with a subcutaneous drain.

## 26.10 Tangential wounds

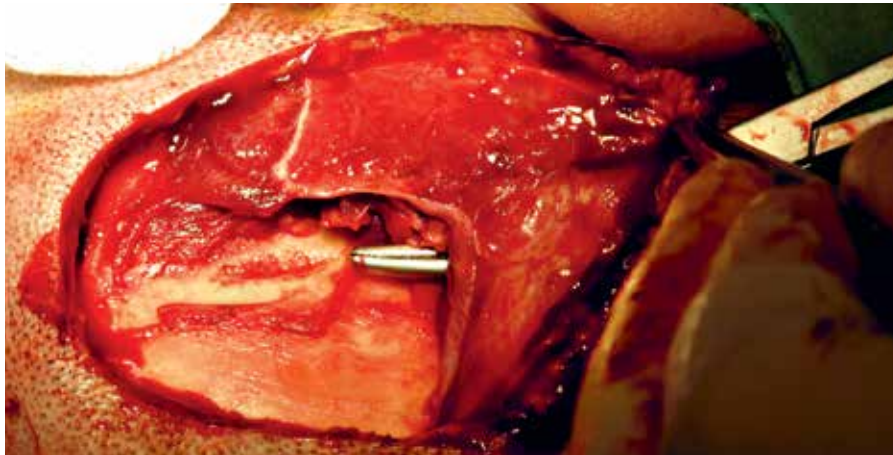
This is a relatively common projectile wound seen by the surgeon, testifying to its survivability.

### 26.10.1 Pathology

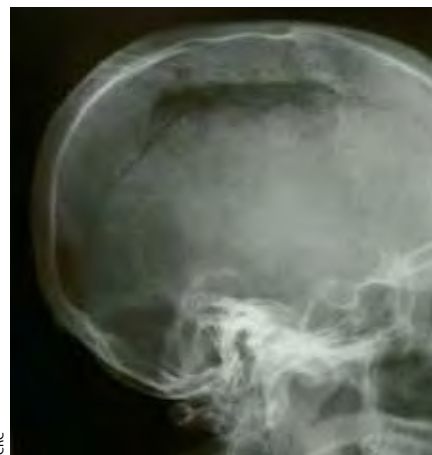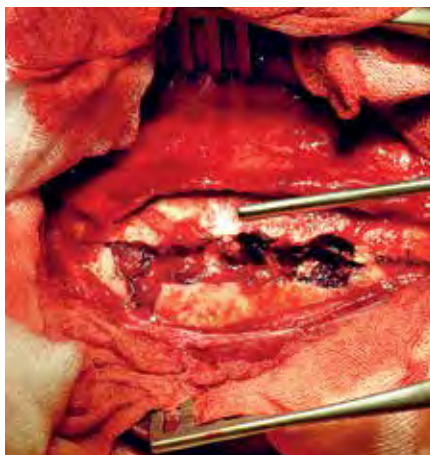
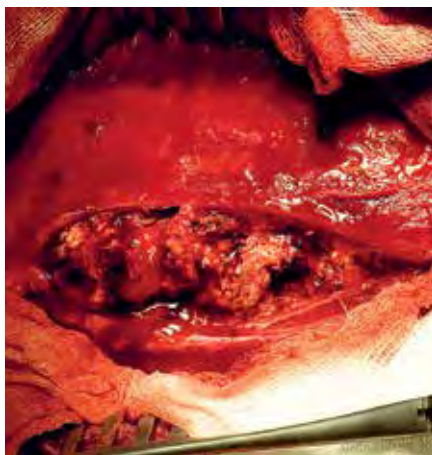The projectile may fracture the bone or not. The fracture may be depressed and have produced a "V-shaped gutter" that has filled with a pulsating haematoma causing the surgeon to think there has been penetration of the dura. Bone splinters may have been driven deep into the brain (Figure 26.1.2), but the external appearance of the wound does not indicate the degree of splintering. Injury to dural vessels can create an extradural or subdural haematoma.



**Figure 26.16.1**  
Tangential gunshot injury: the forceps has been passed through the entry and exit wounds. Note the horseshoe flap incision that includes both wounds.



**Figure 26.16.2**  
The tip of the forceps points out the gutter deformity of the bone: no penetration into the brain.



**Figures 26.17.1 – 26.17.3**  
Gunshot causing a gutter wound with penetration into the brain.

The most severe tangential injury is a gaping wound, a punched-out defect with comminution of the bone resembling a single “entry-exit”, with direct laceration and contusion of the cerebral cortex (Figures 26.1.3 and 26.20.1 – 26.20.2).

Not all fractures or in-driven bone splinters are visible on radiography.

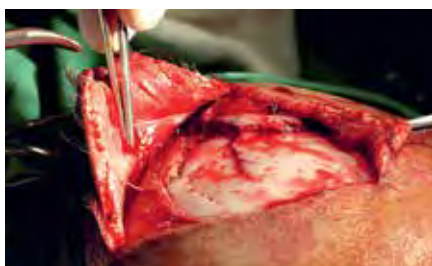With or without fracture or penetration, the impulse of the blow results in a varying amount of contusion of the underlying cortex. The clinical examination of the wound does not always indicate the severity of injury.

**26.10.2 Indications for surgery**

Indications for surgery include the following conditions.

**Depressed fracture with focalizing signs**

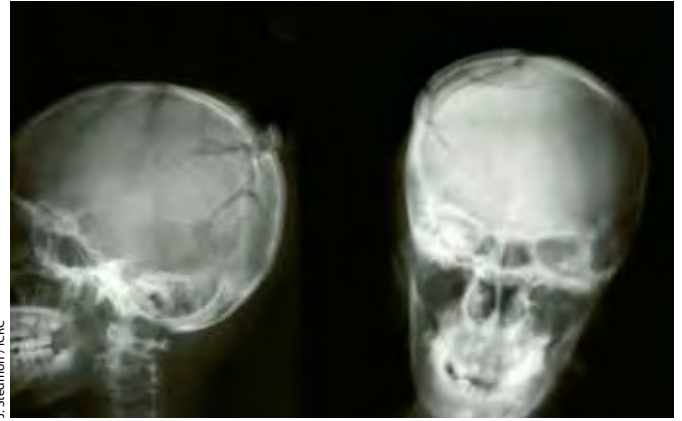
Focal signs of compression are an absolute indication to operate. Many surgeons prefer to trephine all such injuries because of the high incidence of bone splinters driven into the cerebral cortex. Others prefer to observe and operate only if focal signs appear or if there is no improvement over several days.



**Figure 26.18**  
Patient A: depressed fragment of the cranium.



J. Stedman / ICRC



J. Stedman / ICRC

Figures 26.19.1 and 26.19.2

Patient B: circumscribed wound in the scalp and underlying depressed fracture.

### Focal signs of a space-occupying haematoma

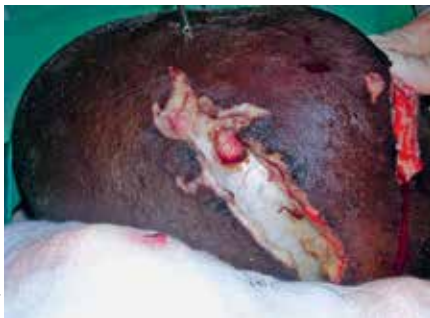Trepanation and evacuation of the clot are essential, whether the haematoma is extra- or subdural, or subcortical.

### Epileptic seizures

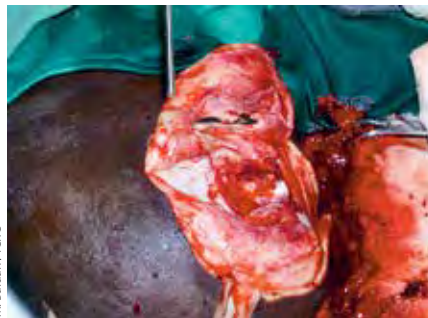Seizures may follow damage to the meninges by bone splinters; their removal does not guarantee long-term relief, but is sometimes able to prevent evolution to *status epilepticus*.

### Single entry-exit, punched-out defect with laceration of the brain

This open wound of the brain requires debridement.



E. Dykes / ICRC



M. Balaban / ICRC

Figures 26.20.1 and 26.20.2

Two examples of tangential penetration: one entry-exit.

## 26.10.3 Operative management

Without an indication for operation, apart from debridement of any scalp wound, conservative treatment as for a closed head injury should be adopted. Recovery is often spontaneous, although slow.

If trepanation is undertaken, it must be performed next to the gutter or depressed fracture; the bone fragments are elevated and the dura inspected. It may be intact or lacerated.

- An intact dura overlying contused brain without actual cortical liquefaction may be left as is.
- If the intact dura is tense and bluish, however, it should be opened and the clot evacuated. Contused brain should be gently debrided.
- Lacerated dura should be cut clean and damaged cortex debrided by aspiration and irrigation, and any accessible bone splinters removed.

The single entry-exit defect should be debrided, just like a penetrating burr-hole wound.

## 26.11 Other penetrating wounds

Small fragment wounds are relatively common; transfixing wounds are rare, as the patient usually does not survive to reach hospital.

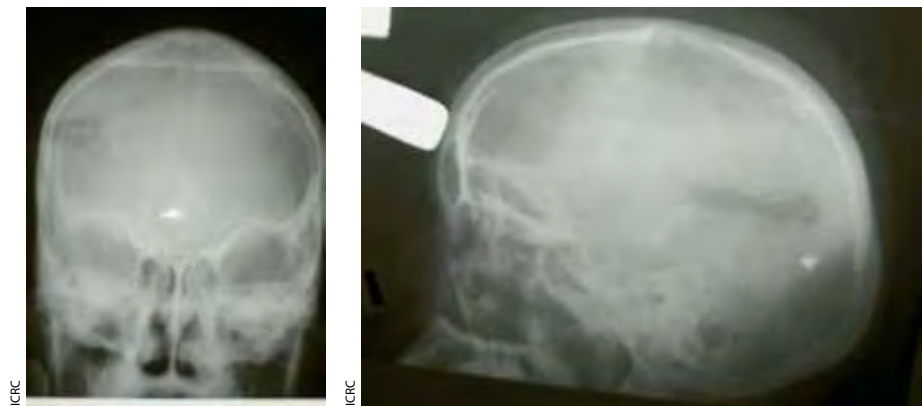
### 26.11.1 Small Grade 1 fragment wounds

Fragments with just enough kinetic energy to pierce the vault of the skull and enter the brain cause relatively little local tissue damage. They constitute a Grade 1 wound according to the Red Cross Wound Score. Several scenarios are possible.

#### Single or limited number of fragments

Given that vital centres are not touched, the prognosis is good and the patient is usually quite lucid, often walking into the emergency admissions. Since oedema and haematoma formation are usually limited, most surgeons adopt a conservative non-operative approach apart from local toilet and suture of the scalp wound.

Figures 26.21.1 and 26.21.2  
Single retained fragment.



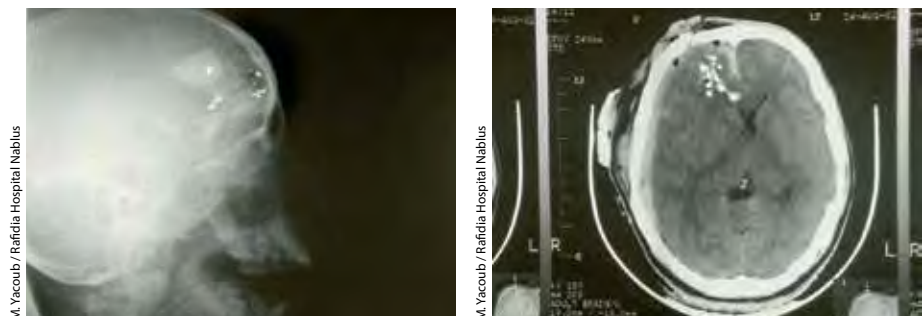The patient must remain under strict observation, however, and any indication of increased intracranial pressure, focalizing signs or CSF leakage dealt with aggressively. This entails a burr-hole trepanation of the punctate entry site(s) and localized debridement of the injured brain.

If the fragment is relatively large and located superficially, it should be removed by trepanation (Figure 14.3).

#### Large number of fragments

With multiple fragments there is a cumulative effect of oedema and haematoma formation. The level of consciousness is usually decreased; even frank coma may ensue. This type more closely resembles a severe closed head injury.

Figures 26.22.1 and 26.22.2  
X-ray and CT scan showing multiple fragments  
in the frontal lobe.



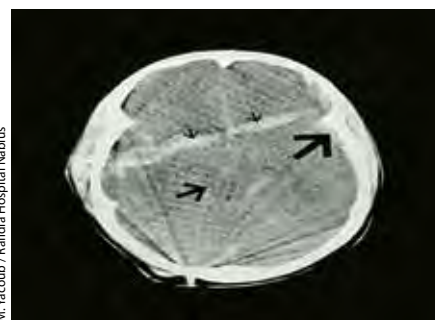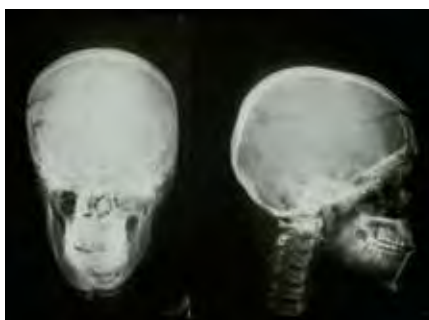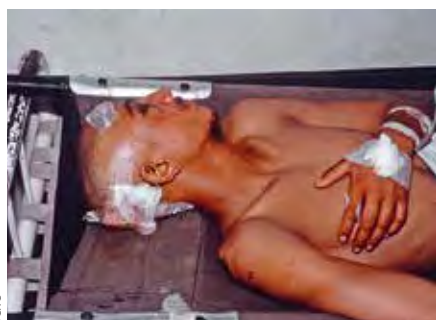If the GCS is  $> 8$  and there is no deterioration of the patient's condition, a conservative approach may be adopted. In the face of a rapidly deteriorating clinical picture, the performance of multiple burr-holes and local debridement for each entry wound may be the only recourse left to the surgeon working with limited resources.

### 26.11.2 Transfixing through-and-through wounds

These are very serious injuries and often fatal; cavitation effect is quickly lethal. The projectile also often traverses the lateral ventricle. Haematoma, bone fragments, and oedema are found irregularly throughout the whole wound track.

### Unilateral hemispheric transfixation

The entry and exit wounds involve only one cerebral hemisphere (Figure 26.1.5). Given the poor prognosis, only a few patients with lesions relatively high in the vault and an acceptable GCS score proceed to surgery.



Figures 26.23.1 and 26.23.2

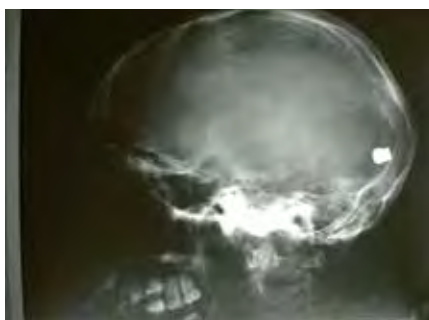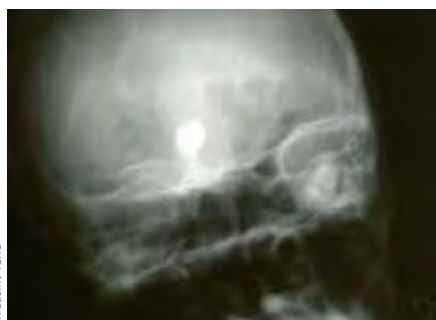GSW of the head: the entry was frontal and the exit parietal.

Figure 26.23.3

CT-scan of a unilateral hemispheric transit showing the narrow shooting channel.

The entry and exit wounds are debrided as usual. The long narrow track is gently aspirated and irrigated using a catheter or naso-gastric tube. The dura and scalp are closed without drains.

Occasionally, the projectile may traverse the entire hemisphere but not have sufficient kinetic energy to exit the skull. The treatment is the same as for a transfixation wound.



Figures 26.24.1 and 26.24.2

Retained projectile after traversing the entire hemisphere.

### Bilateral hemispheric transfixation

The projectile crosses the midline, involving both cerebral hemispheres (Figure 26.1.6). These injuries are rarely seen in hospital, and those that do present are usually high in the vault and involve the frontal lobes and sinuses.

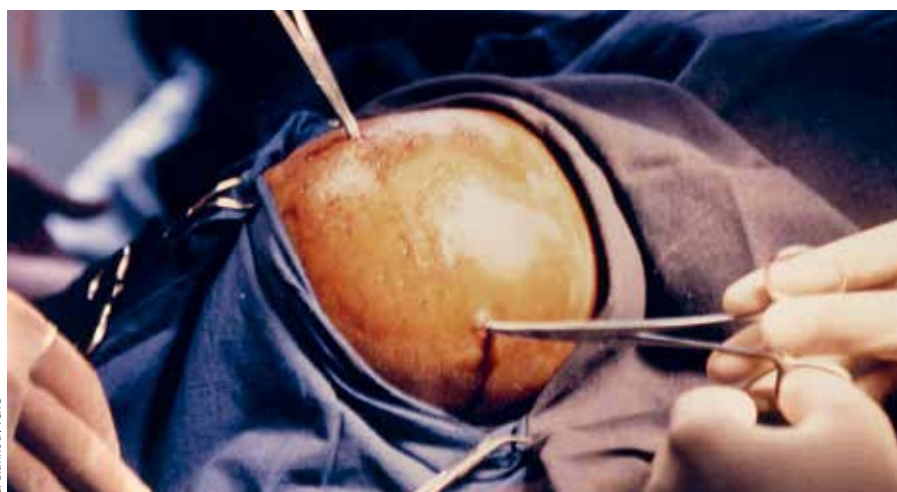


Figure 26.25

The forceps indicate the entry and exit wounds high up in the vault.

Except in the case of bifrontal wounds, a simplified and abbreviated version of the previous procedure is performed. Conservative supportive treatment is usually the best that can be offered these "expectant" patients.

## 26.12 Trepanation

The main indication for trepanation is blunt trauma with an intracranial haematoma or a closed depressed fracture with signs of lateralization; but it is also required for some tangential wounds or those due to small fragments.

### Please note:

As mentioned, tangential wounds and primary blast injuries can also cause a closed intracranial haematoma.

Burr-hole trepanation is an operation well within the competency of the general surgeon and should be included in the standard armamentarium of operative procedures, especially for the lone surgeon working in a rural area. The operative details are to be found in Annex 26.A.

## 26.13 Difficult situations

A number of difficult presentations of penetrating head injury exist. Some require the presence of a neurosurgeon for proper treatment.

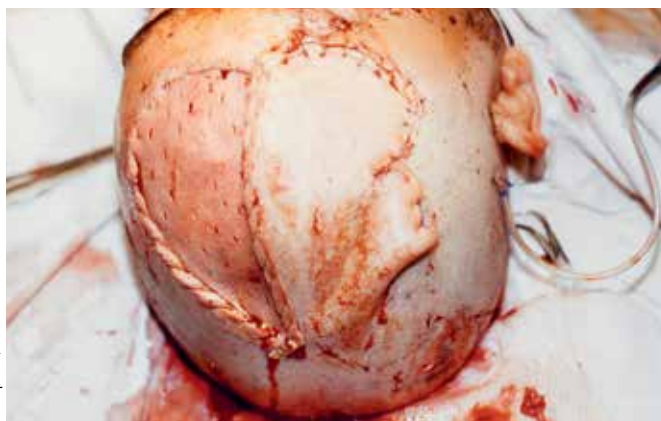
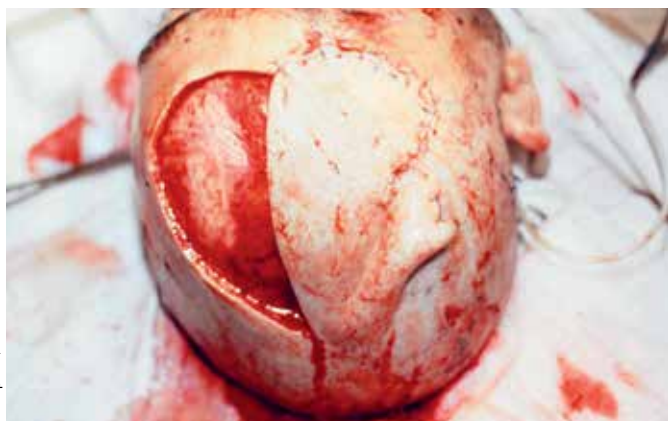
### **Falling bullets**

In many societies, it is customary to celebrate a military victory, birth or marriage by firing rifles into the air; even more so if the country is the scene of armed conflict. It is not rare for the falling bullets to injure or kill bystanders. Some falling bullets have enough energy to perforate the skull and penetrate the brain for several centimetres: a mini-burr hole wound. The surgical management follows the same criteria as the wounds discussed previously.

In a certain number of persons, the bullet will only just perforate the skull and become stuck in the bone of the cranium. *It must never be removed blindly.* A small burr-hole should be made next to the bullet and completed by bone-nibbling forceps to free the projectile. Attention should be paid to the bullet tip to see whether the dura has been penetrated or not. Any lacerated brain should be gently aspirated and the dura closed. The anatomic site of penetration should alert the surgeon to the possibility of injury to the sagittal venous sinus; this specific case is discussed below.

### **Loss of a large amount of scalp cover**

A sufficient rotation flap is fashioned, based on the arterial supply reaching the scalp from below; the flap may involve over half the scalp. Any bare area of pericranium is covered immediately with a split-skin graft.



Figures 26.26.1 and 26.26.2

Large rotation skin flap of the scalp: a split skin graft covers the bare area of pericranium.



### Loss of a large amount of skull

Various synthetic materials now exist to replace large bone defects. Cranioplasty, however, is a specialized procedure and is beyond the scope of this manual. In some cases, the general surgeon may be able to save large pieces of the skull and replace them later. Any dirtied edges of bone should be nibbled away. The bone should then be washed in a saline-antibiotic solution and kept in the blood bank refrigerator, to be retrieved and replaced once the patient is fully stabilized. Another technique is to bury the large piece of skull in the subcutaneous fat of the abdominal wall.

In most cases, however, such bone "storing" and retrieval is not possible and the patient will be obliged to wear a protective bicycle or motorcycle helmet or "hard hat" afterwards.

### Injury to the base of the skull

Local debridement of the wound is the only surgical procedure to undertake. The patient should be nursed in a semi-sitting position. If otorrhoea occurs, the ear should not be packed, but simply covered with an absorbent dressing bandaged over the ear.

### Injury to a deep-seated major blood vessel

This injury is usually rapidly fatal. There may be times when the surgical evacuation of pulped brain, haematoma and bone fragments uncovers and releases such an injury, with ensuing heavy haemorrhage. The condition is usually beyond the competency of the general surgeon, who may choose to take a simple damage-control approach and pack the cavity in an attempt to stop the bleeding and re-operate 24 hours later if the patient is still alive.

### Traumatic aneurysm or arterio-venous fistula

These lesions are usually due to a fragment; a bullet tends to push blood vessels aside or transect them completely with a rapidly fatal issue. Severe primary blast injury to the brain may also lead to the formation of a pseudoaneurysm. In survivors, it is usually the distal and more superficial branches of the cerebral circulation that are concerned. Diagnosis is difficult without sophisticated technology.

When a pseudoaneurysm or arterio-venous (A-V) fistula is discovered during brain debridement, the vessels are usually too small to be repaired with standard vascular techniques and proper exposure usually requires the skill of a trained neurosurgeon. The general surgeon should simply try to ligate the vessels involved and accept the consequences or treat the patient conservatively. Either way prognosis is poor.

## 26.13.1 Superior sagittal sinus injury

The superior sagittal sinus is triangular in shape and lies between the two layers of the falx cerebri. It is held rigidly open and is not compressible, unlike other major veins in the body. The venous sinuses of the cranial cavity, the internal jugular vein, and the superior vena cava do not have valves. Thus, the venous pressure in the right atrium and superior vena cava are reflected in the sagittal sinus when the patient is in the decubitus position.

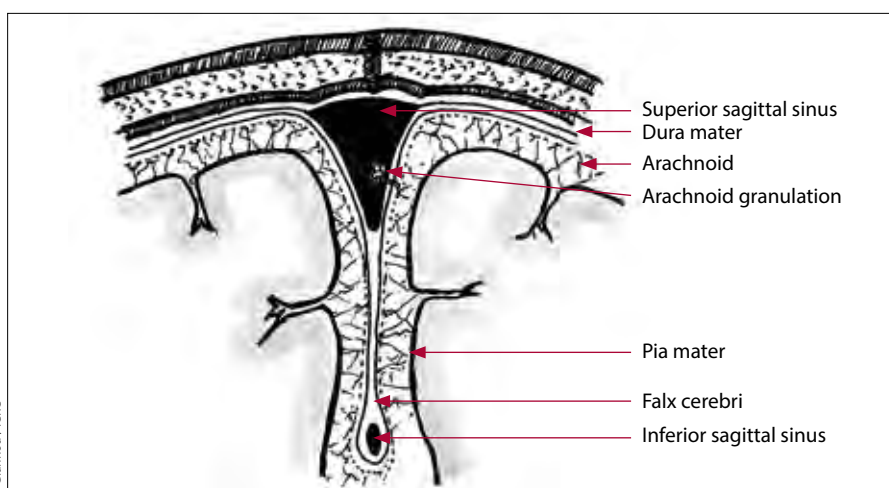


Figure 26.27

Anatomy of the superior sagittal sinus.

Major injury to the sagittal sinus is rapidly fatal owing to exsanguination and/or a space-occupying mass effect. Patients presenting to the surgeon have usually been injured by a falling bullet or a small fragment or spicule of bone piercing the dura of the sinus and becoming lodged there, thus preventing massive haemorrhage.

### Surgical management

Good coordination between the surgeon and the anaesthetist is essential in manoeuvring the patient's head and body position.

1. A scalp flap is fashioned in preference to an "S"-incision to allow for adequate exposure, whether for a falling bullet wound or for a depressed fracture of the vertex.
2. One or two burr holes are drilled and the opening enlarged with bone-nibbling forceps to reveal the projectile or bone splinter. In other cases, it is discovered during brain debridement. All such "foreign bodies" should be left *in situ* until preparations are made to control the haemorrhage that follows their removal.
3. Before removing the object the head and upper body of the patient should be raised, thus decreasing the venous pressure in the sinus. However, removing the object at this point may cause air embolism. Therefore, the wound should first be filled with normal saline.
4. The surgeon then removes the bullet, fragment, or bone splinter and quickly blocks the hole in the sinus with a finger, while the anaesthetist raises or lowers the head of the patient: too low and a very impressive haemorrhage ensues; too high and the saline is aspirated into the sinus. The equilibrium point must be found (usually around 30° elevation) at which there is no haemorrhage and no aspiration of saline. The surgeon can now remove the finger. Should the object become dislodged prematurely, the same digital pressure by the surgeon and manoeuvre on the part of the anaesthetist are necessary.
5. Dural closure is problematic. The walls of the sinus are too rigid for direct suture and the stitches simply cut through. The following techniques can be applied:
  - a patch is fashioned using a small piece of either the pericranium or temporalis fascia; or
  - a meningeal rotation flap is mobilized using a segment of the dura adjacent to the sinus and swung around to cover the hole.
6. Whichever method is used, the patch is now securely sutured into position using a continuous fine vascular suture. The penetration points of the needle all bleed. The patch is therefore reinforced with a piece of crushed muscle, to release tissue clotting factors, and held in place for 5 – 10 minutes while the surgeon, anaesthetist, and nursing staff talk about the weather and take a deep breath.
7. Simple closure of the scalp incision follows.

If the tear in the sinus is too large for a patch graft or meningeal rotation flap, it may be possible to stitch the underside of the scalp to the sinus. Alternatively, a damage-control approach may be adopted: the opening is plugged with gauze, the scalp stitched over it, and a compressive dressing applied. The patient is re-operated after 24 – 48 hours. Otherwise, the only solution is to pass a thick ligature around the sinus, proximal and distal to the opening, and tie it off. The surgeon must then accept the consequences, usually minimal in the first quarter to one third of the sinus, further back often fatal.

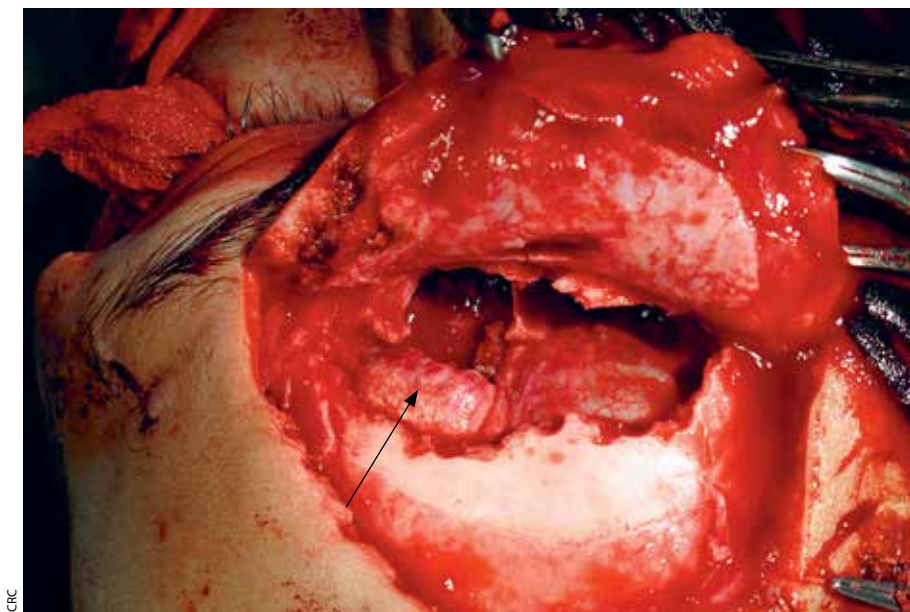
### 26.13.2 Frontal sinus injury

A projectile may pass through the frontal sinus and then enter the frontal lobe of the brain. The orbit may also be implicated. It is simplest to perform a brain debridement directly through the shattered sinus, although a horseshoe flap centred on the supra-orbital artery is preferred.

At the end of the brain debridement, every attempt must be made to close the dura, using whatever graft is necessary in order to prevent ascending infection.

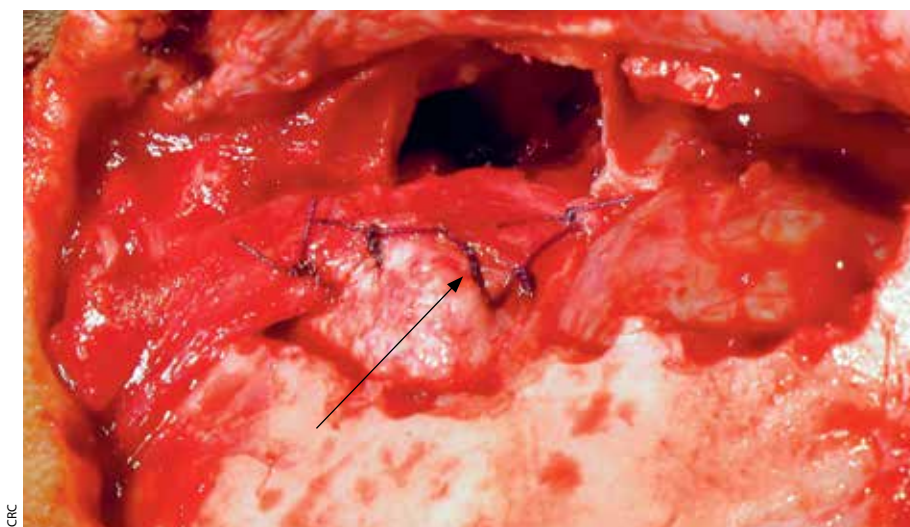
The sinus itself is then scraped with a curette to remove the mucosa and swabbed with a povidone iodine solution. The fronto-nasal ostium is packed with a small piece of fascia. The skin wound is then debrided and closed.

In the event of a large loss of soft tissue, the sinus can be packed with gauze compresses imbued with povidone iodine until flaps can be fashioned at a later sitting (see Figures 27.28.1 – 27.28.3).



**Figure 26.28.1**

A frontal flap has been taken down revealing damage to the sinus and exposure of the dura covering the frontal lobe (arrow).



**Figure 26.28.2**

The dura has been closed by means of a fascial flap stitched in place.

### 26.13.3 Damage-control neurotraumatology

The practice of damage control in head trauma follows the same principles as damage control surgery elsewhere, a function of physiology: preventing hypothermia, coagulopathy, and acidosis (see Chapter 18). It may be successfully practised in remote areas with the possibility of patient transfer and consists of evacuation of a haematoma or abbreviated debridement of open brain trauma.

If patient transfer is *not* available, difficult to control bleeding, especially from deeply-situated vessels, may be temporarily controlled by tamponade packing and the operation revised 24 – 48 hours later once physiological stabilization is achieved.

In a patient with multiple injuries, the surgeon may have to perform a *very rapid* burr hole to relieve ICP and incipient herniation before turning to another wound site to stop haemorrhage. The intracranial haematoma need not be completely evacuated at first sitting, as long as it continues to drain out. The surgeon must use judgment to determine which condition is the more life-threatening.

## 26.14 Post-operative and conservative management

Post-operative care: more “heroic” than the surgery.

Whether they are comatose or lucid, post-operative monitoring and nursing care of patients suffering severe head injury is onerous and a great drain on time, effort, and human resources – as is the conservative treatment of the comatose patient. The compensation comes with seeing the recovery of many patients. The importance of post-operative care is often underestimated. In patients with severe neurotrauma, it is the post-operative care that is “heroic”, not the surgery.

- Close observation and monitoring.

The Glasgow Coma Scale provides a good indication of the evolution of the patient’s condition. Clinical surveillance of intracranial pressure and post-operative haemorrhage (clotting defect, especially disseminated intravascular coagulopathy) should be rigorous.

- Adequate airway.

Where the resources for intubation and mechanical ventilation are lacking, there is a place for a more liberal use of a tracheostomy. A tracheostomy removes 150 ml of dead space from the tidal volume and assists in better oxygenation of the patient and the “blowing off” of CO<sub>2</sub>. The tracheostomy can be removed once the patient is conscious enough to perform spontaneous active expiratory effort.

A patient with *no other* respiratory pathology causing poor oxygenation, as confirmed by pulse oxymeter, and with decreased consciousness (GCS < 12) may often benefit from a tracheostomy. A GCS of 8 or less is a definite indication.

- Administration of humidified supplemental oxygen.
- Semi-sitting position with the head elevated 30°.

This results in the simple hydraulic effect of aiding venous drainage from the brain, thus decreasing ICP.

- Intravenous fluids.

For the first few days of treatment, after complete haemodynamic stabilization, intravenous fluids should be limited to Ringer’s lactate and care taken to prevent over-hydration, which augments cerebral oedema.

- Bladder catheterization.

The urine production must be monitored to assure fluid balance and avoid irritability from a full bladder. Poly- or oliguria may indicate disturbed vasopressin secretion which is a sign of fracture of the base of the skull.

- Ocular hygiene.

The comatose patient is at particular risk of exposure keratitis and conjunctivitis. The eyes should be swabbed daily with a moist compress to remove any secretions. The lids should be taped shut with adhesive skin closure strips (Steri-Strips®) after the instillation of eye ointment.

- Anti-tetanus prophylaxis and antibiotics.
- Analgesia, especially if there are associated injuries.
- Sedation as necessary: diazepam, barbiturates.
- Prevention of gastro-intestinal bleeding.

An H<sub>2</sub>-receptor antagonist or proton pump inhibitor and oral anti-acids should be given to prevent stress ulceration.

- Nutrition.

Feeding through a naso-gastric tube, with full precautions during insertion if maxillo-facial fractures are present, is begun by day three; a feeding gastrostomy or jejunostomy is necessary if the patient is unable to feed for a long time. Metabolic demands are high: (140% of resting metabolism in the non-paralysed patient, with 15% in the form of proteins from day 7). The nutritional requirements as described in Annex 15 A for burn patients are appropriate.

- Prophylaxis of deep vein thrombosis.

This is not indicated everywhere. DVT is highly contingent on diet and lifestyle and prophylaxis is required only if the pathology is common in the community. Non-medical measures such as pressure stockings and physiotherapy take precedence; medication may be used if there are no contraindications but the risk of ongoing bleeding in cranio-cerebral wounds is very great. (See Part F.2)

- Thermal control.

Severe head injury often provokes a loss of thermal control: hypothermia must be avoided at all costs, and the advent of coagulopathy closely monitored. Hyperthermia, by increasing cerebral catabolism, is just as dangerous, especially in children.

- Skin and oral hygiene.

- Physiotherapy.

The lungs are kept clear and movement of the joints is maintained.

- Prophylaxis of epilepsy.

Please note:

Steroids have no role to play in the treatment of head injuries.

The regular clinical assessment of the level of consciousness is essential. Deterioration requires re-exploration, usually to remove a new blood clot or deal with infection.

If the level of consciousness deteriorates, re-exploration is required.

### 26.14.1 Prophylaxis of epileptic seizures

The development of epilepsy varies among clinical studies: up to 50% incidence after 15 years follow-up. Early seizures occurring within 7 days are more common than late onset. Current knowledge suggests that early prophylaxis does not prevent late seizures.

The occurrence of epileptic seizures very early in the convalescent period causes a radical and rapid deterioration of the patient's condition due to secondary brain injury. The immediate treatment is diazepam i.v.

ICRC surgeons have recently modified their treatment protocol to include *one week post-operative prophylaxis* of epilepsy.<sup>15</sup>

Several medications are available for short-term prophylaxis and the choice depends on the circumstances of the hospital.

- Phenytoin sodium intravenous

In both adults and children, a loading dose of 10 – 20 mg/kg i.v. is given (at a maximum rate of 50 mg/minute to prevent cardio-vascular adverse effects such as hypotension and bradycardia).

15 Protocol adopted by the Second ICRC Master Surgeons Workshop held in Geneva, December 2010.

The maintenance i.v. dose after 24 hours for adults is 3 – 7 mg/kg given once daily. For children up to 12 years of age, 2.5 – 5 mg/kg BID is given i.m.

- Carbamazepine

Only available as tablets or suspension, which may be used as a rectal suppository. Adults 200 mg BID initially, and gradually increased to 400 mg BID; children from one month to 12 years, 5 mg/kg daily increasing to 10 – 15 mg/kg daily, in divided doses. If given rectally, the oral dose should be increased by 25%.

- Phenobarbital

This common medication may be used if others are unavailable: adult loading dose 10 mg/kg up to a maximum of 1 g, given at a rate not more than 100 mg/minute. After 24 hours, the maintenance dose is 100 – 200 mg per day. For children up to 12 years, an initial dose of 1 – 1.5 mg/kg BID, increased by 2 mg/kg/day, to a maintenance dose of 2.5 to 4 mg/kg once or twice daily.

Please note:

All anti-epileptics should be withdrawn gradually to prevent precipitating a seizure. The one-week prophylaxis protocol should be progressively decreased over another week. Long-term prophylaxis is controversial and is not recommended.

## 26.15 Increased intracranial pressure

Any increase in ICP should be diagnosed early and treated aggressively. It is much rarer in open wounds than in closed head trauma.

The first priority for the head-injured patient is complete and rapid physiologic resuscitation. During resuscitation, and where sophisticated means of patient monitoring are not available, no specific treatment should be directed at preventing a rise in ICP.

All treatment modalities for ICP (for example, the use of osmotic diuretics) entail serious complications and, again in the absence of sophisticated means of patient monitoring, can directly interfere with resuscitation.

### 26.15.1 Management

Treatment should begin with simple measures: supplemental oxygen, elevation of the head, sedation, rapid control of fever, and avoidance of hypotension and of over-hydration; glucose in water is to be excluded entirely.

In the absence of mechanical ventilation, the capacity to paralyse the patient and proceed with manual ventilation depends on the human resources available in the hospital. Mild, controlled hyperventilation is rapidly effective, but should only be practised for a very short period of time (a good *temporary* measure during surgery to control acute swelling of the brain).

The use of mannitol for the treatment of ICP is not a simple procedure: it demands close monitoring of the patient. In the absence of good nursing care and patient observation, it is probably better not to administer it. In addition, mannitol is more useful in the generalized oedema of blunt trauma or blast injury rather than the localized oedema of a projectile wound.

Mannitol should only be used if the patient is adequately resuscitated and haemodynamically stable. A bolus injection of 0.5 – 1 gm/kg body weight is given over 20 minutes. A rapid infusion brings about a rapid and greater decrease in ICP, but also a rebound effect when stopped. A slower infusion rate allows for a more sustained decrease.

Wound debridement or draining a haematoma will, in itself, decompress the brain and decrease ICP. Ventriculostomy, an external ventricular drain of CSF, constitutes a specialist neurosurgical procedure and is beyond the scope of this manual, as is decompressive craniectomy (removing a large section of the skull).

## 26.16 Cerebrospinal fluid fistula

A leak of CSF may be acute or delayed; 70% present within two weeks of injury. Only about half the leaks occur at the wound site; a post-operative CSF fistula in the vault is usually caused by failure to close the dura. The others are mostly due to the extension of fractures and dural tears, particularly with fractures of the base of the skull; the patient then presents with otorrhoea or rhinorrhoea. In doubtful cases, gentle compression of both jugular veins for half a minute with the head flexed can reveal a hidden leak. Injury through the frontal sinus is particularly prone to CSF rhinorrhoea.

A majority of cases, 50–60%, become infected. However, some experienced war surgeons claim that it is infection, particularly at the wound site with dehiscence of the scalp closure, which causes the CSF leak, not the other way around. Whether cause or effect, the mortality rises dramatically. Fortunately, 40% of CSF leaks close spontaneously.

In the absence of obvious infection, conservative treatment is indicated, especially for otorrhoea which often resolves spontaneously, whereas rhinorrhoea is more problematic and requires antibiotics to cover the entire period of leakage, elevation of the head, and avoidance of coughing or sneezing.

Accessible leaks in the vault that fail to demonstrate a decrease after 2–3 days or show signs of infection should be operated with watertight closure of the dura. A fascial graft is usually indicated. The base of the skull is not accessible and a CSF leak there should be managed entirely conservatively.

## 26.17 Infection

Two different clinical presentations are seen. The first is in patients who have survived the initial wounding but arrive late to hospital; the second is a complication of hospital treatment. It should be noted that many clinical studies have demonstrated no relationship between the bacteria contaminating the wound and the post-operative infective organisms. Furthermore it would appear that bone and metal are not as important in causing infection when compared to skin and hair and their commensal bacterial flora.

### 26.17.1 Neglected wounds

In low-income countries with difficult lines of transportation it is uncommon but not rare to have patients present with a neglected cerebral fungus forming an open, draining abscess. The open, gaping wound – usually a burr-hole type – prevents a fatal increase of ICP. The abscess is walled off by glial tissue (the equivalent of fibrous tissue in the central nervous system) and the pus pours out.

Treatment follows the same standard principles for all neglected wounds and any abscess: drainage first and foremost. There is no urgency since the patient has already survived for several days.

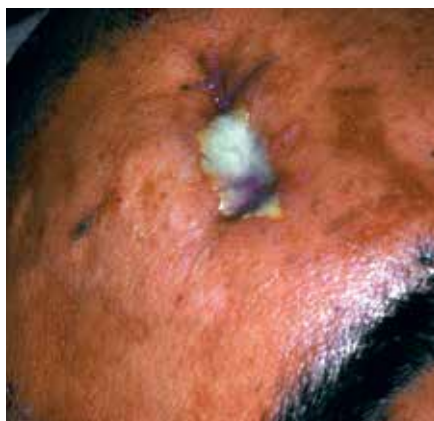After proper resuscitation – the patient is often dehydrated – and antibiotic cover, the cavity is gently irrigated with normal saline and aspirated. Careful, and protected, finger palpation detects any retained bone fragments lodged in the wall of the cavity. These should be gently dislodged. If very large, they may have to await a second or third irrigation session, the idea being not to open up fresh tissue spaces by their premature removal. Any extension of the infection would immediately implicate the cerebrospinal fluid.

Irrigation sessions are repeated twice daily until the glial cavity wall is clean: a glistening, homogenous white. Once clean, the wound can be closed, usually with a rotation flap.

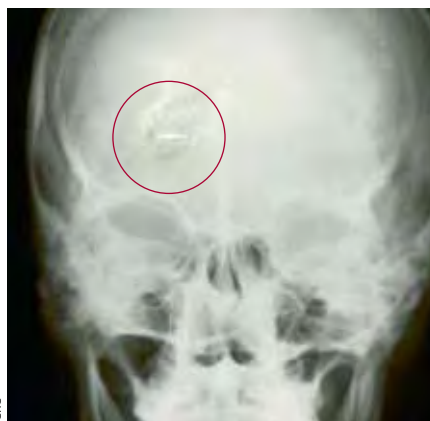### 26.17.2 Post-operative infectious complications

Whether the patient has been treated conservatively or operatively, infection is always a potentially lethal complication in open head wounds, with a mortality rate greater than 50%; historically, it was the great killer after organ destruction. Infection rates of 10 – 15% are not uncommon in modern practice and even higher if there is delay in treatment. Scalp wound dehiscence increases the risk of infection, as well as CSF leakage. Bone fragments carry a greater risk of causing infection than metallic fragments. However, the real “culprits” are pieces of the scalp and hair and in-driven dirt.

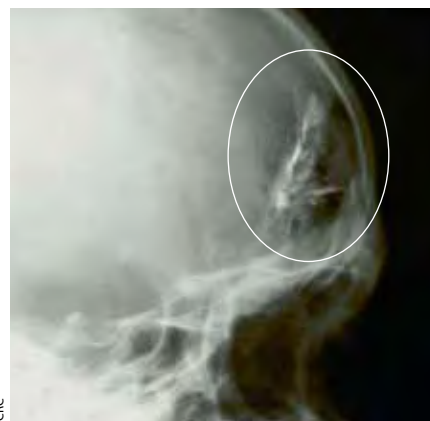Infection can take several forms: scalp wound infection, with the danger of provoking a CSF leak and ascending infection; osteomyelitis of the skull; meningitis, or late brain abscess.



ICRC



ICRC



ICRC

Figures 26.29.1 – 26.29.3

Osteomyelitis after a fragment injury to the frontal sinus.

Progressive neurological signs are rare in post-operative patients with an important loss of brain volume. A more insidious onset is usual: irritability and headache – although sudden fever may occur. Frequently however there is a lack of general signs such as fever, neck stiffness or vomiting. *Pulsations* of the scalp flap usually decrease, but its *bulging* increases.

Antibiotics and re-operation without delay – exploration, drainage, and re-bridement as necessary – form the basis of treatment. It is usually possible to close the dura and skin. A drain should *not* be left in place. The possibility of secondary fungal or bacterial infection should be kept in mind.

## 26.18 Primary blast neurotrauma

As described in Section 19.4.1 and in much of the literature mentioned in the Selected Bibliography, primary blast injury to the central and autonomic nervous systems has several pathophysiological mechanisms of injury, some of which resemble blunt trauma, others not.

The clinical presentations cover a wide spectrum of severity from immediate death to very mild concussion. The incidence of mild concussion is probably greatly underestimated. Although most patients recover spontaneously, a number go on to suffer long-term sequelae.

Many associated injuries occur with explosive blast, including to the face and spinal column. Notable complications include CSF leak, cerebral vasospasm, arterial pseudoaneurysm and A-V fistula. Disseminated intravascular coagulopathy is relatively frequent in penetrating head injuries within the radius of primary blast effects.



## 26.19 Post-trauma rehabilitation

The ultimate outcome of patients suffering severe brain injury is more important than simple mortality figures. Many surviving patients go on to lead full, independent, and productive lives. Active and prolonged rehabilitation is necessary, however, and the means may be limited.

Post-operative rehabilitation is a “creative cooperative effort by the health care team, patient, and family that is aimed at optimizing mental, social, and vocational aptitudes”.<sup>16</sup>

Many patients suffer varying degrees of post-concussion disorders, with psychological, familial, and social consequences. Epilepsy, declaring itself even years after the initial insult, is common. Head-injured patients, more than any others, require long-term support and understanding. The same is true of patients suffering spinal trauma.

### 26.19.1 Patient outcome

Given such a dire outcome for many patients with severe head injury, and the possibility of a wide spectrum of post-trauma disabilities, mortality is not the only parameter to take into account when judging the results of treatment. A widely-used system is the Glasgow Outcome Scale (GOS).<sup>17</sup> The patient’s status is assessed upon discharge and again later, after a certain follow-up period lasting months or even years, to determine the evolution of his or her condition.

The following categories have been established as the Glasgow Outcome Scale.

1. Death
2. Persistent vegetative state
3. Severe disability (conscious but disabled)
4. Moderate disability (disabled but independent)
5. Good recovery (leading normal or close to normal life)

Categories 1, 2, and 3 are considered unfavourable, the worst of all in terms of costs and social repercussions being number 2; categories 4 and 5 are favourable. Nonetheless, even in categories 4 and 5, the impact on family and friends can be exhausting.

Although useful, the GOS is a very broad classification system. Many patients suffering even mild concussion, especially after blast injuries, go on to develop various post-traumatic syndromes months or years later, with varying degrees of disability and psychological problems. The social repercussions of this phenomenon are attested to amongst many armies and societies.

<sup>16</sup> Erdogan et al., 2002.

<sup>17</sup> Jennett B, Bond M. Assessment of outcome after severe brain damage. *Lancet* 1975; 1: 480 – 484.

## ANNEX 26. A Trepanation

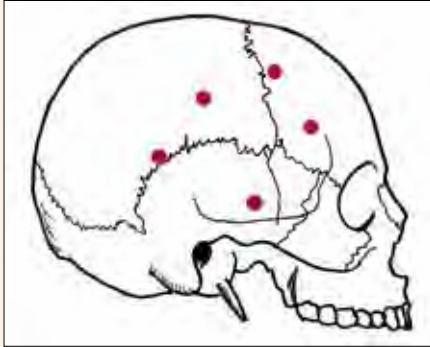
The trepanation of the skull is one of the oldest known surgical operations, practised in ancient Mesopotamia and Pharaonic Egypt. Herein follows a simple presentation. For greater detail the surgeon should refer to standard surgical textbooks.

### 26.A.a Clinical picture and indications for surgery

In blunt injuries, the most common intracranial bleeding is an acute subdural haematoma from rupture of small veins bridging the space between the cortex and the dura. An acute extradural haematoma usually arises from a rupture of the middle meningeal artery after a fracture of the temporal bone and gives rise to the classic phenomenon described as the "lucid interval".

Closed head injuries must be closely and repeatedly assessed and proper precautions taken for the cervical spine. The diagnosis of an intracranial haematoma is an emergency, especially if signs of brainstem herniation are present.

For closed head injury and in the absence of sophisticated diagnostic technology, the presence of focalizing signs or a fracture apparent on plain X-ray help the surgeon to decide where to trephine. If feasible, a direct puncture carotid angiogram performed by the surgeon (see Chapter 24.4.2) can help localize the haematoma. Otherwise, a series of blind burr holes must be made. In one third of the patients none will be found; in this case, a posterior fossa or intracerebral haematoma, or simple brain oedema is the culprit.



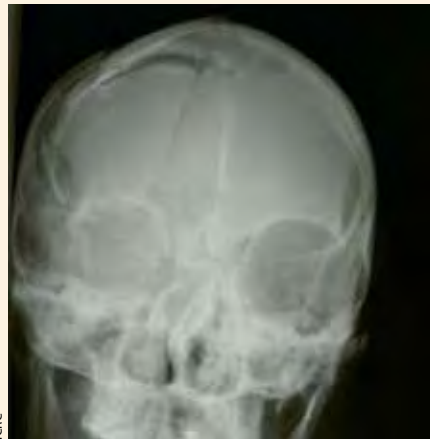N. Papas / ICRC

**Figure 26.A.1**

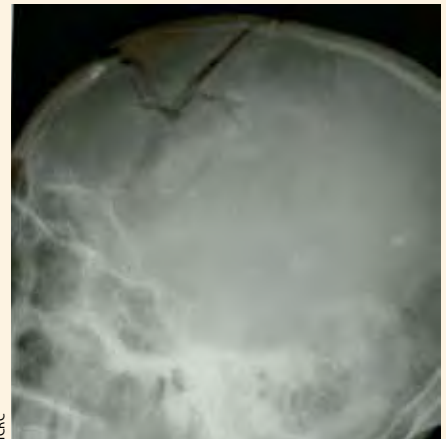Position of blind burr holes for intracranial haematoma. They can be connected thus converting them into a craniectomy.

**Figures 26.A.2 and 26.A.3**

Depressed cranial fracture after a blast injury with focalizing signs.

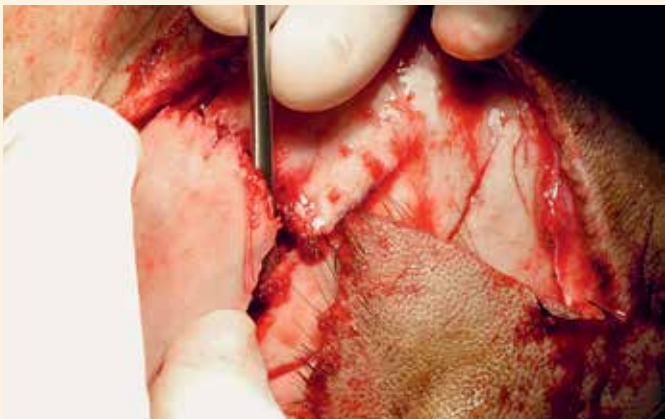

ICRC



ICRC

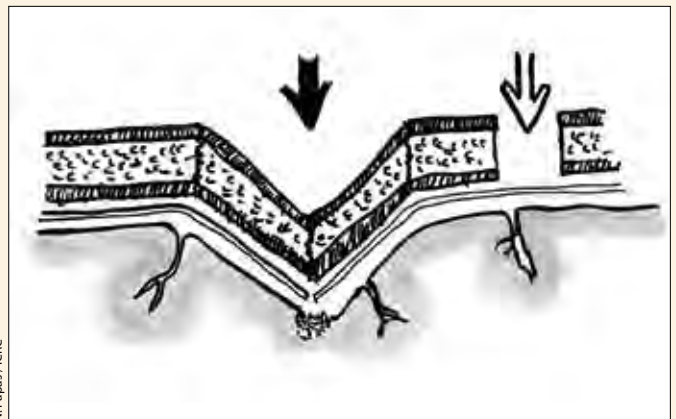
In cases of a tangential wound, the haematoma is most likely to underlie the fracture and the trepanation should be placed next to the fracture or the "gutter". In some patients, a direct approach to the fracture may be possible. Large projectiles, including falling bullets, that have penetrated the skull but remain superficial in the cerebral cortex are also readily removed by trepanation.



ICRC

**Figure 26.A.4**

Direct access to a depressed fracture and elevation by means of a dural elevator.



N. Papas / ICRC

**Figure 26.A.5**

Burr hole access to a depressed fracture; the depressed fragment can then be raised by a lateral approach.

## 26.A.b Operative technique of burr-hole trepanation

Preparation of the patient and anaesthesia are described in Section 26.9. The basic technique of burr-hole trepanation is the same for closed head injuries, tangential wounds or small fragment lesions.

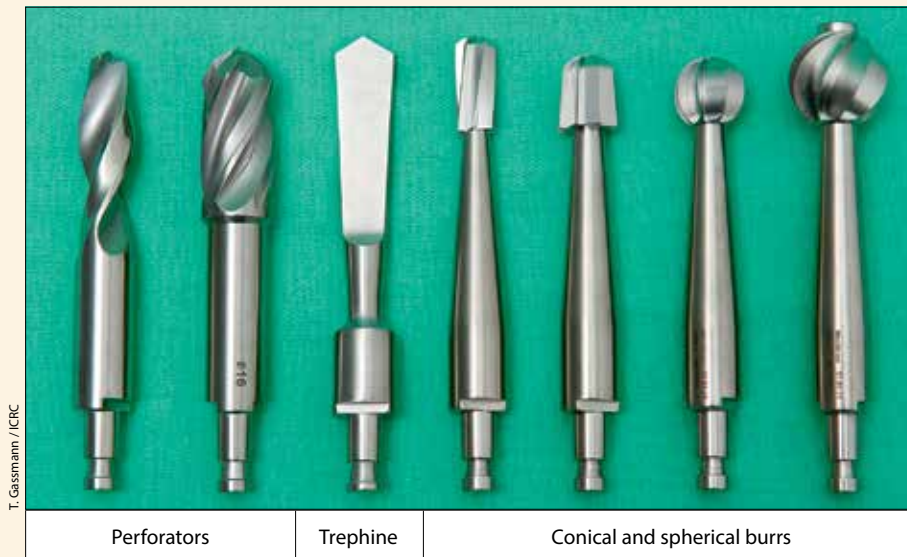

Figure 26.A.6  
Standard trepanation bits.

1. The site is infiltrated with a dilute solution of adrenaline from the skin down to the pericranium.
2. A 4 – 5 cm scalp incision is made and taken down to the bone; the soft tissues are retracted by a self-retaining retractor, which also provides haemostasis. Alternately, and depending on the pathology, a horseshoe-flap may be fashioned.
3. The tip of the perforator or the point of a trephine is placed and, using a hand drill, the outer table is slowly penetrated.

The surgeon encounters resistance, which yields when the diploe is reached. Further resistance is then encountered when reaching the inner table. Care must be taken not to puncture through the inner table with force. The hole is now funnel-shaped with a thin layer of inner table at the bottom.

4. A small spherical or cylindrical burr then replaces the perforator; once the hole is circular, a larger spherical burr is used. The axis of the drill must be maintained steady.

The speed of rotation of the hand drill should be decreased until, slowly, the inner table is breached, creating a small hole through to the dura, but a rim of inner table should be left in place.

Continuing until the opening is the same diameter as the burr risks pushing the burr into the brain substance. The risk is strongly enhanced if the axis of the drill and burr is not maintained always in the same direction, creating a precession movement which enlarges the bone defect irregularly.

5. A dural elevator is inserted to separate the dura from the bone, and then the tip of a bone-nibbling forceps is introduced to carefully enlarge the opening.

The general surgeon can practise trepanation on the skulls of locally available butchered animals: goats, sheep, or pigs; with due permission from the competent authorities and ethical committees, if present, and taking cultural norms into consideration.



Figure 26.A.7

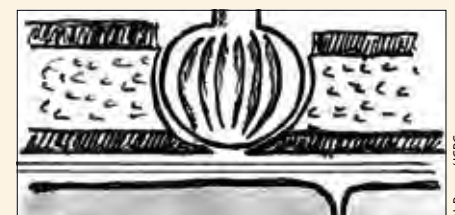

Figure 26.A.8

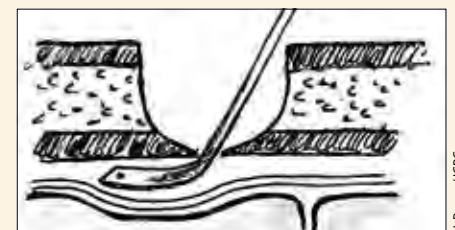

Figure 26.A.9

### 26.A.c Further surgical management

The burr-hole or holes having been accomplished, the surgeon must deal with the intracranial pathology: extradural, subdural or subcortical haematoma, or lacerated dura and brain cortex.

#### Clot evacuation

- Once through the inner table, an extradural haematoma instantly presents itself. A catheter is introduced immediately and the clot aspirated; the opening is then enlarged as necessary. The haematoma is very localized and can be totally missed if the burr hole is off by 1 – 2 cm; it is usually to be found strictly underneath a fracture.
- If the dura is bulging and deep purple in colour, it should be incised by an "X"-incision and the subdural clot evacuated before enlarging the opening. The clot is diffuse and always found if the opening is on the correct side.
- If the dura is bulging but normal pinkish-white in colour, it should be opened and the brain surface around gently explored with the dural elevator to make certain that the swelling is due to cerebral oedema and not a nearby subdural haematoma.
- Bulging, contused and purplish brain is indicative of a subcortical or intracerebral haematoma. Once the dura is incised, a subcortical clot often evacuates spontaneously through the contused cortex; otherwise, aspiration through a fine needle should be attempted.
- Lacerated dura and brain is gently debrided, and superficial spicules of bone removed.

No clot can be adequately evacuated through a burr hole; the opening must be enlarged by bone nibbling. As always, the biggest and commonest mistake is to attempt wound debridement through too small an incision. If the access required is large, the skin incision should be enlarged into a horseshoe and a bone flap fashioned. A dural elevator is carefully passed from one burr hole to another, and a Gigli saw threaded through. The bone is then cut. The bone flap is made by joining several burr holes in the same way and is replaced at the end of the procedure. If the brain is too oedematous, the flap is saved in normal saline in the blood bank refrigerator and replaced at a later sitting. Recently, a technique for temporarily "stocking" the bone flap in the subcutaneous fat of the abdomen has been described.

#### Haemostasis

Most extradural haematomas originate from a branch of the middle meningeal artery. The artery must be exposed and coagulated. Subdural haematomas typically arise from veins bridging from the cortex to the sagittal sinus, most commonly in the frontal region. These veins must be coagulated. Further haemostasis is the same as for an open injury.

#### Dural closure

The dura should be closed at the completion of the procedure. Drains should not be used beneath the dura, but a drain may be placed after evacuation of an extradural haematoma, to be removed 24 hours later.





## **Chapter 27**

# **MAXILLO-FACIAL INJURIES**

27.	MAXILLO-FACIAL INJURIES	
27.1	Introduction	285
27.2	Wound ballistics	286
27.3	Epidemiology	287
27.4	Clinical examination and emergency room care	288
27.4.1	Complete maxillo-facial examination	288
27.4.2	Establishment of an adequate airway	289
27.5	Decision to operate	290
27.5.1	Preparation of the patient	292
27.6	Haemostasis and debridement	292
27.6.1	Control of haemorrhage	292
27.6.2	Debridement and mucosal suture	294
27.7	Mandibular fractures	295
27.7.1	Vertical sling bandage	295
27.7.2	Maxillo-mandibular fixation	295
27.7.3	External fixation	298
27.7.4	Bone defect or non-union of the mandible	299
27.8	Midface fractures	301
27.8.1	Injuries of the maxillary sinus	302
27.8.2	Fractures involving the orbit	303
27.9	Skin closure	304
27.9.1	Specific sites	305
27.10	Post-operative management	305
27.11	Complications	306
27.11.1	Soft tissues	306
27.11.2	Osteomyelitis of the mandible	307
27.11.3	Limitation of mouth opening	307



## Basic principles

The wound always looks more horrendous than it is.

Airway control is of the utmost importance. Early endotracheal intubation or tracheostomy is often necessary.

Mechanism of injury: penetrating or blunt; the latter requires appropriate care of the cervical spine.

Once the airway is assured, a staged procedure may be considered. Delaying debridement is acceptable.

Uncomplicated wounds can be closed primarily after proper debridement.

Proper care of the soft tissues precedes fixation of bone or teeth.

Attention to function: the patient must be able to breathe, see, speak, chew and swallow afterwards.

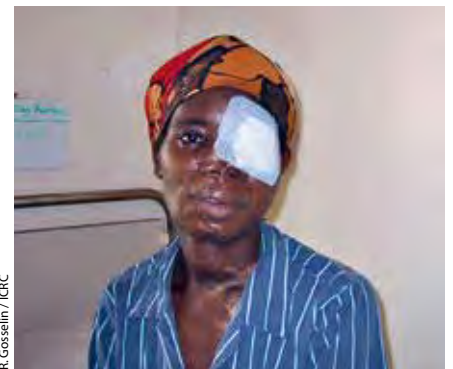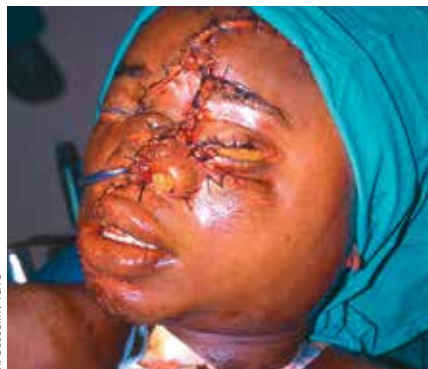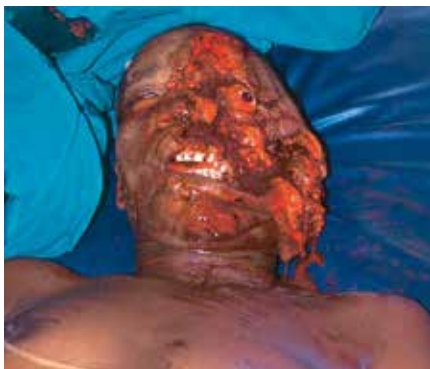## 27.1 Introduction

The face is an exquisitely distinct anatomic area – characteristic of each person's presentation to others and deformity, therefore, is a fundamental issue. Even more important than aesthetic concerns are the essential functions of breathing, seeing, chewing, swallowing, and talking.

The maxillo-facial region is composed of very heterogeneous bony and soft-tissue structures. The bones vary in density and thickness, and contain air sinuses that are colonized by a specific bacterial flora, as is the oral cavity. The well-vascularized soft tissues are very resistant to infection, but contamination from the sinuses and/or by saliva is a constant source of infection. The surgical management of maxillo-facial injuries must take all these considerations into account.

Wounds in the face can be very complicated and life-threatening because of the risk of airway obstruction, which may be delayed, and serious bleeding from areas difficult to access. These are real emergencies and a challenge for both anaesthetist and surgeon.

This chapter concentrates on projectile war wounds although blunt trauma also occurs during armed conflict.



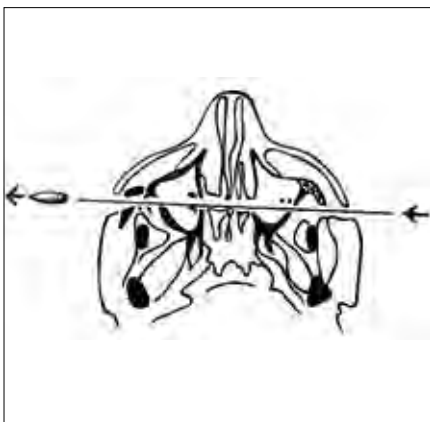
Figures 27.1.1 – 27.1.3

Maxillo-facial injuries are often complicated and life-threatening but the damage is usually less severe than at first sight.

## 27.2 Wound ballistics

The soft tissues of the face are delicate and very small; nothing like the mass of the muscular limbs or the abdominal viscera. Although most damage is due to direct crush or laceration and limited in scope, it represents a relatively large percentage of the volume of these small structures. It is the destruction and dislocation of these delicate elements that gives maxillo-facial wounds their “explosive” character on first inspection. In addition, the maxillo-facial region is not limited by bony structures, thus allowing spectacular accumulations of oedema and haematoma. The injury usually looks far more serious than it actually is. It should be noted, however, that large, sharp-edged fragments can provoke horribly mutilating lesions of the face that are survivable. The expression *gueules cassées* (broken faces) was coined in the First World War to describe these appallingly mutilated faces.

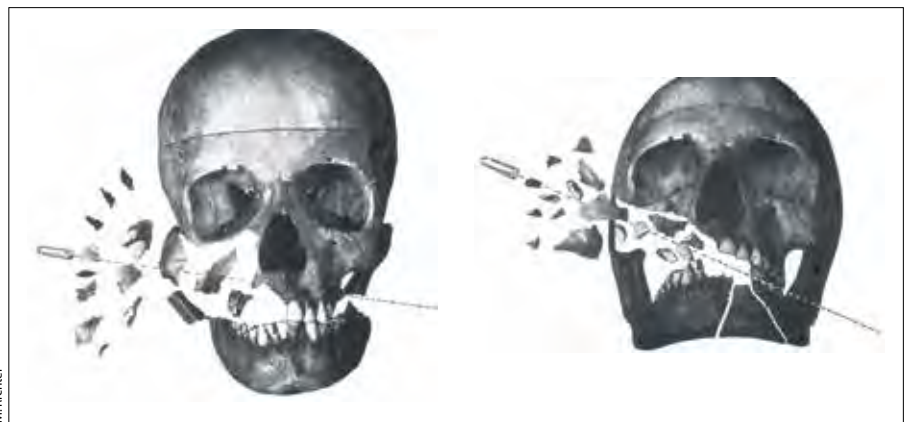
The ballistic effects of a bullet passing through the thin paper-like bone of the maxillary sinuses are shown in Figure 27.2.1 and contrast with a bullet’s effect on the thick and dense bone of the zygoma depicted in Figure 27.2.2.



N. Papas / ICRC

Figure 27.2.1

Through-and-through trajectory of an FMJ bullet passing through the thin bone of the maxillary sinuses. Note that there is no destabilization of the bullet.



M. Richter

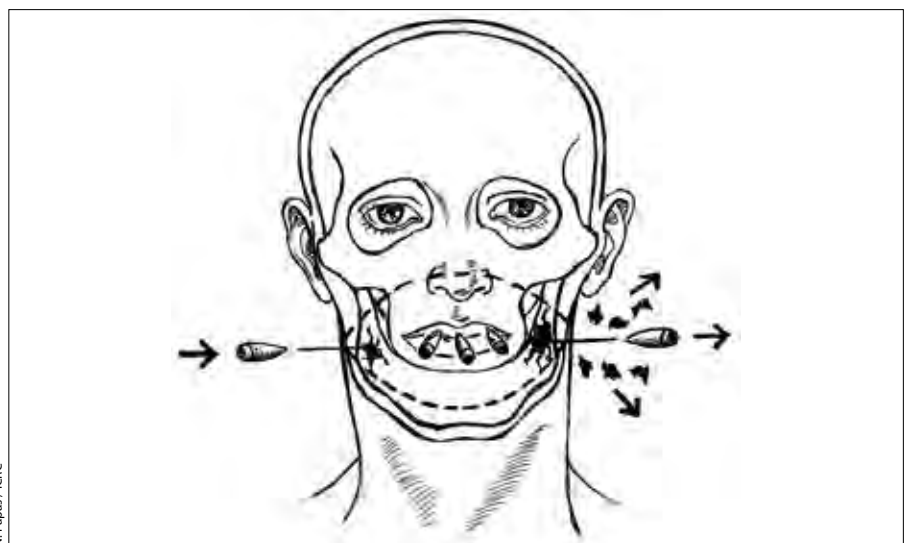
Figure 27.2.2

Bullet injury through the maxillary arch: multiple bone fragments projected outwards.

Cavitation effects are minimal with a stable high-energy FMJ bullet because the length of the trajectory in the face is insufficiently long. Cavitation upon entry does occur of course with a fragment or destabilized bullet. A low-kinetic energy bullet may be destabilized by striking bone and easily tumble in the mass of the tongue.

Figure 27.3

A low-energy bullet has been destabilized by the right ascending ramus of the mandible and tumbles in the mass of the tongue causing major comminution of the left ramus at the exit.



N. Papas / ICRC

A fracture of the mandible due to a bullet usually results in multiple bone fragments: each fragment acquires some kinetic energy, but their *cumulative* kinetic energy is necessarily less than the total energy transferred by the projectile during its passage.

Thus, each bone fragment has a relatively small quantity of kinetic energy, insufficient to serve as a secondary missile. About 20% of these lower mandibular segment wounds involve the neck as well, usually owing to the bullet's trajectory continuing into the neck.

More rarely, a bone fragment, tooth, dental filling or denture mobilized after an explosive blast may have sufficient kinetic energy to penetrate the skin of the neck. Blast injury can also result in open fractures of the air-containing sinuses, especially the maxillary and frontal.

### 27.3 Epidemiology

Historical epidemiological studies that differentiate the various head, face, and neck wounds are rare, and more recently an attempt has been made to rectify this (Tables C.1 and C.2). The clinically important points to note from various military studies are the large number of patients with relatively superficial wounds not requiring hospitalization and, in the head and neck region, the preponderance of wounds to the face (65%). Additionally, there is a high incidence of wound infection in hospitalized patients with face injuries.

One study of purely maxillo-facial combat injuries comes from the Iraq – Iran war. During one month of heavy combat 300 patients with isolated maxillo-facial injuries were admitted to a hospital in Basra in the south of Iraq: 80% of the wounds were due to fragments and 20% to bullets.<sup>1</sup> Soft-tissue injuries only were found in almost one third of the patients. Treatment involved simple measures in a large number of cases: debridement and primary closure (36%), maxillo-mandibular fixation (27%), or packing of the sinus (14%).

On the Iranian side, 1,135 patients with maxillo-facial wounds were treated in a major Tehran hospital: 52% had sustained bullet wounds, denoting a different tactical situation.<sup>2</sup> A large number suffered from the effects of delayed evacuation: infection, debilitation, blood loss, and malnutrition. Nonetheless, 72% of the patients were treated by soft-tissue debridement with or without maxillo-mandibular fixation (MMF), and primary closure.

Civilian statistics from Iraq show a very different pattern of lesions. The projectile maxillo-facial injuries in 100 patients treated in one year in a major specialized Baghdad hospital were due to a mixture of violence: conventional war, civil unrest, individual acts of terrorism, banditry, and personal assault (see Annex 6.C). This is borne out first by the mechanism of injury (49 wounds were due to rifle bullets; 29 to fragments; 15 to handgun bullets; 6 to airguns; and 1 to shotgun), and second by the demographics (79 were men and 21 women). Thirteen patients had soft-tissue injuries only; 87 had fractures (Table 27.1).

Site of skeletal injury	Patients with skeletal injury	Patients requiring urgent airway management
Mandible alone	56	20 (36%)
Middle third face/maxilla alone	22	2 (9%)
Combined maxillo-mandibular	9	5 (55.5%)
Total	87	27 (31%)

**Table 27.1 Correlation of patients requiring urgent airway management with site of skeletal injury; Maxillo-facial Surgery Unit, Hospital of Specialized Surgeries, Medical City, Baghdad: December 2003 – December 2004.<sup>3</sup>**

1 Sadda RS. Maxillo-facial war injuries during the Iraq – Iran war: an analysis of 300 cases. *Int J Oral Maxillofac Surg* 2003; **32**: 209 – 214.

2 Taher AAY. Management of weapon injuries to the craniofacial skeleton. *J Craniofac Surg* 1998; **9**: 371 – 382.

3 Kummoona R, Muna A. Evaluation of immediate phase of management of missile injuries affecting maxillo-facial region in Iraq. *J Craniofac Surg* 2006; **17**: 217 – 223.

Although this series of patients was treated in a specialized unit of a university hospital, several important clinical points are clearly of great relevance to the general surgeon.

- The importance of urgent management of the airway in 27% of patients, especially those with fractures involving the mandible. No patient with isolated soft-tissue injury required urgent airway management.
- Active bleeding was present in 19% of patients, and necessitated operative intervention for its control.
- Over half the patients were treated by simple debridement and primary closure; 46% had extensive soft-tissue lacerations, yet primary closure was nonetheless possible for 80% of these (the remainder were packed with iodoform ribbon gauze and left open for future reconstructive procedures).
- 75% of mandibular and 25% of maxillary fractures were treated with reduction and maxillo-mandibular fixation.
- There were a large number of associated injuries.

It should be kept in mind that studies from civilian referral centres are highly selective and do not give the entire picture. Many patients are treated in other facilities often by general surgeons and only the more complicated cases, especially of the maxilla, are transferred to specialist care.

## 27.4 Clinical examination and emergency room care

The initial examination and emergency care follow the standard ABCDE algorithm. The mechanism of injury determines the need to control the cervical spine. With penetrating projectile wounds, this is not as important as with blunt trauma (see Sections 7.7.2 and 36.5).

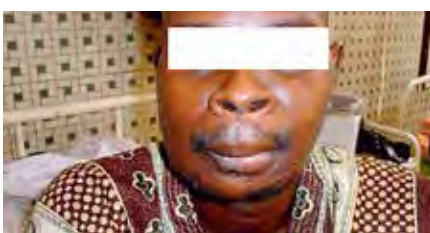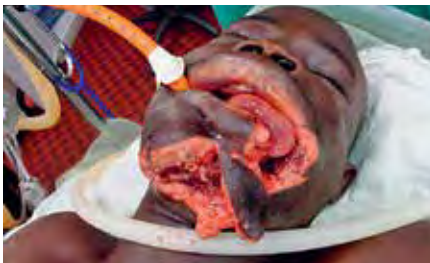The priority is obviously to secure and maintain an open airway. Maxillo-facial injuries are often associated with intracranial wounds and/or injuries to the neck, both of which can compromise the airway. Breathing problems may occur with aspirated foreign bodies or vomitus.

Haemorrhagic shock is uncommon with isolated maxillo-facial injuries, except in the event of laceration of the superficial temporal artery. Profuse bleeding from the soft tissues (anterior bleeding) or from deep fractures of the maxilla (posterior bleeding) may, however, compound blood loss from other injuries. Direct pressure controls most peripheral maxillo-facial bleeding. The head should be elevated once the danger of vomiting has been dealt with.

### 27.4.1 Complete maxillo-facial examination

Important specific points to note in the detailed examination of the maxillo-facial region itself include the following.

- The injury is often “spectacular”, but the tissue damage usually less severe than it appears at first inspection.
- Direct inspection of the mouth and pharynx must be carried out, to look for any loose or broken teeth or bone fragments, or continuing bleeding. This is necessary even in a conscious patient.
- Attention must be paid to delayed oedema formation that may block the airway.
- Occlusion of the teeth should be evaluated to determine future possibilities of bone immobilization.
- Associated ocular and orbital injuries should be noted, as they are the cause of much long-term morbidity, in particular those affecting the orbicularis oculi muscle – they require immediate action to prevent secondary corneal injury (see Section 29.13).



Figures 27.4.1 and 27.4.2

Maxillo-facial injuries are often spectacular.

- Sensory and motor impairments can be due to injury of the facial nerve.
- The chest and neck should be X-rayed to determine the presence of any detached or broken teeth, dentures or bone fragments that may have been aspirated. The surgeon should be aware of the possible pitfalls presented by resin artificial teeth and acrylic dentures that are at times difficult to detect on X-rays.
- X-rays of the maxillo-facial skeleton may be difficult to read for the non-expert.

Blockage of the airway may be immediate, or delayed owing to oedema formation.

#### 27.4.2 Establishment of an adequate airway

Asphyxia resulting from airway obstruction is the major cause of death in facial injuries. The portals for air entry can be obstructed by displacement and excessive mobility of the bony skeleton, oedema and haematoma, vomitus, blood, and “foreign” bodies (bone fragments, broken teeth and dentures). Missile injuries of the mandible usually involve the floor of the mouth and base of the tongue, causing loss of skeletal support to the airway and important oral bleeding and oedema.

1. Most conscious patients do not want to stay lying on their back. They spontaneously assume a sitting position with the head thrust forward, and should be permitted to do so. This position allows the facial skeleton and supporting structures to “fall” forward, thus helping to open the airway and let blood and saliva drool out.
2. The conscious patient lying in a supine or lateral position can swallow a great deal of blood, thus concealing any ongoing haemorrhage and provoking later vomiting.
3. The unconscious patient should be nursed in the lateral security position with the head tilted down to prevent blood and saliva being aspirated into the lungs. If the patient is intubated, blood spills out of the nose and mouth.
4. Dentures, broken teeth, blood and saliva should be *carefully* removed from the mouth and throat. Oral suction may provoke retching, which increases bleeding, or vomiting.

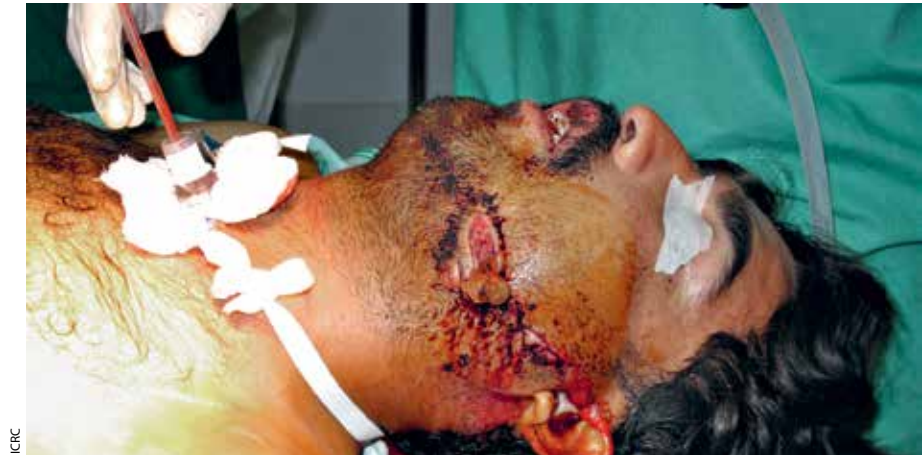Please note:

Vomiting with aspiration of the gastric contents is a constant danger and may be provoked not only by swallowed blood, but may also result from brain injury or alcohol intoxication. The emergency room staff should have a *clear protocol* to manage any sudden and unexpected vomiting: putting the patient in the lateral position while clearing the airway with high-flow suction, and then tilting the head down 30 cm is a simple and effective method.

5. The position of the tongue should be checked, especially with mandibular fractures. Simple methods to secure the tongue and prevent it from falling backwards and obstructing the airway include fixation by a thick suture or with a towel clip or Kirschner wire to an external structure or to the skin of the chest.
6. Endotracheal intubation should be performed if possible, as soon as possible. All patients with maxillo-facial injuries are challenging to intubate and it might prove impossible in those with severe wounds or copious bleeding. Nasotracheal intubation, useful for isolated mandibular wounds, is contraindicated for midface fractures as it is for fractures of the base of the skull.
7. Almost all major fractures of the mandible with significant bone loss require *tracheostomy*. A needle cricothyroidotomy may have to be performed *in extremis* while preparing for a surgical cricothyroidotomy (see Section 8.3.4). This is always a temporary measure and should be transformed into a tracheostomy as soon as possible.

**Figure 27.5**

Major injuries of the mandible almost always require a tracheostomy.



ICRC

#### Important emergency clinical points

- Control the AIRWAY.
- Control bleeding from disrupted soft tissues.
- Look for and remove bone fragments or broken teeth or dentures.
- Observe for delayed oedema formation.

## 27.5 Decision to operate

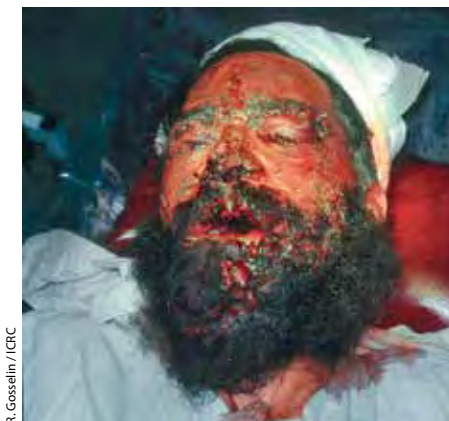The majority of projectile wounds to the maxillo-facial area are simple and isolated lacerations that are easily cleaned and closed primarily: one of the exceptions to the rule of delayed primary closure. Many others require simple maxillo-mandibular fixation as well. The recommended procedure is to deal with both soft-tissue and bone injuries at the time of initial debridement.

However, there is a great difference between the management of an isolated maxillo-facial wound and the management of the same wound when it is associated with other life-threatening injuries; or in the event of triage of mass casualties where it constitutes a Category II wound that can wait for surgery once the airway and bleeding are under control (see Chapter 9). Many maxillo-facial injuries can withstand delay before definitive treatment.

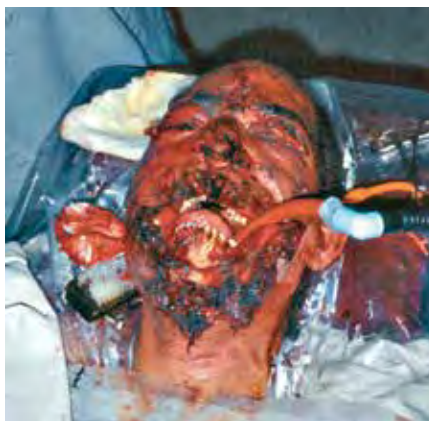A damage-control approach may be undertaken in such patients: tracheostomy if necessary, direct haemostasis and temporary immobilization using just a simple compressive sling bandage. Under less dire circumstances, conservative soft-tissue debridement followed by suture of the mucosa may also be performed. A delay to definitive surgery much longer than the usual 24 – 48 hours acceptable for abdominal damage control can be allowed, to let oedema and haematoma swelling subside and to plan for any reconstructive procedures.

This conservative approach may be the best for blast injuries too, because late tissue ischaemia due to shear injury of blood vessels often occurs; the increasing area of necrosis only gradually becoming apparent. Serial debridements may be necessary (see Section 10.8.2).

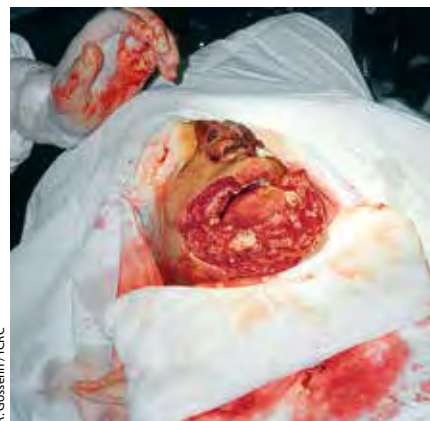Staged management is useful as a damage-control approach for blast injuries, and in late-arrival infected wounds.



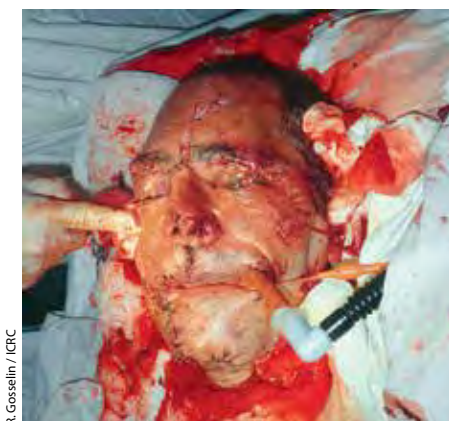R. Gosselink / ICRC



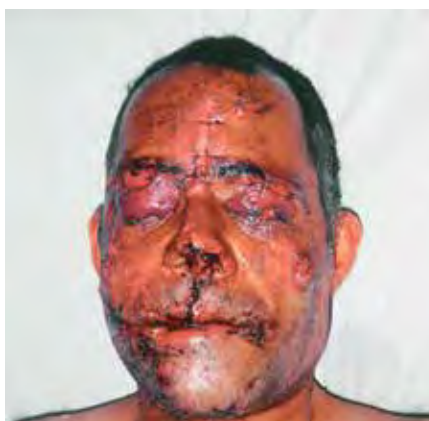R. Gosselink / ICRC



R. Gosselink / ICRC



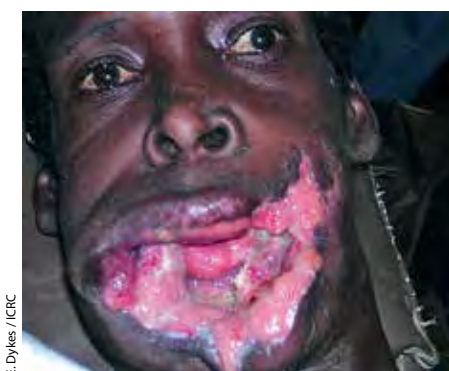R. Gosselink / ICRC



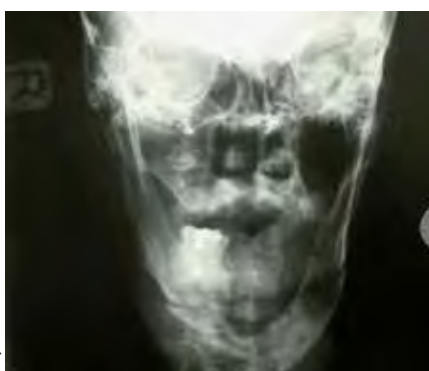R. Gosselink / ICRC

**Figures 27.6.1 – 27.6.5**  
Blast injury of the face managed with staged operations.

A staged management method is particularly useful for neglected wounds in patients who arrive late to hospital and are already infected. Arguably, the first 24 – 48 hours from the time of injury is most suitable for debridement and primary closure. After this interval, all wounds should probably be packed with gauze soaked in povidone iodine and irrigated daily with normal saline because of continuing contamination with saliva. Delayed closure allows the oedema to subside.



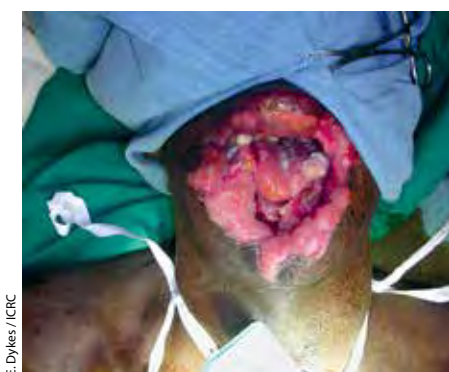E. Dykes / ICRC



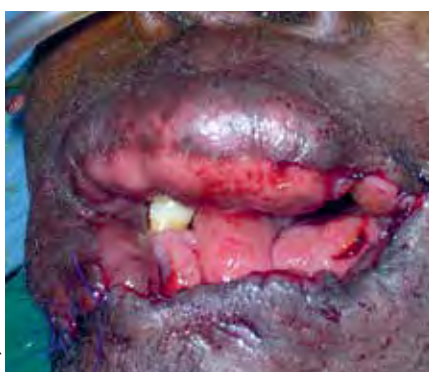E. Dykes / ICRC



E. Dykes / ICRC



E. Dykes / ICRC



E. Dykes / ICRC

**Figures 27.7.1 – 27.7.5**  
The patient arrived several days after suffering a gunshot wound. A staged approach resulted in a reasonably satisfactory outcome.

In very complex injuries with significant tissue loss requiring more sophisticated means of soft-tissue reconstruction, delayed repair in stages is the preferred option. Here too, daily saline rinsing of the wound and mouth is of the utmost importance.

### 27.5.1 Preparation of the patient

Operating on maxillo-facial injuries requires a secure airway. Nasotracheal intubation or tracheostomy is indispensable if maxillo-mandibular fixation is to be employed. In all cases, the pharynx should be packed to absorb blood and saliva. Severe injuries always require a tracheostomy for post-operative care.

A gastric tube is passed to empty the stomach of swallowed blood, and ocular ointment instilled into the conjunctiva. The patient's head is draped in a way that allows the surgeon the necessary mobility and the anaesthetist proper access to the airway.

#### Basic principles of maxillo-facial surgical management

1. Tracheostomy is mandatory if there is any danger of compromise of the airway.
2. Haemostasis is the next priority.
3. Conservative debridement of soft tissue and bone.
4. Repeated irrigation of the wound.
5. Restoration of the soft tissues and closure of the mucosa precede reconstruction of bony elements.
6. Occlusion of the teeth and immobilization of the jaws.
7. Closure of the skin wound.
8. Definitive reconstructive surgery by specialist techniques, if necessary.

## 27.6 Haemostasis and debridement

The airway now under control, operative priority goes to achieving haemostasis, which may be difficult given the disorganization of the injured tissues and the anatomic constraints of the confined area of the oral cavity and midface.

### 27.6.1 Control of haemorrhage

The source of bleeding may be peripheral (facial, temporal or lingual arteries) or central (maxillary artery). The management proceeds in progressive steps.

1. Direct pressure and elevation of the head to control peripheral bleeding.
2. Ligation of bleeding points that do not stop with the above measures. Accurate and targeted control of bleeding vessels is essential to avoid clamping of important structures.
3. Tamponade by means of gauze packs and a large Foley catheter (F20) placed in the wound cavity and the skin tightly stitched around it before inflation with normal saline. The tamponade should be removed within 48 hours.
4. Central bleeding in injuries to the middle third of the face (maxilla, nose, and ethmoid cells) may turn into major haemorrhage. Anterior and posterior oro-nasal and pharyngeal packing is the only way to manage such profuse bleeding if the wound has not exposed the vessels themselves.

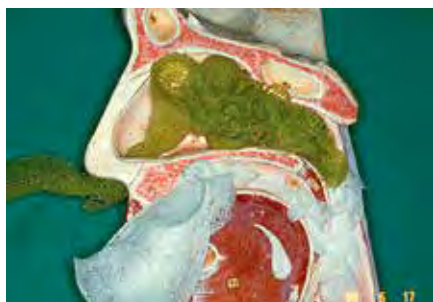


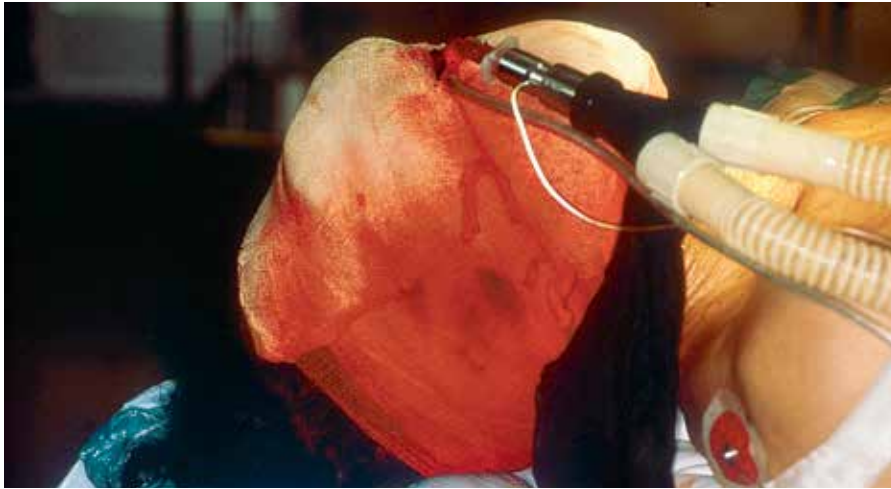
Figure 27.8

Anterior nasal phase of oro-nasal packing.



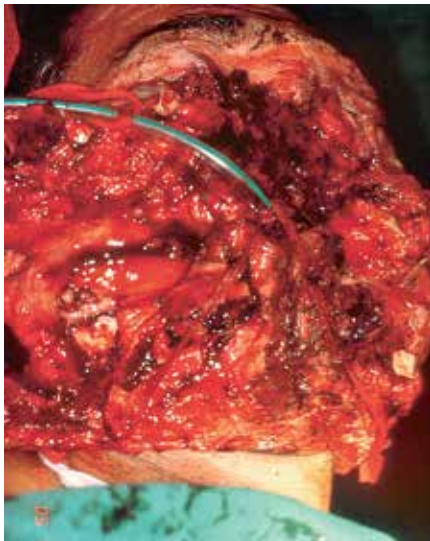
The mouth and pharynx are packed first with dry gauze. Anteriorly, the nasal and maxillary cavities are packed with 5 cm ribbon gauze soaked in povidone iodine and lubricated with vaseline or paraffin gauze to line the cavities. The face is then externally compressed with an elastic sling bandage to prevent oedema and haematoma accumulation (see Figure 27.12).

All packs should be removed or changed within 48 – 72 hours.



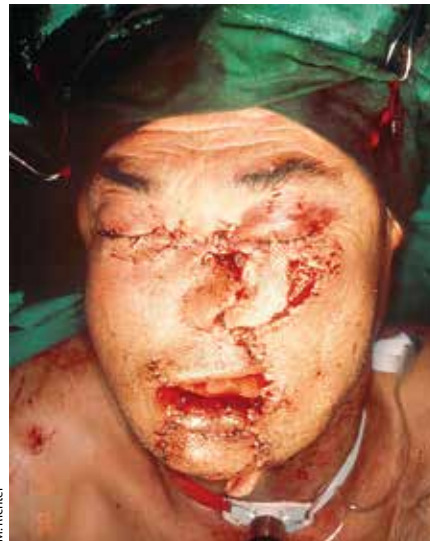**Figure 27.9.1**

Patient arrival in the ER. A compressive bandage was placed in the field.



**Figure 27.9.2**

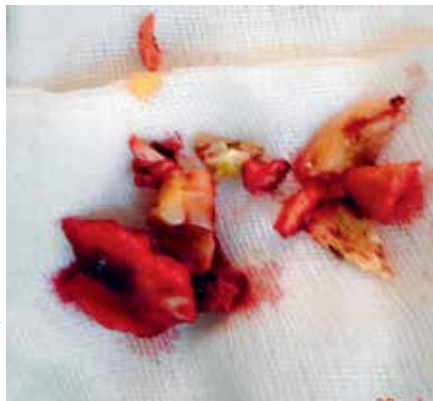Removal of the bandage revealed an avulsion injury of the face.



**Figure 27.9.3**

Haemorrhage was finally controlled by suture of the soft tissues over anterior and posterior packing.

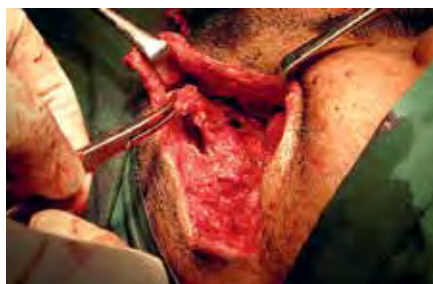5. Ligation of one or both external carotid arteries is a last resort. This is usually not necessary if anterior and posterior packing is possible and can be properly done. The risk of bilateral ligation is ischaemic necrosis of the tip of the nose or the floor of the mouth. It should be noted that the midface is supplied bilaterally from both the external and internal carotid arteries. Therefore, ligation of the external arteries on its own may be insufficient to stop bleeding and should be accompanied by packing to the extent possible.



H. Nasreddine / ICRC

Figure 27.10.1

All loose teeth and bone fragments must be removed.



ICRC

Figures 27.10.2

Attached bone fragments should be retained.

Figure 27.11

Closure of the oral mucosa; in this case a continuous suture reinforced by interrupted sutures to avoid tension on the suture line.

## 27.6.2 Debridement and mucosal suture

The remaining skin is scrubbed with a hard brush to remove any superficial particles causing "tattooing". The wound edges are excised *very conservatively*. Soft-tissue tags that are not clearly necrotic should be preserved. The blood supply to the face is generous and adequate for nearly all tissue, no matter how contused or small the remaining pedicle, which allows a minimalist approach.

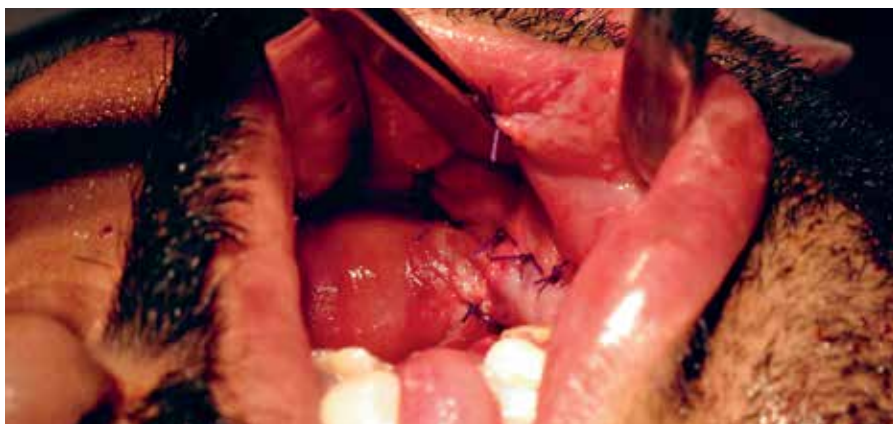Debridement of the well-vascularized soft and bony tissues of the face should be conservative.

All foreign bodies and loose teeth are removed but any bone attached to periosteum or muscle should be left *in situ*. Once any excess cortical bone has been removed, free cancellous bone fragments, washed clean, can be used as though they were a bone graft. As much periosteum as possible should be preserved.

The wound and all fractures are copiously and repeatedly irrigated during debridement.

The mucosa of the inferior oral cavity is then *closed watertight* prior to fracture reduction and immobilization. Closure is performed if possible in two layers by continuous suture, but without tension. This is to prevent continuing contamination of any fracture and the tissues of the floor of the mouth and neck with saliva, and to avert the formation of a salivary fistula. Closure should be attempted no matter how deforming it appears to be; the soft tissues usually fall into place adequately once the fracture has been immobilized and the skin closed. Any bare area of the mandible should be protected by a plug of iodoform-vaseline gauze.<sup>4</sup> Osteomyelitis of the mandible is the most common and devastating complication.

Closure of the inferior oral mucosa is mandatory, *before* immobilization of the fracture.



ICRC

Direct closure of the tightly adherent mucosa covering the hard palate is *not* required, and in any case impossible. A small hole in the bone may be closed by raising a mucosal flap; any bare area will re-epithelialize spontaneously. On the other hand, the soft palate should be repaired as much as possible. Further reconstructive operations are best left to the specialist and can be performed later.

<sup>4</sup> Iodoform-vaseline gauze can be improvised by using gauze soaked in povidone iodine and lubricated with vaseline. Vaseline stimulates the formation of granulation tissue and does not provoke bleeding when the gauze is removed. Chlortetracycline ointment can replace iodoform-vaseline if available.

## 27.7 Mandibular fractures

The management of maxillo-facial fractures can in many ways be considered “facial orthopaedics”<sup>5</sup>. The same general principles apply, particularly the attention that must be paid to associated soft-tissue damage in what are grossly contaminated wounds. The presence of saliva means that every fracture situated in the toothed part of the mandible, even if the fracture site is not open to the skin, must be approached like an open fracture.

There are a number of methods available to immobilize mandibular fractures but if the general condition of the patient is poor or there is a great deal of bleeding and oedema, temporary immobilization can be performed and final fixation can wait for up to one week. The ultimate aim is to ensure functional occlusion of the teeth through good healing of the bones.

### 27.7.1 Vertical sling bandage

The simplest and most rapid method of immobilization is to use an elastic bandage slung under the jaw and wrapped over the vertex of the skull. This is excellent for temporary immobilization, non-dislocated fractures, or for mandibular fractures that cannot otherwise be immobilized (see Figures 27.22.1 – 27.22.5).

### 27.7.2 Maxillo-mandibular fixation

Maxillo-mandibular fixation, also called intermaxillary fixation, is the standard method for mandibular fracture immobilization and allows for osseous healing within six weeks, four in adolescents and young adults. The principle of MMF is to use the teeth to indirectly immobilize the bone fragments in their proper relation.

After closure of the mucosa, reduction of the fracture is obtained manually by restoring normal occlusion between the upper and lower teeth. Immobilization of the upper dental arch to the lower arch is obtained by splinting. Two methods of application are described: arch bars, which are preferred, but not always available; and wiring.

#### Maxillo-mandibular wiring

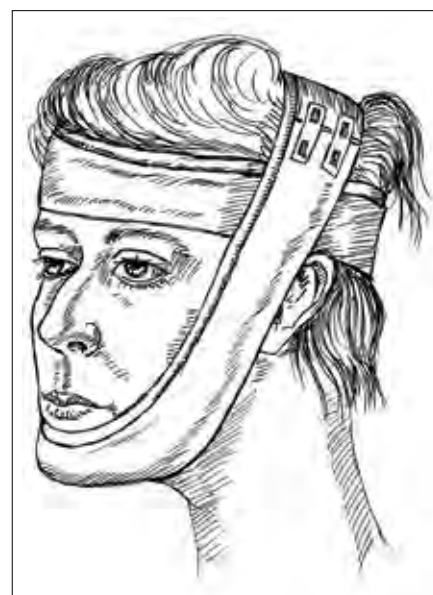This is the simplest method of MMF and is to be preferred in simple fractures provided there are enough opposing teeth in both jaws for accurate occlusion, and when more sophisticated methods are not available. The procedure involves fixing the two jaws together with flexible non-corrosive soft wire that has been pre-stretched.

Maxillo-mandibular wiring requires soft steel wire strong enough to hold the bone fragments with stability, yet thin enough to pass through the narrow interdental spaces without causing undue discomfort or gum irritation. Some specialists use the Ø 0.40 mm size; others prefer a slightly thinner wire. The ICRC intermaxillary wiring set provides Ø 0.40 mm and Ø 0.25 mm sizes.

Special wire-cutters and surgical pliers with various angulations, as well as dentistry instruments, exist for the handling of the wire. In their absence, the surgeon can improvise with Kocher and haemostat forceps and workmen’s tools, properly sterilized.

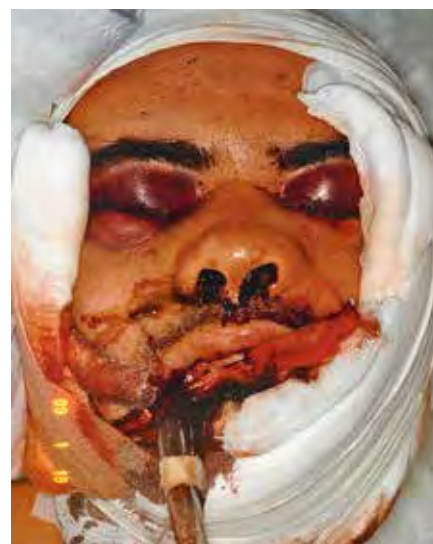For the non-specialist, it is easier to immobilize the fracture *before* closing the skin. The manipulation of pliers and wires in the confines of the oral cavity with the soft tissues and skin sutured up can be very challenging. The presence of a dentist colleague facilitates the procedure.

Numerous variations of maxillo-mandibular wiring have been described; three are proposed here and should be adapted to the particular patient, depending on the extent of bone loss and the number of teeth remaining.



N. Pappas / ICRC

27



M. Richter / ICRC

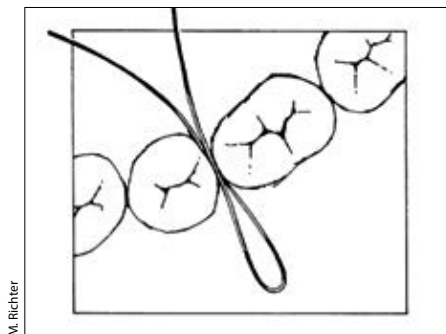
Figures 27.12.1 and 27.12.2

Vertical sling bandage to provide external compression.

5 Perry M, Dancey A, Mireskandari K, Oakley P, Davies S, Cameron M. Emergency care in facial trauma – a maxillo-facial and ophthalmic perspective. *Injury* 2005; **36**: 875 – 896.

**Ivy ligature**

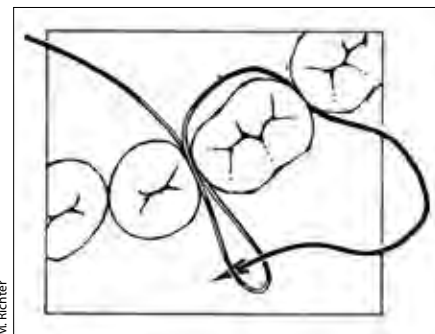
Eyelets of stainless steel wire are fashioned on the labial aspect of the gums and anchored to adjacent teeth of the upper and lower jaws; tie wires or rubber-band loops are then passed through them to provide splinting. Two or several eyelets are placed on each jaw according to the fracture site, degree of bone comminution, and number of remaining teeth: a useful technique if there has been loss of teeth.



M. Richter

**Figure 27.13.1**

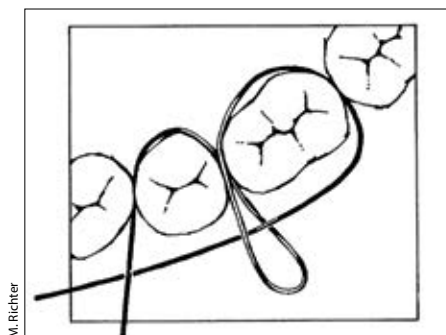
A loop of wire (Ø 0.25 or 0.40 mm) is passed between two teeth, from lingual to labial side.



M. Richter

**Figure 27.13.2**

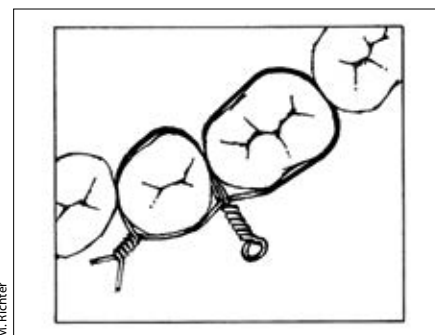
One free end is passed around the neck of one tooth and brought forward. It is then passed through the loop.



M. Richter

**Figure 27.13.3**

The other free end is passed around the other tooth and brought forward.



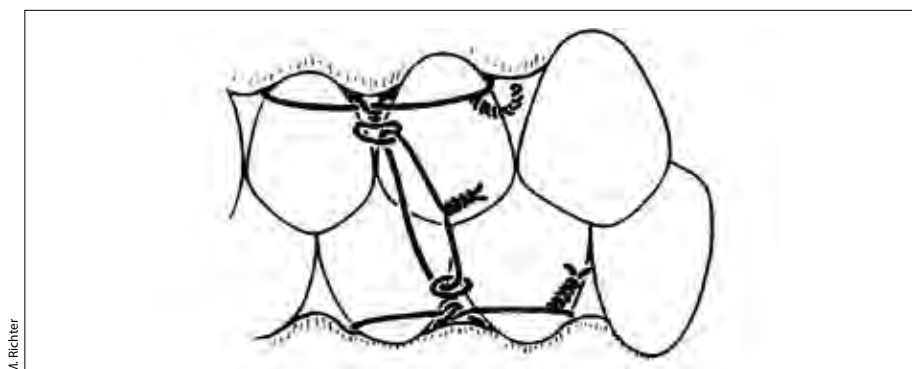
M. Richter

**Figure 27.13.4**

The free ends are twisted together to entrap the adjacent teeth. The eyelet is formed by twisting the loop around a dental burr or the tip of a haemostat. All twists for eyelets should be in the same clockwise direction.

**Figure 27.13.5**

Intermediate tie wires of a thinner gauge (Ø 0.25 mm) or rubber bands join the upper and lower eyelets accomplishing intermaxillary fixation.



M. Richter

**Multiple interdental eyelets**

If enough teeth are present, a more stable fixation is provided by multiple Ivy ligatures. This technique is excellent if arch bars are not available and in the event of a major unilateral loss of mandibular substance.

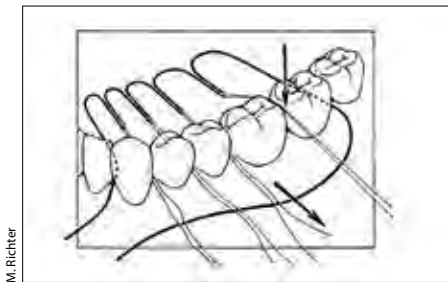


Figure 27.14.1

Interdigital passing wires of a thin calibre ( $\text{\O} 0.25 \text{ mm}$ ) are used to help pass the thicker and sturdier fixation wires between the teeth.

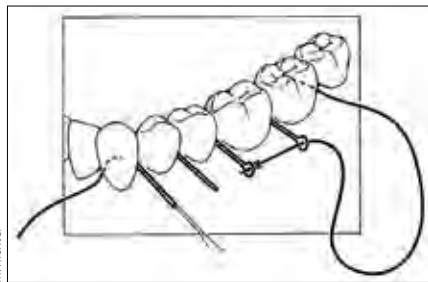


Figure 27.14.2

Interdigital passing wires have been removed. One loose end of the fixation wire is passed through the interdental loops, as for the Ivy ligature.

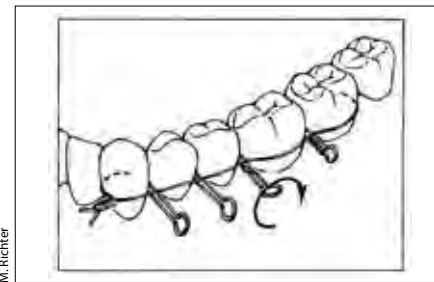


Figure 27.14.3

Multiple eyelets are formed by twisting the loops, all in a clockwise direction. Again as for Ivy ligature, intermediate tie wires of a thinner gauge ( $\text{\O} 0.25 \text{ mm}$ ) or rubber bands join the upper and lower eyelets accomplishing intermaxillary fixation.

### Ernst ligature

These rapidly fashioned ligatures are appropriate as a temporary holding measure to prevent displacement and relieve pain until more definitive immobilization can be accomplished.

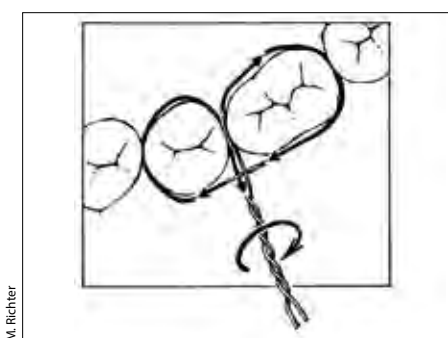


Figure 27.15.1

Ernst ligature: there is no interdental loop. One large loop encloses two adjacent teeth on the labial side and the two free ends are brought out between the teeth from the lingual to the labial aspect, one passing above and the other below the transverse wire and then twisted together.

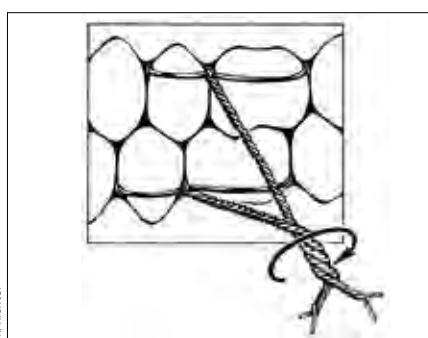


Figure 27.15.2

The mandibular and maxillary wires are kept long enough to be twisted together avoiding the need for separate tie wires.

### Arch bars for maxillo-mandibular fixation

A more sophisticated version of MMF is provided by commercially available arch bars made of malleable metal, available in pre-cut lengths (Erich, Dautrey, Schuchardt, etc.): a much preferred technique if the components are available. One arch bar is placed on the upper jaw and one on the lower and they are then firmly fixed with stainless steel wire to each remaining tooth; intermediate tie wires or rubber bands then join the two bars. This technique is particularly useful in patients with teeth missing, and especially if a dental colleague is present.



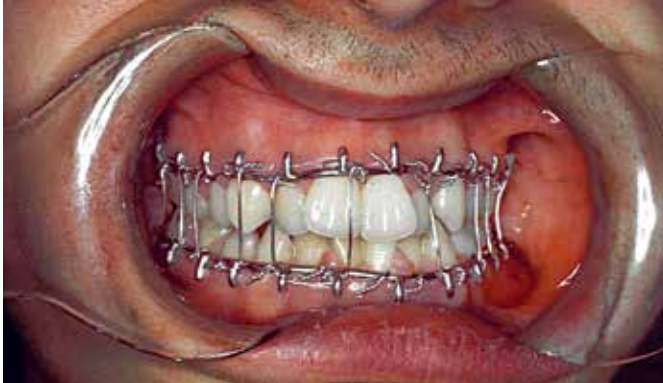Figure 27.16

Malleable prefabricated Dautrey arch bar with hooks.

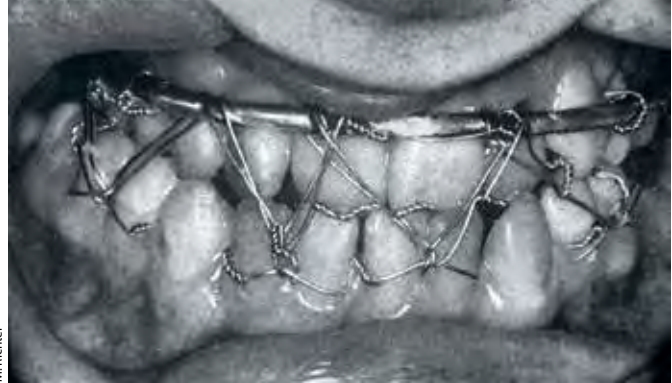The arch bar is easily contoured by hand to fit the outer surfaces of the maxillary and mandibular teeth. Care should be taken to place each bar with the *hooks directed toward the gums*. The hooks take the place of interdental loops. Both bars should extend completely around the dental arch and be placed in a manner that avoids irritation to the gingival margin.

The bar is ligated to each tooth with stainless steel wire (Ø 0.40 mm) passing around the neck of the tooth, from labial to lingual side and then back through on the opposite side of the tooth. One end of the wire is above the bar and the other below. By twisting the two ends of wire together, the bar is tightly fixed around the neck of the tooth. To facilitate the adjustment of the cut twisted ends, it is advisable to twist all wires in a clockwise direction. Several tie wires or rubber bands are interlocked between the hooks of the upper and lower arch bars to complete the maxillo-mandibular splinting.

A combination can be made of arch bar and multiple dental eyelets.



**Figure 27.17**  
Arch bar maxillo-mandibular fixation.



**Figure 27.18**  
Intermaxillary fixation with upper arch bar and lower dental eyelets.

A tracheostomy is mandatory if there is any risk of compromise to the airway, especially if it is due to oedema or in a comatose patient.

With MMF, if an emergency such as vomiting occurs and the mouth has to be opened quickly, the intermediate tie wires or rubber bands can easily be cut with a wire-cutter or scissors, which should *always be kept at the patient's bedside*. Both the patient and the attendant nursing staff must be instructed in their use.

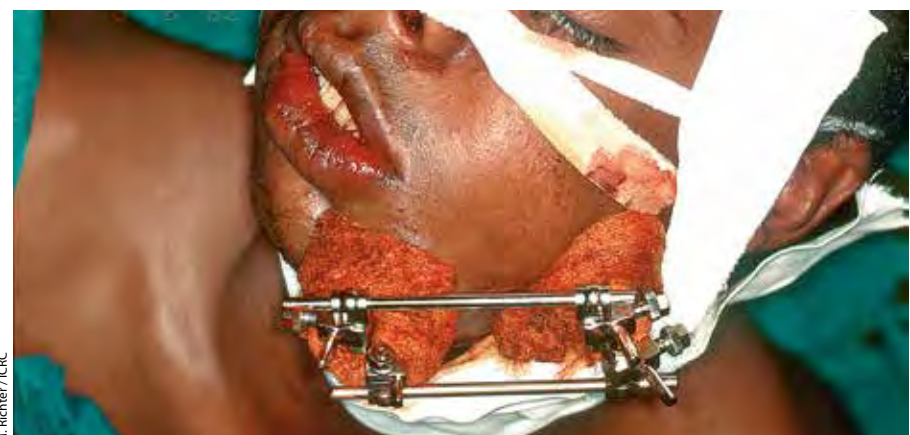If the patient is not capable of compliance, for example if confused after a head injury, either a tracheostomy should be performed or the eyelets or bars applied and left free for a few days before applying the intermaxillary ties.

A wire cutter or scissors should always be kept at the patient's bedside if intermaxillary fixation has been used – and the patient must be instructed in their use.

### 27.7.3 External fixation

Mini-external fixators are a very effective method for immobilizing fractures of the mandible with *extensive soft-tissue damage and bone defect*. It is the only fixation method that allows mandibular movement and function.

**Figure 27.19**  
Mini-external fixator. Stabilization of the fractured mandible.



After mucosal closure, the fracture is reduced and temporarily immobilized with maxillo-mandibular wiring, of the kind used for the Ernst ligature, in order to assure correct occlusion. The muscles and skin are closed and then the pins are placed. This is the only immobilization method where the soft tissues of the face should be closed first, in order to prevent tethering them in the wrong position. The pin bars must be inserted in a three-dimensional manner to prevent rotational movements. Once a stable immobilization of the bone fragments has been achieved with the external fixator, the intermaxillary fixation is removed.

Temporary MMF is mandatory before placement of the external fixator.

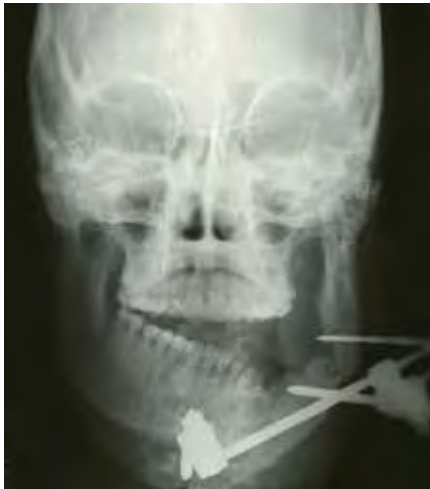

Figure 27.20.1

X-ray of a patient treated with mini-external fixation without prior temporary MMF: excellent consolidation of the bone.

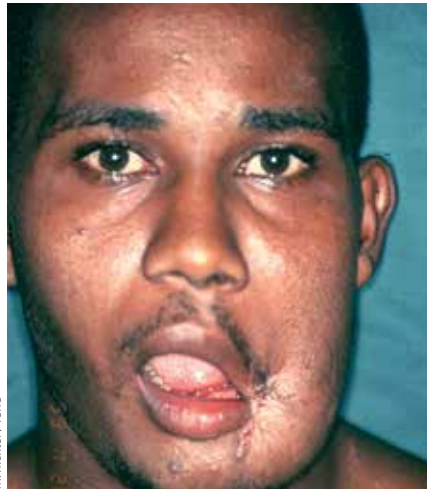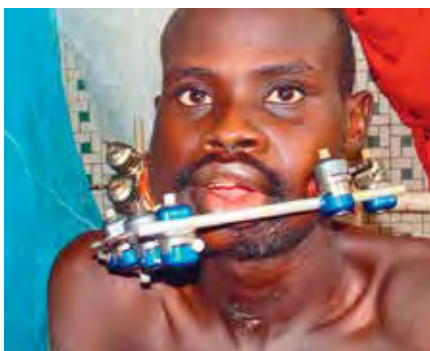


Figure 27.20.2

After removal of the external fixator, the patient is unable to eat because of a major impediment to occlusion of the upper and lower jaws, which resulted from not using temporary maxillo-mandibular fixation.

### Alternatives

If mini-external fixators are not available, improvisation with standard fixators and small Steinmann pins or Schanz screws can be resorted to.



Figures 27.21.1 and 27.21.2

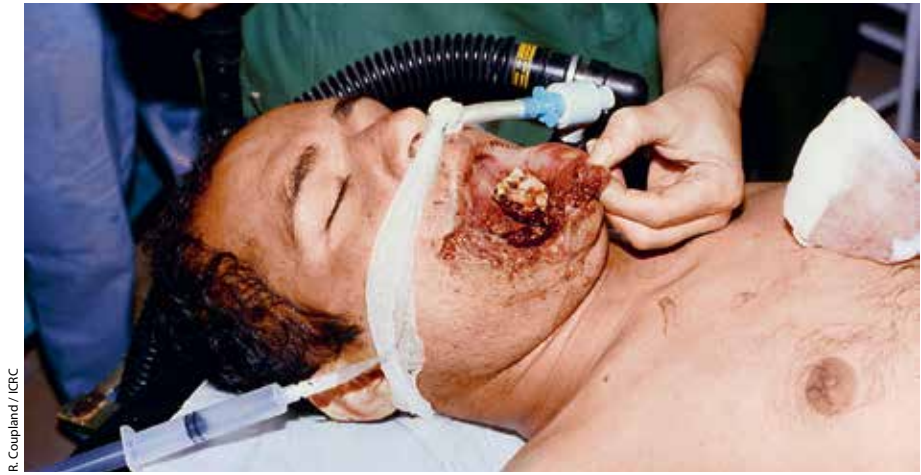Maxillo-facial immobilization using standard external fixator.

### 27.7.4 Bone defect or non-union of the mandible

Repair of bone defects may be contemplated at a later date. However, reconstruction of mandibular defects is a challenge, often requiring specialist techniques. Non-union of the mandible due to a bone defect is unusual if the periosteum has been preserved, as demonstrated in the patient in Figures 27.22.1 – 27.22.5 and 27.23.1 – 27.23.2. A conservative approach can prove fruitful and, just as with limb orthopaedics, there should be no hurry to proceed to grafting. Given enough time and a nutritious diet, defects become smaller.

Figure 27.22.1

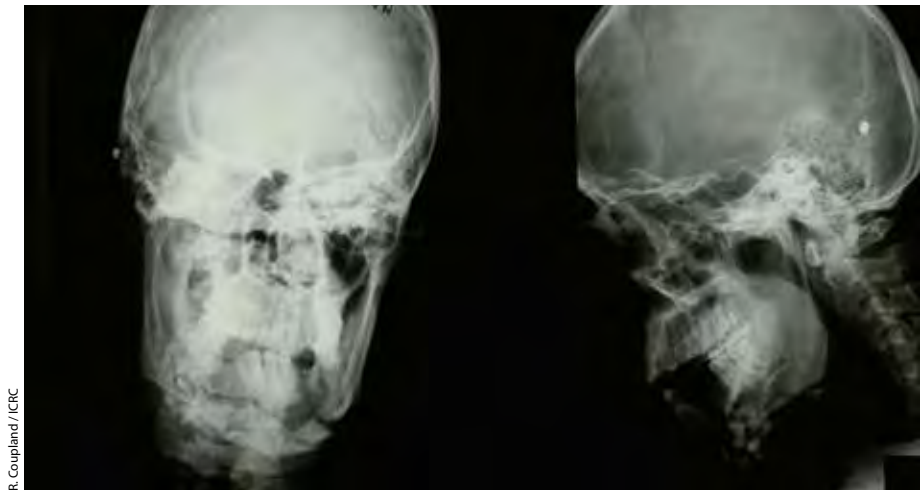
Patient pre-operative: extensive injury to the mandible and soft tissues of the floor of the mouth.



R. Coupland / ICRC

Figure 27.22.2

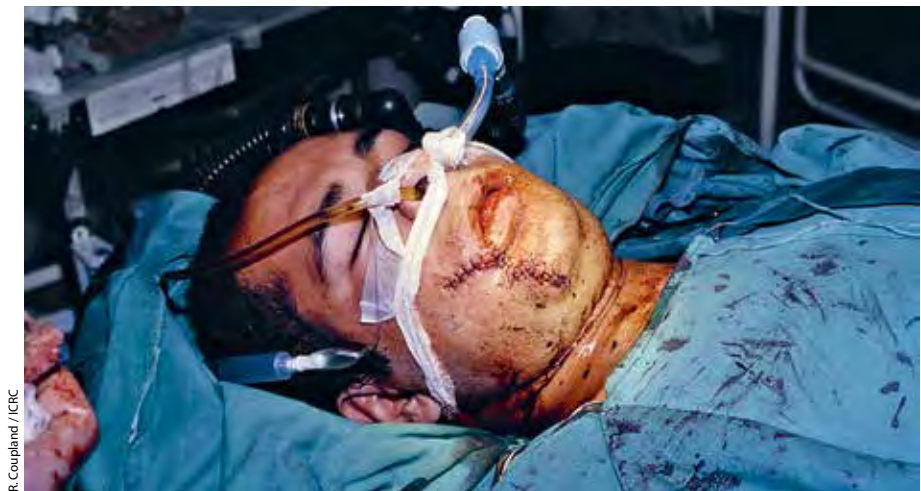Pre-operative X-ray showing severe comminution of the mandible.



R. Coupland / ICRC

Figure 27.22.3

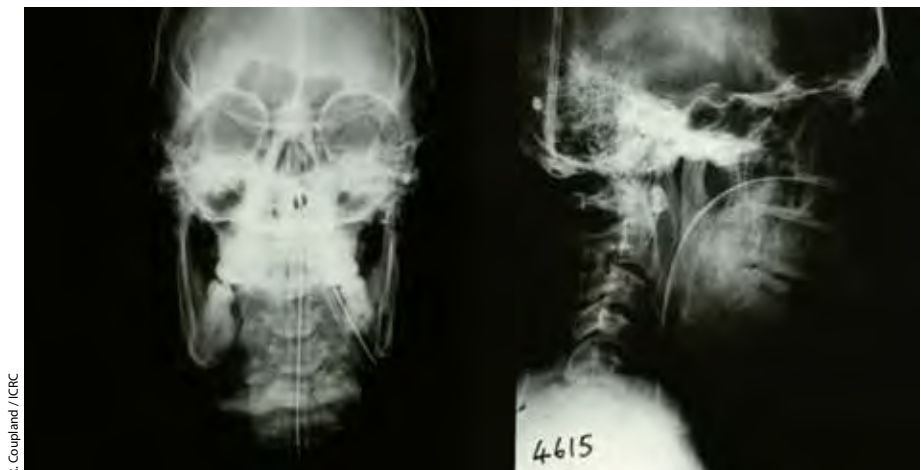Patient post-operative. Closure of the mucosa and skin has been achieved. Immobilization was ensured by a simple sling bandage.



R. Coupland / ICRC

Figure 27.22.4

Post-operative X-ray showing complete loss of the horizontal rami and symphysis menti.



R. Coupland / ICRC

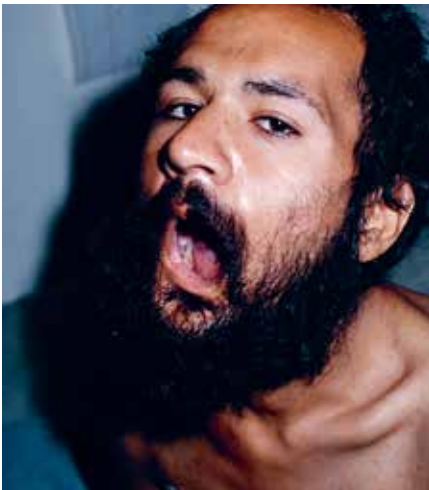



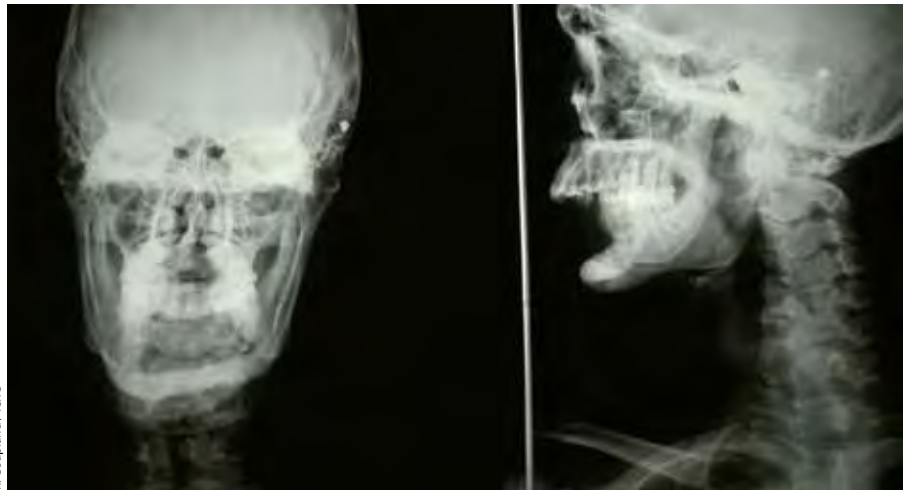Figure 27.22.5

Patient three weeks post-operative enjoying a semi-solid meal

R. Coupland / ICRC



R. Coupland / ICRC



R. Coupland / ICRC

Figure 27.23.1

Same patient on a return visit after a second war trauma, 24 months later.

Figure 27.23.2

X-ray on follow-up visit: osteogenesis from the remaining periosteum has completely replaced the missing bone.

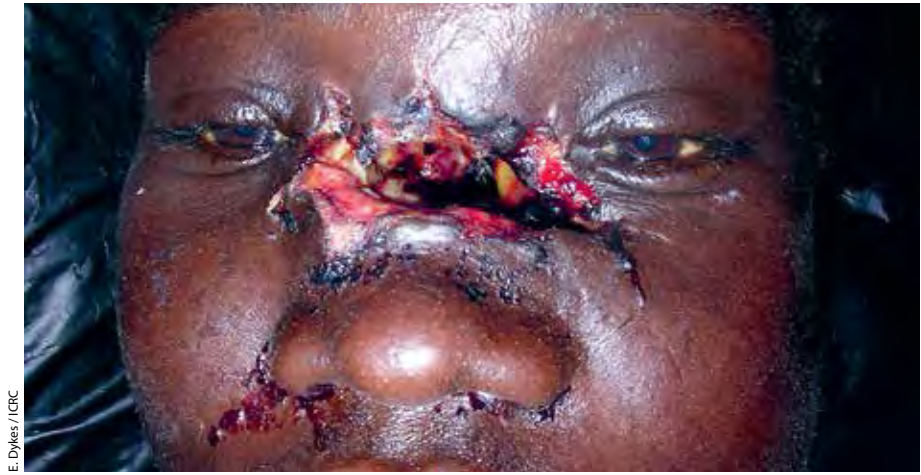When grafting is necessary, a graft from the iliac crest as a combined cortico-cancellous block provides good shape, bulk, and rigidity. Maxillo-mandibular fixation for six weeks is mandatory to prevent movement between the graft and the mandibular fragments. More sophisticated procedures, such as bone grafting using a rib, a myo-epithelial flap or osteo-muscular free flaps, are the domain of the specialist.

## 27.8 Midface fractures

There is a great variety of midface fractures yet, with projectile injuries they are often not as complex as they seem or as occurs with blunt trauma. Patency of the airway and control of haemorrhage are, as always, the essential emergency concerns. Many useful tamponade techniques to control bleeding have been described. In a shattered maxillary sinus, simple straightforward packing is best, removed or replaced after 48 hours. There are few projectile fractures of the maxilla that require reduction or fixation after debridement, in contradistinction to those caused by blunt trauma.

**Figure 27.24**

Projectile wounds are often not as complex as injuries due to blunt trauma, but are challenging nonetheless.



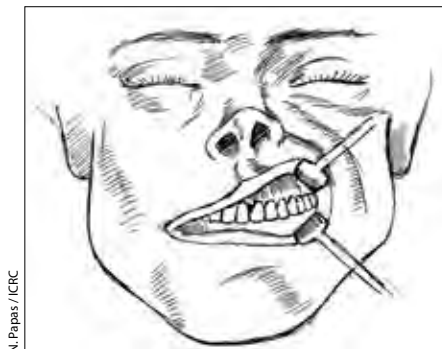E. Dykes / ICRC

**27.8.1 Injuries of the maxillary sinus**

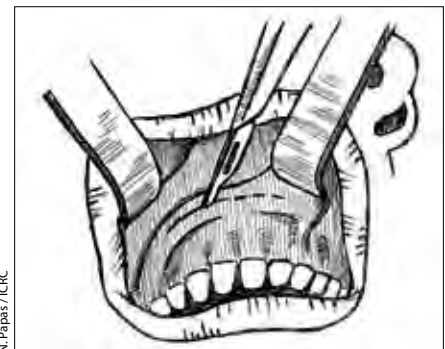
Transfixing through-and-through bullet wounds result in relatively little soft-tissue or bone damage. Entry and any exit wounds should be conservatively debrided and closed, leaving the simple hole in the bone as it is. However, blood often accumulates in the sinus and becomes infected if not properly drained. Drainage of the maxillary sinus is best accomplished through an intra-oral approach in the upper bucco-labial sulcus as is done for drainage of chronic sinusitis, using the Caldwell-Luc approach.<sup>6</sup>

**Figures 27.25.1 and 27.25.2**

Caldwell-Luc approach. A 2.5 cm incision in the oral mucosa of the bucco-labial sulcus is centred above the root of the canine tooth.



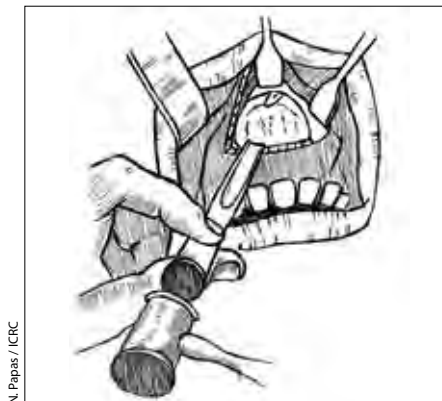
N. Pappas / ICRC



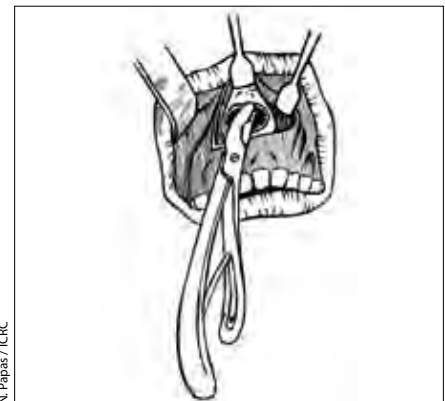
N. Pappas / ICRC

**Figures 27.25.3 and 27.25.4**

The muco-periosteum is elevated. The antrum of the sinus is then entered with a gouge chisel and the opening enlarged with a bone nibbling forceps.



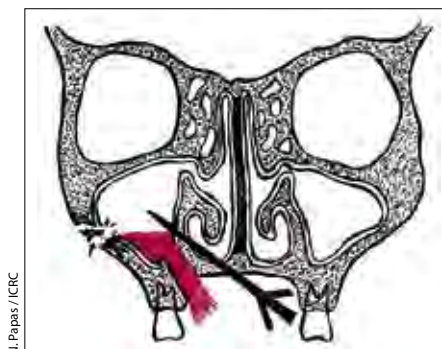
N. Pappas / ICRC



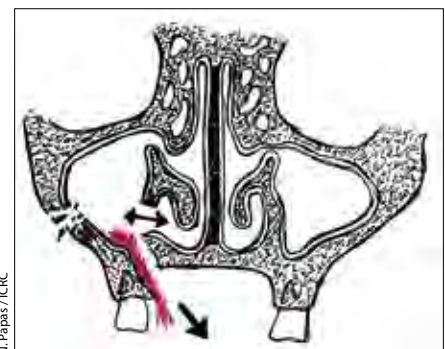
N. Pappas / ICRC

**Figures 27.25.5 and 27.25.6**

An antrostomy through the nose is performed to allow rinsing of the sinus with exit of the fluid through the Caldwell-Luc orifice into the mouth.

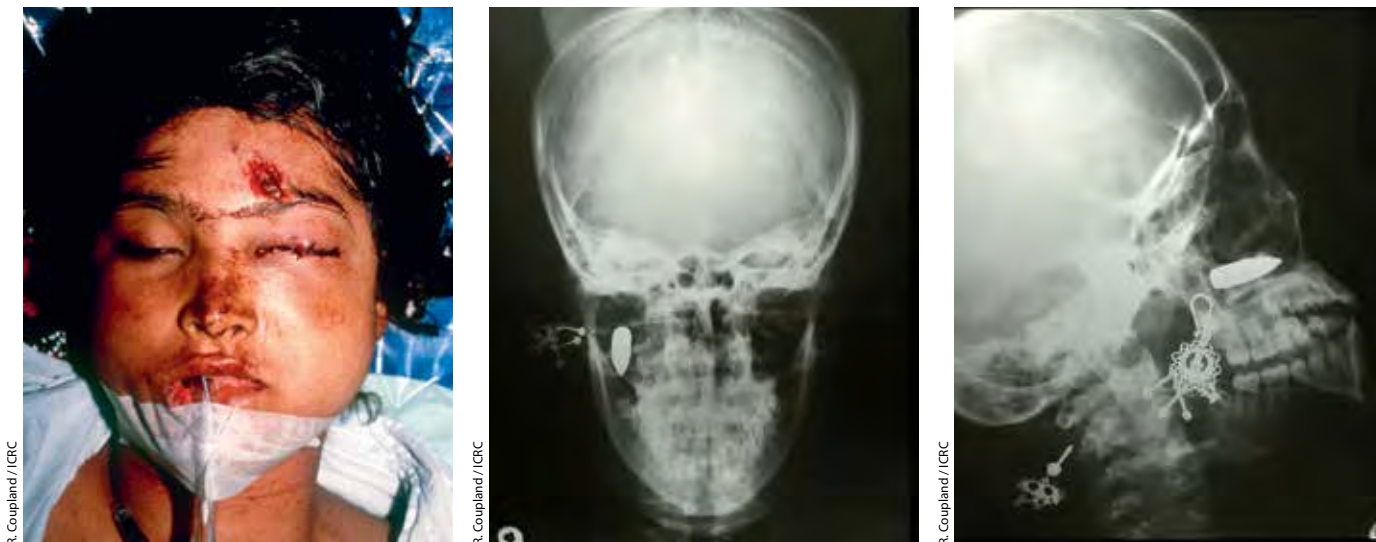


N. Pappas / ICRC



N. Pappas / ICRC

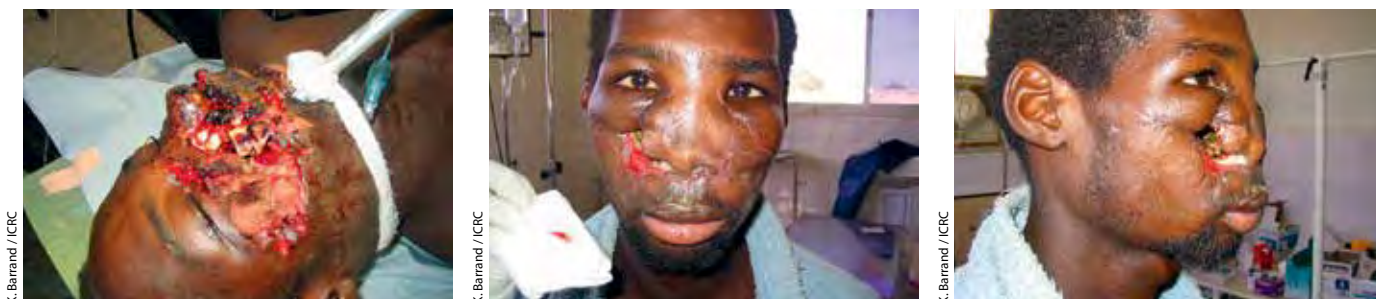<sup>6</sup> Please note: the Caldwell-Luc operation for sinusitis involves the stripping of all the sinus cavities, including the ethmoid cells.



Figures 27.26.1 – 27.26.3

A falling bullet struck this child at the right supraorbital eminence and came to a stop in the maxillary antrum. It was removed through a Caldwell-Luc approach.

Other injuries that leave a wide-open wound or shattered sinus should be packed after debridement, usually a necessary measure to control bleeding. Iodoform-vaseline gauze packs should be changed every 24 – 48 hours and the sinus rinsed out with normal saline, as there is continuing contamination from the secretions of whatever mucosa remains. Soft-tissue closure is performed only once the wound is clean, the extent of reconstruction depending on the degree of tissue loss. Some sort of prosthesis is usually required to fill in the missing bone, a specialist technique.



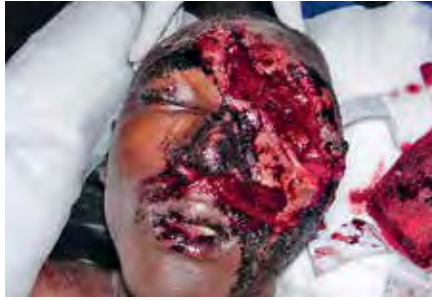Figures 27.27.1 – 27.27.3

GSW causing a shattering of the maxillary sinus. Simple reconstructive surgery performed in austere circumstances allows later referral of the patient for more specialized care.

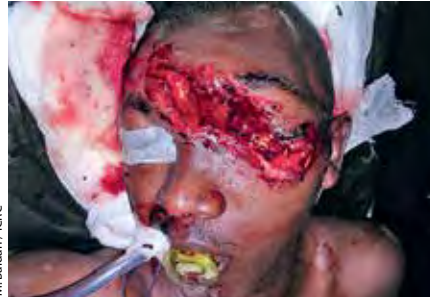### 27.8.2 Fractures involving the orbit

The various components of the bony orbit may be damaged individually or as a whole and should be debrided in the usual manner. Significant injuries usually involve disorganization of the eye globe leading to enucleation (see Section 29.11.2). Note must be made of any extension of the injury into the cranium and brain. Major wounds often involve the superior orbital ridge and frontal sinus; again, any extension into the cranium must be dealt with as a priority (see Section 26.13.2).

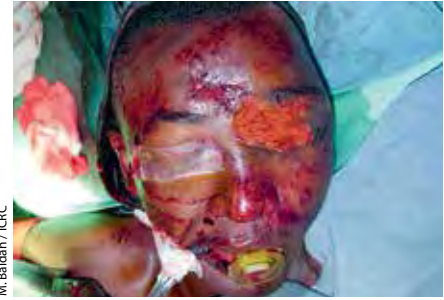Because of anatomic constraints, closure is impossible and the open wound of the orbit should be packed with iodoform-vaseline gauze, changed daily at first and then every other day. Reconstructive surgery must be resorted to at a later date; if not possible or available, the wound is left to granulate and epithelialize spontaneously or with the help of local rotation flaps or skin grafts.



M. Baidan / ICRC



M. Baidan / ICRC



M. Baidan / ICRC

Figures 27.28.1 – 27.28.3

GSW of the orbit and frontal sinus packed with iodoform-vaseline gauze.

Fractures involving the floor of the orbit may cause herniation of the orbit contents into the sinus. This occurrence requires open reduction and a graft in order to support the eyeball and maintain good vision: a complicated and specialist technique. Where specialists are not available, a semi-closed reduction can be achieved by entering the maxillary sinus using the intra-oral Caldwell-Luc approach. The floor of the orbit is kept under direct vision while the fracture is reduced by inserting a Foley catheter and inflating the balloon, the surgeon looking all the while at the level of protrusion of the two eyes from above and behind the patient's head. Alternatively, the sinus can be packed with iodoform-vaseline gauze to form a scaffold. Attention must be paid not to over-reduce the fracture in both cases.

Compression of the eyeball may cause blindness and repetitive testing of vision is mandatory post-operatively. If a gauze scaffolding has been used, it can be left *in situ* for up to two to three weeks, but it must be well lubricated with vaseline and, even so, often requires anaesthesia for removal. Attention must be paid to identify any incipient infection, in which case the packing should be removed and the sinus rinsed out.

## 27.9 Skin closure

Aesthetic considerations are important in the face. The teeth should be occluded and any fractures immobilized before making an attempt to close the skin. This permits a more accurate approximation of the soft tissues.

Immediate primary closure of the skin is acceptable in uncomplicated maxillo-facial injuries: an exception to the rule of delayed primary closure.

Immediate primary closure of the skin, without undue tension, should be attempted. Even in seemingly massive injuries, simple re-approximation is achievable, in layers if possible. Conservative undermining of the skin edges facilitates closure. A small devascularized skin flap with a diminutive pedicle may be excised at the line of demarcation, defatted, and replaced in position as a free whole-thickness skin graft.

Heavily contaminated or already infected wounds, however, are best treated by delayed primary closure. The mucosa is sutured if at all possible but the other soft tissues are left open and any bare mandibular bone is covered with a plug of iodoform-vaseline gauze. Unlike projectile wounds in other parts of the body, maxillo-facial injuries require *daily dressings* when the mucosa is open and there is continuous contamination by saliva. The wound is irrigated with normal saline daily until clean and granulating and ready for delayed primary closure or secondary suture. If the mucosa has been closed, then the usual routine of avoiding a change of dressing until delayed closure is followed.

At delayed or secondary closure, if skin loss is great, a variety of local procedures is available: Z-plasty or V-Y-plasty; local rotation flaps, which match best for colour and

texture; or skin grafting. Often, it is best to perform these operations in a staged fashion. Sometimes sophisticated reconstructive surgery is necessary.

### 27.9.1 Specific sites

The skin-vermilion junction of the *lip* should be realigned accurately. The mucosa, muscle and skin are then closed in separate layers. Penetrating wounds of the *cheek* should also be closed in layers.

Wounds of the *tongue* may bleed a great deal and may require ligation of the lingual artery. Deep lacerations should be repaired with synthetic absorbable sutures. Partial tongue flaps can be used to cover a defect in the mucosa of the floor of the mouth.

The *parotid duct* should be left open because of a high risk of parotitis if ligated. An attempt may be made to repair it over a thin stent, always a difficult procedure; or to re-route the saliva into the oral cavity by means of a Penrose drain stitched to the mucosa. Concomitant closure of the cheek in layers – muscle and skin – is important to avoid the development of an oro-cutaneous salivary fistula. The *submandibular gland* should be excised if injured.

Any repair of the *facial nerve* is a delayed procedure at six weeks and requires specialist care, including a nerve stimulator and an operating microscope.

## 27.10 Post-operative management

Antibiotic cover and anti-tetanus prophylaxis should be administered according to protocol and analgesia given as necessary.

Continued attention must be paid to the airway. In major injuries, particularly those with large soft-tissue wounds and extensive oedema or fracture of the mandible with loss of substance, the patient requires a tracheostomy for a considerable period of time, whatever the method of immobilization, until the upper airway is sufficiently free.

Occlusion of the teeth must be checked regularly. Physiotherapy and movement through the use of chewing gum should be instituted if using external fixation.

Oral hygiene using a toothbrush, saline and antiseptic mouth wash (chlorhexidine 0.2% or simple sodium bicarbonate) several times a day, is of the utmost importance to avoid infection and provide patient comfort, whether fixation is intermaxillary or with an external fixator.

Oral hygiene is essential.

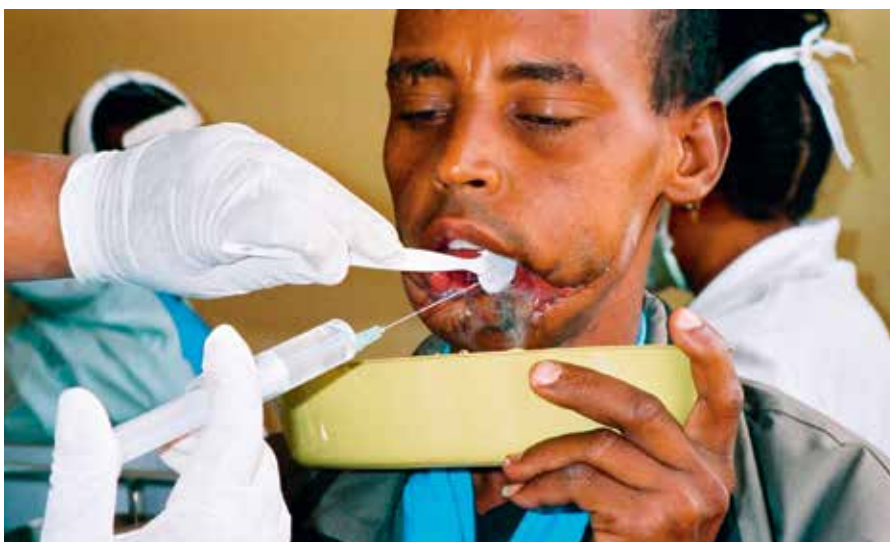

Figure 27.29

Oral hygiene: syringe-assisted mouth rinse.

Open skin wounds with salivary contamination awaiting delayed primary closure also require daily saline cleansing and proper pin care for any external fixation device.

Nutrition *must* be maintained. There are several means available and the choice depends on whether the patient is conscious or not, and on the stage of post-injury with consequent subsidence of oedema and haematoma. The appropriate method should be chosen to suit each individual patient.

The comatose patient should be fed either through a naso-gastric tube, if there is no fracture of the base of the skull, or by means of a feeding gastrostomy or jejunostomy in the case of a prolonged period of compromised consciousness. The procedure is described in Section 26.14 and the diet based on Annex 15.A for burn patients.

Conscious patients with severe oedema can be fed through a naso-gastric tube until such time as its resolution permits an oral liquid diet. Many patients treated with MMF have lost one or more teeth, providing a space to pass a straw to allow the ingestion of a diet of soups and mashed fruit and vegetables. However, even with a complete set of natural teeth patients are able to ingest bouillons and soups several times a day.

The removal of sutures in the face and neck can be performed after 5 days. The fracture can be mobilized after 2 weeks, by replacing the tie wires with rubber bands, and complete removal accomplished within 6 weeks.

## 27.11 Complications

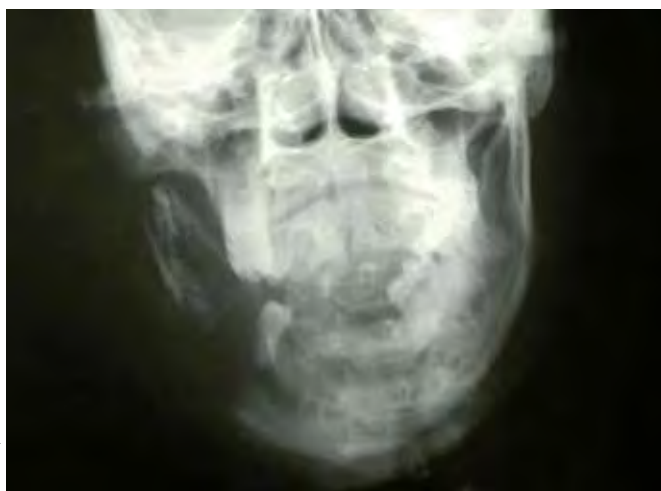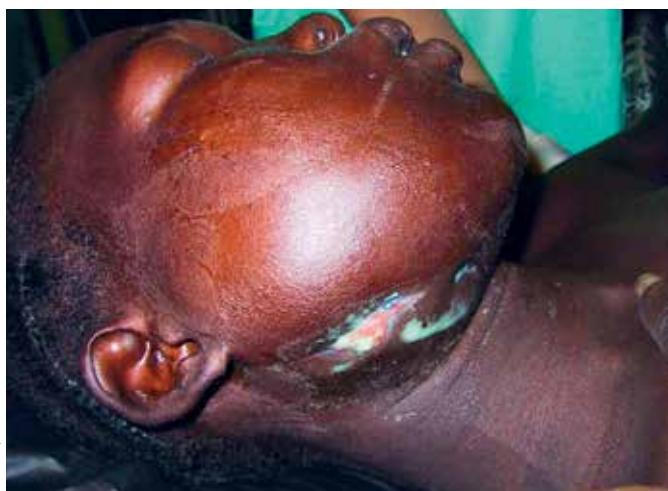Complications may be early or late and concern the soft tissues or bone.

### 27.11.1 Soft tissues

The most common and important early complication is a salivary fistula causing infection, which can provoke secondary haemorrhage. The mucosal repair must then be revised and the skin wound laid open. This is followed by copious irrigation of the soft tissues of the floor of the mouth and neck, removal of any foreign bodies, and close inspection made of remaining fragments of bone that may have become sequestered. The wound is left open and packed with iodoform gauze and revisited daily. Delayed primary closure is performed when the wound is clean, usually after one or two dressings.

Late soft-tissue complications include deformity due to a poor scar or contracture. Reconstructive surgery may require specialist care.

Late fistula formation usually occurs as a result of a deep-seated infection. This may be due to a sequestrum, infected root of a tooth, tissue necrosis, or a foreign body. Fistulectomy, as in orthopaedics, involves excision of the sinus and dissection of the fistula tract up to the source, and its removal. A fistulogram is helpful (see Section 22.9.5).



Figures 27.30.1 and 27.30.2

Infected salivary fistula in a late presenting patient probably due to a necrotic tooth.

### 27.11.2 Osteomyelitis of the mandible

Mandibular osteomyelitis is the most dreadful complication to deal with and occurs relatively often, usually in conjunction with a salivary fistula. The principles of treatment are the same as for post-traumatic osteomyelitis of any bone: removal of sequestra; wide, open drainage; prevention of further contamination; judicious use of antibiotics; and maintenance of the general and nutritional status of the patient.

After opening the wound and removing necrotic bone fragments, closure of the oral mucosa should be attempted but it is often difficult owing to local oedema. Copious irrigation of the site and leaving the wound open are essential. As with a salivary fistula, the wound is packed and dressed daily or twice a day, with saline irrigation until the mucosa can be closed. The wound itself requires delayed primary or secondary closure once clean and granulating.

### 27.11.3 Limitation of mouth opening

Inability to open the mouth widely is a frequent complication. Severe cases may be due to soft-tissue contractures requiring excision and reconstructive surgery, or to problems with the mandible necessitating special operations. The best method of management in such cases will depend on the availability of transfer to specialized care on the one hand, and on the technical competency of the surgeon on the other.

Three major forms are recognized, from simple to more complicated.

#### Trismus

Trismus is a reversible limitation of mouth opening due to a lack of muscle relaxation (temporal and/or pterygo-masseter). It is the consequence of direct trauma, chronic inflammation, and/or infection or simply of a long period of maxillo-mandibular immobilization.<sup>7</sup> Intensive jaw-opening exercises using wooden tongue blades and chewing gum are generally sufficient to allow a return to normal mouth opening.

#### Ankylosis and coronoid process hyperplasia

This limitation of mouth opening results from a progressive fibrotic change and, later, bony transformation of the tendon of the temporalis muscle. A patient with coronoid hyperplasia or fibrous ankylosis is able to open the mouth only about 10 to 15 mm, as measured between upper and lower anterior teeth, and to move the mandible laterally. Removal of the coronoid process (coronoidectomy) is the treatment of choice but not easy to achieve owing to the significant limitation of mouth opening.

#### Ankylosis of the temporo-mandibular joint

Ankylosis of the joint is a fusion of the condylar head with the glenoid fossa of the temporal bone. This osseous bridge is usually the consequence of fractures that involved the condyle and that were immobilized during too long a period of time. The patient is no longer able to open the mouth even 10 to 15 mm. Excision of the mandibular condyle gives poor results, because of the high incidence of relapse with a larger ankylosis. To prevent its development, the best treatment of condylar fractures consists in early self-mobilization with forward protrusion of the mandible.

<sup>7</sup> The word trismus describes a clinical sign of clenching the jaws shut. Its use here following infection should not be confused with the occurrence of trismus during tetanus.





## **Chapter 28**

# **INJURIES TO THE EAR**

28.	INJURIES TO THE EAR	
28.1	Epidemiology and mechanism of wounding	311
28.2	External ear	311
28.3	Middle ear	312
28.3.1	Management of a ruptured tympanum	312
28.4	Inner ear	313

## Basic principles

The most frequent injuries after explosive blast are a functional temporary sensory deafness and a ruptured eardrum, making it difficult to communicate with patients.

A wound of the meatus or a ruptured eardrum needs careful cleaning and systemic antibiotics; the ear should be covered with a sterile dressing.

In principle, no irrigation and no ear drops – fluid propagates contaminants and infection and may interfere with the monitoring of CSF leakage.

Wounds of the external ear must be carefully and conservatively debrided, with minimal removal of skin and cartilage. Skin should be closed or at least approximated to cover the cartilage.

## 28.1 Epidemiology and mechanism of wounding

The ear is divided into three parts: the external, the middle, and the inner ear, all exposed to injury from the various weapons of war. There are four functions related to the ear: hearing, balance, cosmetic appearance and facial expression mediated through the facial nerve. Missiles and explosive blast injury can affect all four functions.

The different parts of the ear may be injured directly by projectiles, but this occurrence is relatively rare. Open wounds of the external ear occur in about 10% of head and neck injuries. Far more common is primary blast injury causing rupture of the tympanum, which is the most frequent lesion in people exposed to an explosion.

Rupture of the tympanum is the most common injury in people exposed to an explosion.

The setting, distance from the explosion and orientation of the head all play important roles in determining the frequency of injury. The incidence after an open-air explosion can be up to 30% and in an enclosed space reach 50%. The closer the person is to the explosion, the greater the blast pressure generated. The greatest damage occurs when the auditory meatus is perpendicular to the blast wave.

At higher pressures and very high decibel levels, there may be neurapraxia of the receptor organs or dislocation of the middle ear ossicles. Degloving of the cartilage of the external ear may also occur.

Bomb blast explosions will deafen many patients, making it difficult to communicate with them.

The victim of an explosive blast often suffers multiple injuries, many life-threatening, and the auditory apparatus has low priority. Consequently, injuries to the ear may go unnoticed at first. It is important to complete the examination once the patient's condition has been stabilized.

## 28.2 External ear

Trauma to the pinna and external auditory canal is usually due to projectiles and should be managed like other soft-tissue injuries; unless treated correctly it may well result in considerable deformity.

A haematoma of the pinna is treated by aspiration or evacuated under strict aseptic conditions and the ear protected with a firm sterile dressing. The dressing is removed at least every 48 hours and the wound inspected for recurrence of the haematoma.

In simple lacerations, the damaged tissues of the auricle are carefully and conservatively excised, with minimal removal of skin and cartilage. Primary closure, in layers, is preferred. Care must be taken to retain good apposition of the cartilage using absorbable suture material. The skin and subcutaneous tissue are closed with fine atraumatic sutures.

If the auricle is partially avulsed, careful excision of the dead tissues and re-approximation must be undertaken as soon as possible. In instances where a portion of the auricle is missing, approximation of the anterior and posterior layers of skin over the exposed cartilage should be accomplished.

Degloving injuries that expose the cartilage carry the risk of chondritis, which may lead to complete necrosis and the loss of the auricle. Any bare cartilage must be buried in a post-auricular pouch of skin for reconstruction at a later date.

Lacerations of the external auditory canal must be repaired precisely. It is most important to keep the meatus *open* afterwards; otherwise stenosis is likely to occur. The lumen is packed with narrow ribbon gauze soaked in an antiseptic agent.

Post-operatively, all wounds are covered with a firm sterile dressing for 48 hours, after which they may be left open. Sutures are removed at 5 – 7 days. Systemic antibiotics are administered for five days.

## 28.3 Middle ear

Injury to the tympanic membrane is caused most frequently by primary blast. It may also be the result of direct penetration by a projectile hitting the base of the skull or extension of a fracture of the base of the skull involving the tympanic ring.

Blast injury produces a spectrum of insults from hyperaemia and intra-tympanic haemorrhage, to one or several perforations, or even complete loss of the eardrum. Perforations may be smooth, punched out, or have ragged inverted or everted edges. One or both ears may be affected.

If the tympanum is ruptured by blast, fragments of keratinizing squamous epithelium may be pushed into the middle ear and mastoid air cells. Some viable epithelial cells may become implanted and grow to create a destructive cholesteatoma. Specialist follow-up is required for a period of two years – if available.

### 28.3.1 Management of a ruptured tympanum

Diminished hearing or outright deafness, tinnitus, otalgia, and bleeding from the ear are the obvious signs. Small perforations, less than 1/3 of the eardrum (about 80% of cases), usually heal spontaneously within a few weeks. Severe injuries and failure to heal will require the services of a specialist surgeon to perform tympanoplasty.

The basis of treatment is conservative. In general, nothing should be introduced into the external auditory meatus; no irrigation, no ear drops. The presence of any fluid assists in propagating contaminants and infection inwards and may cause confusion in the monitoring of CSF leakage.

If proper instruments and skills are available, excessive amounts of contaminated debris and dirt in the auditory canal should be removed by gentle swabbing or suction under direct vision, or removed with an ear hook.

In all cases the ear must be covered with a sterile dressing and the patient nursed with the damaged ear down to allow for drainage of blood, secretions, and contaminants by simple gravity. The ear must be kept dry during bathing by the use of a cotton wool tampon. Any antibiotics are to be given systemically.

Until the ruptured tympanic membrane has healed, every precaution should be taken to avoid ascending naso-pharyngeal infection.

The patient should be warned not to blow the nose and nasal decongestants should be given. If suppuration occurs, it must be vigorously treated with antibiotics.

Similarly, in the presence of a leak of cerebrospinal fluid complicating a ruptured tympanic membrane, systemic antibiotics are given; the instillation of local antibiotics is contraindicated. The intracranial injury takes precedence over the damage to the ear.

## 28.4 Inner ear

Trauma to the inner ear may occur in combination with the above injuries or in isolation injury and may be accompanied by total hearing loss, severe vertigo, high-pitched tinnitus, or facial nerve palsy.

Many victims of blast suffer from a temporary shift of their hearing threshold and tinnitus. The hearing loss usually resolves in a few hours when the patient is placed in a quiet environment. In some patients, it may persist and even become permanent, most commonly in the high tones. Rarely is this accompanied by vertigo and the few cases reported after blast are most probably due to a post-concussion state rather than to damage to the vestibular labyrinth.

The most dramatic dizziness occurs after complete destruction of the vestibular apparatus. The clinical picture is that of vomiting, associated with severe dizziness, even when the patient is still, which increases with the slightest movement of the head. Examination will show horizontal nystagmus. This injury usually occurs after penetrating missile injuries or transverse fractures of the temporal bone. Antihistaminics that sedate the labyrinth such as cyclizine or meclizine are of considerable help and the dizziness tends to disappear gradually.

The facial nerve lies in a narrow bony canal and runs a tortuous course through the temporal bone. Immediate damage to the facial nerve in association with a fracture of the skull is likely to be the result of tearing of the nerve or impaction of bone onto the nerve. Recovery of nerve function requires operation, performed by a specialist surgeon.

### Clinical features of primary blast injury of the ear

- Loss of hearing and tinnitus are frequent, but usually resolve spontaneously.
- Otagia is usually temporary, but may last for several weeks.
- Vertigo is uncommon.
- Bleeding from the external auditory meatus is due to perforation of the tympanum.
- Tympanic membrane perforation usually heals spontaneously.
- Mucopurulent discharge is a sign of secondary infection of the middle ear and requires aggressive systemic antibiotic treatment.



## **Chapter 29**

# **INJURIES TO THE EYE**

29.	INJURIES TO THE EYE	
29.1	Introduction	317
29.2	Wounding mechanisms and ballistics	318
29.3	Epidemiology	319
29.4	First aid and emergency care	320
29.5	Clinical picture and examination	320
29.5.1	Basic principles of ocular examination	322
29.5.2	Complete ocular examination	322
29.6	Primary management	323
29.7	Assessment of injury and decision to operate	323
29.8	Anaesthesia	324
29.9	Minor procedures	325
29.9.1	Conjunctival foreign bodies and lacerations	325
29.9.2	Corneal foreign body and/or corneal abrasion	325
29.9.3	Iris and ciliary body injury: hyphaema	325
29.9.4	Lacerations of the eyebrows and eyelids	326
29.9.5	Orbital blow-out fracture	327
29.10	Intermediate injuries	327
29.10.1	Wounds of the cornea and sclera	327
29.10.2	Uveal tract, vitreous body and lens capsule	328
29.11	Excision of the eye	329
29.11.1	Evisceration of the eye	329
29.11.2	Enucleation of the eyeball	330
29.12	Retrobulbar haemorrhage	331
29.13	Treatment of complications	332
29.13.1	Endophthalmitis	332
29.13.2	Sympathetic ophthalmia	332
29.14	Burns of the eyelids and eye	333
	ANNEX 29. A Complete ocular examination	334



## Basic principles

Retrobulbar haematoma is the only true traumatic ophthalmic emergency.

Look for ocular injuries with any wound close to the eye.

Check visual acuity.

If possible, refer to an ophthalmologist.

At least instil antibiotic drops or ointment, and a cycloplegic when indicated, and cover the eye.

Eyelids should be repaired after minimal excision.

Small repairs to the cornea and sclera can be performed by the general surgeon.

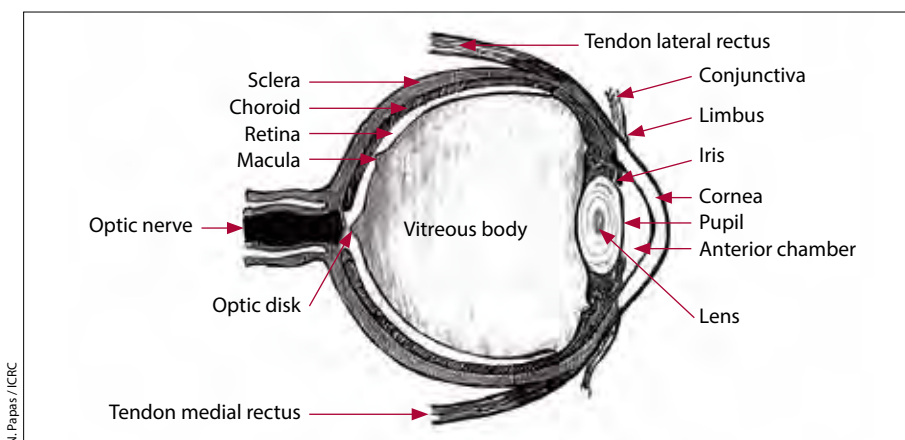
Removal of a destroyed eye is never urgent; it must be discussed with the patient and if possible with the family.

## 29.1 Introduction

The most common wounds of the eye incurred during armed conflict are inflicted by projectiles; primary blast and blunt trauma also occur. Chemical and laser weapons cause distinct pathologies. Although these weapons systems have been prohibited by international treaty, they are still available.<sup>1 2</sup> Fortunately, scenes such as that depicted in Figure 2.6 with long lines of blinded soldiers have not recurred in contemporary armed conflict, with rare exceptions. This Chapter deals only with wounds caused by conventional weapons.

Loss of sight has far-reaching consequences for the patient, the family and society as a whole. Rehabilitation services are all too often lacking in low-income countries and socio-economic reintegration is difficult and fraught with problems.

Penetrating injuries to the eyes constitute one of the greatest technical and emotional challenges for the general surgeon working with limited resources. Referral to an ophthalmologist is always preferable, but unfortunately seldom possible and the surgeon must make do with the means at hand. Most injuries, however, are either minor, or present complete disorganization of the eye globe. The general surgeon can readily deal with the many minor injuries, but is reduced to simple and temporizing procedures for most others, with the exception of excision of the disrupted globe.

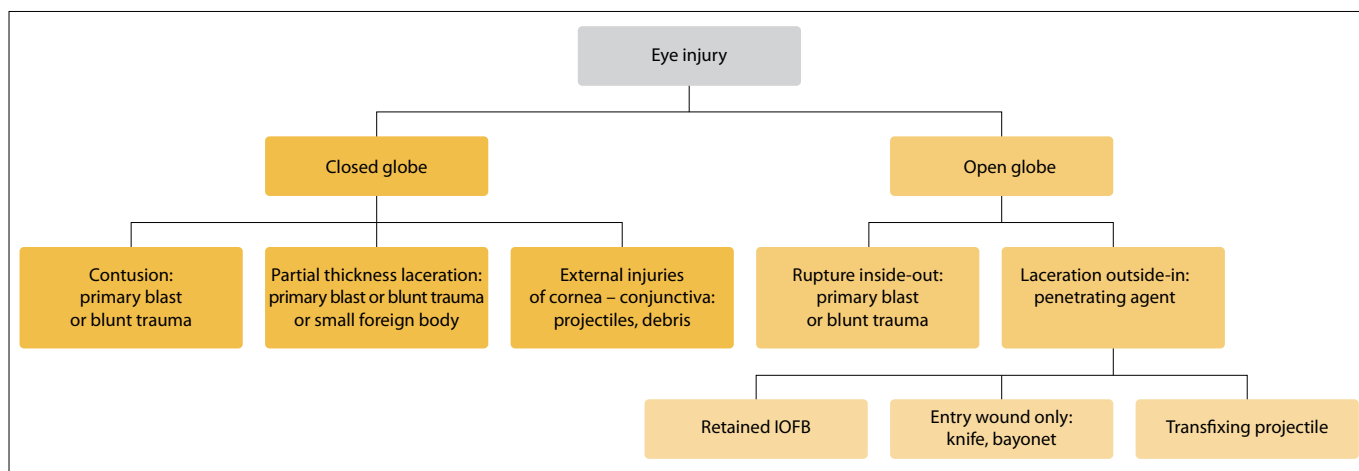


**Figure 29.1**  
Anatomy of the eye: cross section.

- 1 Convention on the Prohibition of the Development, Production, Stockpiling and Use of Chemical Weapons and on their Destruction, 13 January 1993.
- 2 Protocol on Blinding Laser Weapons, 13 October 1995. Protocol IV to the 1980 United Nations Convention on Prohibitions or Restrictions on the Use of Certain Conventional Weapons Which May be Deemed to be Excessively Injurious or to Have Indiscriminate Effects.

## 29.2 Wounding mechanisms and ballistics

The eye is a very delicate organ and susceptible to the slightest ballistic trauma. A simple classification of eye injuries is given in Figure 29.2, adapted from the Birmingham Eye Trauma Terminology System. Injuries are either closed globe, where no full-thickness wound of the sclera or cornea has occurred; or open globe.



**Figure 29.2**  
Classification of eye trauma.<sup>3</sup>

Most ocular injuries in contemporary warfare are open globe and due to small fragments and debris from explosions, particularly shattered glass and grit or small stones. Much of the debris is so small and has so little kinetic energy that it does not penetrate clothing or the skin, but can nonetheless pierce the eye and be retained as an intra-ocular foreign body (IOFB). The presence of an IOFB greatly increases the risk of endophthalmitis.

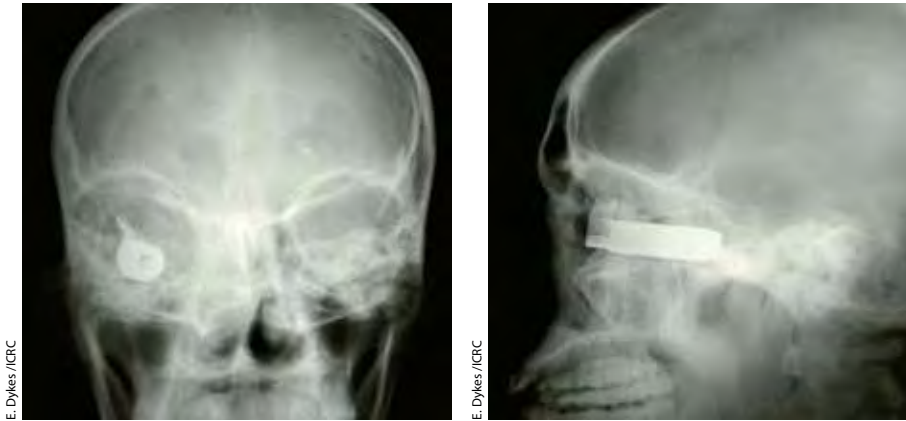If carrying enough kinetic energy, the projectile passes through the eye in a transfixing wound. Penetrating trauma may also involve the ocular adnexae or contents of the orbit – extra-ocular muscles and motor nerves, or the optic nerve – and the penetration can continue into the cranium. The optic nerve may be affected by a direct hit or by the proximity of a passing projectile causing intense vasoconstriction – in which case any resulting loss of function can be merely temporary or permanent. In addition, the impulse of a projectile impact can fracture the bony orbit or cause retinal detachment. Other agents that penetrate the eye may present only an entry site, as sometimes seen with a knife or bayonet stab.

On the other hand, the eye is relatively well protected from primary blast by the bony orbit, the similar density of its component parts and the tough and resistant sclera. The position of the body, offering protection of the torso while the head is exposed, and the direction of gaze are important factors. Closed globe lesions from primary blast effect are multiple and include:

- conjunctival lacerations and subconjunctival haemorrhage;
- hyphaema;
- lens dislocation and traumatic cataract;
- vitreous haemorrhage, retinal haemorrhage and detachment;
- injury to the optic nerve due to intense vasoconstriction of its supplying vessels;
- air emboli from pulmonary blast injury causing loss of vision (see Section 19.10);
- blow-out fracture of the maxillary sinus affecting the floor of the orbit, the eye remains intact.

Both closed and open globe injuries are capable of totally disorganizing the eye.

<sup>3</sup> Kuhn F, Morris R, Witherspoon CD, Heimann K, Jeffers JB, Treister G. A standardized classification of ocular trauma. *Ophthalmology* 1996; **103**: 240 – 243.



Figures 29.3.1 and 29.3.2

Bullet cartridge lodged in the orbit causing complete disorganization of the globe.

Burns affecting the eyelids or cornea may result from ordinary fires or from a blast fireball; the latter may also affect the retina. Protective goggles, or even commercially available sunglasses, provide some protection from burns and small fragments or debris.

Various blast, blunt or penetrating trauma affecting the orbital contents can provoke a retrobulbar haematoma resulting in an *acute orbital compartment syndrome*: the only true traumatic ocular emergency.

Retrobulbar haematoma is the only true traumatic ocular emergency.

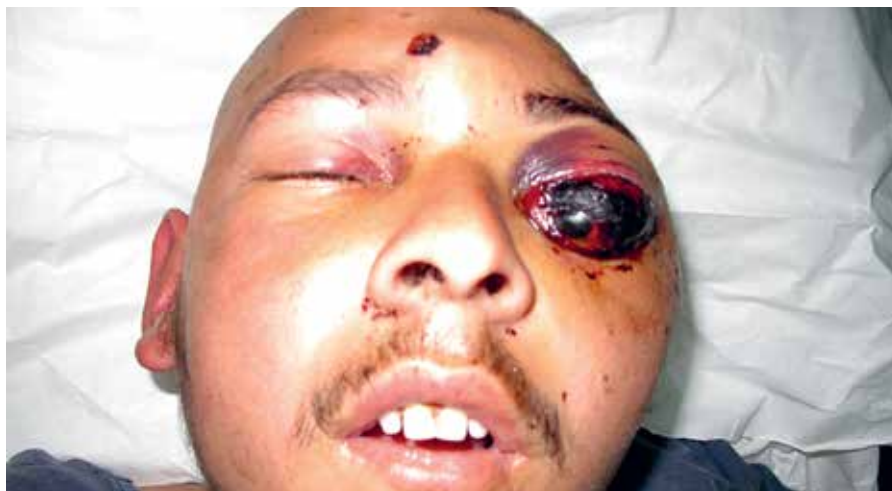

Figure 29.4

Acute retrobulbar haemorrhage with extreme proptosis and subconjunctival haemorrhage resulting from penetration by an artillery shell fragment.

## 29.3 Epidemiology

Like the head in general, injuries to the eye occur disproportionately often. Although it represents only 0.27% of the anterior body surface area and 4% of the face, about 5–10% of all casualties in a modern war zone suffer an injury to the eye; up to 25% in one-off explosions. Most are isolated injuries to the eye and orbit, but 20–40% are associated with penetrating wounds in the brain or other maxillo-facial injuries. In addition, bilateral lesions occur in 15 to 25% of patients. As with other injuries in contemporary warfare, there is a preponderance of fragment wounds from explosive weapons (50%–80%); approximately 20% are due to primary blast trauma. The wearing of body armour and especially eye protection tend to modify the relative frequency of the anatomic distribution of wounds.

Penetrating wounds of the globe constitute 20–50% of all ocular injuries, yet corneal abrasions, superficial foreign bodies, and eyelid and conjunctival lacerations are very common and are well within the reach of the general surgeon.

Table 29.1 shows the distribution of injuries in 5,320 injured eyes in 4,622 patients from the Iran – Iraq war treated in specialized ophthalmology units in Tehran hospitals, and represent a hospital-selected sample. Almost 17% of these patients (863 eyes) had a retained intra-ocular foreign body. Interestingly, 22% of these IOFB were composed of organic materials and probably mostly due to landmine injuries. Pattern 3 mine injuries often involve the eyes (see Section 21.3.3).

Injury		Number of eyes	Percentage
Minor injury	Corneal abrasion, mild conjunctivitis or iritis	651	12.2 %
Major injury	Posterior segment	3,020	59.1 %
	Lens	1,100	21.5 %
	Anterior segment	695	13.6 %
	Orbit	240	4.7 %
	Optic nerve	59	1.2 %
Chemical injury	Mustard gas	350	6.6 %

Table 29.1 Ocular injuries treated in Tehran hospitals during the Iran – Iraq war.<sup>4</sup>

Many of the minor injuries in this study have to do with the environment. Desert conditions are conducive to corneal abrasions and conjunctivitis. In an urban context, lacerations due to glass shards are relatively common.

## 29.4 First aid and emergency care

Although the main reason for examining the pupils is the “D” of the C-ABCDE paradigm to assess any neurological deficit, this also allows a quick examination to ensure the presence and integrity of the eyes and any sight-threatening lesion. A bulging proptotic hard eye globe is indicative of retrobulbar haematoma and constitutes a true surgical emergency.

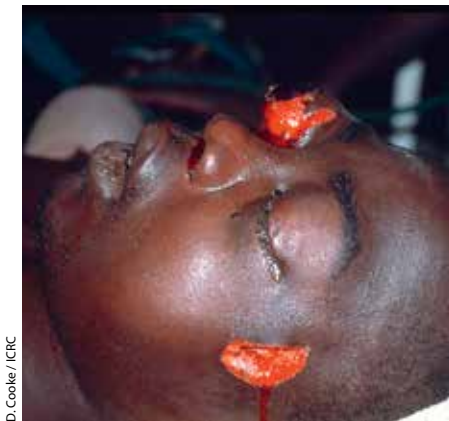A lacerated lid should be gently closed to protect the cornea. A protruding foreign body should be left *in situ*.

If an open globe injury is observed or suspected, the eye should not be irrigated or any drops or ointment instilled, but rather it should be covered with a moist saline dressing and protected with a hard eye patch until a proper examination can be undertaken. Any pressure on an injured eye may compromise the prognosis and rubbing the eyes or squeezing the eyelids tightly shut should be avoided. A makeshift eye shield can be made out of the bottom of a styrofoam cup or cut out of a plastic water bottle and held in place by a bandage.

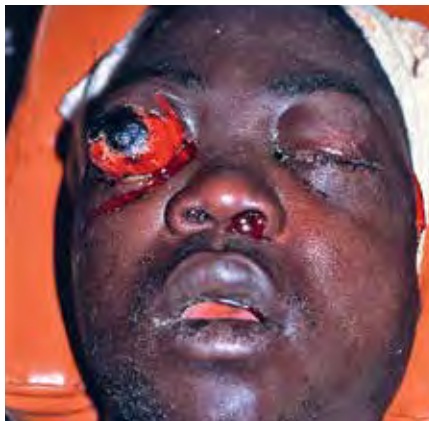## 29.5 Clinical picture and examination

Until proven otherwise, it should be assumed that all injuries around the eye involve an open globe. There is a wide spectrum of clinical presentations. The eyeball may be grossly disrupted or suffer only a minute penetrating wound. Blast injuries in particular may be accompanied by minimal symptoms while concealing major lesions. Common signs and symptoms include irritation and discomfort, or frank pain; sensation of a foreign body; diminished vision or entire loss of vision; orbital haematoma and oedema.

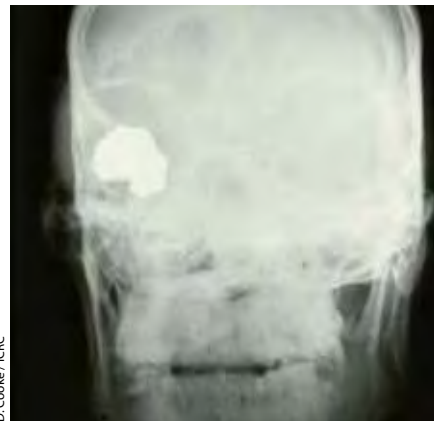4 Adapted from Lashkari K, Lashkari MH, Kim AJ, Crane WG, Jalkh AE. Combat-related eye trauma: a review of 5,320 cases. *Int Ophthalmol Clin* 1995; **35**: 193 – 203.



D. Cooke / ICRC



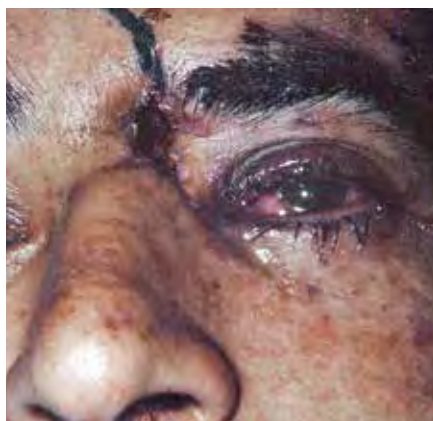D. Cooke / ICRC



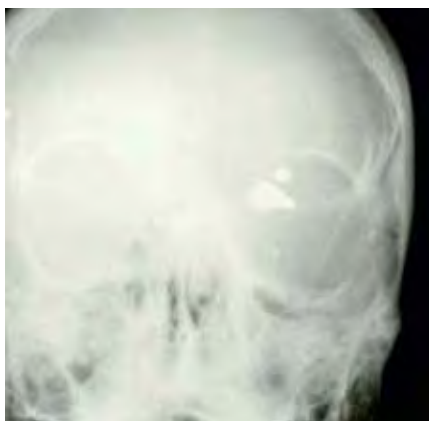D. Cooke / ICRC

Figures 29.5.1 – 29.5.3

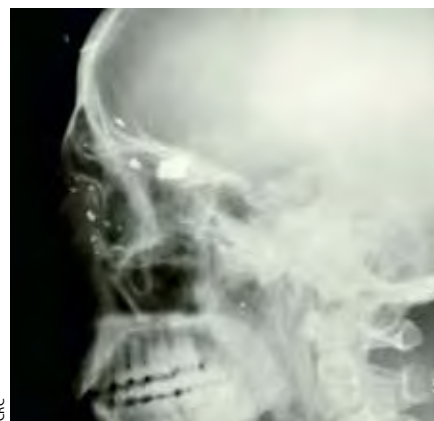Entry of a fragment lateral to the left eye. The globe of the left eye was intact, but transection of the optic nerve resulted in complete loss of vision. The right eye presented extreme proptosis and subconjunctival haemorrhage and was enucleated. The X-ray shows a large fragment retained in the right orbit.



ICRC



ICRC

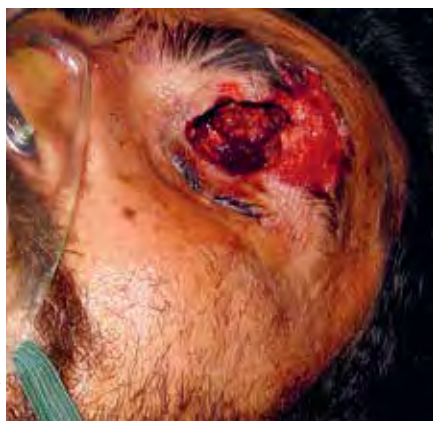

ICRC

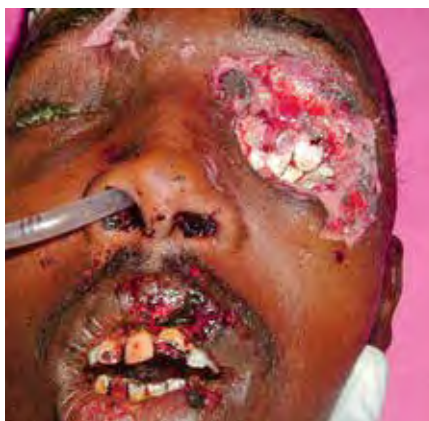Figures 29.6.1 – 29.6.3

High degree of suspicion: any wound around the orbit may involve the eye.

It is unlikely that injuries to the eyes will go unnoticed in the multiply-injured patient although, like wounds of the ear, relatively little attention is paid to them at first, given the presence of other life-threatening priorities. A high degree of suspicion is necessary when examining a penetrating wound of the orbit for any extension to the intracranial contents.



F. Plani / ICRC



M. Baldan / ICRC

Figure 29.7

GSW penetrating the orbit and extending into the frontal sinus and frontal lobe.

Figure 29.8

GSW involving the maxilla and orbit causing traumatic loss of the eye globe and shattering of the orbital bone.

### 29.5.1 Basic principles of ocular examination

An open globe injury should be suspected in every wound around the eye.

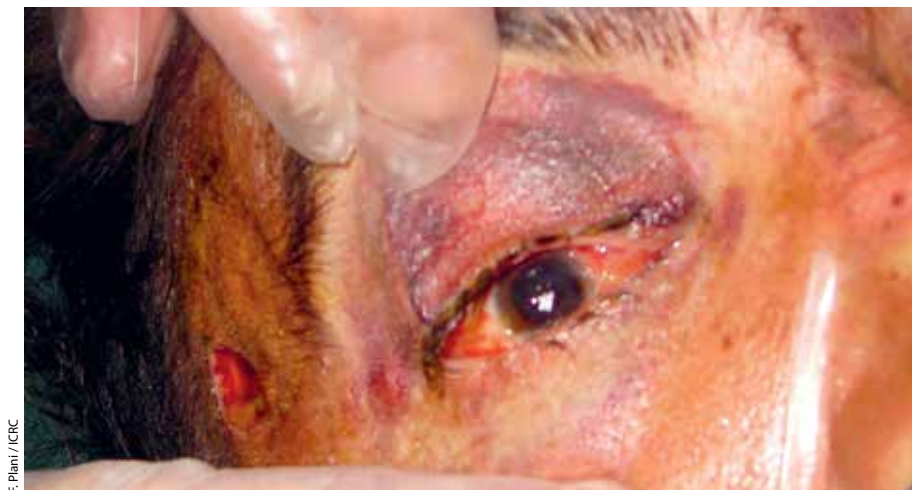The preliminary examination should be performed with the lids retracted. Voluntary opening of the eyelids is difficult in case of injury and topical anaesthesia should be used (oxybuprocaine 0.4% or lidocaine 2%) and general analgesia administered. Gentle separation using a lid retractor is preferable. In its absence, the tips of the fingers should be braced against the bony ring of the orbit before attempting digital separation of the eyelids. If a disrupted globe is suspected, the eyelids should not be everted, but rather retracted apart.

The lids should not be forced open, however, and massive oedema or haematoma should be allowed to resolve before attempting even a preliminary examination.

No pressure should ever be applied to the globe.

**Figure 29.9**

Retraction of the eyelid without exerting any pressure on the globe. Note the ecchymosis of the eyelids and subconjunctival injection. There is a fragment entry wound just lateral to the orbit.



The slightest pressure on a globe which is lacerated or perforated may cause irretrievable loss of the delicate and essential contents. Extreme caution is warranted during examination and emergency treatment.

### 29.5.2 Complete ocular examination

After confirmation of the presence of both eyes and their overall integrity, as well as that of the bony orbit, a thorough ocular examination should follow. A slit-lamp is preferred for proper examination but is rarely available in the absence of an ophthalmologist.

The complete examination includes:

- eyelids and lashes;
- conjunctiva, cornea and sclera;
- reaction of the pupils;
- ocular motility;
- visual acuity of both eyes.

Visual acuity is the single most important parameter.

A plain X-ray will show the condition of the bony orbit and any retained foreign bodies, whether related to the orbit or intracranial. Plastic, however, is usually not radio-opaque. An intra-ocular foreign body must be distinguished from an extra-ocular orbital one. The X-ray is repeated with the patient looking up and then down. An IOFB will be seen

to move, whereas an orbital foreign body remains stationary. Ultrasound, if available, is also good for detecting the presence of foreign bodies, even radio-translucent ones.

The basic principles of a complete ophthalmic examination are described in Annex 29.A. For further details the reader should refer to standard textbooks.

## 29.6 Primary management

Ideally, all eye injuries should be treated primarily by an ophthalmologist, even if this means several days' delay.

Where no specialist is available, the following measures should be undertaken.

Topical anaesthetic having been applied, the conjunctival sac is washed out with copious saline or water and any loose foreign material gently picked out. Embedded foreign bodies are left *in situ* at first.

Measures aimed at prevention of post-traumatic endophthalmitis should be instituted; the incidence after a retained foreign body is estimated to be 10%. These include systemic antibiotics according to protocol; tetanus prophylaxis should also be administered.

Locally, a generous application of either antibiotic eye drops is instilled every four hours or antibiotic ointment applied twice daily, together with 1% atropine sulphate drops every six hours.

A sterile gauze dressing is applied to keep the area clean. A *pressure dressing should be avoided* and the eye protected by an eye shield; this is especially important in children who tend to play with the dressing. The gauze dressing is changed twice daily and sterile irrigation of mucopurulent secretions from the lid margins and conjunctiva carried out. The uninjured eye should be covered with a patch to reduce unwanted eye movements.

Anti-emetics are given and any increase in intra-ocular pressure avoided: coughing, sneezing, retching, constipation, urinary retention, etc. The patient must remain calm; therefore pain control is important.

## 29.7 Assessment of injury and decision to operate

If the patient can be referred to an ophthalmologist, no eye surgery should be performed. The exception is the one true ophthalmic surgical emergency: retrobulbar haemorrhage and acute orbital compartment syndrome calling for immediate sectioning of the lateral canthal ligament (lateral canthotomy and cantholysis: see Section 29.12).

If the patient cannot be referred, the general surgeon should be able to repair simple injuries to the eyelid, cornea and sclera, or excise the totally disrupted globe. Fine instruments and suture material are necessary, however. In addition, the surgeon should be able to deal with the basic management of bony orbital injuries, discussed in Section 27.8.2.

Unless it is obvious that disruption is total, the possibility of salvaging the eye should always be considered. An eye is potentially useful so long as it retains *perception of light* (grade 4 of the visual acuity test: see Annex 29.A). Gross reduction of vision may be due to temporary causes which may clear up and the eye eventually recovers sufficiently to allow some vision. This is a matter of great importance in cases where injury is bilateral. However, poor initial visual acuity, a defect in the relative afferent pupil reaction, and trauma to the posterior portion of the eye all carry a poor prognosis.

It is important that the surgeon differentiate a closed from an open globe injury. Any penetrating eye wound is dangerous as it is liable to cause endophthalmitis or sympathetic ophthalmia. A totally disorganized or blind and painful eye is of no use to the patient and the possible cause of these serious complications. The *exception* to the perception of light rule is the presence of endophthalmitis resistant to antibiotics or sympathetic ophthalmia. Both call for excision of the eye.

The general surgeon should have no trouble dealing with superficial and minor injuries. With serious but intermediate injuries, prudence in clinical decision-making is of the greatest importance. In the absence of complications, the decision concerning an injured eye providing useful vision or not, and therefore the necessity of excision, should only be taken two weeks after injury. Any decision to excise the eye must be a "collaborative effort" and include the treating surgeon, patient, friends and family. Consent and counselling are essential.

Thus, the physical integrity of the ocular globe, the degree of visual acuity, and the presence of any major complications help define several major clinical presentations.

#### Ophthalmic decision-making for the general surgeon

1. Minimal damage with good vision. The prognosis is good and requires little or no immediate surgical intervention. Small IFOB should be treated conservatively.
2. Moderate to severe damage with compromised visual acuity. Two-week waiting period before deciding on excision: the general surgeon should aim for conservative surgery to avoid complications and preserve what vision remains.
3. Severe damage with no visual perception whatsoever or severed optic nerve. Anatomic reconstruction even by a specialist is of little value. The choice is between minimal surgery to avoid infection and excision of the eye.
4. Destroyed eye globe: excision.
5. Endophthalmitis resistant to antibiotics or sympathetic ophthalmia: excision.
6. Acute retrobulbar haemorrhage and orbital compartment syndrome. A surgical emergency calling for lateral canthotomy and cantholysis.

## 29.8 Anaesthesia

Minor procedures and ocular irrigation can be performed using anaesthetic eye drops. Although it is theoretically possible to operate on the eye under local or regional block anaesthesia, with or without i.v. thiopentone sedation, general anaesthesia is preferred for significant procedures, especially in the hands of the non-specialist surgeon. In case of open globe injury, muscle relaxation is mandatory to prevent any retching or spasm that may raise intra-ocular pressure and cause intra-ocular contents to be lost.

Depolarizing agents, such as suxamethonium (succinylcholine), should not be used, however, as they raise intra-ocular pressure and provoke extra-ocular muscle contractions. Induction should be made with a non-depolarizing drug (vercuronium, alcuronium, etc.) and a barbiturate.

Ketamine should not be used alone because it causes nystagmus and eye movements, making the surgery difficult. In the absence of other general anaesthetic agents, ketamine anaesthesia should be combined with a local block to ensure paralysis of the extra-ocular muscles.

Ketamine used alone renders eye surgery difficult.



## 29.9 Minor procedures

Most minor procedures can usually be performed under local anaesthesia. In the distraught and uncooperative patient, general anaesthesia or sedation may be necessary.

### 29.9.1 Conjunctival foreign bodies and lacerations

The conjunctival sac is irrigated by syringe with copious quantities of sterile saline or water, and any loose foreign material picked out with forceps or a cotton-wool bud on a stick. Non-penetrating conjunctival lacerations heal spontaneously. Chloramphenicol eye drops should be instilled into the conjunctival sac 4 times daily for a week. No dressing is required.

### 29.9.2 Corneal foreign body and/or corneal abrasion

As mentioned in Annex 29. A, fluorescein helps visualize a corneal abrasion, but is usually only available with the presence of an ophthalmologist. A good magnifying glass is of great help.

A foreign body lying on the surface of the cornea can be removed with the tip of a large sterile hypodermic needle after instillation of a local anaesthetic, the shaft of the instrument approaching the cornea at a tangent. Any rust in the ulcer crater that is left after this procedure should be scraped out with the tip of the needle in the absence of ophthalmic instruments; otherwise it will leave a corneal abrasion.

A few drops of a cycloplegic, such as 1% homatropine, *and* 1% chloramphenicol drops are instilled three times daily for a week. Non-steroidal anti-inflammatory drops and systemic analgesics may be necessary as well as simple lubricant eye drops.

### 29.9.3 Iris and ciliary body injury: hyphaema

Hyphaema occurs with non-penetrating injuries more commonly than with penetrating wounds. The danger lies in the tendency to have a second bleed on the third to fifth day after injury, which is often worse than the primary haemorrhage, and leads to secondary glaucoma and corneal staining with blood. Patients should be tested for sickle-cell anaemia or other blood dyscrasias where this is relevant. A re-bleed and consequent increase in intra-ocular pressure should be prevented by:

- complete bed rest for a week with the head elevated to 30°, followed by another week of reduced activity;
- cycloplegic drops, such as 1% atropine or homatropine TID, to prevent the pupil moving;
- chloramphenicol eye drops TID;
- steroid eye drops TID;
- a pad on both eyes.

Aspirin and non-steroidal anti-inflammatory medications should not be taken as they promote bleeding. Paracetamol and oral tramadol are acceptable.

Treatment should be continued for two weeks. Generally, the prognosis is good and the condition usually resolves with complete restoration of vision.

Non-resolution of hyphaema requires its surgical removal. A very fine butterfly needle is used to enter the anterior chamber on a tangent and fluid blood washed out by an infusion of normal saline. One or two washouts are usually sufficient. Clotted blood is removed by fine forceps after a small incision in the lateral limbus (sclero-corneal junction), which is sutured afterwards.

Glaucoma is a long-term risk and the patient should be followed up regularly. An increase in intra-ocular pressure requires treatment with oral and topical ocular antihypertensives. Acetazolamide is contraindicated in patients suffering from sickle cell disease.

### 29.9.4 Lacerations of the eyebrows and eyelids

An eyebrow should never be shaved, as it may not regrow. Sutures should be avoided if possible; adhesive skin tape or skin closure strips (Steri-Strips<sup>®</sup>) are usually sufficient.

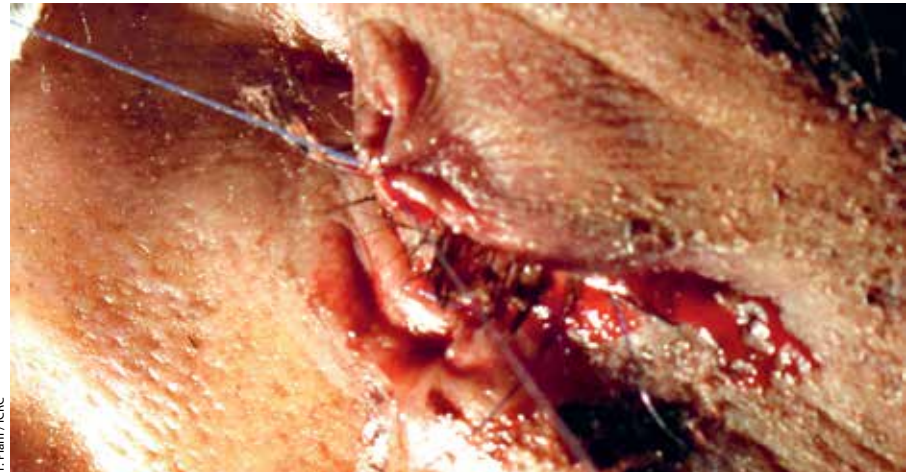A laceration of the eyelid calls for irrigation of the eye first. It is then infiltrated using 1% lidocaine with adrenaline. Minimalist excision of any dead tissue is sufficient if at all necessary; the eyelids are highly vascular and even necrotic-looking tissue can often survive. Very simple and superficial cuts can be left unsutured as they heal spontaneously.

Repair involves the anatomical apposition of the lid margin in two layers.

1. An initial 5/0 or 6/0 suture is placed between the lash line and the mucocutaneous junction of the lid margin (the grey line) to serve as a stay suture.
2. The lid is then everted using the stay suture. Interrupted 6/0 or 5/0 synthetic absorbable sutures are used for the tarsal plate, burying the knots so that they do not scratch the cornea.
3. The lid is then let down and the skin and the mucocutaneous junction closed with interrupted 7/0 or 6/0 non-absorbable sutures, taking small bites. If patient follow-up is uncertain, synthetic absorbable sutures should be used instead.

**Figure 29.10**

Insertion of the initial stay suture between the lash line and the grey line.



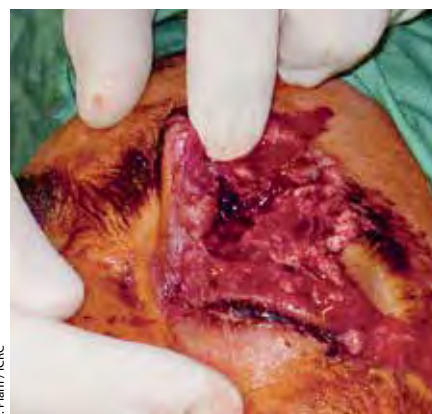F. Plant / ICRC

Cutaneous sutures are removed on day 5 and adhesive skin closure strips can be applied if necessary. Removal of lid margin sutures at day 11 – 14 is preferred if they have not yet been absorbed or if non-absorbable have been used.

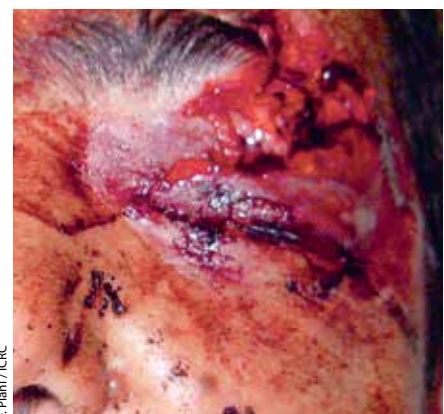If the tissue loss of the eyelid is so extensive as to expose the cornea, temporary cover can be provided by approximating whatever tissue is available. A layer of 1% chloramphenicol ointment should be maintained continuously over any residual exposed cornea. In extreme cases, a conjunctival flap can be mobilized to cover the cornea (Figure 29.14). Further reconstruction may involve extensive undermining of the surrounding skin or a local rotation flap. Injury to the lachrymal apparatus usually requires the services of a specialist ophthalmologist.

**Figures 29.11.1 and 29.11.2**

“Degloving” injury of the eyelid. The grey line is intact.



F. Plant / ICRC



F. Plant / ICRC

### 29.9.5 Orbital blow-out fracture

Primary blast may cause a blow-out fracture of the maxillary sinus affecting the floor of the orbit. The orbital contents may herniate into the sinus. Reduction of the contents followed by tamponade packing of the sinus is required (see Section 27.8.2).

If the eye is not affected, management of an orbital blow-out fracture is conservative: it should simply be kept under observation for two weeks. The patient is instructed not to blow the nose and vasoconstrictor nose drops are instilled four times daily.

## 29.10 Intermediate injuries

Repair should be attempted only if fine instruments and suture material are available. It is preferable that open globe injuries be repaired within 24 hours. A few basic principles of plastic surgery techniques must be observed.

### 29.10.1 Wounds of the cornea and sclera

Corneal wounds should be sutured and the anterior chamber reformed.

#### Corneal wounds

Magnification of any type is of great assistance. It should first be determined if the lesion is full or only partial thickness. A partial thickness wound of the cornea should be repaired if materials are available; otherwise a conservative approach may be taken. A full thickness wound should be repaired with whatever materials are available.

The finest silk, monofilament nylon, or synthetic absorbable suture material available (6/0 – 8/0) and the finest available instruments should be used. The globe is fixed in position by forceps over the sclera in the upper and lower conjunctival fornices; no pressure should be exerted on the eye itself.

Suturing begins in the most central part of the cornea and proceeds towards the periphery. For non-coloured or absorbable suture material, a curved needle is introduced almost perpendicularly into the tissues, about 2 mm from the wound edge, and taken to mid-stromal depth from where it is directed horizontally to the edge of the wound. The needle should then penetrate the opposing edge of the wound at mid-stromal depth and come out of the cornea 2 mm from the wound edge. The interrupted sutures are placed every 2 mm. The suture is then rotated so that the knot is buried in the tissue. Silk or coloured monofilament sutures should take a full bite of the corneal stroma and be removed after ten days.

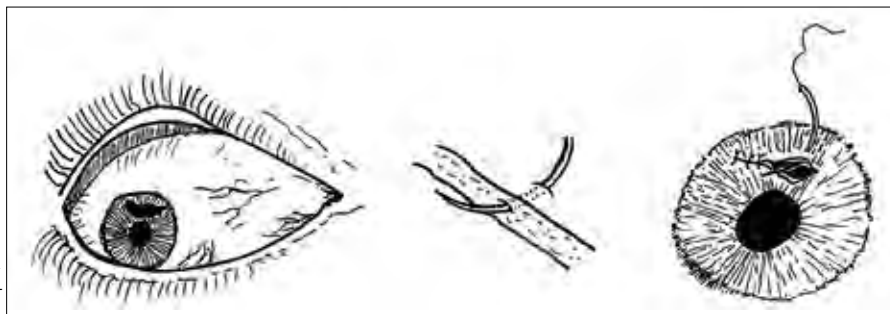


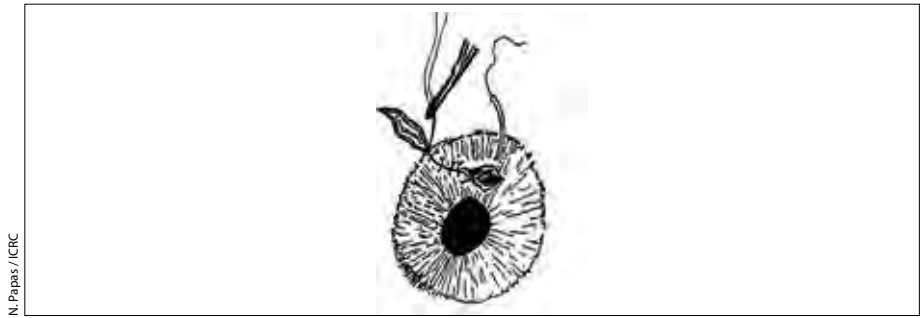
Figure 29.12

Midstromal suture of the cornea using non-coloured or absorbable suture material.

For wounds involving both cornea and sclera, a stay suture is first placed at the limbus after careful alignment of the edges of the wound. The cornea is repaired first and then the sclera.

**Figure 29.13**

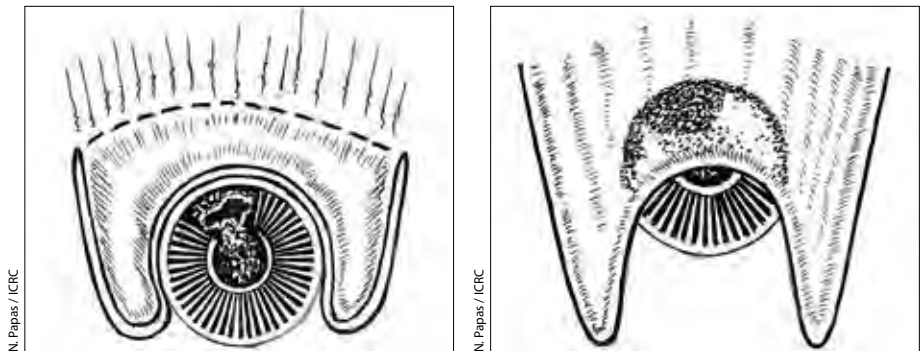
Suture of combined scleral and corneal laceration: a stay suture is placed at the limbus and the corneal wound is sutured first.



Gaping corneal wounds which cannot be closed by direct corneal suture should be covered with a conjunctival flap. The cornea is circumcised close to the limbus and the conjunctiva undermined so that the flap is drawn over the cornea without any tension. The flap is held in place with stay sutures into the conjunctiva.

**Figures 29.14.1 and 29.14.2**

Conjunctival flap to cover a gaping wound of the cornea. The area up to the dotted line denotes the extent of undermining of the conjunctiva.



**Scleral wounds**

As with the cornea, a partial thickness lesion of the sclera may be treated conservatively if materials are not available and is the treatment of choice for very posterior wounds. Full-thickness wounds should be closed in a similar fashion as those of the cornea, using non-coloured sutures. Gaping scleral wounds that cannot be closed should also be protected by a conjunctival flap.

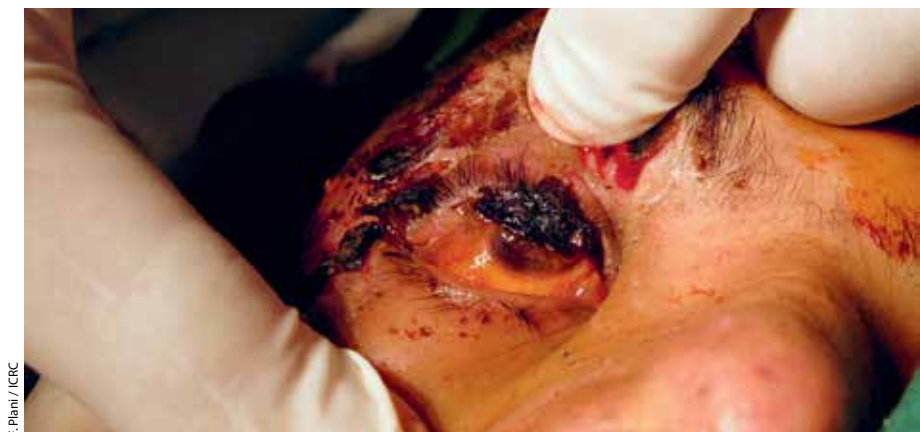Local antibiotic eye drops or ointment should be applied for 1 – 2 weeks.

**29.10.2 Uveal tract, vitreous body and lens capsule**

After reflection of the conjunctiva, any prolapse of the contents of the globe is excised using sharp scissors and the cornea or sclera closed as described above. Intra-ocular tissue must never be left incarcerated in a wound. Systemic and local antibiotic cover is essential.

**Figure 29.15**

Extrusion of the iris through a corneal wound.



With all penetrating wounds, the possibility of a retained foreign body should be kept in mind. If the presence of an IOFB is confirmed, local steroid eye drops should be administered. The removal of small intra-ocular foreign bodies should, however, be left to the properly trained and equipped ophthalmologist. The same is true of major injuries requiring cataract extraction, vitrectomy and anatomic reconstruction of the eye.

Small extra-ocular but intra-orbital foreign bodies should be left in situ unless easily accessible.

## 29.11 Excision of the eye

Excision of the eye is indicated for:

- complete disorganization of the globe,
- painful, blind eye,
- endophthalmitis resistant to therapy, or
- sympathetic ophthalmia.

If excision of the eye is indicated, complete evisceration of the contents is preferred to enucleation, in order to prevent ascending meningitis. As with all mutilating surgery, proper consent and advice to the patient are essential. The correct fitting of an artificial eye is a specialist technique, but local, less professional, alternatives are sometimes to be found.

### ICRC EXPERIENCE

ICRC surgeons visited and made an assessment of a missionary hospital in Kalongo, northern Uganda, where a dentist had a collection of ceramic eye prostheses of various sizes. These were tried out on the patients to see if any fitted correctly.

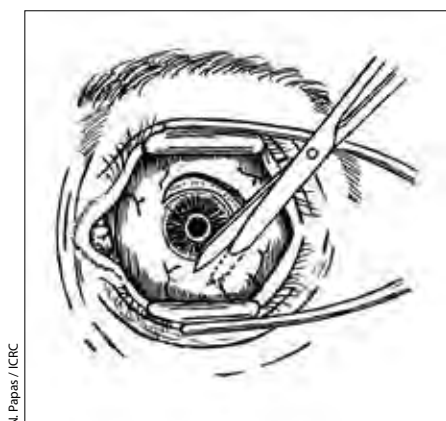
### 29.11.1 Evisceration of the eye

The posterior half of the globe should be retained, with the attachments of the extrinsic eye muscles intact. This is the best technique for fitting a prosthesis at a later date.

1. The eyelids are kept retracted by an ophthalmic speculum or fine retractors.
2. An incision is made in the sclera fairly close to its junction with the cornea and is carried through its full thickness and around the whole circumference, thus removing the cornea.
3. All the contents of the eye are removed and the interior scraped with a curette.
4. The entire uveal tract should be removed; the interior must appear white.
5. The cavity of the globe is packed with a swab soaked in hot saline or dilute adrenaline and pressure applied for haemostasis.

### 29.11.2 Enucleation of the eyeball

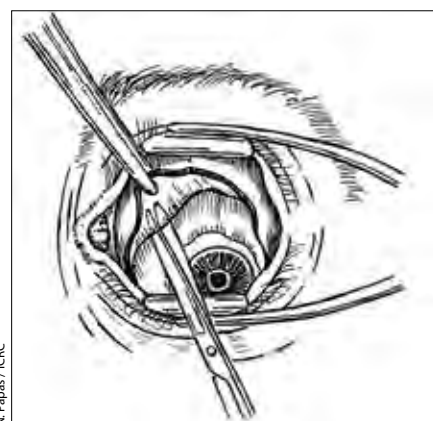
In some cases, the destruction of the globe is so great that its entire removal is inevitable. Enucleation provides less risk of ascending infection.



N. Pappas / ICRC

**Figure 29.16.1**

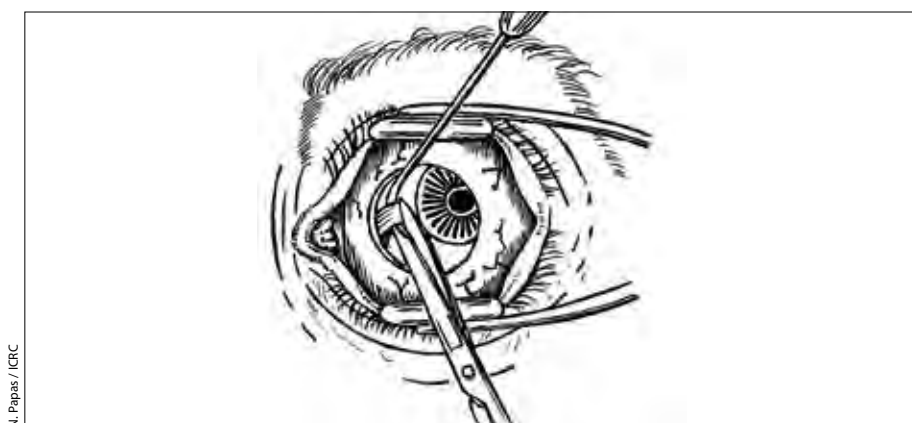
After retraction of the eyelids, whatever remains of the conjunctiva is picked up and incised as close as possible to the remaining cornea.



N. Pappas / ICRC

**Figure 29.16.2**

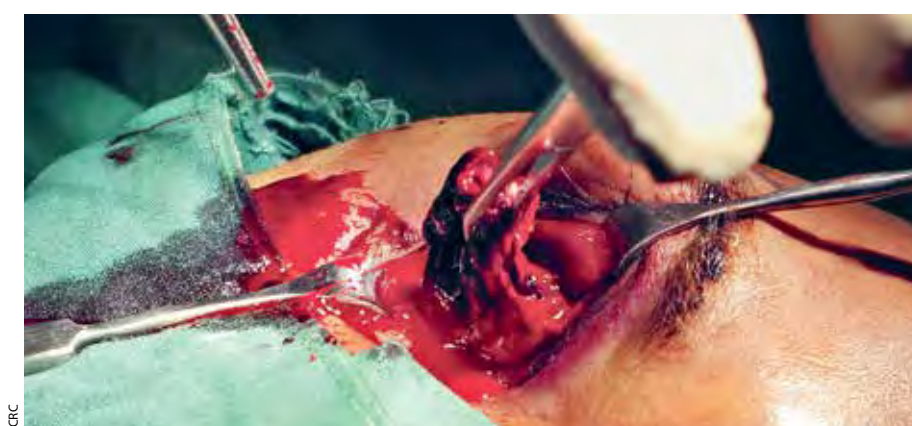The space adjacent to the globe (Tenon's capsule) is entered by blunt dissection with curved scissors.



N. Pappas / ICRC

**Figure 29.16.3**

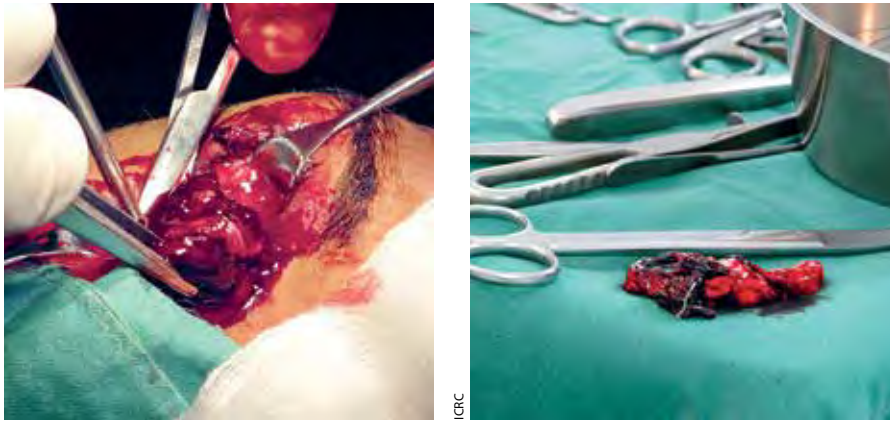
The eye muscles are successively clamped and cut as close to the sclera as possible. The severed muscle is ligated or a stitch passed through and the end left long.



ICRC

**Figure 29.16.4**

The remains of the globe, freed from the muscle attachments, are then grasped with Kocher forceps and pulled upward until the optic nerve is isolated.



Figures 29.16.5 and 29.16.6

The nerve is cut and the globe removed, any strands of connecting tissue are severed.

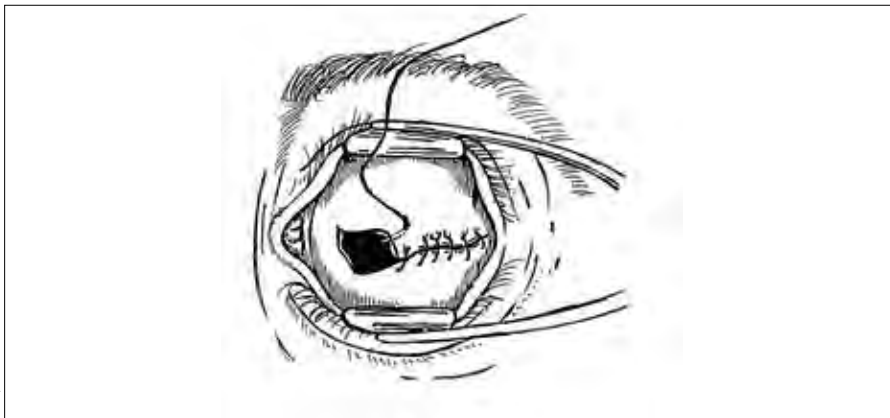


Figure 29.16.7

A compress with hot saline or dilute adrenaline solution is inserted into the empty socket and pressure applied for a few minutes for haemostasis.

The loose ligatures of the muscles are tied together to fill the residual cavity and the conjunctiva sutured closed.

A firm dressing is applied for 2 days.

## 29.12 Retrobulbar haemorrhage

As mentioned, retrobulbar haemorrhage with the advent of an acute orbital compartment syndrome constitutes a true surgical emergency and treatment must be instituted within two hours if the eye is to be saved. Severe burns on the face may also result in an orbital compartment syndrome.

The eye presents with severe pain, tense proptosis that is hard to the touch, loss of pupillary reactions to light, ocular paralysis and rapidly progressing loss of vision.

Decompression of the orbit by a lateral canthotomy with sectioning of the lateral canthal ligament is a relatively simple procedure that can be performed quickly and easily repaired later.

1. Local anaesthesia with adrenaline is infiltrated into the conjunctiva of the lateral canthus, the lateral canthal ligament and for two centimetres into the skin.
2. The lids are stretched and held open by an assistant, a self-retaining retractor, or by the thumb and index of the surgeon's non-dominant hand.
3. Using a pair of very fine and sharp scissors (or a 15 scalpel blade) a cut is made in the canthal junction of the upper and lower eyelids and extended laterally for one centimetre in the skin. The cut involves the full thickness of the conjunctiva and the skin.

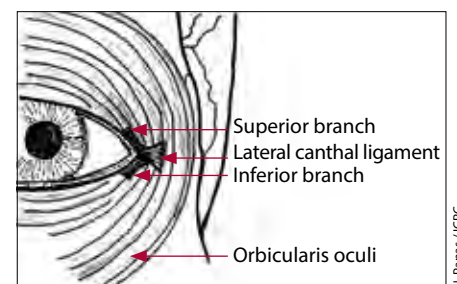


Figure 29.17.1

Anatomy of the lateral canthus.

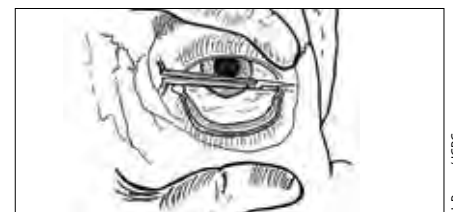


Figure 29.17.2

Incision of the lateral canthus: the eyelids are retracted back and the skin cut for one centimetre.

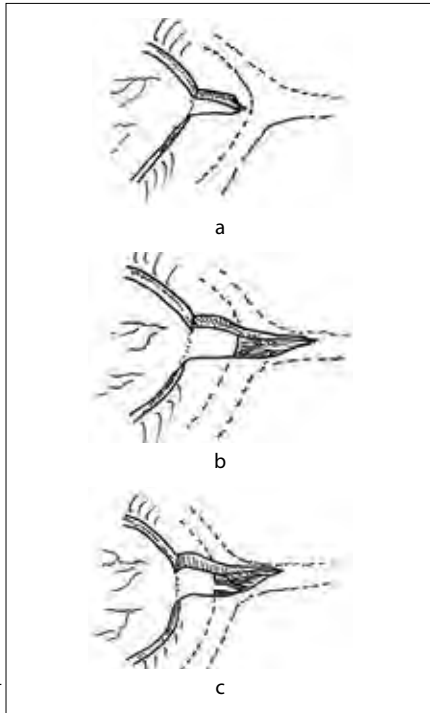


Figure 29.17.3

The skin is cut through to expose the inferior branch of the lateral canthal ligament, which is then sectioned.

4. Blunt dissection with curved scissors or a haemostat isolates the lateral canthal ligament at its attachment to the orbital rim, which is either stripped from the periosteum or the inferior branch of the ligament sectioned. The release of tension is immediate and is the equivalent of a limb fasciotomy.
5. Later, a simple suture of the ligament is sufficient for its repair.

The operation should be accompanied by i.v. acetazolamide (500 mg over 30 minutes followed by 250 mg every four hours for a total of one gram) and mannitol to lower the intra-ocular pressure. Oral acetazolamide can be used if the intravenous preparation is not available.

### 29.13 Treatment of complications

One entirely preventable complication is *exposure keratitis*. Injuries and burns of the eyelids or injury affecting the orbicularis oculis muscle can directly expose the cornea, which should be protected by eye ointment or a conjunctival flap. Far more common occurrences, however, are seen in comatose patients with no ocular involvement whatsoever or an alert patient with a facial nerve injury. Proper eye hygiene of the comatose patient involves daily swabbing with a moist compress to remove any secretions, eye ointment and taping shut the eyelids with adhesive skin tape or Steri-Strips®.

Conditions such as traumatic cataract, small intra-ocular foreign bodies, detached retina, fibroblastic proliferation, and secondary glaucoma, can only be effectively managed by an ophthalmic surgeon. For these cases, referral, if possible, should be made as soon as possible after emergency care.

Other serious complications such as endophthalmitis and sympathetic ophthalmia cannot await delayed referral and treatment should begin immediately.

#### 29.13.1 Endophthalmitis

Intra-ocular infection, either bacterial or fungal, is always a risk with penetrating wounds especially after landmine injuries with organic intra-ocular foreign bodies. Endophthalmitis constitutes a medical emergency.

Headache and local pain are usually prominent, photophobia and visual loss acute, and the patient may have a fever. The eye is "fiery" red, the conjunctiva and lids greatly swollen and purulent discharge abundant. Examination of the anterior chamber frequently reveals pus in the chamber (hypopyon).

Treatment includes closure of the entry wound after the local instillation of a wide-spectrum antibiotic (cephalosporin or gentamycin) as well as intravenous and local eye antibiotics. Cycloplegic eye drops help provide good analgesia. Bed rest and keeping the eyes covered are mandatory. If a fungus is suspected, intra-ocular injection of amphotericin B (10 µg in 0.1 ml) and systemic fluconazole (6 – 12 mg/kg per day, maximum dose 400 mg) should be administered. Prognosis is poor in all cases, however, and the condition often requires excision of the eye.

#### 29.13.2 Sympathetic ophthalmia

Although the condition has been known since the time of Hippocrates, and much feared, it is a rare occurrence and its incidence has probably been exaggerated. In modern wars its estimated incidence is lower than 0.2% of all ocular injuries.

This auto-immune granulomatous uveitis begins in the injured "exciting" eye and goes on to involve the uninjured "sympathizing" eye later on. The pathological changes are the same in both eyes and the condition leads to loss of vision in *both* eyes.

Prolapse of the uvea exposes retinal proteins to the immune system, provoking an autoimmune response; it is unknown in closed globe injuries. Furthermore, a suppurating eye rarely gives rise to sympathetic ophthalmia. The condition begins after a latent period, which can be as short as five days and as long as 60 years;



65% of cases occur within two weeks to two months after injury, 90% present within the first year. Excision of the damaged eye is the only known prevention, but the patient remains at risk for the rest of his or her life.

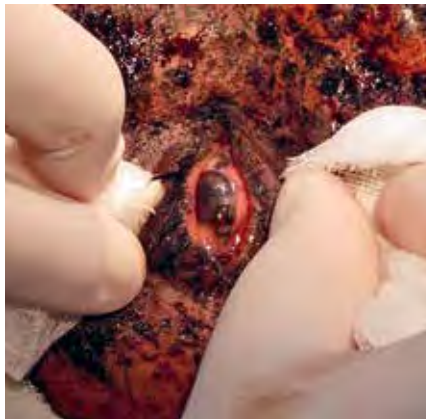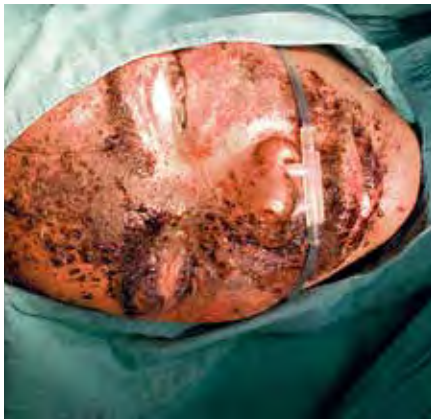The condition begins with photophobia and blurring of vision. The injured eye becomes red and painful and there is loss of vision, but no signs of acute pyogenic inflammation as with endophthalmitis.

Treatment with local steroid eye drops and high-dose systemic steroids is attempted for one week. Methylprednisolone is given intravenously, 30 mg/kg over 30 minutes, followed by 15 mg/kg every six hours for two days. With improvement, the dosage is reduced to an oral intake of 80 mg, 60 mg, 40mg and finally 20 mg every six hours, each dose for three days. Alternatively, an entirely oral regime may be followed: 100 – 200 mg of prednisone per day for the first week, the dose reduced by 5 mg per week to a maintenance regime of 5 – 10 mg per day, and continued for a total of 6 months. Corticosteroids are effective in controlling the disease but cannot prevent it.

A lack of improvement, or the commencement of involvement of the other eye, or inability to withstand the high-dose steroids, demands the removal of the injured eye no matter what the level of visual acuity in order to save the sympathizing eye. Enucleation rather than evisceration is the procedure of choice.

## 29.14 Burns of the eyelids and eye

Burns in the region of the eye *should not be treated with drying agents*, as this invariably results in extensive ectropion from scar contraction leading to exposure keratitis, frequently followed by blindness or loss of the eye.



Figures 29.18.1 and 29.18.2

Pattern 3 blast mine injury: second degree burns and small superficial fragment wounds to the face, eyelids and cornea. The patient also suffered injuries to the hands, arm and leg.

The burnt area of the lid should be thoroughly cleaned with saline, any blister opened and an antibiotic cream applied over the raw area. This should be covered by vaseline gauze dressing and a pad under a firm bandage. The pad should always be changed before it becomes soaked with exudate to avoid bacterial contamination.

For open exposure treatment of burns around the eyes, the area is irrigated with saline and chloramphenicol eye ointment applied every four hours, and 1% homatropine drops instilled twice daily.

Whole thickness skin burns of the eyelid should be excised and grafted at the earliest possible moment (see Section 15.7.2). This gives the best chance of healing and reduces subsequent scarring to a minimum. If this is not done at an early stage, skin grafts should be applied to the raw surfaces of the lids as soon as granulation tissue appears. If the grafts fail, they should be repeated.

The cornea must be kept covered. Initially, this is accomplished by the swollen eyelid. Later, and if necessary, a conjunctival flap is mobilized until the eyelid is completely healed. The same is true for a burn extending to the cornea itself. Tarsorrhaphy is not recommended; the sutures usually cut through creating greater damage.

## ANNEX 29. A Complete ocular examination

A full and proper examination of the eyes should be performed using a slit-lamp, which is rarely available in the absence of an ophthalmologist. Nonetheless, a systematic approach using the means at hand is quite adequate when working with limited resources. A pen torch, ophthalmoscope and simple eye chart are sufficient. The reader should refer to standard textbooks for more detail.

Figures 29.A.1 – 29.A.3

Relative afferent pupillary reaction.

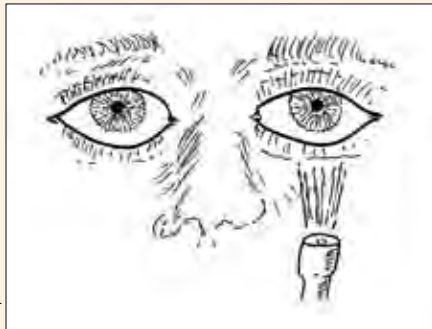

Figure 29.A.1

Normal eyes: bilateral myosis. Shining a light in one eye results in its constriction = direct response. The other pupil also exhibits myosis = consensual response.

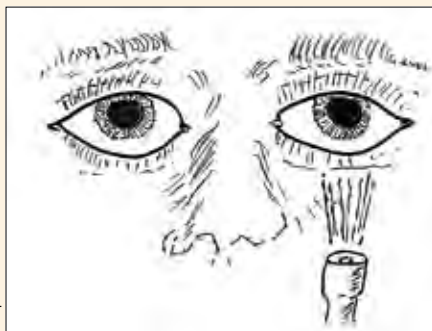


Figure 29.A.2

If the left optic nerve is damaged, neither pupil constricts when the left eye is stimulated (neither direct nor consensual response). When a light is shone in the right eye, both pupils constrict.

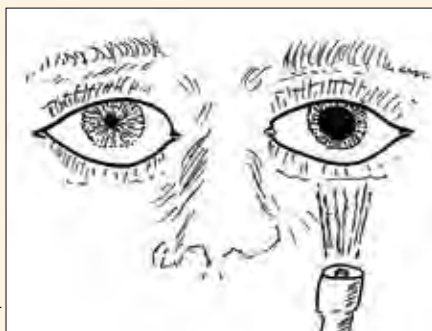


Figure 29.A.3

If the left oculomotor nerve is damaged, the direct response of myosis is lost but not the consensual: the right pupil constricts. When a light is shone in the right eye, only the direct response of constriction is maintained.

### 1. Inspection of the eyelids and lashes

A flattened upper eyelid may indicate a disrupted globe. If a disrupted globe is suspected, the eyelids should not be everted, but rather retracted apart.

Even a small laceration of the eyelid may hide serious damage underneath and be the entry point of a projectile that has penetrated the globe and even the brain. A high degree of suspicion is necessary.

The depth of any laceration should be noted, whether superficial or full-thickness. In addition, any loss of tissue increases the risk of exposure of the cornea. Involvement of the lachrymal system requires specialist care.

### 2. Inspection of the conjunctiva, cornea, and sclera with a torch

Gross contamination of the conjunctiva by dirt and debris is frequent. Once a disrupted globe is excluded, the upper eyelid should be everted and a few drops of local anaesthetic instilled (0.4% oxybuprocaine or, if not available, 2% lidocaine). Foreign bodies on the tarsal surface can be removed by irrigation or by picking them out with a fine forceps or a cotton-wool bud on a stick.

Any abrasion of the cornea should be sought out. Fluorescein assists in its visualization, but is usually only available where there is an ophthalmologist. Corneal lacerations usually present with a shallow anterior chamber and an irregular pupil with extruding pigmented material: the prolapsed iris.

Penetrating wounds of the sclera cover a spectrum of injuries from minute lacerations that are very subtle and difficult to distinguish, to disruption of the globe. Small perforating scleral wounds and even quite large lacerations may be obscured by a subconjunctival haematoma. Signs of penetration include the presence of a clear jelly-like substance, conjunctival haemorrhage, and darkly pigmented extruded choroid. Even more extensive prolapse of intra-ocular contents, such as vitreous humour, uvea, the lens, or retina, may protrude from any laceration.

A retained foreign body may be large and obvious or small and impossible to detect with the naked eye.

### 3. Pupillary reactivity

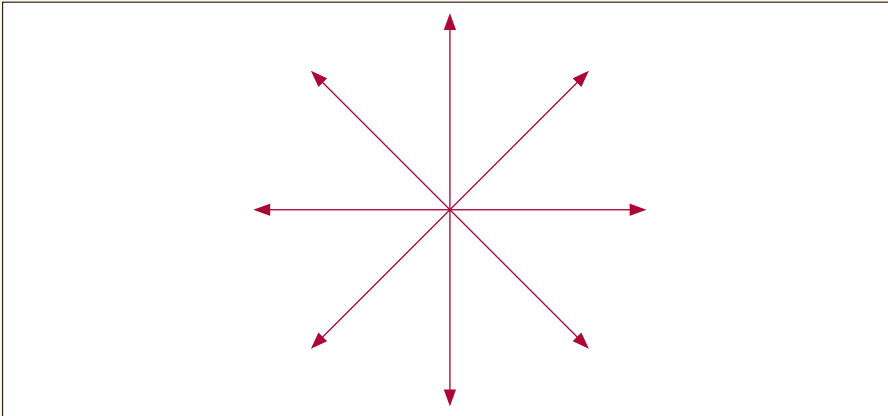
The size, shape, symmetry and reaction of the pupils to light should be noted, as well as any opacity of the lens. Pupillary irregularity and blood within the anterior chamber (hyphaema), or even collapse of the anterior chamber, denote anterior segment trauma with loss of aqueous humour causing the iris to come into contact with the posterior surface of the cornea. There may be prolapse of the iris through a wound.

The *pupillary red reflex* is tested by direct ophthalmoscopy at a distance of 50 cm. Its absence indicates a cataract, vitreous haemorrhage, or retinal detachment.

Swinging a strong flashlight rapidly from one eye to the other tests the integrity of the afferent visual pathway: the *relative afferent pupillary reaction*. With normal sight, both pupils constrict when the light is shone in either eye. If one eye has a lesion to the retina or optic nerve, the affected pupil dilates when the light is swung from the normal to the damaged eye. This is a sensitive test and does not require a conscious patient, unlike simple visual acuity described below. The test also distinguishes injury to the optic nerve from injury to the oculomotor nerve.

#### 4. Ocular motility

The full range of eye movements tests the integrity of cranial nerves III (oculomotor), IV (trochlear) and VI (abducent) and can only be elicited in a conscious and cooperative patient. All nine positions of gaze are tested.



**Figure 29.A.4**

The nine positions of gaze, including straight ahead.

#### 5. Visual acuity of both eyes

This is the most important parameter in diagnosing the seriousness of an eye injury, but requires a conscious and cooperative patient. It should be recorded in five grades:

1. reads print;
2. counts fingers;
3. perceives hand movements;
4. perceives light;
5. does not perceive light.

In evaluating perception of light, it is important to pass a very bright light in front of the eye whilst completely shielding the other eye from the light and possible heat from the torch.



## **Chapter 30**

# **INJURIES TO THE NECK**

30.	INJURIES TO THE NECK	
30.1	Introduction	339
30.2	Surgical anatomy	339
30.3	Wound ballistics	341
30.4	Epidemiology	341
30.4.1	Red Cross Wound Score	342
30.5	Clinical presentations and emergency room care	343
30.5.1	C-ABCDE: Catastrophic haemorrhage	343
30.5.2	Airway	344
30.5.3	Breathing and Circulation	345
30.5.4	Disability	345
30.5.5	Oesophagus and visceral wounds	345
30.5.6	Investigations	346
30.6	Decision to operate	347
30.7	Patient preparation	347
30.8	Surgical management of vascular injuries	348
30.8.1	Basic principles	348
30.8.2	Zone I access and injuries	349
30.8.3	Zone II access and injuries	350
30.8.4	Zone III access and injuries	351
30.8.5	Posterior triangle: vertebral artery	352
30.9	Surgical management of laryngo-tracheal injuries	352
30.9.1	Surgical access	352
30.9.2	Laryngeal wounds	352
30.9.3	Tracheal wounds	353
30.9.4	Blunt injuries	353
30.9.5	Other viscera and soft tissues, etc.	353
30.10	Surgical management of pharyngo-oesophageal injuries	354
30.10.1	Access and operative diagnosis	354
30.10.2	Repair	354
30.11	Post-operative care	355
30.12	Tracheostomy	356
30.12.1	Tracheostomy care	357

## Basic principles

Good knowledge of anatomy is fundamental.

Airway control is essential and may require a tracheostomy.

Shock may be neurogenic in origin.

Most wounds penetrating the platysma require surgical exploration even in asymptomatic patients.

Major vascular injuries must be repaired immediately.

Wounds of the oesophagus are often asymptomatic: complications of a missed injury are the major cause of late mortality in neck injuries.

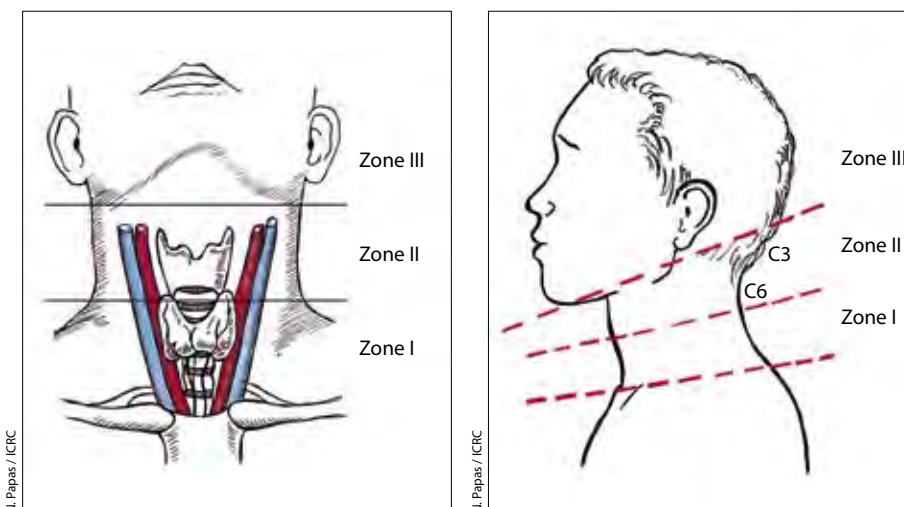
## 30.1 Introduction

The most common causes of death from projectile wounds in the neck are asphyxia and exsanguination. Direct blunt trauma to the neck, such as being struck with the cross or butt of a rifle, also occurs during combat. Late causes include sepsis, most commonly following an oesophageal fistula.

The cervical spine requires special care during examination and treatment if the patient has suffered the more common forms of blunt trauma and deceleration injury following falls or motor vehicle crashes. This is not the case with projectile wounds (see Sections 7.7.2 and 36.5). It should, however, always be kept in mind for victims of blast trauma following explosions.

## 30.2 Surgical anatomy

In classical anatomy textbooks, the neck is usually described as comprising anterior and posterior triangles with their various subdivisions. Although useful, this classification is not totally relevant to penetrating injuries and a division into Zones, specifically pertinent to vascular injuries, is preferable. Zone I extends from the sternal notch and clavicle to the cricoid cartilage; Zone II from the cricoid cartilage to the angle of the mandible; and Zone III from the angle of the mandible to the base of the skull.<sup>1</sup>



Figures 30.1.1 and 30.1.2

Zones of the neck.

Zone I: great vessels of the thoracic outlet; lung apices and trachea; oesophagus, thyroid, and thoracic duct; cervical spine and cervical nerve trunks. Access to the major vessels of Zone I may require resection of part of the clavicle or a sternotomy.

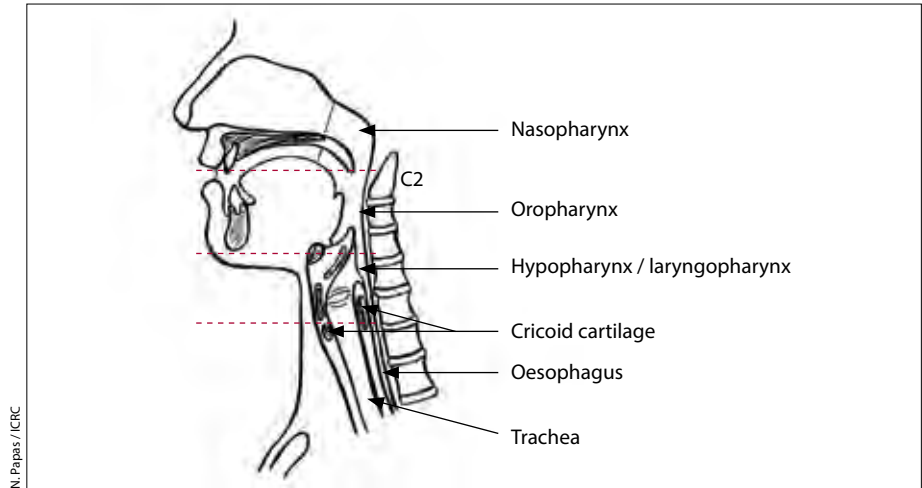
Zone II: jugular-carotid vascular bundle and vertebral vessels; larynx, pharynx, and cervical spine. The vasculature of Zone II is easy to access.

Zone III: distal internal carotid and vertebral arteries entering the skull and jugular veins exiting; oropharynx and cervical spine. The distal vessels at the base of the skull in Zone III are particularly difficult to isolate.

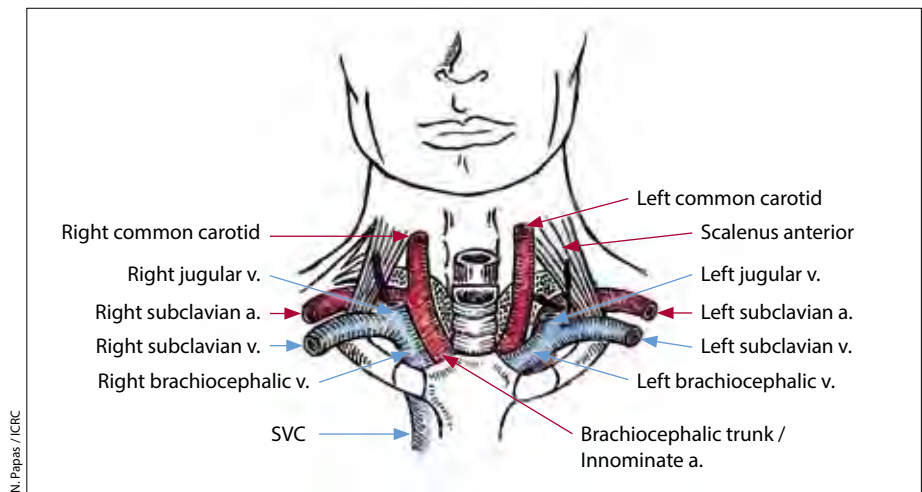
The anterior triangles of all three Zones contain the organs of the aero-digestive tract and the jugular-carotid vascular bundle under the sternocleidomastoid (SCM). The posterior triangles contain the vertebral artery, cervical spine and the cervical plexus.

<sup>1</sup> First described by Monson DO, Saletta JD, Freeark RJ. Carotid vertebral trauma. *J Trauma* 1969; **9**: 987 – 997 and refined by Roon AJ, Christensen C. Evaluation and treatment of penetrating cervical injuries. *J Trauma* 1979; **19**: 391 – 396.

**Figure 30.2**  
Aero-digestive tract in the neck.

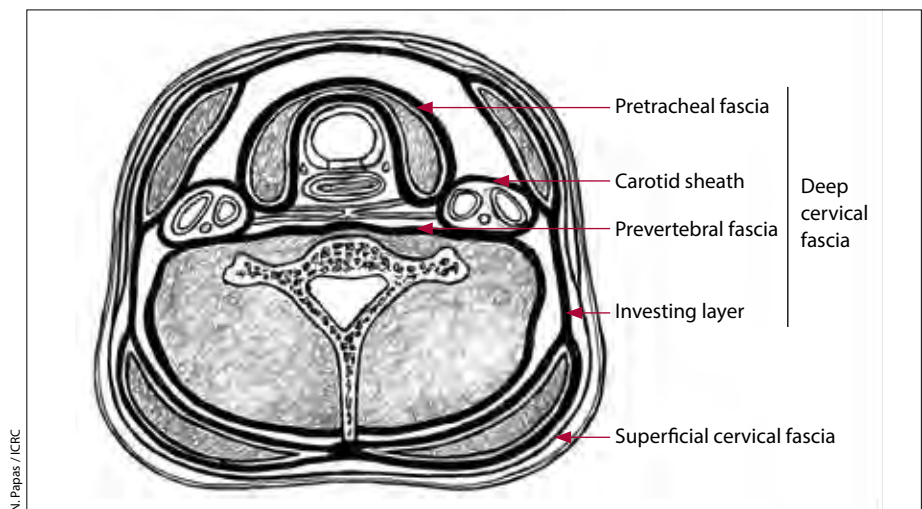


**Figure 30.3**  
Major vessels of the root of the neck.



Two fascial layers enclose the structures of the neck: the superficial fascia containing the platysma and the deep cervical fascia, which divides into the investing, pretracheal, and prevertebral layers. The deep fascia forms compartments that may limit external haemorrhage, but the ensuing accumulation of blood can compromise the airway by external pressure. The attachments of the fascia are such that infection or air can track down from the neck to the mediastinum and pericardium.

**Figure 30.4**  
Fascial layers and compartments of the neck.





### 30.3 Wound ballistics

The neck is an intersection of soft organs lying against the cervical vertebral column and surrounded by an inelastic fascial enclosure. In terms of wound ballistics, three regions can be described. Posteriorly, the nape comprises muscles and fascia surrounding the cervical spine – a uniquely mobile bony axis. Laterally, the posterior triangles contain relatively few vital structures. The anterior triangles contain the great vessels and the hollow organs of the aero-digestive tract. The three Zones of the neck are clinically most relevant in the anterior triangles.

The major vessels and nerves in Zone I are partially protected from low-energy projectiles by the clavicle and the first rib; major damage can occur if these bony elements are fractured by a high-energy projectile.

The narrowness of Zone II – both antero-posteriorly and from side-to-side – means that a high-energy FMJ bullet displays only the effects of the narrow phase 1 shooting channel: a through-and-through wound. These transfixing wounds follow the “all-or-nothing” rule: either they hit a vital structure, often with fatal consequences, or not, causing survivable lesions. The immediate threat to life is direct injury to a major blood vessel. The smaller the calibre of the injured artery, the greater the chance of temporary haemostasis by haematoma tamponade within the closed space of the fascial compartment.

Small, low-energy fragments, with a small entry wound, can perforate a vessel or cause slight damage leading to a pseudoaneurysm or A-V fistula. On the other hand, large fragments and deforming or ricochet bullets create a large cavity immediately on impact in a small anatomic region that is resistant to stretch because of the presence of the deep fascia. The entry wound is much larger and haemorrhage from a major vessel to the outside can be exsanguinating.

The respiratory passages are relatively rigid structures held up by their cartilages, so that when hit by a projectile a defect results. The defect can be through-and-through and small, tangential in the lateral wall and of variable size, or result in a major loss of substance.

The oesophagus behaves like a hollow organ, characterized by resistance to stretch damage because of its elasticity. This elasticity allows for very small entry and exit wounds that may not always be visible during an endoscopic examination or at operation.

A projectile entering Zone III has a much greater chance of hitting bone, either the mandible, the vertebral column, or the base of the skull.

### 30.4 Epidemiology

Like the head, the neck receives a disproportionate percentage of injury. The surface area of the neck represents only 1% – 2% of the body, yet accounts for 5 – 15% of wounds amongst survivors. Table 30.1 shows statistics for neck injuries among US armed forces during World War II, in Korea and in Viet Nam.

Conflict	Killed in action	Died of wounds	Wounded survivors
World War II	9%	6%	9%
Korea	10%	7%	11%
Viet Nam	8%	8%	17%

Table 30.1 Neck wounds among US casualties during World War II and the conflicts in Korea and Viet Nam.<sup>2</sup>

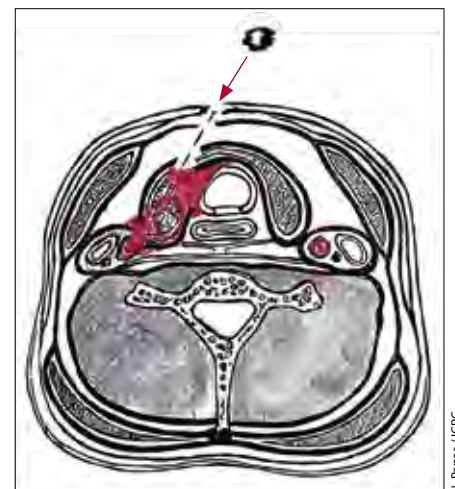

Figure 30.5

Low-kinetic energy fragment involving the carotid and resulting in a haematoma in the closed fascial compartment leading to compression of the airway.

<sup>2</sup> Adapted from Carey ME. Learning from traditional combat mortality and morbidity data used in the evaluation of combat medical care. *Mil Med* 1987; **152**: 6 – 13.

In general, Zone II injuries tend to be the most common (about half the patients); followed by Zone I (slightly less than a third) and Zone III (about a quarter). Injuries to the anterior triangle predominate (85%) over the posterior.

Studies of the distribution of injured organs in the neck demonstrate that vascular and visceral lesions occur almost equally: 47% versus 45% in one report from the Lebanese civil war, 53% and 46% in another, from the war in the former Yugoslavia.

Table 30.2 shows the distribution of 142 lesions encountered during 112 neck explorations (Zones II and III) taken from the Lebanese study, in which most wounds were due to fragments. Notable is the fact that major positive findings were seen in only 55% of the 112 patients. Similarly, in the other example from the former Yugoslavia, only 58% of explorations in 95 patients revealed positive findings.<sup>3</sup>

Site of injury		Number of lesions	Positive findings
Arterial	Common carotid	11	19 %
	Internal carotid	8	
	External carotid	6	
	Vertebral	2	
Venous	Internal jugular	36	28%
	External jugular	4	
Total vascular		67	47 %
Airway	Larynx	17	21 %
	Trachea	13	
Digestive tract	Pharynx	28	24 %
	Oesophagus	6	
Total visceral		64	45 %
Soft tissue	Thyroid	1	–
Neurological	Cranial nerves	10	7 %

Table 30.2 Anatomic distribution of wounds in 112 neck explorations. American University Hospital, Beirut.<sup>4</sup>

A number of clinically important findings can be taken from these studies.

- Whatever the cause of injury about one-third of the carotid artery lesions are accompanied by signs of cerebral ischaemia. Theoretically, restoration of circulation might transform an ischaemic infarct into a haemorrhagic one. In reality this does not occur; rather it is cerebral oedema that causes post-repair complications.
- Except in the case of a small fragment, it is rare to see an isolated vascular injury.
- Up to 50% of laryngo-tracheal wounds present concomitant injury to the pharynx or oesophagus.

A projectile injuring the neck may also cause intracranial or thoracic lesions depending on the angle of attack of its trajectory.

### 30.4.1 Red Cross Wound Score

Injuries to major structures are considered vital wounds. Wounds of the major vessels, carotid artery and internal jugular vein, qualify as V = H, given that exsanguination is possible with both. Lesions of the airway from the larynx down through the trachea constitutes a V = T wound. Injury to the cervical spine is V = N.

3 Progmec D, Đanić D, Miličić D, Leović D. Management of war-related neck injuries during the war in Croatia, 1991 – 1992. *Eur Arch Otorhinolaryngol* 1996; **253**: 294 – 296.

4 Adapted from Ramadan HH, Samara MA, Hamdan US, Shahinian HK. Penetrating neck injuries during the Lebanese war: AUBMC experience. *Laryngoscope* 1987; **97**: 975 – 977.

## 30.5 Clinical presentations and emergency room care

### C-ABCDE sequence for the neck

Catastrophic haemorrhage = open bleeding from major vessel.

Airway = larynx + trachea.

Breathing = apex of lungs.

Circulation = contained bleeding from thoracic outlet, carotid, jugular, or vertebral vessels.

Disability = cervical spine + cranial nerves + cervical and brachial plexus + internal carotid artery.

E = Esophagus.

### 30.5.1 C-ABCDE: Catastrophic haemorrhage

Catastrophic haemorrhage from a major vessel is rarely seen in emergency reception unless the patient has been injured close to the hospital or if pre-hospital care has controlled the bleeding by digital pressure and the evacuation time is relatively short. First aiders should be questioned about any loss of blood in the field.

If direct digital pressure keeps the haemorrhage under control, it should be maintained up to the operating theatre where the first aider's hand is included in the sterile operating field. If it is inadequate, as demonstrated by an increasing haematoma in the neck or continued external bleeding, then an emergency room damage-control procedure is indicated. A large Foley catheter (20 F) is inserted in the entry wound and inflated with saline with the drainage outlet clamped; the wound edges are stitched closed to ensure tamponade. Some wounds, particularly at the base of the neck, may require the placement of two catheters.

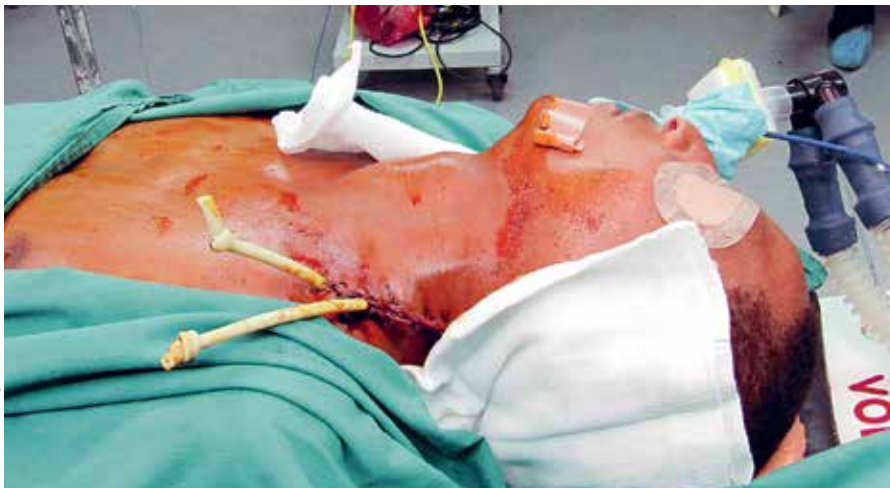

Figure 30.6

Tamponade of a vascular lesion in the neck by means of two Foley catheters.

Under no circumstances should blind clamping be performed in the depths of a wound.

If a Foley catheter tamponade is used, the *airway should be secured even if it is not immediately threatened*. Failure to intubate leads to asphyxiation as the haematoma expands and presses on the airway.

### 30.5.2 Airway

The next important life-threatening condition is a compromised airway, which may be due to direct injury or compression by a haematoma.

Most penetrating airway injuries are obvious on presentation. The signs and symptoms include stridor or hoarseness, dyspnoea and haemoptysis; laryngeal instability, tracheal deviation and tenderness on palpation. There may be “bubbling” of blood in the wound or subcutaneous emphysema. Because of the anatomy of the fascial planes, surgical emphysema may extend to the mediastinum, pericardium, or pleural cavity, and may reach from the “scalp to the abdomen” in extreme cases.

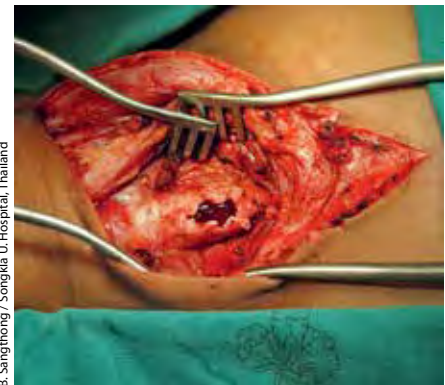
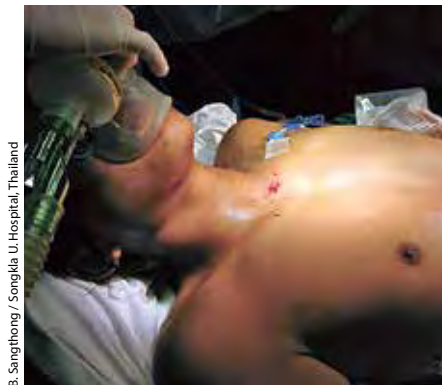If the laryngo-tracheal wound is very small, usually caused by a small fragment, the patient can be kept in the lateral security position with the head down. This allows the blood to trickle into the mouth and be spat out. A cooperative patient may be allowed to sit up and expectorate.

Any wound that *compromises* the air passages requires a definitive airway in the ER. Intubation may be attempted, but can be difficult and cause gagging and retching that may increase bleeding by dislodging a clot. Depending on the expertise of the ER staff, it may be more expeditious to perform needle cricothyroidotomy *in extremis* while preparing for a surgical cricothyroidotomy and then converting this into a formal tracheostomy in theatre (see Section 8.3.4).

Cricothyroidotomy can be life-saving.

Figures 30.7.1 and 30.7.2

This patient suffered a GSW to the neck. The trachea has been intubated.



A very large wound in the larynx or trachea constitutes a “traumatic tracheostomy” and a small endotracheal tube can be directly inserted while awaiting a formal, surgical tracheostomy. To avoid tearing the lacerated trachea during insertion of the tube, a large suture should be passed through the distal edge of the laceration and fixed to the skin; it serves as a retractor, a guide, and avoids avulsion of the trachea during intubation (see Figure 30.18.2).

Severe, complicated wounds such as an arterial-tracheal fistula are extremely difficult to deal with in the ER. An endotracheal tube inserted through a cricothyroidotomy and placed so that the balloon compresses the opening in the vessel may be the best that can be done in these circumstances. The oesophageal balloon of a Sengstaken-Blakemore tube used for bleeding oesophageal varices is more appropriate, if available.

External compression of the airway by haematoma is best dealt with by endotracheal or cricothyroid intubation.

Blunt trauma to the neck may usually be managed conservatively in the absence of hoarseness or change in quality of the voice, surgical emphysema, or dysphagia. A significant blow from the butt of a rifle often requires a definitive airway as there is almost always a fracture of the hyoid, larynx, or cricoid.

### 30.5.3 Breathing and Circulation

Injury to the apices of the lungs or vascular lesions in Zone I may lead to tension pneumothorax or haemothorax requiring a chest tube.

Less than catastrophic bleeding may show active external haemorrhage or “bubbling” of blood at an entry wound. A tracheo-vascular fistula may present as haemoptysis and an oesophago-vascular fistula as haematemesis. An expanding or pulsatile haematoma may be seen and felt on gentle palpation. In the event of a pseudoaneurysm or A-V fistula, a thrill is felt on palpation and a bruit is heard on auscultation.

The carotid and superficial temporal pulses should be felt, and the blood pressure measured in *both* upper limbs.

Shock may not be haemorrhagic, however; neurogenic shock is a distinct possibility in wounds of the neck and should not be forgotten (see Section 36.3.2).

Intravenous lines should be placed in the contralateral arm or the legs. Note should be taken of which leg, since a saphenous vein graft may need to be taken for vascular repair in the neck. The urine output should be monitored by catheter.

### 30.5.4 Disability

Disability presents as tetraplegia, cranial nerve dysfunction and/or brachial plexus injury. Sensation and movement and the cranial nerves should be tested.

Injury to the carotid or vertebral arteries may show signs of cerebrovascular ischaemia: hemiparesis or hemiplegia, aphasia, or decreased level of consciousness. Such central neurological manifestations may occur with spasm of the carotid artery owing to a “near-miss” by a passing bullet; the clinical picture improves with time. Projectile wounds in the neck may extend into the cranium depending on the angle of attack of the trajectory, and neurological signs may be the result of direct brain injury.

#### Neurological signs of injury

Cervical spine: tetraplegia, neurogenic shock.

Cervical plexus: Horner’s syndrome (ptosis, myosis, enophthalmosis, anhydrosis).

Brachial plexus: motor and sensory deficit in the arm.

Facial nerve (VII) mandibular branch: drooping of the corner of the mouth.

Glosso-pharyngeal nerve (IX): affects swallowing and the gag reflex.

Vagus (X) or recurrent laryngeal nerve: change in voice.

Accessory nerve (XI): weakness of trapezius.

Hypoglossal nerve (XII): deviation of tongue.

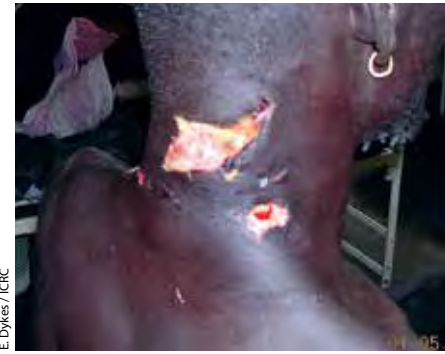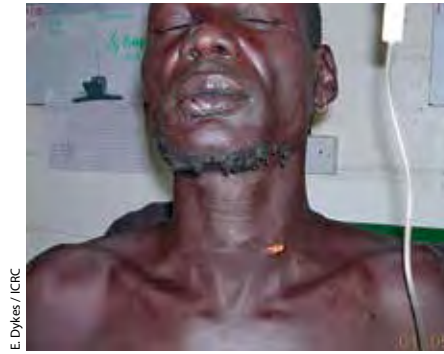Carotid artery: hemiparesis.

### 30.5.5 Oesophagus and visceral wounds

Injury to the hypopharynx or oesophagus may present as dysphagia, haematemesis, or pain on swallowing (odynophagia). Such lesions are often asymptomatic at first but serious injury may well have occurred in spite of the initial absence of clinical findings. Many cases are associated with lesions of the larynx or trachea, and a high degree of suspicion is warranted when faced with wounds in the airway. Late presentation is frequently complicated by fistula formation and infection that may extend into the mediastinum.

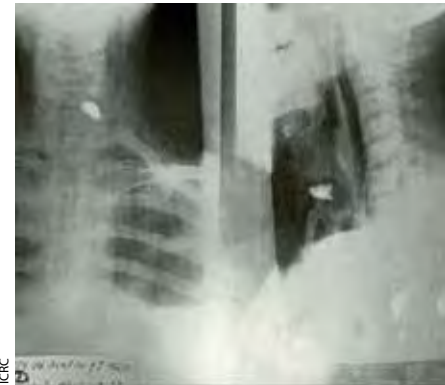**Figures 30.8.1 and 30.8.2**

GSW to the front of the neck resulting in an oesophageal fistula. The patient's neck was tilted back when hit with the resultant ragged double exit wound. No haematoma, no airway problems and no infection. The patient is under i.v. antibiotics preoperatively.



**Figures 30.9.1 and 30.9.2**

Late-presentation oesophageal fistula; the airway was intact. Fluids escape from the orifice in the patient's neck when drinking. X-ray showing a retained fragment.



A clear or milky discharge from a left-sided wound indicates injury to the thoracic duct. Injury to the thyroid has no specific sign or symptom.

**30.5.6 Investigations**

The haemodynamic stability of the patient determines the extent of paraclinical investigations. Plain X-rays of the neck (antero-posterior and lateral) and chest should be taken as a minimum, with radio-opaque markers placed on entry and any exit wounds. Radiography may show tracheal deviation or subcutaneous emphysema, soft-tissue swelling denoting a haematoma, or a haemo- or pneumothorax, as well as a lesion of the vertebral column or a retained projectile. Retropharyngeal air may be the only sign of an injury to the oesophagus.

Please note:

Standing or sitting for an X-ray and taking a deep breath carries the risk of air embolism through an injured vessel. The airway should be secured and wound haemorrhage controlled before the taking of X-rays.

Laryngoscopic examination in the operating theatre is generally available. Angiography, oesophagoscopy (rigid or flexible), and contrast studies are less likely to be at hand.

Barium is the best contrast medium to demonstrate an oesophageal perforation. There have been reports of a tissue reaction that could theoretically lead to mediastinitis. This should not be a problem if the delay to operation is likely to be shorter than two hours. A water soluble contrast medium such as diatrizoate (Gastrografin®) is theoretically safer, although it has a higher incidence of false negatives and positives. An alternative in the absence of contrast media is to give the patient a dilute solution of methylene blue or gentian violet to drink.

An appropriate technology alternative to contrast radiographic studies: give the patient methylene blue to drink.

## 30.6 Decision to operate

Superficial wounds down to the platysma require only a debridement, thorough irrigation, and immediate primary closure; one of the exceptions to delayed primary closure.

Traditional treatment holds that all wounds penetrating the platysma require surgical exploration even in asymptomatic patients, a practice largely based on military experience. The high percentage of negative explorations, as noted in the section on epidemiology, has given rise to a more conservative approach in recent practice, except in the case of transfixing wounds traversing the neck.

However, this selective approach is related to low-kinetic energy wounds and the availability of sophisticated diagnostic means. Although improvised arteriography may be undertaken by the surgeon himself even where resources are limited (see Section 24.4.2), the selective approach involves repeated clinical examinations requiring sufficient numbers of doctors and well-trained nursing staff. High-energy projectiles cause a greater volume of tissue damage and in such cases there is arguably less call for a selective approach.

### Zone II injuries

The surgeon working with limited resources has a relatively straightforward task when faced with Zone II injuries and can revert to the classic military protocol: *obligatory exploration*, even in the absence of clinical signs. In addition to haemorrhage, an obviously inadequate airway and extensive surgical emphysema necessitate rapid intervention.

Zone II injuries: in a low-resource environment, it is safer to look-and-see rather than wait-and-see.

### Zone I and III injuries

The real dilemma for the general surgeon working in resource-poor settings lies with wounds in Zones I and III, where sophisticated diagnostic technology is of greater value for localizing the anatomy of any lesion, especially since many injuries may be clinically occult.

Obvious signs of active haemorrhage or a massive or pulsatile haematoma require emergency intervention. The insertion and inflation of a Foley catheter can be a useful temporizing measure; in Zone III, the sternocleidomastoid muscle should be tightly sutured around the catheter to promote the tamponade effect. Zone III injuries high up near the base of the skull are very difficult to access even in experienced hands and a conservative approach is often justifiable.

It is always possible to stop haemorrhage by ligating an artery and accepting the consequences. A few basic operative techniques will, nonetheless, help the general surgeon to better explore these wounds. In the asymptomatic patient, the surgeon may prefer a more conservative approach. However, observation and conservative treatment put the patient at greater risk and require much time and effort from the nursing staff. The experience and expertise of the surgeon help determine how aggressive an operating posture should be taken.

## 30.7 Patient preparation

A naso-gastric tube is gently placed *only when in the operating theatre*, before induction of anaesthesia. The gagging that its introduction may produce can easily dislodge a clot in a major vessel. The patient is intubated or a tracheostomy performed, under local anaesthesia if necessary.

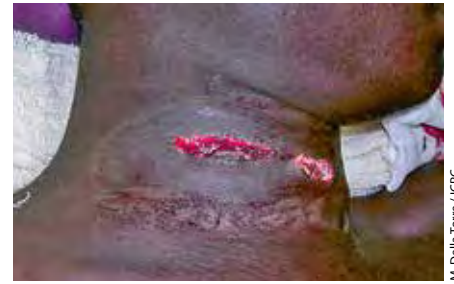

Figure 30.10

Superficial wound of the neck – entry and exit – with no symptoms of airway distress or haemorrhage: simple wound debridement and primary closure are sufficient.

M. Della Torre / CRC

The patient is placed in a supine position, both arms tucked in at the sides with a small roll under the shoulders to extend the neck. The head is held in a ring-shaped or “doughnut” pillow and rotated to the contralateral side. In addition, the table should be put in the Trendelenburg position to help prevent air embolism in the case of a venous injury.

Both sides of the neck up to the lower lip and down to the upper chest are prepared and draped. One lower limb should be prepared for the possible harvest of a saphenous vein graft, which may be taken more distally than the groin in order to match the calibre of the vessel.

In the case of Zone I injury, the upper arm and entire chest are included in the scrub field. The arm is draped so that it can be tucked in at the side or extended. The arm at the side helps “push” the first portion of the subclavian artery above the clavicle; extended, it allows for better exposure of the third part of the subclavian and the axillary artery.

## 30.8 Surgical management of vascular injuries

### 30.8.1 Basic principles

As mentioned in Section 24.6, if repair of a vessel is not possible, ligation is the simplest and surest method to stop bleeding. The neck is a good example of two extremes of any resultant ischaemia: the external carotid artery can be ligated with impunity, the brachiocephalic trunk never.

Two extremes: the external carotid artery can always be ligated, the brachiocephalic trunk never.

As with all vascular surgery, gaining proper access proximal and distal to the lesion constitutes most of the work. In the region of the neck this involves some easy and some difficult incisions. The general surgeon should be familiar with the necessary anatomy.

In the presence of heavy haemorrhage from an important vessel, do not panic.

Any haematoma should be dislodged with caution, as it is readily associated with damage to a major vessel. In the limbs, clamping of the vessels proximally and distally before exploration usually means control of the wound haematoma. In the neck and the torso, such prior clamping is not always possible. If exploration reveals heavy haemorrhage, the key to success is *not to hurry and not to panic*. Direct pressure with a surgical compress usually stops any bleeding and allows the surgeon to pause and let the anaesthetist “catch up” with respect to resuscitation if necessary. Vascular control proximally and distally then permits the removal of stopgap measures and the calm planning of ligation or repair of the vessel. Time can be gained by using a temporary shunt to bridge the gap in a major artery (see Section 24.8).

The use of a temporary shunt can be life-saving.

The injection of a dilute heparin solution distally into the severed artery should be standard procedure with any arterial anastomosis. If the common or internal carotid artery must be clamped, an exceptional i.v. bolus of heparin (5,000 – 10,000 IU) may be given if other body injuries permit. For further details concerning vascular repair, see Chapter 24.



Vascular repair in all three Zones should have a drain placed for 24 hours, especially if a tracheostomy is not part of the surgical procedure. Any accumulation of haematoma in the narrow strictures of the neck may compromise the airway.

The different Zones of the neck require different incisions for access to the various structures. Close clinical observation determines which Zone is the likely seat of injury.

### 30.8.2 Zone I access and injuries

Vascular access is the challenge with these injuries, more so than the actual repair or ligation. A wound to a Zone I vessel may bleed locally (external, haematoma, pseudoaneurysm or A-V fistula) or into the chest. The neck thus constitutes a "junctional" area between the chest and the head (see Section D.6).

Most injuries to the brachiocephalic trunk, subclavian or axillary vessels can be repaired directly or with a venous graft. The subclavian and axillary arteries can be ligated if repair is not possible, usually with few consequences given the excellent collateral circulation.

The brachiocephalic trunk must be repaired.  
The subclavian or axillary vessels can be ligated.

#### Second or third parts of the subclavian or axillary vessels

Proximal control of wounds in the second or third parts of the subclavian or axillary vessels can be achieved through a supraclavicular incision while the arm is kept tucked in at the side. The SCM and anterior scalenus muscles are divided at their insertion to the clavicle, with preservation of the phrenic nerve lying on the scalenus. The middle third of the clavicle may be sectioned or resected subperiosteally if necessary. The collateral circulation is so good that bleeding will continue from the distal parts of the vessels, however. To accomplish distal control, the arm is then extended and dissection proceeds through the deltopectoral groove with division of the pectoralis major and minor at their insertions in the humerus.

#### Brachiocephalic trunk and first part of the subclavian vessels

The brachiocephalic trunk and first part of the subclavian vessels require proximal control *in the chest*. The preferred approach is a "trapdoor" incision.

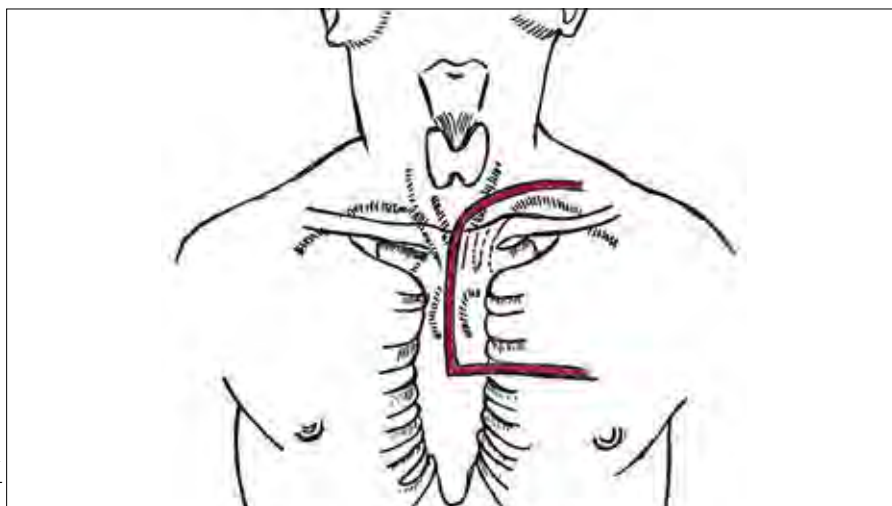


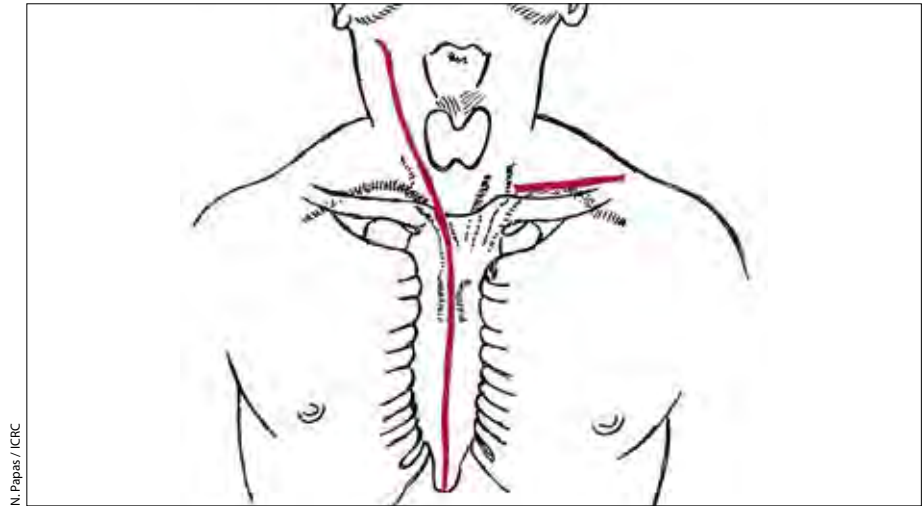
Figure 30.11

"Trapdoor" incision: a manubriotomy extended laterally. The manubrium and part of the sternum are split in the midline by a hammer and bone chisel and the incision carried sideways into the third intercostal space distally. Proximally, it is extended into a supraclavicular incision. This flap is folded back; the clavicle may have to be sectioned.

An alternative is a median sternotomy that is extended into the neck as an SCM incision for the right brachiocephalic trunk or left carotid, or as a supraclavicular incision for the first part of the subclavian vessels. The median sternotomy is described in Annex 31. C.

**Figure 30.12**

Left supraclavicular incision and median sternotomy extended into a right SCM incision (see Figure 30.13.1).



N. Pappas / ICRC

Once the mediastinum is opened, haemorrhage control from the subclavian and brachiocephalic vessels is achieved by grasping the vascular bundle behind the sternoclavicular joint with the fingers and handing it off to the surgeon’s assistant. This buys time. Time is often necessary to achieve distal venous control by opening the neck and supraclavicular fossa in order to gain control of the proximal internal jugular and subclavian veins.

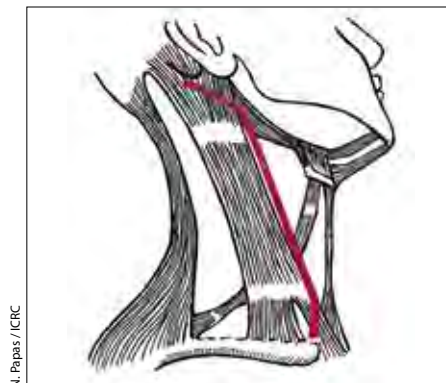
**Neck wound with exsanguinating haemothorax**

In the event of an exsanguinating haemothorax from a neck wound, it is best to perform an *anterior thoracotomy* through the fourth intercostal space of the injured side and push up a pack of gauze compresses into the apex of the thorax to act as a tampon. This is handed over to the assistant who applies manual pressure to the compresses from within the chest. Manual pressure by the assistant’s other hand is applied over the supraclavicular fossa or a large Foley catheter inserted through the skin wound and inflated. The shed blood can be recuperated and autotransfused (see Chapter 34).

A damaged thoracic duct should be ligated.

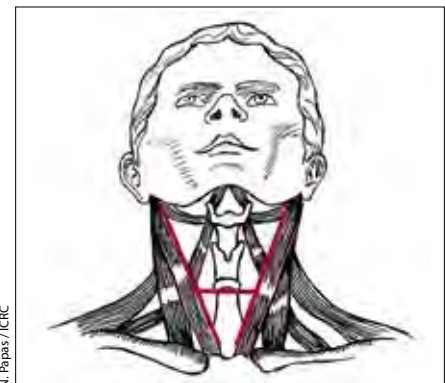**30.8.3 Zone II access and injuries**

Most injuries occur in Zone II, which is also fortunately the easiest to access. An incision along the anterior border of the SCM offers excellent access to the carotid sheath, hypopharynx and oesophagus, and the lateral and posterior wall of the trachea. The SCM is retracted laterally or may be sectioned at its sternoclavicular insertion and pulled back for better exposure. Bilateral SCM incisions connected by a transverse extension create a large superior platysma flap that allows good exposure of bilateral injuries and especially of the larynx and oesophagus.



N. Pappas / ICRC

**Figure 30.13.1**  
Anterior sternocleidomastoid incision.



N. Pappas / ICRC

**Figure 30.13.2**  
Bilateral SCM incisions with transverse connection.

### Internal jugular vein

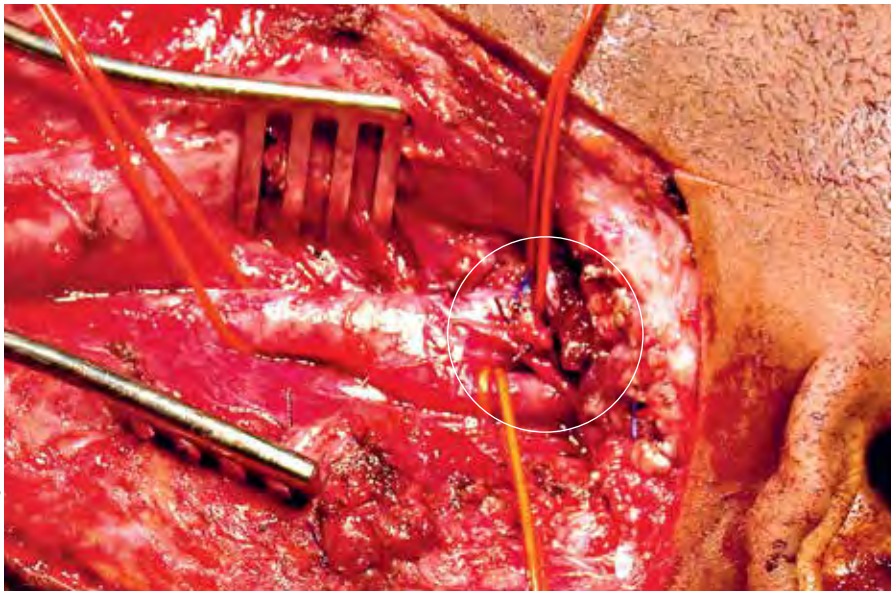
In the case of injury to the internal jugular vein, the patient's head should be kept lower than the heart to lessen the possibility of air embolism. The vein should be repaired if possible, but no great efforts should be deployed to do so; it can be simply ligated with a transfixing suture. For bilateral injuries, however, an attempt to repair at least one should be made. Bilateral ligation has significant morbidity and mortality.

### External carotid artery

The external carotid artery and its branches may be ligated with impunity, even bilaterally.

### Common and internal carotid arteries

For the common and internal carotid arteries, repair is worthwhile only if the patient is neurologically intact. Repair or ligation is possible if the patient suffers a mild deficit and there is retrograde flow from the artery. In the absence of retrograde flow, it is probably too late with respect to cerebral ischaemia and better to simply ligate the vessel. The operating time and age of the patient must be taken into consideration. Repair of the common carotid can be accomplished by direct anastomosis or vein interposition graft; the external carotid artery can be sacrificed to provide for a lateral patch graft. Post-operative stroke is more common and mortality higher in patients who have suffered from shock and neurological deficit pre-operatively.



**Figure 30.14**

A lesion at the bifurcation of the carotid has been repaired.

F. Plani / C.H. Baragwanath, S. Africa

If the patient is neurologically intact, the carotid should be repaired.

If there is already a neurological deficit and retrograde flow, it could be ligated.

If there is no retrograde flow, it is better to simply ligate.

In the event of injury to both the carotid and the jugular vein, the artery should be repaired first to assure perfusion to the brain; one jugular vein is sufficient to assure outflow.

### 30.8.4 Zone III access and injuries

The anterior SCM incision is carried up as far as possible and curved posteriorly over the mastoid process to avoid the mandibular branch of the facial nerve. Exposure of the distal internal carotid at the base of the skull is aided by dislocation of the temporo-mandibular joint or section of the mandible just below the condyle, allowing a pseudo-arthritis to form later. In addition the mastoid insertion of the SCM can be sectioned.

In most cases, ligation of the distal carotid artery is the best that can be achieved and the patient and surgeon must accept the eventual neurological consequences. If the segment of the distal carotid before entering the skull is too short for ligation, the hole should be plugged with bone wax (one of the rare occasions when bone wax is acceptable in war surgery). Temporary tamponade can often be accomplished by the insertion of a Foley catheter.

### 30.8.5 Posterior triangle: vertebral artery

Fortunately seldom injured, the vertebral artery in the posterior triangle is very difficult to access, especially in the foramina of the upper 6 vertebral transverse processes. Tamponade is probably the procedure of choice in the acute condition, whatever the Zone of injury. Most cases undergo thrombosis and little need be done after removal of the tamponade after 24 – 48 hours. Should bleeding recur, the hole in the transverse process should be stopped up with a piece of crushed muscle or, exceptionally, bone wax, and pressure applied.

## 30.9 Surgical management of laryngo-tracheal injuries

Up to 50% of laryngo-tracheal wounds are complicated by injury to the pharynx or oesophagus; any airway lesion requires an appropriate exploration. A tracheo-oesophageal fistula should be repaired.

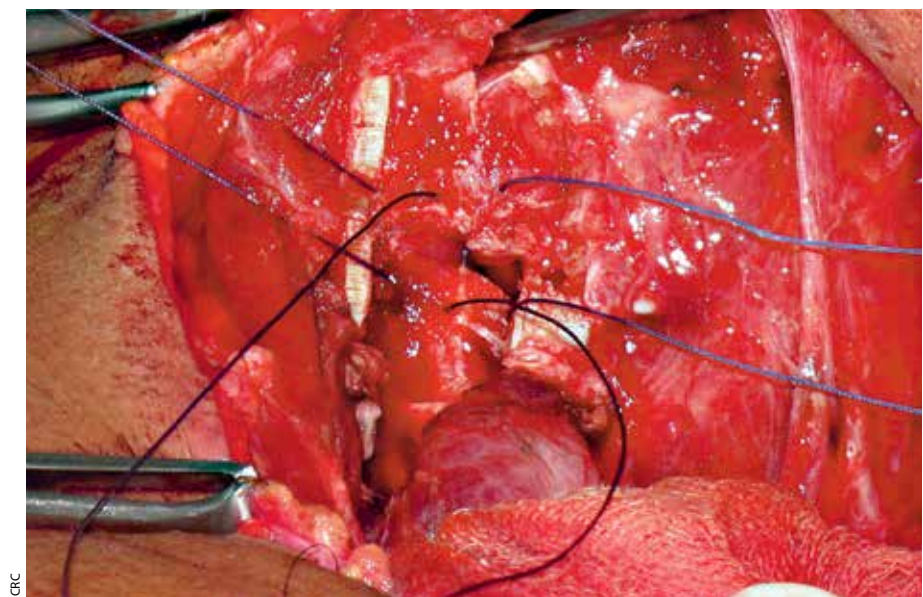
### 30.9.1 Surgical access

A midline incision should be used only for very small and uncomplicated injuries. Otherwise, adequate access to the larynx and trachea is usually easily accomplished through bilateral SCM incisions with a transverse connexion.

### 30.9.2 Laryngeal wounds

A distal tracheostomy is mandatory. Small wounds are debrided and the mucosa and cartilage closed with absorbable sutures; the knot is placed external to the laryngeal cavity. For an injury to the cricoid cartilage, the tissues around the first tracheal ring should be mobilized to close the defect. A stent such as an endotracheal tube should be used to prevent stenosis of the larynx and kept in place for 14 days.

Figure 30.15  
Repair of a laryngeal wound.



Severe damage to the laryngeal skeleton or paralysis of the vocal cords pose enormous surgical problems; as does late laryngeal stenosis. With the airway secured by a tracheostomy, it might be wisest to accept that state and close the laryngeal skeleton as best as possible. Late reconstruction and repair should be performed only by an ENT surgeon.

Late reconstruction and repair of laryngeal wounds should be undertaken by an expert.

### 30.9.3 Tracheal wounds

If the wound is very small and anteriorly placed it can be transformed into a formal tracheostomy and cannulated with a tube until oedema resolves. The tube is then removed and the opening allowed to close spontaneously.

A tracheal wound less than 40% of the circumference can be directly repaired. The edges of the mucosa and cartilage are conservatively debrided and the mucosa closed with absorbable sutures, the knot again being placed outside the airway cavity. The cartilaginous sutures include one tracheal ring above and below the site of injury. A distal tracheostomy is performed.

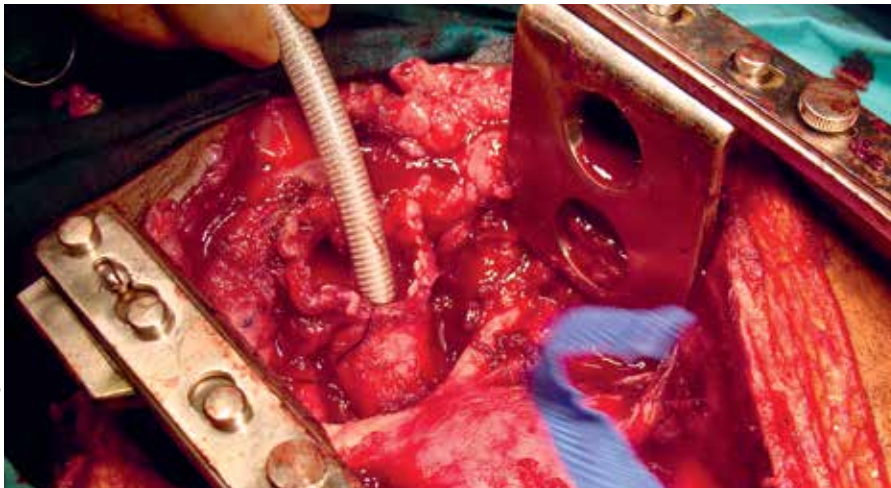


Figure 30.16

Direct intubation of a tracheal wound prior to repair.

Large lacerations of the trachea greater than 40% of the circumference should be resected and primary anastomotic repair performed over an endotracheal-tube stent. This is accomplished by mobilizing the trachea in the anterior and posterior planes (the blood supply to the trachea comes laterally). A large gap can be bridged by a free periosteal flap: the clavicular head of the SCM is detached sub-periosteally from its attachment and the periosteum harvested. A tracheostomy distal to the repair completes the operation.

### 30.9.4 Blunt injuries

A sharp blow to the throat with the butt of a rifle, for example, may cause a laryngeal or soft-tissue haematoma, or a dislocation-fracture of the laryngeal cartilages. Immediate laryngeal obstruction may not occur but the risk is always present. Careful observation is important and cricothyroidotomy may be required as an emergency procedure. If such close observation is not readily available, then a temporary tracheostomy is the best and most prudent choice.

### 30.9.5 Other viscera and soft tissues, etc.

Injury to the thyroid gland requires minimal debridement and closure of the capsule. Attention must be paid to the parathyroid glands and recurrent laryngeal nerve as with all thyroid surgery.

## 30.10 Surgical management of pharyngo-oesophageal injuries

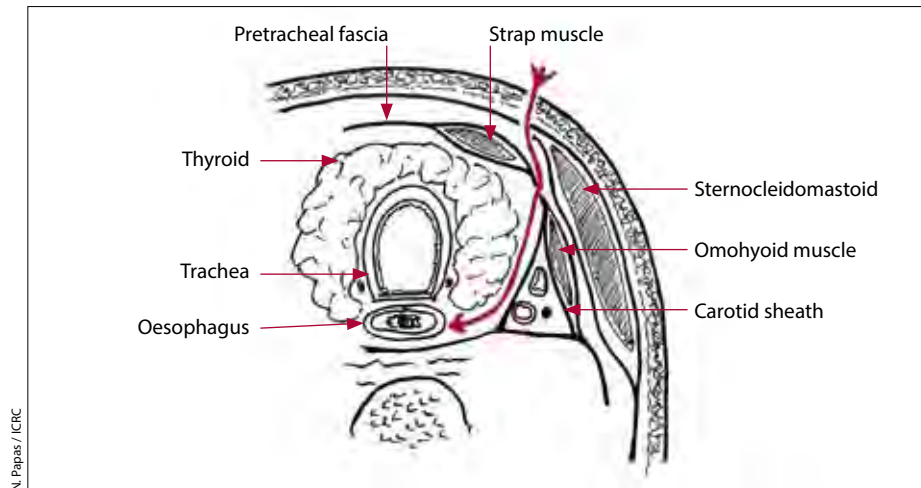
Wounds involving the laryngopharynx or cervical oesophagus tend to cause gross contamination of the tissue planes of the neck with saliva. The subsequent infection may track downwards and cause fatal mediastinitis. Every attempt should be made to prevent such spreading contamination.

### 30.10.1 Access and operative diagnosis

In all cases careful and wide exposure through bilateral SCM incisions with a transverse connexion is necessary to get at the depths of the wound. A Foley catheter or Penrose drain passed around the oesophagus allows it to be rotated to permit better inspection of its entire circumference.

**Figure 30.17**

Surgical access to the cervical oesophagus.



Lesions of the pharynx or oesophagus may not be obvious, the clinical signs minimal or absent. Often, the only evidence is a small haematoma in the para-oesophageal tissues. The complications of a missed oesophageal wound are the major cause of late mortality in neck injuries.

Missed oesophageal wounds are the major cause of late mortality in neck injuries.

Careful examination for entry and exit wounds is essential: the surgeon must always be suspicious of an *odd number* of perforations. Simple methods help in identifying any holes in the oesophageal wall: staining with barium or with methylene blue or gentian violet. An alternative method performed on-table is to fill the wound with normal saline and insufflate air through a proximal naso-gastric tube with fingers pinching the distal oesophagus to close it.

### 30.10.2 Repair

The edges of the injured pharynx or oesophagus are carefully trimmed. Surrounding dead and contaminated tissues are debrided.

Primary repair of the hypopharynx should be done if practicable. Otherwise a defunctioning pharyngo-cutaneous mucosal fistula and cervical oesophagostomy should be performed.

Small oesophageal lacerations should be sutured directly. Larger injuries may require some mobilization of the oesophagus to permit closure without tension on the suture line. Gentle blunt dissection in the areolar tissue plane behind the oesophagus, the continuation of the retropharyngeal space, permits the gain of several centimetres in length. The oesophageal wound is closed in two layers and an appropriate muscle mobilized to cover the suture line, since the oesophagus has no serosa. If the strap

muscles prove too flimsy, the SCM can be detached either from its proximal or distal insertion and swung around. This is especially important when separating the injured oesophagus from the trachea after repair of a tracheo-oesophageal fistula.

Mobilize a muscle to cover an oesophageal repair or to separate the repairs of a tracheo-oesophageal fistula.

A soft Penrose drain should be placed on the muscle covering the repair and the wound left open for DPC two to three days later. Drainage of the oesophagus is more crucial than the technique of repair. Having no serosa, it is very prone to a suture leak and the subsequent cervical cellulitis can easily track downwards causing mediastinitis, empyema, and septicaemia.

Drainage of the oesophagus is more important than the technique of repair.

Post-operatively, the suture line must be protected for 7 – 10 days and the patient nourished through a naso-gastric tube or a feeding gastrostomy or jejunostomy. After this period, if there is no clinical evidence of a leak, a methylene blue or barium swallow test is performed. If the test is negative, oral intake can then begin, but the drain should be removed only after another two days with no discharge. If there is evidence of a leak, the drain must be left in place to help control it. The fistula is usually small and closes spontaneously with time. Non-closure requires re-operation once local inflammatory changes have subsided.

A large wound of the oesophagus, not amenable to mobilization and repair, can be converted into a controlled cervical fistula and oesophagostomy and closed at a later time. A "T-tube" inserted in the oesophagus and held in place with thick ligatures helps to control the drainage of saliva. This also serves as an emergency damage-control procedure.

If repair of injury to both trachea and oesophagus is difficult, the oesophagus should be sacrificed in favour of the trachea. The oesophagus can be replaced later, the trachea cannot.

### 30.11 Post-operative care

The patient should be nursed in a semi-sitting position. Close monitoring of the tracheostomy and signs of complications specific to neck injuries is essential:

- haemorrhage;
- compression of the airway by an enclosed haematoma;
- pneumothorax;
- missed oesophageal injury with a salivary fistula;
- infection;
- thoracic duct injury with chylothorax or a lymphatic fistula.

Antibiotic coverage should be administered, according to protocol: if the airway or digestive tracts are open, ampicillin and metronidazole; otherwise, simple vascular injury requires penicillin only. Anti-tetanus measures must be given as always.

Proper attention must be paid to the patient's nutrition, by either naso-gastric feeding, gastrostomy or jejunostomy. Physiotherapy for the chest is essential, especially if the patient has a tracheostomy.

## 30.12 Tracheostomy

Mention is often made of tracheostomy in this manual. It is a very useful procedure when working with limited resources and its importance easily underestimated. A tracheostomy removes about 150 ml of dead space from the airway, thus making respiration more efficient in terms of oxygen delivery and removal of carbon dioxide with less effort on the part of the patient. It is a good adjunct to the treatment of a patient with severe head or lung injury or tetanus, and is essential for the management of maxillofacial and neck injuries. It makes patient management easier when adequate care is taken.

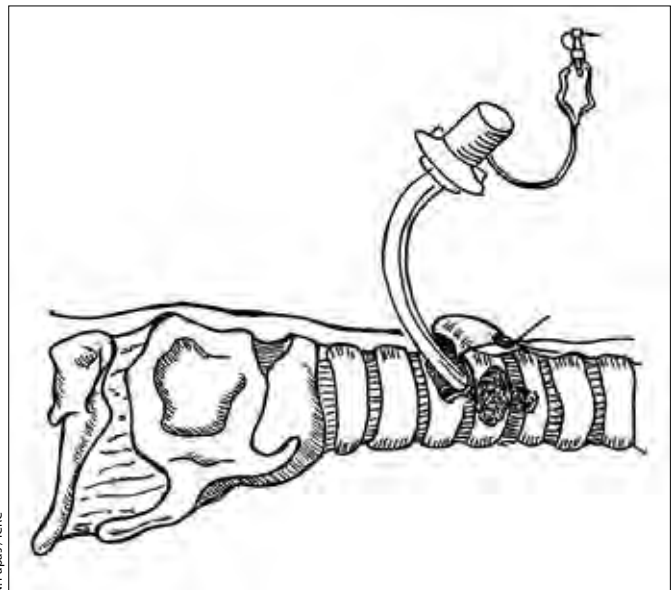
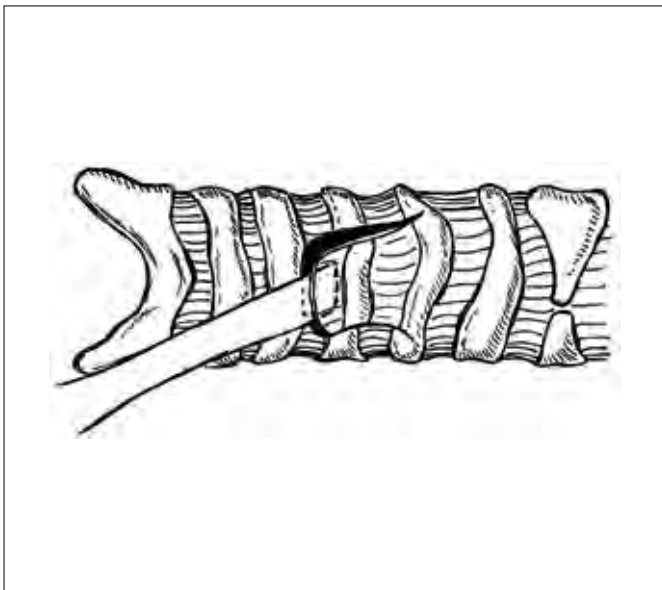
It is not a replacement for mechanical ventilation, but when this is not available, it is the best procedure to be had. Even in hospitals where mechanical ventilation is a routine, most protocols involve changing the patient from endotracheal intubation to a tracheostomy after a few days to a week.

### Please note:

Technically, cutting into the trachea is a “tracheotomy” and the use of the opening as an artificial orifice is a “tracheostomy”. Some authors, however, use the term tracheotomy to describe an intubation of the opening *without suturing* the trachea to the skin, reserving the term tracheostomy for when there is such suturing. Other authors speak of a temporary versus a permanent tracheostomy.

In this manual, the term tracheostomy is used indiscriminately whether the trachea is sutured to the skin or not. In situations where nursing care is limited, however, fixing the tracheal edges to the skin is recommended, to avoid life-threatening developments in case of tube displacement or inadvertent removal.

Various techniques are available for tracheostomy, more or less sophisticated, more or less as an elective procedure. Simple emergency tracheotomy through a *vertical* midline incision with the head well extended and a pillow between the shoulders, reaching the trachea *below* the thyroid isthmus, is a quick and relatively bloodless operation in experienced hands. The strap muscles are split by blunt dissection and the thyroid isthmus retracted upward if necessary. A simple slit or an inverted “U”-incision is made through one or two rings in the trachea. It is preferable to insert a synthetic stitch through a tracheal ring just distal to the intended opening, which holds the opening steady and prevents further distal laceration of the trachea during tube introduction. The stitch can then be fixed to the skin.



Figures 30.18.1 and 30.18.2

“U”-flap tracheostomy with a distal stitch. The same distal stitch should be placed in case of a “traumatic tracheostomy”.



Two types of tracheostomy tube in various sizes are available: a disposable synthetic one with an inflatable balloon at the end, and a synthetic or silver-plated model with inner and outer tubes. The models with double tubes allow the inner tube to be removed for cleaning while the outer “permanent” tube remains in place. They are preferred if the patient is to remain with a tracheostomy for a considerable period of time or in the case of severe oedema where re-inserting a displaced single tube can be very difficult.

### 30.12.1 Tracheostomy care

Adequate nursing care is the key if the patient is to receive full benefit of the treatment and complications avoided.

- The skin around the tracheostomy should be kept clean of any dried secretions; gentle swabbing with a moist compress is usually sufficient.
- A special filter to breathe through should be used, if available. Otherwise, a gauze compress kept moist with normal saline should cover the opening.
- Any oxygen delivery should be humidified.
- The balloon should be deflated several times a day to prevent pressure necrosis of the trachea and later stenosis. Once the tracheostomy is well established, it may be left deflated.
- The inner tube should be cleaned twice daily at least with saline and sodium bicarbonate to remove mucus secretions and then rinsed with a mild disinfectant.

Noisy breathing and gurgling, indicates a build up of secretions, which should be gently suctioned. The following protocol for tracheostomy suctioning is recommended.

1. Prior to suctioning, 7 – 10 ml of a solution of normal saline plus sodium bicarbonate are instilled into the trachea by syringe. This helps humidify and break up the secretions and stimulates coughing.
2. The suction catheter is kinked between the fingers to stop the aspiration flow and gently passed through the tracheostomy tube for as far as it can go.
3. The kink is then released to apply suction while the catheter is gently rotated and slowly withdrawn.
4. The procedure is repeated several times until all the secretions are gone.

If the hospital has a sufficient quantity of disposable catheters, then a new one should be used for each session. If not, the cleaned suction catheter should be kept in a jar of disinfectant.

Good physiotherapy and breathing exercises help to dislodge any secretions and prevent hypostatic pneumonia. The patient should be mobilized as much as the clinical condition permits.



**Part D**

# **TORSO**

D.	TORSO	
D.1	Introduction	361
D.2	Epidemiology	361
D.3	Thoraco-abdominal wounds	362
D.4	Injuries to the diaphragm	364
D.5	Transaxial injuries	365
D.6	Junctional trauma	365
D.7	The general surgeon and the chest: the psychological partition	366

## Basic principles

Projectile wounds of the torso are a surgical challenge.

A chest tube should be inserted routinely in all thoraco-abdominal wounds, before anaesthesia.

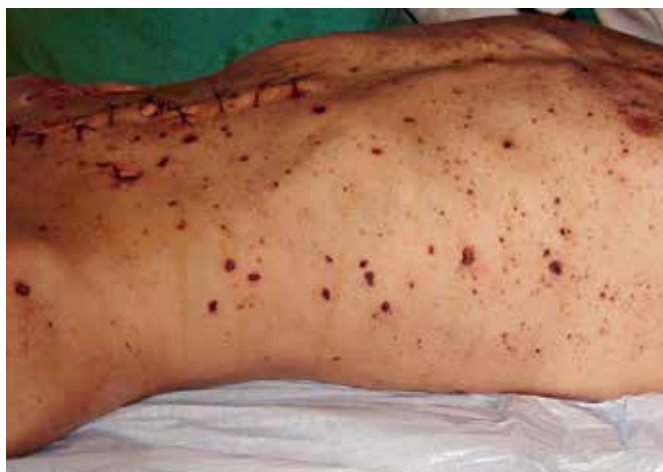Deciding which cavity has priority – thoracic or abdominal – can be difficult.

The chest should not be “off limits” to the general surgeon.

### D.1 Introduction

The torso comprises the chest, abdomen, and pelvis, including the buttocks. Penetrating missile wounds to the torso can easily involve more than one body cavity, and commonly do. The extent of the thorax differs considerably during inspiration and expiration with excursion of the diaphragm. Thus, an entry wound in the “thorax” can easily affect the abdomen as well. Any penetrating wound from the nipple line to the groin and upper thighs must raise suspicion of an abdominal injury.

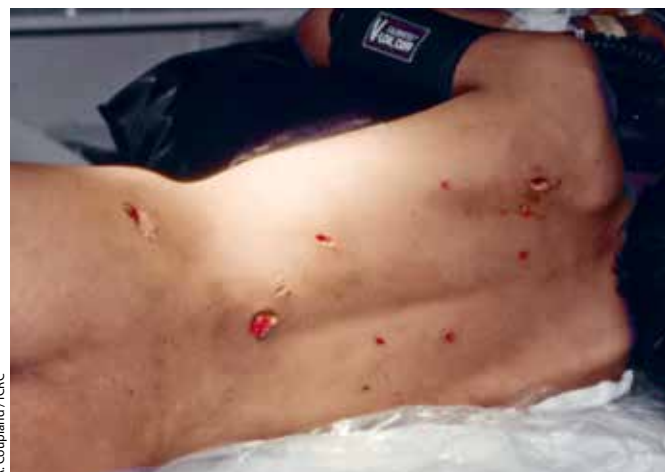The surgeon must bear in mind that while a single projectile may injure both the chest and the abdomen, passing through the diaphragm, multiple gunshot wounds and especially multiple fragments may well injure both cavities without affecting the diaphragm.



F. Planz / ICRG

**Figure D.1**

Multiple fragment wounds often pose a problem of clinical diagnosis.



R. Coupland / ICRG

**Figure D.2**

And do not forget the back!

### D.2 Epidemiology

In most series from the past, both the thorax and the abdomen are the site of 6 to 15% of the injuries (see Table 5.6). Up to 40% of thoracic injuries are thoraco-abdominal. Table D.1 shows some examples from various modern conflicts where the wearing of body armour was not yet standard.

Conflict / Source	Intrathoracic injuries (N = number of patients)	Thoraco-abdominal wounds	Other associated injuries*
USA – Viet Nam (1968 – 69) McNamara et al., 1970.	547	34 %	85 %
Israel – Egypt, Syria (October 1973) Levinsky et al., 1975.	42	21.5 %	14 %
Chad (1980) Dumurgier et al., 1996.	56	12.5 %	≈ 50 %
Israel – Lebanon (June 1982) Rosenblatt et al., 1985.	64	42 %	> 40 %
Lebanon civil war (1969 – 82) Zakharia, 1985.	1,992	12.6 %	10 %
ICRC (Lebanon civil war 1976) Kjaergaard, 1978.	44	31.8 %	≈ 25 %
Belfast (1969 – 76) Ferguson & Stevenson, 1978.	100	31 %	25 %
Belfast (1969 – 88) Gibbons, 1989.	430	29 %	≈ 40 %
Soviet Union – Afghanistan (1981 – 84) Roostar, 1996.	1,314	29 %	19 %

\* Includes spinal cord.

**Table D.1** Incidence of thoraco-abdominal wounds and other associated injuries. Source articles are cited in the Selected bibliography under Chapter 31 General references.

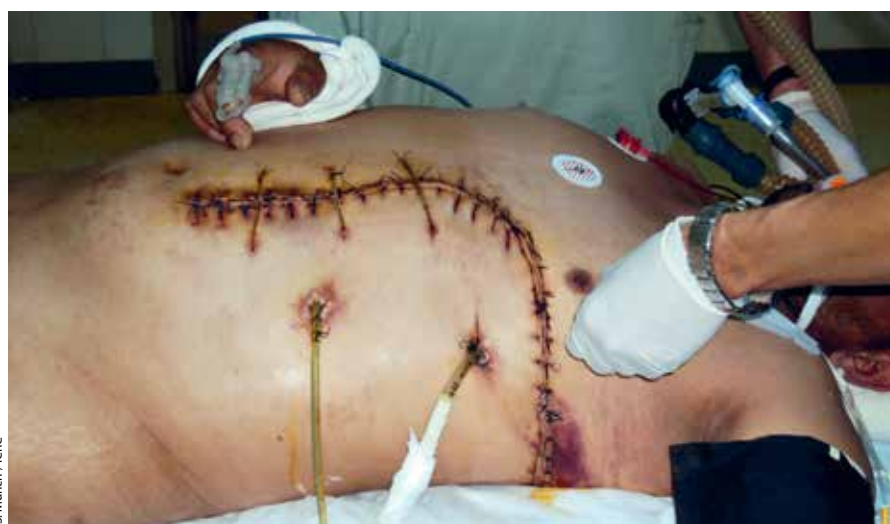### D.3 Thoraco-abdominal wounds

A chest tube should be inserted routinely in all thoraco-abdominal wounds, and before the laparotomy.

Patients with thoraco-abdominal injuries have thoracic wounds that can usually be managed by closed chest tube drainage, and abdominal wounds that require laparotomy. Mortality in war trauma comes not from a negative laparotomy, but from a missed abdominal injury. It has been said that the most common operation for chest trauma, after intercostal tube drainage, is a laparotomy. The chest tube should always be placed *before* the laparotomy. There are patients, however, who require both a thoracotomy and a laparotomy. Making separate chest and abdominal incisions is the standard procedure in the vast majority of these cases.

**Figure D.3**

A good example of what should not be done: the laparotomy incision is paramedian rather than midline and is continued on in a low anterior thoracotomy. This incision is of very little use in trauma surgery.



J.S. Munch / ICRC

If both thoracic and abdominal explorations are necessary, separate incisions should be made when possible.

A dilemma may arise where both a thoracotomy and a laparotomy are called for and the surgeon must decide which cavity to enter first. With some injuries, this is obvious; in other cases, not. Communication and cooperation with the anaesthetist are essential to establish priorities for these patients.

An open, sucking chest wound requires immediate closure and insertion of a chest tube to ensure the proper functioning of the lung. Should such a wound be accompanied by heavy abdominal haemorrhage, the chest defect can be closed by a temporary dressing while the laparotomy proceeds. The anaesthetist must closely observe the patient for the development of a tension pneumothorax and for oxygen saturation. This example is relatively straightforward.

What if the amount of blood exiting from the chest tube warrants an exploratory thoracotomy and a laparotomy is required as well? Which haemorrhage is more life-threatening? Which cavity should be entered first? Is the blood flowing from the chest tube thoracic in origin? Or is it abdominal and passing through a hole in the diaphragm? The surgeon must be prepared to enter the left chest both to inspect the thoracic contents and to clamp the descending aorta if necessary. The source of bleeding, and whether or not a rapid damage-control laparotomy through a separate midline incision is warranted before releasing the aortic clamp, should become obvious.

What if the choice is made to perform a laparotomy first, revealing little or no haemorrhage and yet hypotension persists in spite of little blood coming from the chest tube? Is the chest tube badly placed, kinked, or blocked by a clot? Is the hypotension due to pericardial tamponade? Or is it due to neurogenic shock?

These problems are well known.<sup>1 2</sup> Chest tube drainage, central venous pressure readings as well as the clinical examination of a patient with a thoraco-abdominal injury can all be unreliable and misleading. The clinical signs in the abdomen are not always clear when the patient is straining to breathe.

An inappropriate choice in the sequence of thoracotomy – laparotomy can be made for anywhere between 20% and 45% of haemodynamically unstable patients presumed to have suffered thoraco-abdominal injuries. Therefore, the surgeon must prepare the patient for both a thoracotomy and a laparotomy when scrubbing, and be mentally prepared to interrupt a procedure prematurely to exit one cavity and enter another. Patients who are simultaneously bleeding from more than one site may require the surgeon to make a “jump” from an abbreviated thoracotomy to an abbreviated laparotomy, performing damage-control procedures to help gain time in one cavity before attending to the other.

The surgeon must be flexible and mentally prepared to jump from one side of the diaphragm to the other, interrupting one procedure to deal with a second source of bleeding.

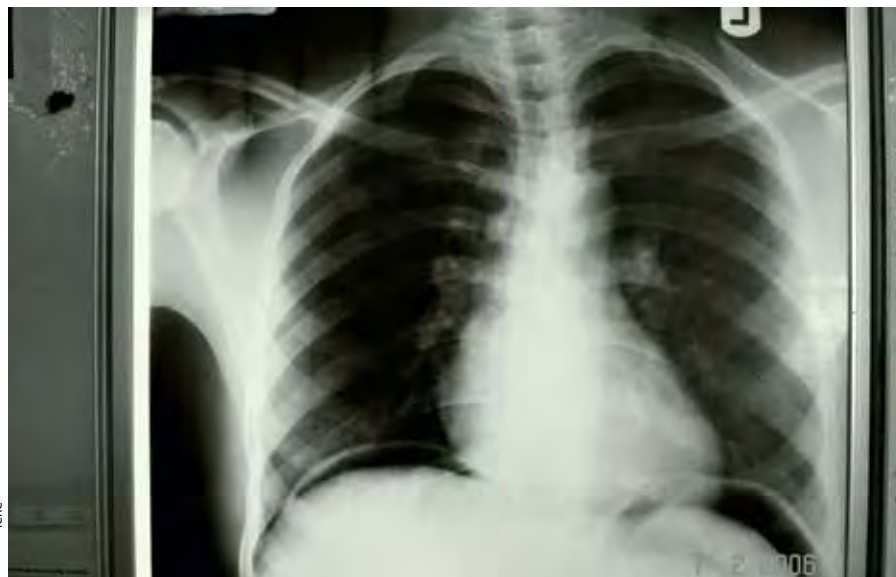1 Hirshberg A, Wall MJ Jr, Allen MK, Mattox KL. Double jeopardy: thoracoabdominal injuries requiring surgical intervention in both chest and abdomen. *J Trauma* 1995; **39**: 225 – 231.

2 Asensio JA, Arroyo H Jr, Veloz W, Forno W, Gambaro E, Roldan GA, Murray J, Velmahos G, Demetriades D. Penetrating thoracoabdominal injuries: ongoing dilemma – which cavity and when? *World J Surg* 2002; **26**: 539 – 543.

## D.4 Injuries to the diaphragm

Figure D.4

Thoraco-abdominal wound with air under both cupolas of the diaphragm.

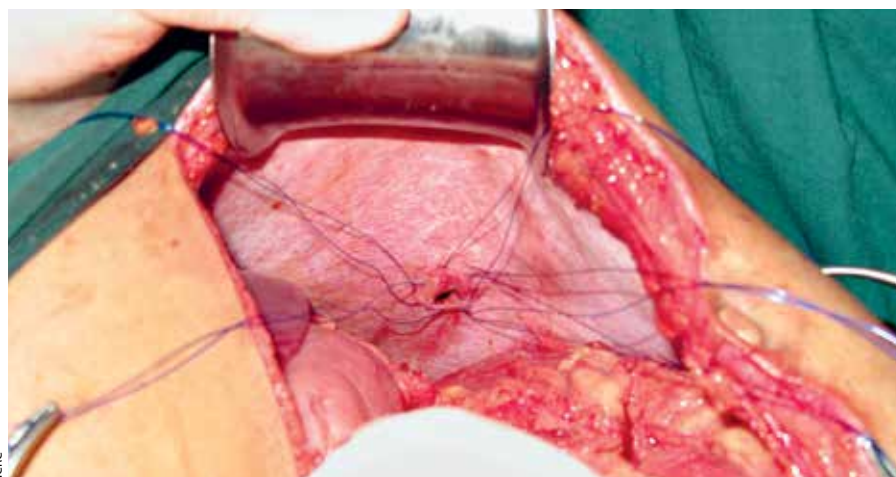


A single projectile wounding both the thorax and the abdomen must perforate the diaphragm. If the defect is large enough, an abdominal viscus may herniate into the chest, although this is more common with blunt trauma. More importantly, intestinal contents from a perforated bowel may pass into the chest, demanding appropriate toilet and washing out of the pleural cavity after adequate control of the abdominal injuries. It is essential to remember that an unrecognized perforation of the diaphragm can become a sucking wound that can readily lead to tension pneumothorax. Small perforations along the posterior pulmonary sulcus can easily go unnoticed.

Perforations of the diaphragm should be closed carefully with a thick non-absorbable suture; placing stay sutures at both ends of the laceration helps to provide traction. Small lesions can be closed with a continuous suture, long ones with interrupted horizontal mattress sutures to prevent shredding of the muscular diaphragm and ischaemia that may lead to diaphragmatic hernia later on. Some surgeons prefer a two-layer closure, first continuous then interrupted.

Figure D.5

Repair of a perforation of the diaphragm.



Furthermore, if a diaphragmatic perforation is discovered during thoracotomy, a transthoracic approach to the abdomen should *not* be attempted – it does not permit adequate exploration of the abdomen.

Access to the abdomen should never be attempted through a diaphragmatic perforation during thoracotomy.



## D.5 Transaxial injuries

Transaxial injuries present entry and exit wounds on opposite sides of the torso, or a retained bullet on the opposite side of the entry, as diagnosed either by X-ray or intra-operatively. Such a projectile trajectory obviously has a great chance of hitting a vital structure in either the thorax or the abdomen, or both. Automatic, natural triage comes into play and not all casualties survive to reach hospital. The shorter the evacuation time, the more serious the injuries encountered in the ER. Otherwise, the surgeon sees the patients in whom the projectile passed between vital organs without hitting anything important. Indeed, the anterior mediastinum is a largely “empty” space.

The transaxial bullet trajectory is not always obvious: patients are not injured while standing in the anatomic position. Misinterpretation of the resulting injury is easy and it is often difficult to identify the correct body cavity to enter first. This is clearly shown in one study involving 223 consecutive patients with wounds to the torso.<sup>3</sup> The projectile trajectory was transaxial in 28% of patients and unilateral in 66%; 5% were undeterminable because of multiple bullet wounds. Among the 63 patients with definite transaxial wounds, the abdomen was the site of injury in 67% of the cases; the thorax in 14%; and 19% suffered thoraco-abdominal injuries.

The transaxial wounds resulted in a much higher incidence of injury to a vital structure and significantly greater mortality, especially for transaxial thoraco-abdominal wounds, where mortality reached 42% and two-thirds of the deaths were intra-operative. The authors encountered many surgical problems: in particular that the first cavity they opened was *not* the site of active haemorrhage. The other side of the diaphragm or other hemi-thorax then had to be explored *in extremis*. There were many missed injuries, and 19% of the transaxial patients required early re-operation.

## D.6 Junctional trauma

The torso forms a “junction” with the upper extremities at the axilla, with the lower limbs at the groin, and with the root of the neck at the thoracic outlet. Trauma at these junctions, particularly in major vascular bundles, puts life and limb at risk. Proximal control of haemorrhage must be performed in a body cavity and distal control in the limb or the neck. The general surgeon is thus faced with an especially complicated task.

A good analysis of the challenges is presented in Table D.2.

Characteristic	Implication
Owing to the anatomy, digital pressure cannot be exercised or a tourniquet cannot be placed above the wound.	Proximal control requires surgical incision extending across a joint flexure or into an adjacent torso cavity: thoracic or peritoneal.
The limb may be at risk because of vascular or associated injury.	Limb salvage must be balanced against life preservation.
Neighbouring body cavity structures may have been damaged by the same projectile trajectory.	There is the potential for hidden blood loss in the form of haemothorax or haemoperitoneum. A vascular repair in the groin may be at risk from faecal contamination.

Table D.2 The hallmarks of junctional trauma.<sup>4</sup>

As with thoraco-abdominal wounds in an unstable patient, recognizing the nature of the injury and deciding which body part to enter first can be problematic. Setting operative priorities is the key to saving “life and limb”. Is the patient haemodynamically stable or not? What are the different sources of bleeding: chest and/or abdomen and/or limbs? How can one best gain proximal control of any extremity haemorrhage? What damage-control techniques are available? When to ligate; when to put in a shunt; when to perform definitive vascular repair?

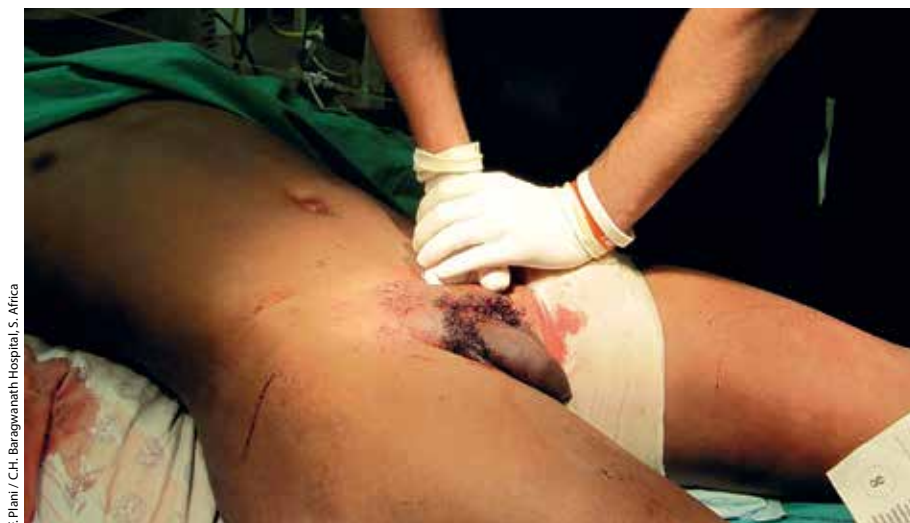3 Hirshberg A, Or J, Stein M, Walden R. Transfix gunshot injuries. *J Trauma* 1996; **41**: 460 – 461.

4 Adapted from: Tai NRM, Dickson EJ. Military junctional trauma. *J R Army Med Corps* 2009; **155**: 285 – 292.

Proximal control of the vascular bundle at the root of the neck (Zone 1) is dealt with in Section 30.8.2 and covers the junction between thorax and neck on the one hand, and between the thorax and upper limb on the other. The vascular bundle at the junction between the abdomen and the lower limb is most rapidly and best controlled proximally by laparotomy to expose the iliac vessels.

**Figure D.6**

Direct pressure to control a case of junctional haemorrhage; there is no space to apply a tourniquet.



F. Plani / CH. Baragwanath Hospital, S. Africa

## D.7 The general surgeon and the chest: the psychological partition

The diaphragm not only constitutes an anatomic partition between the thorax and the abdomen, but also a psychological barrier in the mind of many general surgeons. The general surgeon must familiarize himself with thoracic anatomy in order to operate with confidence – and gather courage. Most general surgeons lack experience in operating in the chest and approach a thoracotomy with trepidation. This is probably due to the presence of the heart and great vessels; it also has a great deal to do with their own training. Faced with a patient dying before one's eyes, however, courage should overcome fear.

The thorax is not a "sacred" cavity and the same basic surgical principles apply to the chest as apply to the abdomen. In the same way that neurotraumatology is not neurosurgery, the general surgeon usually has all the skills required to deal with most surgically correctable lesions in the thorax. The most extreme cases of thoracic trauma end up being non-salvageable in any case.

The chest is not off-limits.

A few basic principles can easily be understood and learnt:

- underwater seal drainage of the pleural cavity rather than an open abdominal drain;
- tight closure of the pleura to re-establish the negative intrathoracic pressure required for respiration.

Occasionally a thoracic surgeon may be present, but when working with limited resources this is seldom the case. Nonetheless, much can be done by applying simple well-founded surgical principles despite the lack of equipment and supplies.<sup>5 6</sup>

5 Dumurgier C, Teisserenc JY, Emanuely P. A propos du thorax en chirurgie de guerre: plaidoyer pour la thoracotomie. [Concerning the thorax in war surgery: a plea for thoracotomy.] *Lyon Chir* 1996; **92**: 124 – 128.

6 Hassan MY, Elmi AM, Baldan M. Experience of thoracic surgery performed under difficult conditions in Somalia. *East C Afr J Surg* 2004; **9**: 94 – 96.





## **Chapter 31**

# **THORACIC INJURIES**

31.	THORACIC INJURIES	
31.1	Introduction	371
31.2	Wound ballistics	371
31.2.1	Reaction of bone	372
31.2.2	Reaction of the lung	372
31.2.3	Reaction of other organs	373
31.2.4	Reaction of the diaphragm	373
31.3	Epidemiology	373
31.3.1	Mortality	373
31.3.2	Distribution of thoracic organ injuries	373
31.3.3	Thoracotomy rate	374
31.3.4	Associated injuries	375
31.3.5	Red Cross Wound Score	375
31.4	Clinical presentation	376
31.4.1	Initial examination	376
31.4.2	Complete examination	377
31.4.3	Haemothorax and pneumothorax	378
31.4.4	Paraclinical investigations	379
31.5	Emergency room management	380
31.6	Intercostal chest tube drainage	381
31.6.1	Indications and basic principles	381
31.6.2	Chest tube drainage and autotransfusion	382
31.6.3	Post-operative care of chest tube drainage	383
31.6.4	Complications	385
31.7	Thoracotomy	385
31.7.1	Emergency room thoracotomy	386
31.7.2	Indications for urgent thoracotomy	386
31.7.3	Indications for early thoracotomy	387
31.7.4	Indications for late thoracotomy	388
31.7.5	Patient preparation, positioning, and anaesthesia	388
31.7.6	Choice of incision	389
31.8	Exploration of the chest cavity	390
31.9	Wounds of the chest wall	391
31.10	Injuries of the lung	391
31.10.1	Haemostasis of the lung parenchyma	391
31.10.2	Intrapulmonary haematoma, blast lung, lung contusion and flail chest	393
31.10.3	Tracheobronchial injury	394
31.11	Great vessels, heart and pericardium	395
31.11.1	Pericardial tamponade	395
31.11.2	Subxyphoid pericardial window	395
31.11.3	Anterior thoracotomy and injuries to the heart	396
31.11.4	Myocardial suture	397
31.11.5	Azygous venous system	397
31.12	Oesophageal injuries	398
31.13	Other injuries	399
31.13.1	Thoracic duct	399
31.13.2	Thymus	399
31.13.3	Diaphragm	399
31.14	Thoracic damage control	400
31.15	Post-operative care after thoracotomy	400
31.16	Retained haemothorax	401
31.17	Empyema	402
31.17.1	Decortication of empyema	403
ANNEX 31. A	Intercostal nerve block	405
ANNEX 31. B	Intercostal chest tube	406
ANNEX 31. C	Thoracic incisions	412

## Basic principles

More than 90% of thoracic projectile injuries can be treated by the insertion of a chest drain only.

The proper functioning of the chest drain must be checked regularly.

With a major haemothorax, autotransfusion should be considered.

Thoraco-abdominal injuries are common.

Pain relief and physiotherapy are essential if empyema is to be prevented.

## 31.1 Introduction

“Bleeding from the parenchyma of the lung in wounds of the thorax may be massive, but is slow and seldom requires hemostasis. On the other hand, free bleeding from the heart, great vessels, internal mammary or intercostal arteries is fast and profuse. Rapidly progressive shock is present early and death may quickly ensue unless hemorrhage is checked.”

R. Arnold Griswold and Charles H. Maguire<sup>1</sup>

Blunt, blast, and penetrating trauma to the chest all occur during armed conflict. Many patients suffer superficial soft-tissue wounds and fractures of the chest wall without intrathoracic damage. In some, minimal chest wall damage may accompany internal lesions that, if not immediately fatal, quickly put the patient's life at risk.

Given the high concentration of vital structures in the chest, thoracic wounds are highly lethal. However, for the overwhelming majority of survivors reaching hospital, simple chest tube drainage will be all the surgical management they need. The correct placement of a chest tube can be accomplished by a well-trained general practitioner or experienced nurse.

When dealing with primary blast trauma, the surgeon must be aware that a blast wave envelops and affects the entire torso, and may inflict bilateral injuries.

Even when blood for transfusion is in ready supply, autotransfusion for a massive haemothorax can be lifesaving – even more so in circumstances where blood is scarce (see Chapter 34).

## 31.2 Wound ballistics

The chest is composed of a set of heterogeneous organs with widely differing ballistic characteristics. The trajectory and particularly the length of the wounding channel are of crucial importance for the production of cavitation effects. A particularly stable bullet traversing the antero-posterior diameter of the chest may create only a narrow shooting channel with little permanent tissue damage (Figure 31.1); if cavitation occurs at the exit point, it will result in a large sucking wound (Figure 31.2). On the other hand, the same bullet traversing the side-to-side diameter has a high chance of displaying all three phases of the wounding channel – narrow phase 1, temporary cavity, and terminal narrow channel – within the confines of the chest (see Section 3.3.3).

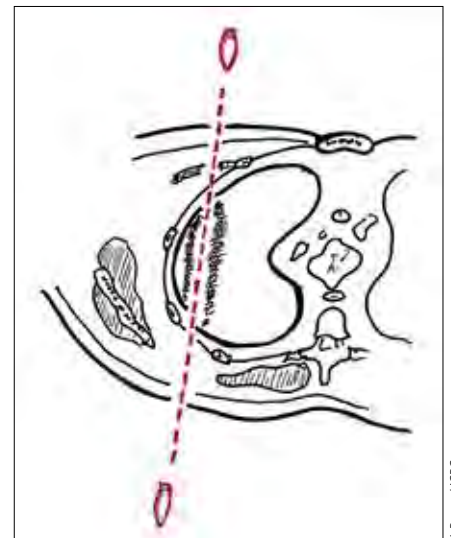


Figure 31.1

Transfixing wound of the lung entirely within the narrow phase 1 shooting channel with no cavitation effects.

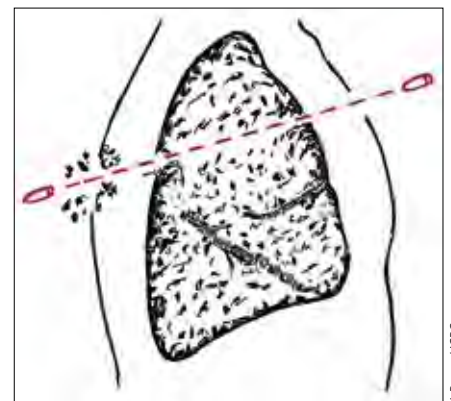


Figure 31.2

Antero-posterior transfixing FMJ bullet: cavitation beginning at the exit and resulting in an open sucking chest wound.

1 Griswold RA, Maguire CH. Penetrating wounds of heart and pericardium. *Surg Gynecol Obstet* 1942; **74**: 406 – 418.

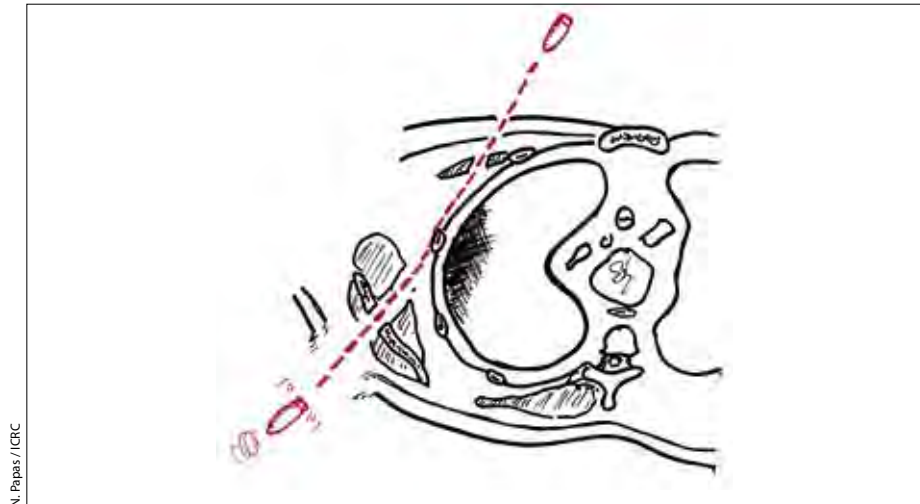
### 31.2.1 Reaction of bone

A stable bullet punches a hole through a rib or the sternum, but a fragment or destabilized bullet can drive bits of bone into the underlying lung or mediastinum. The point of entry of an unstable projectile can create a large hole resulting in the open pneumothorax of a sucking chest wound.

The flexibility and curvature of the ribs can cause a bullet arriving at a small impact angle to inflict a tangential wound. The impulse provokes a serious contusion of the underlying lung. Depending on the angle and level of kinetic energy, a large part of tissue may be torn away, also causing a sucking chest wound.

**Figure 31.3**

Tangential wound of the chest wall with underlying pulmonary contusion. The bullet has become destabilized.



N. Papas / CRC

#### An open pneumothorax sucking chest wound can result from:

- injury by a fragment or ricochet bullet;
- cavitation effect at a bullet's exit point;
- a tangential missile blow to the ribs.

In terms of ballistic effects, the thoracic vertebral column offers the same characteristics as that of the neck, except that the bony elements are larger and have less flexibility. Fracture of a vertebral bony element can push bony fragments into the spinal cord as well as the lung or mediastinum.

### 31.2.2 Reaction of the lung

The lung parenchyma is highly elastic and can easily withstand stretch deformation; however, it is readily lacerated. Thus a high-energy stable rifle bullet can cause less permanent damage than a slower and heavier handgun bullet that has little cavitation effect but crushes a greater volume of tissue. Larger lacerations are the result of bony fragments projected into the lungs. Significant cavitation from a high-kinetic energy bullet may nonetheless provoke a zone of pulmonary contusion with copious bloody secretions aspirated into the uninjured part of the lung. This can cause atelectasis and pneumonia. Laceration and the zone of contusion can also result in an intrapulmonary haematoma.

The lungs are particularly sensitive to primary blast injury. Rupture of alveoli and their capillaries in addition to intra-alveolar and interstitial oedema lead to a disorder of the ventilation-perfusion relationship and an inadequate alveolar gas exchange. Pneumothorax, haemothorax, surgical emphysema and pneumomediastinum have been observed. With alveolo-venous fistulas the risk of systemic air embolism is high (see Section 19.8).



### 31.2.3 Reaction of other organs

The heart and great vessels are essentially fluid-filled organs that do not tolerate stretch at all: cavitation causes explosive rupture. The trachea and oesophagus react like hollow organs little affected by stretch. The close proximity of all these vital structures in the mediastinum makes isolated injuries uncommon and most major wounds are quickly fatal.

In survivors, however, injuries from low-kinetic energy projectiles – small fragments or bullets travelling at a very low velocity – are seen, resulting in the clinical presentations of cardiac tamponade, pseudoaneurysm of a great vessel, or perforation of the trachea or oesophagus. As in the neck, the entry and exit orifices in the oesophagus may be difficult to see even during operative exploration.

### 31.2.4 Reaction of the diaphragm

Cavitation effects close to the diaphragm cause very serious lesions to this muscle. A large laceration of the left cupola may result in herniation of abdominal organs into the chest; wounds in the right cupola invariably lead to severe injury to the liver. More frequently, simple projectile perforation and small radial tears of the diaphragm are seen; cavitation effects may be observed further along the wounding channel, either in the lung or in the abdomen depending on the direction of the shot.

## 31.3 Epidemiology

### 31.3.1 Mortality

Penetrating chest wounds account for about 10% of the wounded and approximately 25% of those killed in action in contemporary warfare. The mortality of a thoracic wound is about 70% and depends to a great extent on the weapon; it is much higher with high-energy bullets and close-up primary blast than with small fragments. Wearing body armour changes these percentages by preventing projectile penetration but does not protect against primary blast effects.

The main causes of death are lesions to the heart or major vessels. Investigations into preventable deaths in the field reveal that approximately 5% are due to tension pneumothorax or a sucking chest wound, which are amenable to simple treatment. Early hospital mortality is associated with exsanguination and cardiac tamponade. Associated injuries of the airway and bleeding into the abdomen are important cofactors. Most survivors suffer relatively simple wounds in the chest wall or lung parenchyma.

Acute lung injury manifests itself early after primary blast injury and profound haemorrhagic shock; later, acute respiratory distress syndrome (ARDS) may develop.

The danger of infection is always present: a retained haemothorax can progress into empyema and an intrapulmonary haematoma or atelectasis into pneumonia, often with a fatal outcome.

### 31.3.2 Distribution of thoracic organ injuries

Pulmonary lesions are present in 98 – 100% of all series. Injury to certain intrathoracic organs such as the trachea and oesophagus, on the other hand, are rarely observed in survivors; their anatomic relationship to the major vasculature explains the dearth of such lesions. Table 31.1 shows the distribution of injuries to intrathoracic organs, other than the lungs, found during thoracotomy in several series from past conflicts.

Conflict / Source	Patients with intrathoracic injuries	Thoracotomies (Thoracotomy rate)	Heart / pericardium	Major blood vessels	Trachea / bronchi	Oesophagus
USA – Viet Nam (1968 – 69) McNamara et al., 1970.	547	78 (14%)	2.4%	2.9%	0.2%	0
Israel (1973 October war) Levinsky et al., 1975.	42	19 (45%)*	2.4%	9.5%	0	0
Israel – Lebanon (1982) Rosenblatt et al., 1985.	64	6 (9.4%)	7.8%**	0	0	0
Lebanese civil war (1969 – 82) Zakharia, 1985.	1,992	1,422 (71%)*	14.3%	2.7%	2.1%	0.4%
Belfast (1969 – 76) Ferguson & Stevenson, 1978.	100	100 (78%)*	2%	7%	0	1%
USSR – Afghanistan (1981 – 84) Roostar, 1996.	1,314	138 (10.5%) ***	1.5%	0.8%	3.2%	0.5%

\* Referral hospital with specialist surgeons, short evacuation times.

\*\* Small fragments in the pericardial sac and myocardium, not symptomatizing and not operated.

\*\*\* Emergency and early thoracotomies only. The total thoracotomy rate was 19%, but 45% of these were for late empyema.

**Table 31.1 Findings at thoracotomy. Percentages are of total patients with intrathoracic injuries based on operative findings at thoracotomy. See Selected bibliography for sources.**

### 31.3.3 Thoracotomy rate

Chest tube drainage has been reported to be sufficient surgical treatment in about 90% of patients reaching hospital; the experience of ICRC surgeons puts this figure over 95%. Some patients, however, do not require drainage at all.

The great historical controversy in thoracic trauma concerns the criteria for performing a thoracotomy. While an intercostal chest drain is sufficient treatment for most injuries, certain circumstances have encouraged surgeons to take a more aggressive approach and perform thoracotomies more readily and more often. These circumstances can differ widely and explain the great variability in thoracotomy rates shown in Table 31.1.

It would also appear that an important subjective factor should be taken into account: the personality and “aggressiveness” of the individual specialist thoracic and cardiovascular surgeon. The general surgeon dealing with severe thoracic injuries tends to have the opposite subjective prejudice and prefers to be more conservative.

Two noteworthy studies from Chad and Afghanistan with specialist surgeons available but working under difficult and precarious circumstances offer an interesting contrast. In Chad in 1980, a French military forward field hospital received 1,484 war-wounded patients in eight weeks during conflict in an urban environment; 56 of them had suffered thoracic injuries requiring surgery.<sup>2</sup> The total thoracotomy rate was 68% (38 out of 56). The urge to operate after just one hour of observation under intercostal tube drainage was based on several factors in the opinion of these specialist surgeons: heavy workload, lack of nursing staff to monitor the patients properly, lack of blood for transfusion apart from autotransfusion and no X-ray control. The procedures performed during the 38 thoracotomies included vascular control, debridements and suture of the lung, lobectomies, and one cardiorrhaphy of the right ventricle: all in all, an “aggressive” approach.

In Afghanistan, the Academy of Medical Sciences of the Afghanistan Armed Forces was the central military referral hospital.<sup>3</sup> Out of a total of 25,000 war-wounded during the three years under study (1981 – 84), 2,873 patients presented with chest wounds, 1,314 of whom had suffered intrathoracic injuries and were admitted to hospital. Blood for transfusion was often in short supply; autotransfusion was frequently used. The criteria

<sup>2</sup> Dumurgier C, et al., 1996.

<sup>3</sup> Roostar L. *Gunshot Chest Injuries*. Tartu, Estonia: Tartu University Press; 1996.

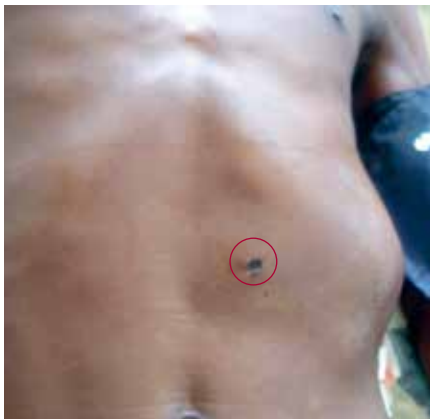for thoracotomy were conservative: exsanguinating or continuing haemorrhage after observation, major air leak, chest wall defect, and evidence of oesophageal injury. The emergency and early thoracotomy rate was 10.5 % (138 cases). Total thoracotomies included 111 late operations for empyema; i.e. 45% of the total thoracotomy rate of 19%. All in all, a “conservative” approach.

#### ICRC EXPERIENCE

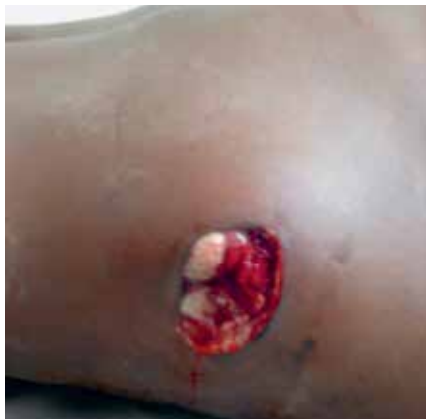In the ICRC context, about 95 % of intrathoracic injuries are adequately treated with tube drainage. The availability of good nursing care and physiotherapy means that the need for late thoracotomy for a retained haemothorax or empyema is relatively rare. Resorting to a thoracotomy requires greater post-operative nursing care and monitoring than simple chest tube drainage – and, in addition, ICRC surgeons are rarely thoracic specialists.

### 31.3.4 Associated injuries

The incidence of concomitant abdominal injuries ranges between 10% and 40% (Table D.1). Penetrating thoracic injuries below the T4 level (nipple line) have a high probability of involving abdominal structures. Apart from wound excision and insertion of chest tubes, overall the most common operation in projectile or blast chest injury is laparotomy. Other associated injuries are also common, varying from 12 to 90% in reported series, but depend largely on the wounding agent: multiple wounds in several body regions are more frequent with fragments.



H. Nasreddine / ICRC



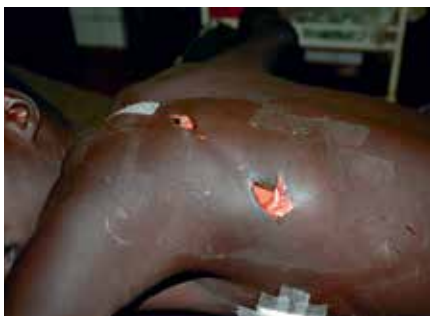H. Nasreddine / ICRC

Figures 31.4.1 and 31.4.2

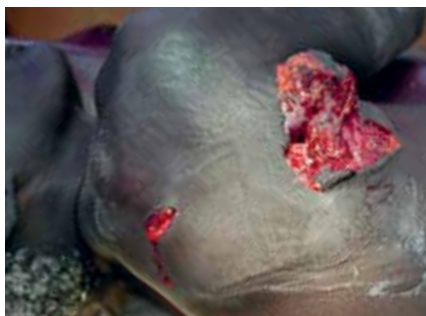
Combined abdominal and thoracic gunshot wound: small entry and large exit.

### 31.3.5 Red Cross Wound Score

Many studies note a large proportion of superficial wounds to the thorax; anywhere between 45 and 65% of chest injuries. It is interesting to note that this phenomenon occurs in urban conflict with short evacuation times as well as during rural guerrilla warfare with delayed evacuation. As mentioned in Sections 4.5 and 5.6.2, not all studies make this distinction between superficial and penetrating wounds, but it is an essential one.



M. Della Torre / ICRC



M. Della Torre / ICRC

Figures 31.5.1 and 31.5.2

Small and large wounds of the chest wall, without penetration of the pleural cavity.

In the Red Cross Wound Score and Classification System penetration of the pleura counts as a vital wound:  $V = T$ . A lesion of the thoracic trachea also qualifies as  $V = T$ , even without penetration of the pleura, although this is rare.

## 31.4 Clinical presentation

The standard procedure of immediate examination according to the ABCDE sequence of trauma resuscitation should be carried out and followed by a complete physical examination.

### 31.4.1 Initial examination

It is important to remember that the chest is directly involved in problems of the airway (intrathoracic trachea), breathing (lung parenchyma, chest wall defect), and circulation (lung, heart and great vessels), as well as neurological deficit through thoracic spinal injury.

Since 90% or more projectile chest wounds can be treated by intercostal tube drainage, the early diagnosis of the other 10% is of extreme importance. These are life-threatening injuries, some of which may require thoracotomy, and can be grouped into urgent, early, and late. Some pathologies overlap the border between urgent and early, depending on the severity of the damage.

#### Most common life-threatening thoracic injuries in armed conflict

##### URGENT

##### Airway

- Injury to intrathoracic trachea or major bronchus with massive air leak.

##### Breathing

- Sucking chest wound/ open pneumothorax.
- Tension pneumothorax.
- Major flail chest with significant pulmonary contusion.

##### Circulation

- Massive haemothorax due to pulmonary lesion.
- Pericardial tamponade.
- Injury to the great vessels of the mediastinum.
- Air embolism.

##### EARLY

##### Airway

- Mild disruption of the tracheobronchial tree.

##### Breathing

- Simple pneumothorax.
- Intrapulmonary haematoma, pulmonary contusion and blast lung.
- Flail chest with pulmonary contusion.

##### Circulation

- Limited haemothorax.
- Myocardial contusion due to blast injury.
- Pseudoaneurysm of great vessels.

##### Other

- Injury to the oesophagus.

**By far the most common late condition is empyema, often complicated by pre-existing malnourishment and anaemia.**

Most patients present with pain on breathing or dyspnoea. Some may be in frank respiratory distress with hypoxia and/or haemoptysis or clear-cut haemorrhagic shock.

A significant intrapulmonary haematoma, contusion of the lung or blast lung can have profound pathophysiological effects. Decreased lung compliance, increased pulmonary vascular resistance and pain all lead to an imbalance between ventilation and perfusion, exacerbating hypoxaemia and causing hypercarbaemia.

A tangential wound more often results in a sucking chest wound with open pneumothorax. If the wound is greater than two-thirds of the tracheal cross-section, air enters the pleural cavity rather than the trachea and effective breathing on that side of the chest essentially stops. An open pneumothorax constitutes a life-threatening emergency and requires preliminary closure on three sides or occlusion by a simple

wet dressing while the patient is taken immediately to theatre (see Section 8.4 and Figure 31.10).

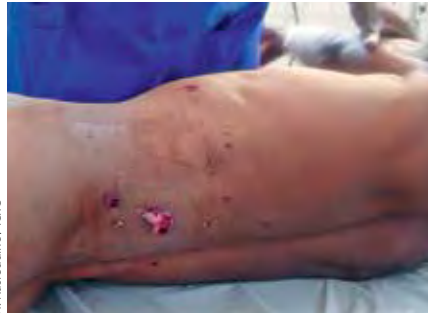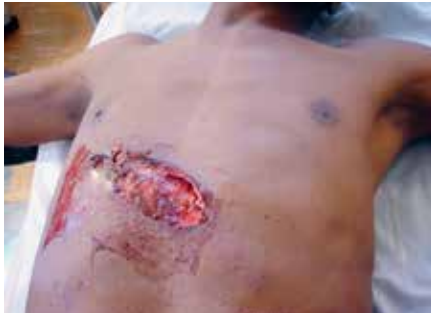A high degree of suspicion of pericardial tamponade is necessary when faced with parasternal wounds or hypotension not commensurate with blood loss or explained by paraplegia. Hypotension, engorged neck veins and muffled heart sounds (Beck's triad) are not universally present; neither is narrowed pulse pressure nor paradoxical decrease of systolic pressure with inspiration. Furthermore, a pericardial tear may not always present as tamponade; the blood may escape into the pleural cavity and present as haemothorax.

The pulmonary veins and main bronchi are in close proximity and a small lesion to both may result in a traumatic bronchopulmonary venous fistula. Although rare, air embolism is a dangerous possibility. This is especially true when the patient is under positive-pressure ventilation with general anaesthesia. Prior to intubation, there may be haemoptysis, a foamy air-blood mixture seen when withdrawing blood for analysis, seizures, or neurological deficit. Under anaesthesia, a sudden haemodynamic collapse may occur.

Embolization of a projectile, more commonly of a small fragment than a bullet, is also rare, but more frequent in the chest than elsewhere in the body because of the large size of the major blood vessels. Vascular embolization can present in strange ways; ischaemia in a lower limb, for example. The surgeon should be aware of this possibility.

### 31.4.2 Complete examination

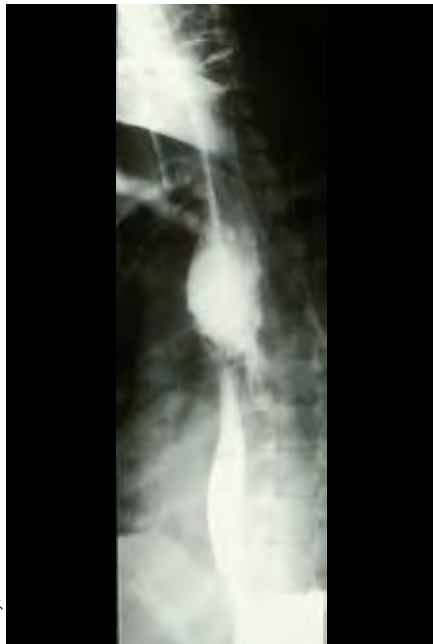As always, proper exposure of the patient for the shortest period possible and complete examination – front and back – are necessary, while protecting the patient from hypothermia. The location of all wounds should be noted. It may be difficult to see a small opening in the folds and body hair of the axilla. Concomitant injury to the abdomen, neck, or an anatomic juncture should be sought out. It should also be remembered that the anterior mediastinal space immediately under the sternum is relatively large and empty, and a projectile may pass through without hitting a major structure.



Figures 31.6.1 and 31.6.2

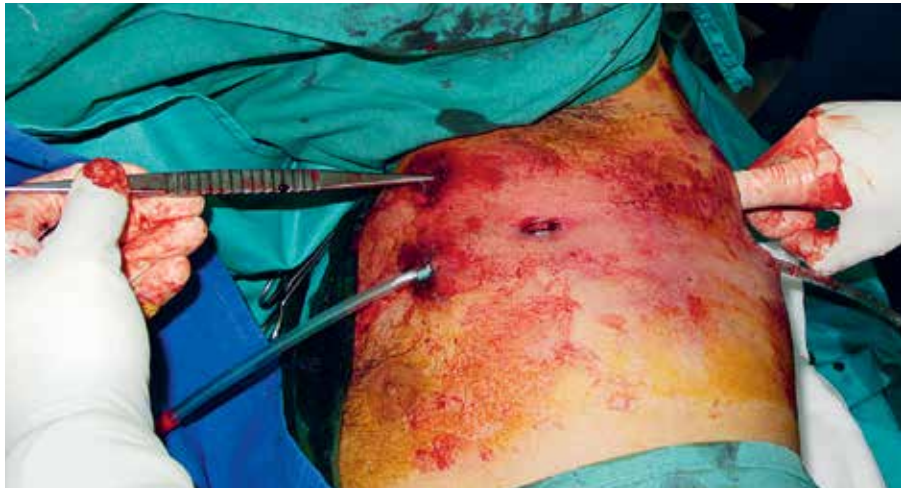Multiple fragment wounds from shelling resulting in a thoraco-abdominal injury: the penetrating wound was in the back.

It is a great mistake to assume that the missile track proceeds along a straight line from the entrance site to the exit site. A bullet arriving at an acute impact angle may be deflected by hitting a rib and travel "around" the chest in the subcutaneous tissues. The entry wound and present location of the projectile make it seem as though there were a through-and-through transfixing wound, but proper palpation will elicit tenderness along the projectile's subcutaneous true trajectory and perhaps the crepitus of a slight degree of surgical emphysema. The same phenomenon has been seen with a bullet hitting the inner surface of a rib and ricocheting around within the chest.



F. Firney / ICRC

**Figure 31.8**  
Barium swallow demonstrating injury to the oesophagus.



H. Nasreddine / ICRC

**Figure 31.7**  
The patient was wounded by two bullets at close range as noted by the tattooing around the entry wounds. The bullets ricocheted off the ribs without penetration of the thoracic cavity. The surgeon demonstrates the superficial character of the wounds. Bilateral chest tubes have been placed prior to proper examination.

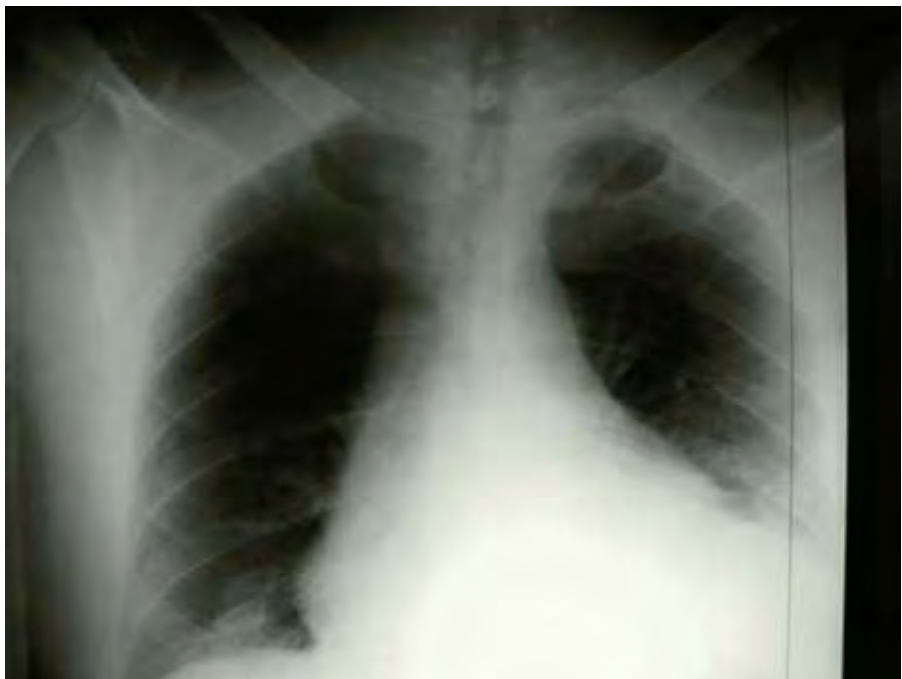Fractures of the ribs, sternum, scapula, or clavicle occur in up to 70% of cases. Slight pressure with both hands on the lateral sides of the rib cage and in the antero-posterior plane (sternum – vertebral compression) is easily and quickly performed.

Suspicion of an oesophageal injury is warranted in a stable patient with a transaxial mediastinal wound. A lesion of the oesophagus may manifest itself by surgical emphysema and crepitus in the neck only. The naso-gastric tube may bring up blood. The methylene blue test or a thin barium swallow may be of help (see Sections 30.5.6 and 31.12) as is oesophagoscopy – if available. A chylous discharge through a chest drain signals an injury to the thoracic duct.

### 31.4.3 Haemothorax and pneumothorax

Technically, all wounds penetrating the pleura create a mixed pneumo-haemothorax; clinically, one predominates. Haemothorax or pneumothorax is present in almost all patients with intrathoracic war injuries.

**Figure 31.9**  
The patient suffered multiple gunshot wounds to the chest, abdomen and left elbow six hours previously. The BP was 140/90 and the pulse 80. The right hemithorax presented one penetrating wound and was hyper-resonant on percussion. The left side showed two penetrating wounds. It was bulging and demonstrated subcutaneous emphysema and a dull note on percussion. A clinical diagnosis of right pneumothorax and left haemothorax was made and confirmed by radiography.



H. Nasreddine / ICRC

Bleeding usually comes from the low-pressure pulmonary system, less often from an intercostal or internal mammary vessel. Lesions to the great vessels or heart are usually fatal before the patient arrives at hospital. In thoraco-abdominal injuries bleeding may be due to an abdominal source.

Continued bleeding via a chest tube may be coming from the abdomen through a tear in the diaphragm.

Less than 10% of patients with penetrating injuries to the chest present pneumothorax alone.

A *simple pneumothorax* is rare with projectile injuries: in such cases the small wound orifice is closed off by the soft tissues of the chest wall, but the result is usually a haemopneumothorax. A simple pneumothorax may require drainage or no intervention at all: the threshold for the placement of a chest tube is a pneumothorax greater than 2 cm on X-ray. The exception is for patients undergoing surgery under general anaesthesia in whom a chest tube should be placed before intubation.

Sometimes, a *tension pneumothorax* develops, but it is more frequent with blast and crush injuries and occurs in less than 3% of stab wounds. As mentioned in Section 8.4, patients with tension pneumothorax may present with respiratory distress or may decompensate over time. The clinical diagnosis is “evident” only in overt decompensation.

An *open pneumothorax* – sucking chest wound – is a more common occurrence.

#### 31.4.4 Paraclinical investigations

X-rays should be taken in the antero-posterior and lateral planes, but should neither delay treatment for a clinically obvious acute condition nor hinder resuscitation. A proper chest X-ray should be taken in the sitting position; up to 1,000 ml of fluid may be present in the pleural cavity and appear only as a haze, especially if the film is taken while the patient is supine. Superposition of a projectile on the normal radio-opaque heart shadow may make diagnosis difficult. Unless the patient has a clinically obvious pericardial tamponade and is *in distress*, second “hard” films of the chest should be taken to distinguish the position of the metallic foreign body.

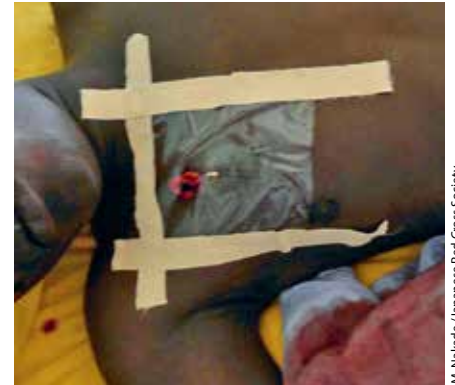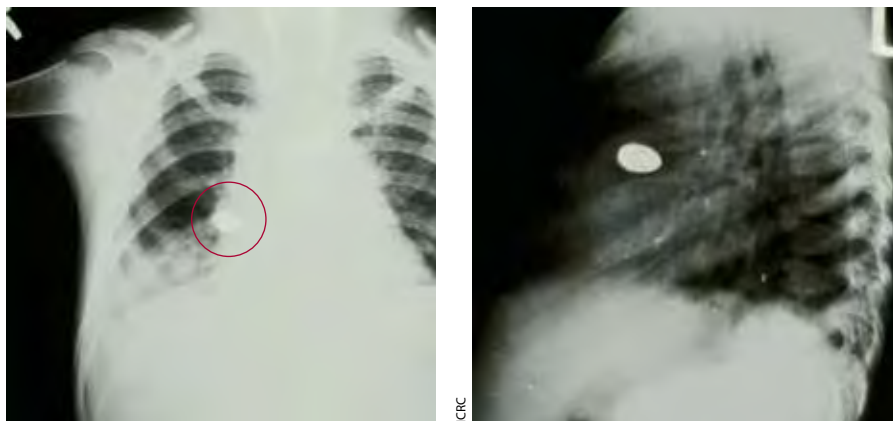


Figure 31.10

Emergency treatment of an open pneumothorax by means of a three-sided closure.

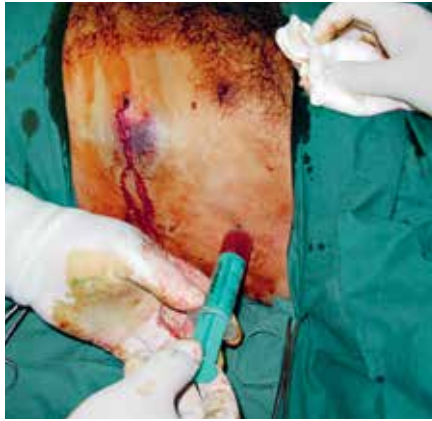Figures 31.11.1 and 31.11.2

Difficult diagnosis: the radio-opaque shadow of the bullet is not easily distinguishable in the A-P view when superimposed on the heart shadow.

It is best to put a radio-opaque object over any entry and exit wounds to help the surgeon “visualize” the possible trajectory of the projectile, while keeping in mind the previously mentioned limitations.

In some countries, the widespread prevalence of pulmonary disease prior to injury can cause confusion on reading the X-ray. The pleural cavity can be obliterated by a pre-existing condition, particularly post-tuberculous adhesions.

Widening of the mediastinum on X-ray may be relevant in blunt trauma, but is of relatively little value in projectile injuries. In a haemodynamically stable patient, the presence of mediastinal air on X-ray calls for investigation of the trachea and oesophagus.



**Figure 31.12**  
Diagnostic thoracocentesis.

Diagnostic thoracocentesis is a simple pleural puncture and aspiration using a plain syringe and needle inserted in the 4th or 5th intercostal space in the midaxillary axillary line. It is a time-proven valuable diagnostic procedure when faced with the triage of mass casualties or in the absence of X-rays or with questionable quality of radiography. Thoracocentesis should be used as a *diagnostic tool only*; it has no part to play in the actual treatment of acute haemothorax. Only a very minor haemothorax, less than 50 ml of aspirated blood in an otherwise asymptomatic patient, may be evacuated in one go and the patient then assigned to conservative treatment. Repeated thoracocentesis even for a very small haemo- or pneumothorax is NOT “safe” and requires much more patient observation than a straightforward chest drain. It usually results in retained clotted haemothorax and empyema. The protocol of ICRC surgeons is to place a chest drain for any haemothorax.

A more modern approach is the surgeon-performed *eFAST* ultrasound (extended Focused Assessment Sonography in Trauma). This is especially useful for detecting blood in the pericardium and pleural cavity, although there are false positives and negatives. It is not used in the practice of ICRC surgeons. Angiography, if available, is of use in haemodynamically stable patients with transaxial wounds.

### 31.5 Emergency room management

The immediate steps that need to be taken depend on the presence of any life-threatening conditions. Their clinical diagnosis and treatment take precedence over X-rays. *Initial radiography is of limited value and tends to waste a great deal of precious time.* The most common injury putting the patient’s life at risk is a massive haemothorax, which should be diagnosed clinically and a chest tube placed as an emergency procedure.

Whenever there are clinical signs of massive haemothorax or tension pneumothorax, treatment precedes X-rays.

Acute tension pneumothorax is an extreme emergency. Once the diagnosis is made a needle thoracocentesis is performed in the second intercostal space at the midclavicular line. A cannula long enough to penetrate the chest wall is necessary; body fat, musculature, subcutaneous emphysema, and chest wall haematoma may all influence the thickness of the chest wall.

Failure of needle thoracocentesis does not rule out the diagnosis; it only means that the attempt to relieve the condition has failed. If successful, an audible whoosh of expelled air is heard. The cannula should be attached to a one-way Heimlich-type valve, manufactured or improvised (Figure 8.3). If thoracocentesis fails, a thoracostomy (cutting into the chest wall as if to insert a chest tube) in the mid-axillary line may be performed *in extremis*, turning the tension pneumothorax into an open pneumothorax. In all instances, needle thoracocentesis or thoracostomy is only a prelude to the insertion of a chest drain.

The equipment necessary for chest tube insertion is relatively limited and simple. The operation may be performed in the emergency department or in the operating theatre, depending on the capacity and circumstances of the hospital ER, the urgency of the case, and the availability of the theatre. In general, when working with limited resources it is best to perform the procedure in the operating theatre. All the necessary equipment is available there in case of complications, and so is the anaesthetist. In addition, considerations of security all too often argue in favour of taking the patient to the OT, away from the ER where excited and armed people tend to converge, making work there difficult if not impossible (see Section 9.3). Mass casualty triage, when there is a need to keep the OT free for major operations, constitutes a special situation. The specific circumstances at the hospital determine the best solution.

If the conditions in the ER make chest tube insertion difficult, they will be even worse for an emergency room thoracotomy (ERT) as described in Section 31.7.1.



Proper circulatory resuscitation should be instituted. In case of a massive haemothorax, hypotensive resuscitation should be seriously considered (see Section 8.5.4) and an autotransfusion set-up promptly installed (see Section 34.5.1).

As always, adequate oxygenation, analgesia, antibiotics according to protocol, and anti-tetanus measures should be administered to all patients suffering from thoracic trauma. They require close observation and monitoring; deterioration can occur quickly.

## 31.6 Intercostal chest tube drainage<sup>4</sup>

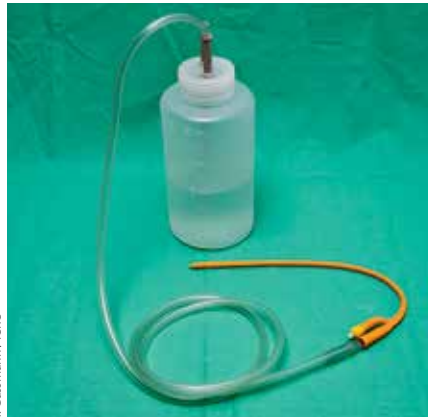The equipment necessary for chest tube placement is rather simple. Ready-made manufactured items are usually available; alternatives can readily be improvised.



T. Gassmann / ICRC

**Figure 31.13.1**

Essential equipment: commercially manufactured chest drainage system.



T. Gassmann / ICRC

**Figure 31.13.2**

Essential equipment: improvised chest tube using a Foley catheter and re-sterilizable plastic bottle with underwater seal of sterile normal saline.



E. Erichsen / Alra Hospital, Ethiopia

**Figure 31.13.3**

Essential equipment: improvised two-bottle drainage system.

### 31.6.1 Indications and basic principles

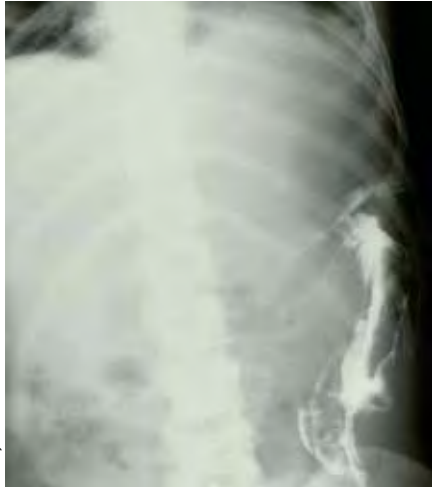#### Indications for intercostal chest tube drainage:

- all detected haemothoraces;
- tension pneumothorax;
- simple pneumothorax greater than 2 cm on X-ray;
- any pneumothorax and the patient requires intubation and ventilation;
- bronchopleural fistula;
- blast lung: bilateral chest tubes;
- signs of chest penetration in a patient during a mass casualty situation when adequate examination or X-ray is not possible;
- as part of thoracic operation;
- empyema.

"When in doubt, drain it out." Chest tubes should be inserted as soon as possible.

Haemothorax is by far the most common condition necessitating a chest tube as the sole surgical procedure.

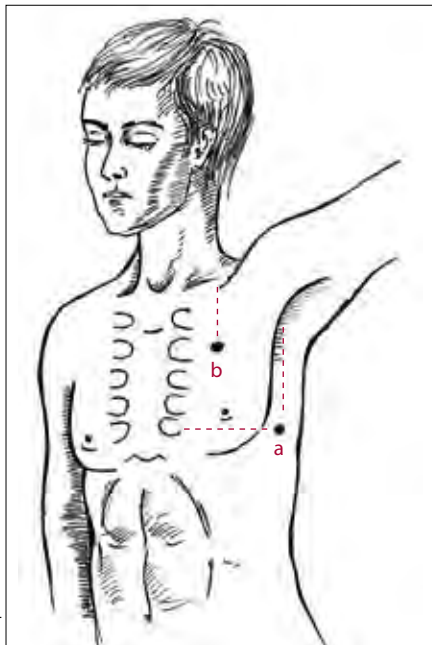
<sup>4</sup> The ICRC protocols for the management of intercostal chest tubes were updated by the Second ICRC Master Surgeons Workshop, Geneva, December 2010.



F. Irnay / ICRC

**Figure 31.14**

Perforation of the diaphragm by a chest tube mounted on a trocar and diagnosis by injection of radio-opaque material.



N. Papas / ICRC

**Figure 31.15**

Two sites for chest tube insertion:  
a. the preferred midaxillary (basal), and  
b. the midclavicular (apical).

Several simple measures should be taken in order to ensure the safe insertion of a chest tube and the effective decompression of a haemothorax or pneumothorax.

- Sterile technique must be respected, even in this “relatively” minor operation.
- Large-calibre tubes should be used to enable blood to be drained quickly, particularly if a suction apparatus is not available.
- A chest drain should never pass through a wound. The wound should be excised and the drain placed elsewhere.
- Chest tubes are usually inserted under local anaesthesia (see Annex 31.A), but when there is a large wound to excise or another operation to perform ketamine is more appropriate. However, chest tubes should be inserted *before* intubation of the patient.
- Trocar-mounted chest tubes should not be used; the trocar should be thrown away and the open technique adopted at all times.

A chest tube mounted on a trocar is a “dangerous weapon”.

There are numerous examples in the surgical literature of chest tubes placed with a trocar that have penetrated the lung, mediastinum, heart and great vessels, or an abdominal organ herniated into the chest; or that traversed the diaphragm and punctured the spleen, stomach, or liver. The ICRC does not distribute chest tubes mounted on a trocar.

Two sites are classically used for the insertion of a chest tube: midaxillary (basal) and midclavicular (apical) as shown in Figure 31.15. The vast majority are inserted in the midaxillary position. A large air leak may require a second chest drain in the apical position. However, the apical position presents more risks than the basal and should only be resorted to for this condition.

Insertion and the protocol for removal of a chest tube are described in Annex 31.B.

### 31.6.2 Chest tube drainage and autotransfusion

Blood in the thoracic cavity rarely clots unless the haemothorax is so large that the lung is completely collapsed and thus unable to defibrinogenate the blood by its movements.

If the clinical picture of the patient points to a massive haemothorax with shock, autotransfusion of the shed blood should be resorted to. Rather than “remove and waste” the blood coming through the chest tube, it should be recuperated. Therefore, normal saline should be put into the chest bottle and not ordinary water which is hypotonic and results in haemolysis. Details of autotransfusion techniques are given in Section 34.5.1.

### 31.6.3 Post-operative care of chest tube drainage

#### Elementary measures for *all* patients with thoracic injury

- The head of the bed is raised and the patient placed semi-sitting.
- Supplemental oxygen must be humidified.
- Pain is relieved by repeated intercostal nerve blocks and strong analgesics that do not depress respiration (e.g. tramadol).
- Physiotherapy is essential: deep-breathing exercises, voluntary coughing, inflating a balloon, or blowing through a straw into a bottle of water. A trained physiotherapist should be present; if not, the surgeon and nursing staff must make certain the patient performs the exercises properly.
- Secretions are eliminated by frequent bronchial toilet through physiotherapy and mucolytics and nebulized bronchodilators if indicated – heavy smokers, patients suffering asthma or bronchiectasis, etc.
- Tracheostomy is performed in severely-injured patients should breathing become overly difficult to help remove secretions and decrease dead space, especially in the absence of mechanical ventilation.

#### Functioning of the chest tube

The functioning of a chest tube must be checked immediately. The bloody discharge inside the drain and the fluid level in the underwater seal tubing should swing with each breath. If this is not the case, the tube should be inspected to confirm that there has been no dislodgement from the chest wall exposing a side-hole. Or, if the drain is blocked, it can be flushed with 50 ml of normal saline. If this does not work, the chest tube should be withdrawn and replaced.

A chest X-ray soon after inserting the drain is valuable to confirm the following points.

1. Proper positioning – the tube can easily be misplaced inside a pulmonary fissure, or through a laceration into the lung, or even be extra-pleural in the subcutaneous tissues.
2. No kinking of the chest tube.
3. Full re-expansion of the lung with complete evacuation of blood and air from the pleural cavity.

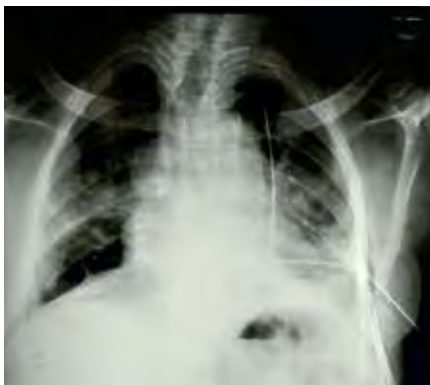

Figure 31.16

Patient X: kinking of the chest tube compromising function.

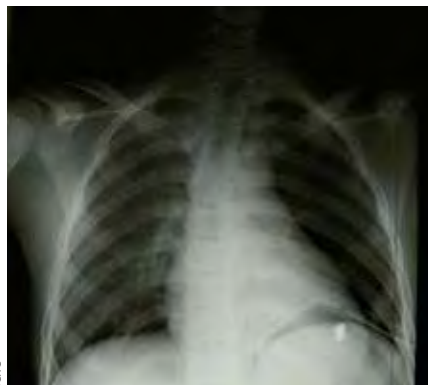

Figure 31.17

Patient Y: kinked chest tube, but functioning well.

If these criteria are not fulfilled, further measures are necessary.

1. The drain should be changed or repositioned – however, if the drain is functioning correctly, its exact position on X-ray is of little consequence.
2. The efficiency of suction should be checked if this is being used.
3. A second apical chest drain may be required, especially if there is significant continuing air leakage.
4. A thoracotomy may be necessary if all the above fail to deal directly with the underlying cause.

Once the functioning of the chest tube has been confirmed, proper positioning of the patient, good analgesia and vigorous post-operative physiotherapy are essential for a chest tube to work correctly.

### Observations

The tubing connections and fixation and clinical condition of the patient should be checked hourly after first placement of the chest drain and then every four hours once the patient's condition has stabilized.

Observations should include:

- the functioning of the drain;
- any bubbling of air;
- amount and nature of the drainage discharge;
- respiratory rate, pulse and blood pressure;
- O<sub>2</sub> saturation by pulse oximetry.

A subjective assessment should also be recorded of the patient's:

- mental state;
- comfort of respiration;
- strength of cough; and
- pain score: verbal, numeric, or visual analogue representation (see Section 17.5.2).

Daily control X-rays are not absolutely necessary; good clinical examination of the patient is.

### Care of the chest bottle

When the patient is moved or mobilized, care must be taken to make sure the drainage system remains below the level of the chest tube. If it is absolutely necessary to raise it above this level, the tubing should be clamped *very briefly*. Similarly, clamping is necessary when changing an overfull chest bottle. If after clamping the patient becomes dyspnoeic the clamp should immediately be removed. The plastic tubing should not be clasped directly by the clamp, but rather protected by the interposition of a gauze compress.

Never leave a patient unattended while the chest tube is clamped.

### Antibiotics

It used to be the practice of ICRC surgical teams to continue the administration of oral antibiotics for 48 hours after drain removal to cover any residual collection or intrapulmonary haematoma. This usually resulted in a total antibiotic administration of 4 – 5 days. The updated ICRC protocol is to administer antibiotics to all patients for a standard five days, in order to simplify nursing care.

### Removal of a chest tube

A chest tube should be removed once it has accomplished its task: i.e. the lung has re-expanded and there is no active haemorrhage or air leak. In the vast majority of patients with a haemothorax this means two to three days. An air leak that slowly decreases and does not require a thoracotomy takes about a week to close.

A common occurrence with a chest tube in place after a couple of days is the discharge of clear serous fluid. This is a foreign body reaction to the presence of the tube and will continue as long as it is in place. The chest drainage can be removed when the serous discharge falls below 250 ml per day.

Details for chest tube removal are to be found in Annex 31.B.c.

### 31.6.4 Complications

Although a “relatively simple and minor” operation, especially when compared to a thoracotomy, chest tube drainage like any other surgical procedure is not entirely free of complications. These may be of several different sorts.

- Insertional, i.e. faulty insertion technique leading to:
  - laceration of the lung or other organ;
  - haemorrhage due to injury of the intercostal vessels;
  - exposed side-holes;
  - extrapleural placement in the subcutaneous tissues.
- Positional:
  - kinking;
  - within a lung fissure;
  - within a laceration of the lung;
  - subsequent dislodgement of the drain with exposed side-holes.
- Functional:
  - clotted blood in the tube with persistent haemothorax or pneumothorax.
- Post-removal:
  - criteria for removal were not met and the pathology persists;
  - pneumothorax while closing the thoracostomy incision due to faulty technique.
- Infective:
  - minor, i.e. drain site infection;
  - major, i.e. empyema thoracis.

Some of these complications are readily remedied by replacing or repositioning the tube, some require a second tube; others may require further surgery and a thoracotomy.

## 31.7 Thoracotomy

Transport logistics and security constraints surrounding casualty evacuation usually mean that thoracotomy is required for less than 5 – 10% of the patients because “natural triage” has already occurred. Warfare within urban areas may allow rapid transport of severely injured patients and therefore lead to a higher rate of thoracotomy. However, the principles of mass casualty triage frequently intervene as well, thus limiting the possibility of performing a thoracotomy. Nonetheless, the basics of this procedure should be understood. For the surgeon working with limited resources the choice may be between letting a patient die without intervention, or doing the best one can given the prevailing circumstances.

The experience and technical skill of the surgeon and the hospital’s personnel determine the appropriate degree of “aggressiveness” when deciding on whether and how to operate. This should not mean resorting to poor surgical technique in an attempt to be “heroic”. Sometimes, it is best to let nature takes its course, as is done with the supportive treatment of Category IV triage patients.

Thoracotomy can be an urgent procedure performed as part of resuscitation, an early operation performed after the physiology has been partly restored, or a late surgical intervention usually due to a complication.

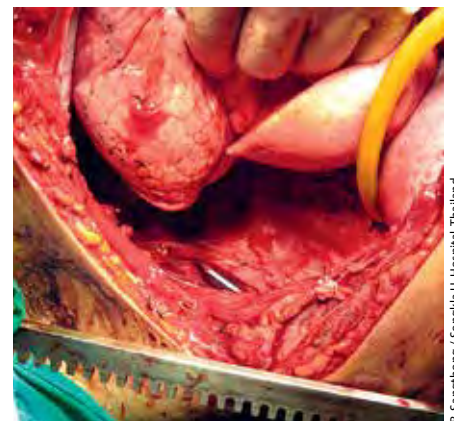


Figure 31.18

Placement of a chest tube in the soft tissues of the thoracic wall diagnosed at thoracotomy.

### 31.7.1 Emergency room thoracotomy

Emergency room thoracotomy (ERT) is a desperate resuscitative procedure for patients *in extremis* owing to exsanguinating haemorrhage or suspected cardiac tamponade resulting in cardiac arrest. The practice of a thoracotomy in the ER rather than the OT may be considered in a referral trauma centre – although even there the results are generally poor, leading to controversy about its usefulness. Furthermore, the use of sharp instruments in a hurried fashion with splashing of the patient's blood in an uncontrolled manner may transfer communicable diseases to emergency room personnel (HIV, hepatitis B and C). This in itself strongly argues in favour of thoracotomy being performed only in the OT.

Any controversy is largely irrelevant to the general surgeon working with limited resources; under such conditions it is a futile exercise. Better to bring the patient to the operating theatre and, if still alive, with good lighting and instruments and trained personnel, make an attempt at emergency resuscitative thoracotomy there.

### 31.7.2 Indications for urgent thoracotomy

#### Indications for urgent thoracotomy in the operating theatre

1. Open pneumothorax of a sucking chest wound.
2. Exsanguinating haemorrhage.
3. Haemopericardium with cardiac tamponade.
4. Massive air leak.

A sucking chest wound can be brought under control in the emergency department, even if only with a large wet dressing, and the patient taken to theatre immediately. The wound itself is the equivalent of a "traumatic mini-thoracotomy". A small wound does not really require a formal thoracotomy, rather debridement with closure of the chest wall and placement of a chest drain.

Operating for exsanguinating haemorrhage should be attempted only if provision has been made for autotransfusion and there is at least a minimal blood bank supply ready for transfusion. The source of haemorrhage is usually an artery of the chest wall, occasionally a great vessel.

A special case is a right-sided exsanguinating thoraco-abdominal wound with dark blood coming from the chest tube. Exploratory laparotomy reveals a retrohepatic venous injury and blood passing through a hole in the diaphragm. The liver should *not be mobilized*. Rather, the hole should be plugged and liver packed to keep it in its anatomic position. A thoracotomy should then be performed and large haemostatic sutures placed to close the hole in the diaphragm from above to allow natural tamponade to occur.

Much can be done for pericardial tamponade, provided early diagnosis is made. A massive air leak due to a major tracheobronchial injury, with collapsed lung on X-ray and continuous bubbling of air throughout the breathing cycle, requires immediate operation as well. The results depend on the exact level of the injury.

The patient must show signs of life for a thoracotomy to be considered. In the absence of EEG, retained pupillary reaction is a good indicator for operating in emergency cases.

### 31.7.3 Indications for early thoracotomy

#### Indications for early thoracotomy

1. Continued bleeding.
2. Persistent significant air leak.
3. Massive or increasing intrapulmonary haematoma.
4. Mediastinal injury: oesophagus, trachea and great vessels.
5. Foreign body: large and in a “delicate” location.

The indications for early thoracotomy, less than 24 – 48 hours after injury, are more commonly met. Most often encountered is continuing haemorrhage, followed by persistent significant air leakage.

#### Continued bleeding

In the practice of ICRC surgeons this applies to cases arriving shortly after injury, with more than 1,500 ml blood discharge at the time of insertion of the chest drain,

- and 500 ml in the first hour;
- or 200 – 300 ml/hour for 2 – 3 hours afterwards.<sup>5</sup>

Autotransfusion of the haemothorax gives the patient a chance of haemodynamic stabilization and readily permits this period of observation.

This bleeding must indeed be coming from a thoracic wound and not from the abdomen through a lesion in the diaphragm. Blood loss through the chest drain, however, is not always a reliable indicator of the total loss; much clotted blood can remain in the pleural cavity if the lung has completely collapsed.

After the initial rush of blood, bleeding may cease. Haemorrhage from the intercostal vessels or the low-pressure pulmonary system, even if causing an initial massive haemothorax, often stops. Obviously, the surgeon cannot make this diagnosis *a priori*: this is the reason for waiting one or two hours before committing the patient to surgery.

An old method to determine continuing haemorrhage is the Ruvilua-Grégoire test. If discharged blood coagulates, the bleeding is ongoing; the fresh blood has not had time to be defibrinogenated by the movement of the lung. If the blood stays fluid, the bleeding has stopped, since the blood draining out has been defibrinogenated. It should be mentioned that the colour of the blood is a poor indicator of ongoing haemorrhage.

In a situation where blood for transfusion is in short supply and the surgeon is experienced, some surgeons have argued for an aggressive approach and very early thoracotomy to control bleeding quickly and not let the patient slowly exsanguinate (the Chadian experience described in Section 31.3.3). The capacity for autotransfusion often determines whether there is “enough blood” to allow observation of the patient before making the decision to perform a thoracotomy.

#### Persistent pleural air leak

Thoracotomy should only be considered in the presence of continuing and significant leakage of air over a period of 24 – 48 hours, with no sign of diminishing.

#### Intrapulmonary haematoma

Clinical evidence of respiratory distress with an intrapulmonary haematoma larger than 5 cm in diameter on X-ray or increasing in size on serial X-rays is an indication for thoracotomy. Given the additional risk of infection in a large haematoma, a thoracotomy is justified. In the event of a lung abscess, however, massive antibiotic therapy without thoracotomy is the treatment of choice.

<sup>5</sup> In children, the initial volume is calculated as 15 – 20 ml/kg and, for ongoing haemorrhage, 2 – 4 ml/kg.

### Mediastinal injury

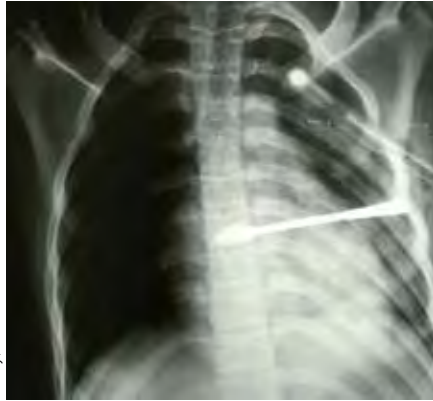Injury to mediastinal structures is often problematic, especially with a transaxial wound of the chest. In a haemodynamically stable patient, the presence of dyspnoea, surgical emphysema or mediastinal air on X-ray calls for investigation of the oesophagus and trachea. The patient can usually withstand a few hours delay for proper resuscitation and diagnosis.

Most patients with injury to the great vessels who arrive at the hospital alive have come through “natural, automatic triage”. They usually have suffered a relatively “minor” injury leading to a pseudoaneurysm of a major vessel. Time is well spent stabilizing the patient, performing further diagnostic tests, and making the proper preparations for thoracotomy. Furthermore and as mentioned above, the retrosternal anterior mediastinum is an “empty space” and projectiles may traverse it without hitting any important structures.

### Foreign body

A very large and especially jagged fragment retained in the pleural cavity, lung parenchyma or lying on a great vessel in the mediastinum, or exceptionally a projectile embolus in the heart, carries extraordinary risks. The possibility of infection or erosion of a vessel provoking haemorrhage or embolization may be great enough to warrant a thoracotomy to remove the projectile.

The criteria, medical on the one hand and related to the surgeon on the other, have been discussed in Chapter 14. Again, once the patient is stabilized, after 24 – 48 hours, thoracotomy under controlled and calm circumstances may be envisaged.



E. Firmy / CRC

**Figure 31.19**

A foreign body – spear tip – requiring thoracotomy and removal.

### 31.7.4 Indications for late thoracotomy

**Thoracotomy is also indicated in the following cases**

1. Clotted haemothorax/clot retention.
2. Empyema thoracis.

#### Clotted haemothorax

Only the very small retained haemothorax reaching less than the 7th rib on an upright X-ray may be treated conservatively. If greater than this, a thoracotomy for evacuation of the retained clot should be performed within 5 – 7 days.

#### Empyema

Infection is a complication that should not occur, but all too often does. It is most frequently seen in neglected injuries with long evacuation times, but also occurs following inadequate analgesia and physiotherapy with subsequent failure to fully expand the lung and drain a haemothorax.

### 31.7.5 Patient preparation, positioning, and anaesthesia

For an exploratory thoracotomy, the patient is placed in the supine position with both arms abducted. In urgent cases a strict minimum of preparation is sufficient; i.e. quick swabbing with disinfectant. Otherwise, the area from the neck to the symphysis pubis is prepared in case a laparotomy is required. For oesophageal injuries, clotted haemothorax and empyema, the patient is put in the lateral position with the arm raised on a stirrup.

**Chest tubes should be inserted before intubation to avoid iatrogenic tension pneumothorax.**



In an unstable patient, rapid intubation with a single-lumen endotracheal tube should be the standard. The insertion of a double-lumen tube that permits the injured lung to be excluded from ventilation is not recommended, even if available. It takes more time to place and requires more experience on the part of the anaesthetist. It can only be considered in planned thoracotomies. Ketamine anaesthesia with muscle relaxation is perfectly adequate.

Caution must be exercised in the administration of positive pressure with penetrating lung trauma. If a bronchus and large pulmonary vein are disrupted and in communication, air embolism is possible if the pressure in the airway exceeds the pressure in the vein.

Permissive hypotension of 90 mm Hg and autotransfusion should be standard procedures in urgent cases. For early and delayed thoracotomies, blood for transfusion should be prepared in advance of the operation; its availability often decides the case.

### 31.7.6 Choice of incision

A correct choice of incision is necessary for a successful thoracotomy. In an exploratory thoracotomy, an *anterolateral incision* on the injured side should be made in the fourth or fifth intercostal space, going as far posteriorly as possible with the patient in the supine position.

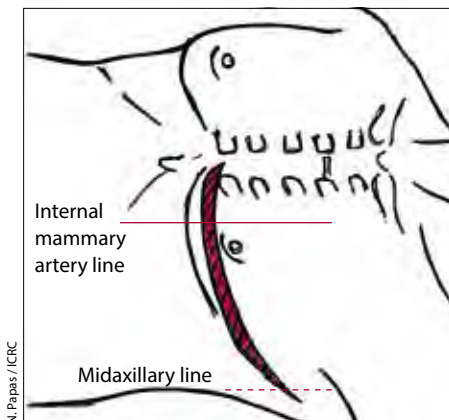


Figure 31.20  
Anterolateral incision.

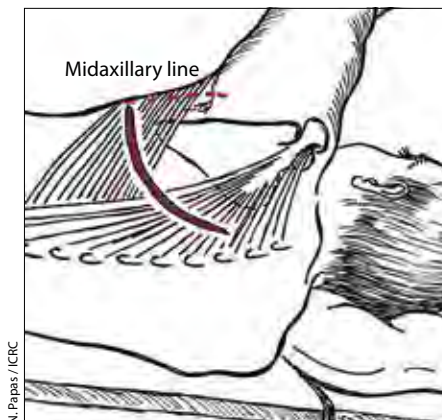


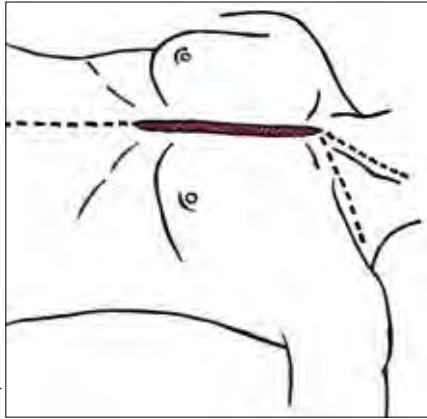
Figure 31.21.1  
Posterolateral incision.

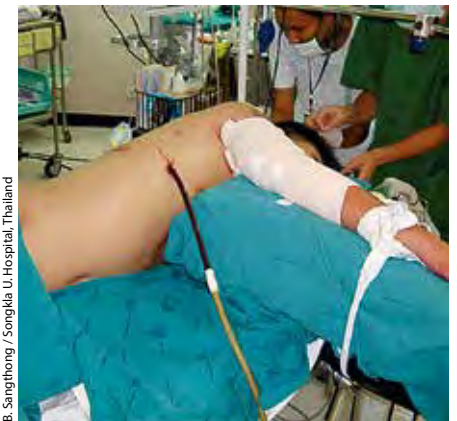

Figure 31.21.2  
Lateral position for a posterolateral thoracotomy.

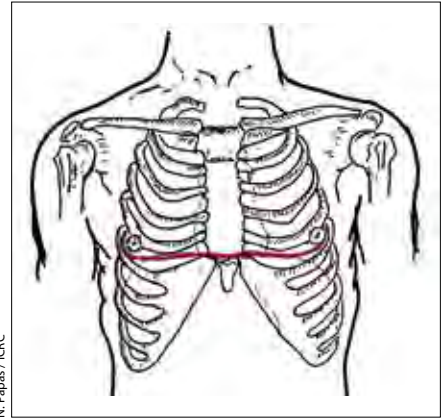
Lesions of the descending aorta and oesophagus and more rarely the main bronchus require a *posterolateral incision* for access to the posterior mediastinum. If an emergency thoracotomy has been performed through an anterolateral incision, the patient may need to be repositioned for a posterolateral approach. The posterior approach is also best for a retained clotted haemothorax and for empyema.

Other possible incisions include a *median sternotomy* and the bilateral "*clam-shell*" incision. The latter is a last-resort incision and amounts to performing bilateral anterolateral incisions connected by sawing through the sternum. The chest is then opened up, giving excellent access to the heart and major vessels. It is quicker and easier to perform than the median sternotomy and is particularly useful for the exploration of a transfixing mediastinal injury in an unstable patient. However, most patients require mechanical ventilation afterwards.



N. Papas / ICRC

**Figure 31.22**  
Median sternotomy with possible extension as a laparotomy, into the neck as an SCM incision, or as a supraclavicular incision.



N. Papas / ICRC

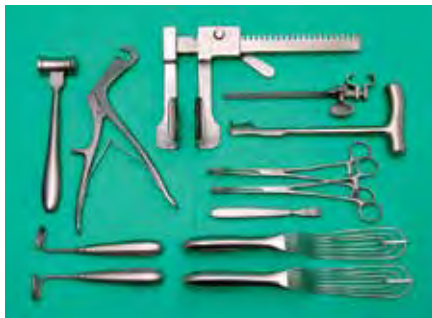**Figure 31.23**  
Clamshell incision: bilateral anterolateral incisions joined across the sternum.

The operative details of the different incisions available for thoracic trauma are to be found in Annex 31.C.

### 31.8 Exploration of the chest cavity

Once the chest cavity has been entered a Finochietto rib retractor is inserted; two wide and long laparotomy retractors can be used if a Finochietto is not available. The inflated and moving lung makes exploration difficult. The anaesthetist can cease ventilation momentarily; or the surgeon can help guide the endotracheal tube into the contralateral bronchus thus achieving selective ventilation without the use of a double-lumen tube.

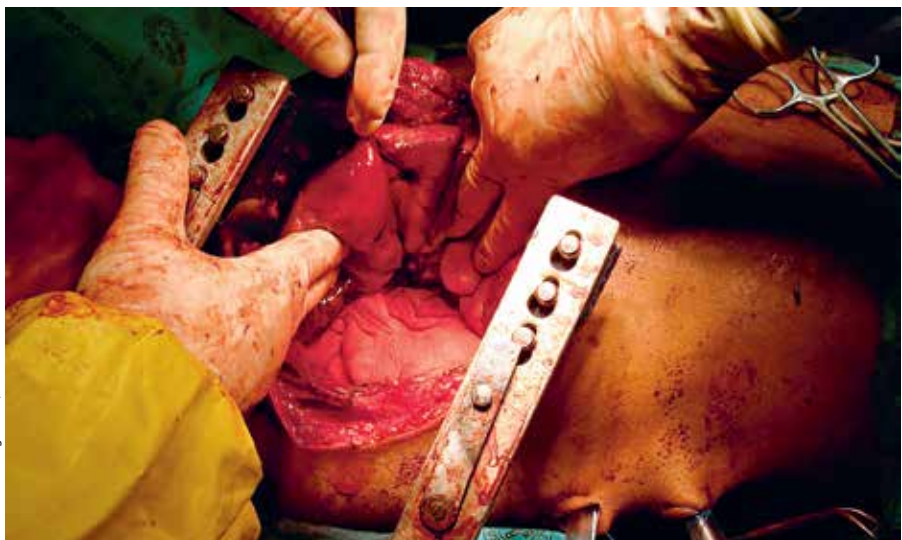
To visualize the mediastinum and posterior chest, the lung must be mobilized. It can be grasped and pulled upwards, stretching the inferior pulmonary ligament, which is then carefully cut with scissors. The inferior pulmonary vein lies at its reflection.



T. Gassmann / ICRC

**Figure 31.24**  
Basic essential equipment: thoracotomy set.

**Figure 31.25**  
Exploration of the chest cavity: visualization of the mediastinum.



F. Plani / CH, Baragwanath, S. Africa

Blood is evacuated quickly by scooping it out and temporary control of bleeding achieved by manual pressure squeezing the hilum in one hand (thoracic Pringle manoeuvre), the "hilum-twist" (see Section 31.10.1) or packing. Care must be exercised to locate any bleeders from the chest wall; they may be posterior or distant from the exploratory thoracotomy incision and difficult to see.

Inspection then proceeds.

## 31.9 Wounds of the chest wall

Entrance and exit wounds should be excised removing all devitalized tissue.

Intercostal vascular bleeding should be handled by ligation. Occasionally, a vessel may be difficult to access and a new incision may be necessary to gain control. A cut intercostal artery can retract into the muscles and require a figure-of-eight haemostatic suture: the needle is passed parallel to the ribs, not perpendicular, as there is not enough room to manoeuvre in the intercostal space. Removing a segment from an adjoining rib also helps to gain space.

The internal mammary artery is relatively easy to clamp and ligate proximally and distally because of its superficial anterior position.

A sucking chest wound requires a mini-thoracotomy *through the wound*. The standard principles apply: the soft tissues are debrided; rib fragments are removed from the lung if present and jagged edges of fractured ribs nibbled with a rongeur or filed smooth. After pleural toilet, a chest tube is placed through a *separate fresh incision*. The pleura and the deep muscle layer are closed together to ensure an airtight seal as for the closure of a thoracotomy incision. However, the injured outer muscle layers and skin are left open for delayed primary closure on the fifth day. In effect, they constitute a dirty and contaminated wound, whilst a thoracotomy is a clean incision.

It may not be possible to close a very large defect. Temporary closure by the “Bogotá bag” technique as used in the abdomen (see Section 32.9.1) may be resorted to in order to reconstitute a functional pleural cavity. A continuous interlocking suture joins the plastic bag to the edge of the pleura and first layer of intercostal muscles and covered with an adhesive for an effective seal, if available (Steri-Drape®, Opsite®).

Reconstruction of the defect is then performed as a planned procedure once the condition of the patient has stabilized. This may involve a myocutaneous rotation flap of the latissimus dorsi, pectoralis major, or even the rectus abdominis depending on the location of the defect.

## 31.10 Injuries of the lung

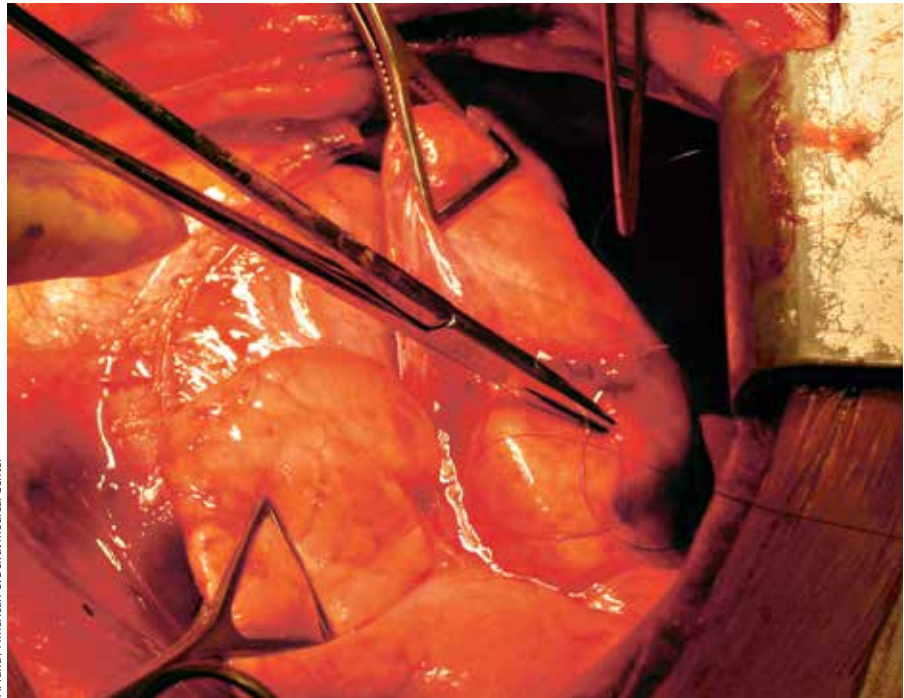
### 31.10.1 Haemostasis of the lung parenchyma

It is best if the anaesthetist momentarily stops ventilation, or the surgeon manipulates the endotracheal tube into the contralateral bronchus, allowing the lung to be deflated while the surgeon deals with the damage. There are several methods of surgical haemostasis of the injured lung depending on the extent of tissue damage.

#### Direct suture

Small lesions of the margins of the lung may be directly oversewn with hepatic-type mattress sutures: pneumonorrhaphy.

**Figure 31.26**  
Suture of a pulmonary laceration.

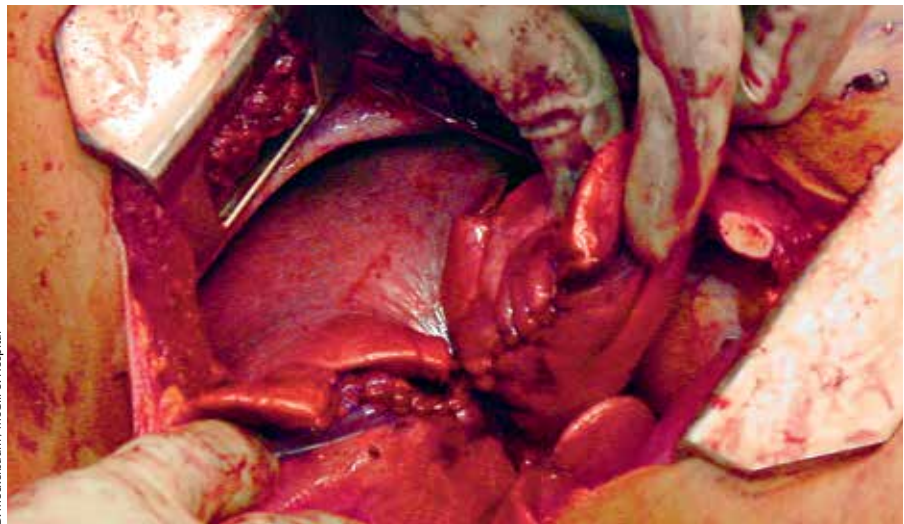


A. Taha / American U. Beirut Medical Center

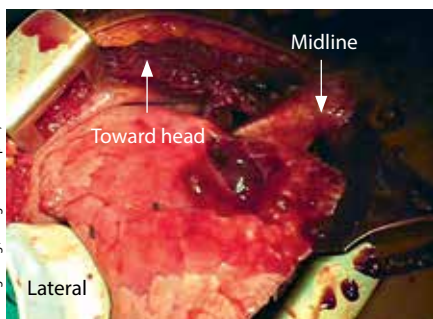
**Non-anatomic wedge resection**

Larger wounds are best clamped with Duval lung clamps, large vascular clamps, or non-crushing intestinal clamps and the isolated wedge resected in a “V” fashion. The edges are then oversewn with a 3/0 continuous synthetic absorbable suture.

**Figure 31.27**  
Wedge-resection and suture of the lung.



D. Meckelbaum / McGill U. Hospital



B. Sangthong / Songkla U. Hospital, Thailand

**Figure 31.28**  
Large entry wound of a transfixing injury of right the lung.

**Tractotomy: debridement and selective haemostasis of the wound tract**

Entry and exit wounds pouring blood, especially from deep through-and-through injuries, should *not* be sutured closed. This does not control the bleeding; it simply allows accumulation of an intrapulmonary haematoma and spill-over of blood into the rest of the tracheobronchial tree. It may also increase the risk of air embolism through a broncho-venous fistula.

Tractotomy, an adaptation to the lung of the hepatic finger-fracture technique, is the procedure of choice. Two long aortic or non-crushing intestinal clamps are inserted in the wound tract and closed. The bridge of tissue between them is then divided by scalpel and the lung tissue is debrided if necessary. Any bleeding points or air leaks are controlled by selective figure-of-eight sutures. The lung tissue in the clamps is then oversewn with a continuous mattress suture of 3/0 synthetic absorbable material, the clamps removed, and the cut edges of the lung reinforced with another simple continuous suture. The edges are not approximated; rather the tractotomy is left open. Stapling devices for wedge resection and tractotomy make the surgery easier, but are rarely available.

### Damage control and lobectomy or pneumonectomy

If there is massive bleeding or air leakage from a central cavity in the lung, it is better to perform a “thoracic Pringle manoeuvre” first, pinching the hilum between the fingers to stop haemorrhage and prevent air embolism before attempting to cross-clamp the hilum.

A simple “damage-control” technique is the “pulmonary hilum twist”.<sup>6</sup> The lung is grasped in both hands and pulled laterally and posteriorly. The stretched inferior pulmonary ligament is divided up to the inferior pulmonary vein. One hand is then placed over the lung apex and the other under the lower lobe, which is swung up rotating the entire lung 180° so that the lower lobe points up. This effectively twists the pulmonary artery and veins around the relatively rigid bronchus. Laparotomy packs are then placed to prevent the twist from unravelling. The physiological status of the patient is the same as after a pneumonectomy. Once the patient has been stabilized, the twist can be undone and repair performed or, if the damage is too great, the hilum is clamped and the lung removed.

Lesions so large that they require lobectomy or pneumonectomy to control haemorrhage or air leakage are very rare in patients reaching hospital and have an exceedingly high mortality rate in those that do.

### 31.10.2 Intrapulmonary haematoma, blast lung, lung contusion and flail chest

Most intrapulmonary haematomas from penetrating projectiles are small and self-contained and usually resolve by draining into a haemothorax, haemoptysis, or slow absorption. Only an intrapulmonary haematoma larger than 5 cm in diameter on X-ray or increasing in size on serial X-rays should be treated by thoracotomy and evacuation.

Pulmonary contusion following blunt trauma and blast lung usually progress for 2 – 3 days and resolve slowly. Most patients can be managed conservatively without a respirator. A severe lesion may progress to ARDS and the resultant respiratory failure can be subtle and develop over time. ARDS requires mechanical ventilation, which is not always available and conservative measures must suffice. One temporizing alternative is a tracheostomy and short periods of alternating bag and spontaneous ventilation.

Conservative treatment is essentially the same as routine post-operative care for a chest tube or thoracotomy with one added provision because of the risk of pulmonary oedema. The patient should be kept euvolaemic but “on the dry side”, with slight restriction of fluids once haemodynamically stabilized. Diuretics are administered *only* if pulmonary oedema supervenes.

The use of corticosteroids in these pathologies to inhibit the intense host inflammatory reaction has been controversial. The results of clinical trials have been contradictory and there is an increased risk of infection and gastro-intestinal bleeding. Corticosteroids are not used in the practice of ICRC surgical teams.

Flail chest is accompanied by lung contusion. Historically, the flail segment itself has received too much attention. The real clinical problem, and cause of mortality, is not the multiply-fractured ribs but the underlying lung pathology. Treatment aims to alleviate three elements:

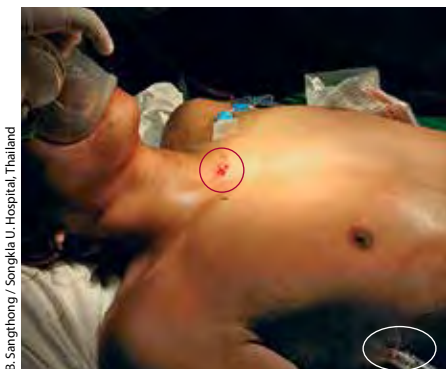
- paradoxical movement, and the distressing anxiety it provokes;
- pain, and its effect on lung ventilation;
- lung contusion.

Strapping the flail segment with a firm adhesive dressing and having the patient lie on the injured side are often sufficient to stop flailing and allow optimal function of the uninjured lung. The anxiety provoked by the paradoxical movement is frequently overcome by proper nerve block. The essence of treatment, however, is aimed at the lung contusion.

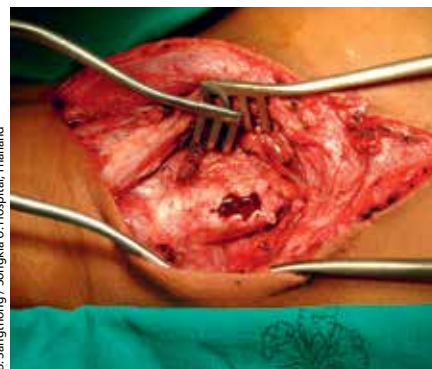6 Wilson A, Wall MJ Jr, Maxson R, Mattox K. The pulmonary hilum twist as a thoracic damage control procedure. *Am J Surg* 2003; **186**: 49 – 52.

### 31.10.3 Tracheobronchial injury

Half the trachea is in the neck and half in the thorax and always intimately related to the oesophagus and major vessels; therefore isolated injury is rare.



**Figure 31.29.1**  
Midline gunshot wound to the juncture of the neck and chest: tension pneumothorax was diagnosed and a chest tube placed (white circle).

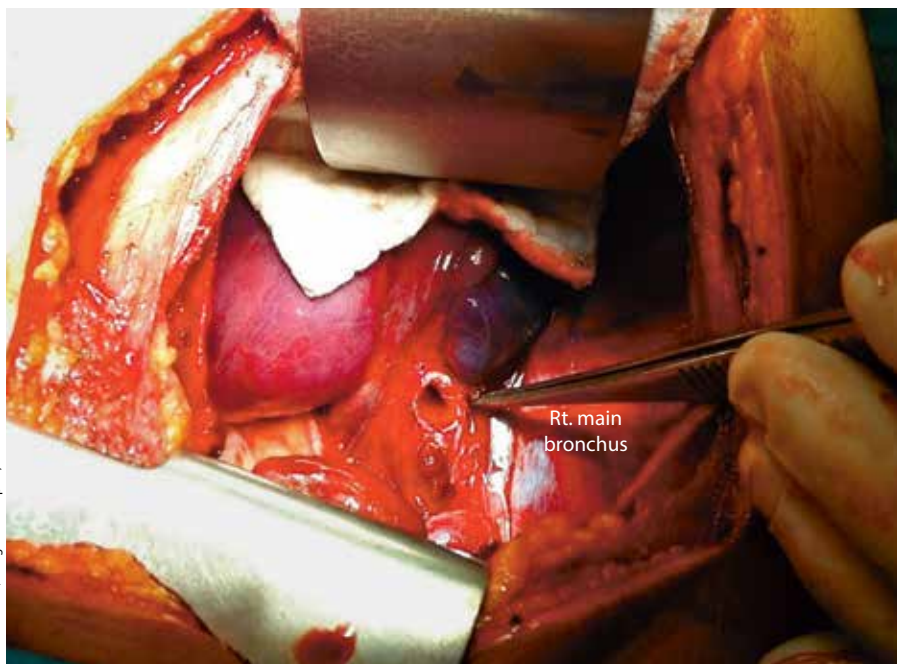


**Figure 31.29.2**  
It was possible to intubate the patient in order to splint the injured trachea.

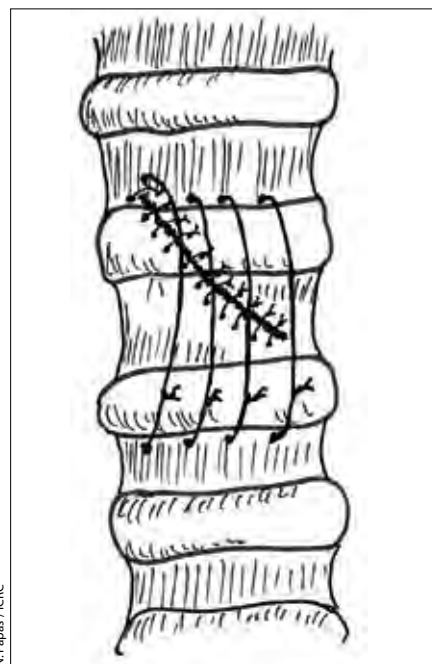
A small broncho-pleural fistula is more common than a massive air leak. Bleeding stops but air continues to bubble through the water seal in the chest bottle with every breath. Many small fistulae close spontaneously with time. A conservative approach is therefore justified.

The following signs and conditions suggest major tracheobronchial injury:

- pneumothorax in which no expansion of the lung can be achieved with suction drainage while continued vigorous bubbling of air is seen through the underwater seal;
- obvious mediastinal emphysema;
- severe subcutaneous emphysema;
- severe, repeated or persistent haemoptysis or dyspnoea;
- appearance and persistence of unusual atelectasis that cannot be corrected by conservative therapy.



**Figure 31.30**  
Injury to the right main bronchus.



**Figure 31.31**  
Tracheal repair.

During exploration, a lesion of the trachea is best treated by manoeuvring the endotracheal tube beyond the injury to provide a stent. For a main bronchus, it is better to push the endotracheal tube into the contralateral bronchus. Repair is best

accomplished by primary closure with interrupted absorbable synthetic sutures with the knots placed on the outside, covered with a flap of muscle or pleura. In the trachea, the sutures should include one ring above and one below the lesion.

### 31.11 Great vessels, heart and pericardium

A patient with a massive haemothorax requiring thoracotomy and who arrives alive to hospital will usually have suffered injury to the internal mammary or intercostal arteries. These can be safely ligated. A lesion in the aorta or another great vessel is not commonly encountered, unless an inadvertent injury is caused iatrogenically, i.e. intra-operatively.

The surgeon for whom this manual is intended is more likely to see a pseudoaneurysm or arterio-venous fistula than a freely bleeding laceration of a major vessel. Proximal and distal control is impossible for these vessels. A side-bite with a large, curved vascular clamp allows for repair without interrupting the flow of blood to vital structures. Lateral repair is sufficient most of the time; a larger laceration that would require grafting will have been fatal.

#### 31.11.1 Pericardial tamponade

Among the patients with cardiac injury who reach hospital alive the majority will have a small wound with self-limiting haemorrhage resulting in a pericardial tamponade. The patient has an automatic permissive hypotension of less than 90 mm Hg; the constrained heart is not capable of filling and pumping at a higher pressure. Efforts to raise the blood pressure by i.v. fluids should be avoided: the shock is cardiogenic, not hypovolaemic.

These injuries are more commonly seen with stab wounds than with projectiles and with fragments more frequently than with bullets. When caused by a bullet, such lesions occur at the end of its trajectory where it has only enough energy to pierce the chest wall, reach the heart, and then stop. In surviving casualties the injury has usually affected the low-pressure system – either the atria or the right ventricle. Very small fragments may only enter the pericardial sac and not present any clinical symptoms. A fragment lodged in the myocardium without penetration of a heart chamber creates the equivalent of a localized infarction. In both cases, they should be left *in situ*.

Section 8.5.1 describes the procedure of pericardiocentesis – a *temporizing measure* – while preparing for thoracotomy, and is often not successful. Blood that is rapidly lost into the pericardial sac clots, leaving a relatively small volume of fluid plasma that cannot always be efficiently aspirated. The surgeon must then decide if the patient is stable enough to wait while a full thoracotomy is performed. If the patient's condition remains unstable then a subxyphoid pericardial window allows for *further temporizing* while preparation for a full thoracotomy is undertaken.

#### 31.11.2 Subxyphoid pericardial window

The patient lies supine with a pillow under the lumbar spine to accentuate the lumbar lordosis. The operation can be performed under local anaesthesia and proper sedation. The incision begins to the left of the xyphoid and then down for 5 – 6 cm in the midline of the abdomen, through the linea alba but not penetrating the peritoneum. If necessary the xyphoid process is excised. The sternum is then retracted upward to reveal the preperitoneal fat.

Blunt finger dissection downwards removes the fat and peritoneum exposing a tough fibrous triangle: the coalescence of the diaphragm and base of the pericardium. A pericardial tamponade will present as a purplish bulge in the operative field. The pericardium is grasped with Allis forceps, or stay-sutures are placed, on either side of the midline and a small opening made with scissors.

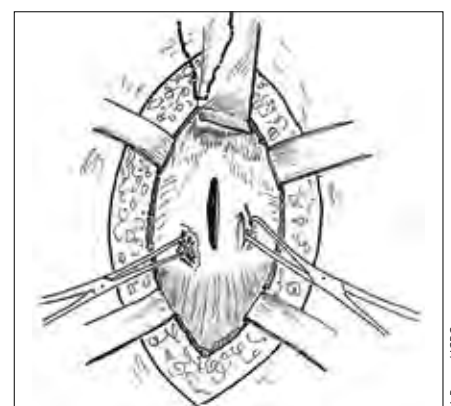


Figure 31.32

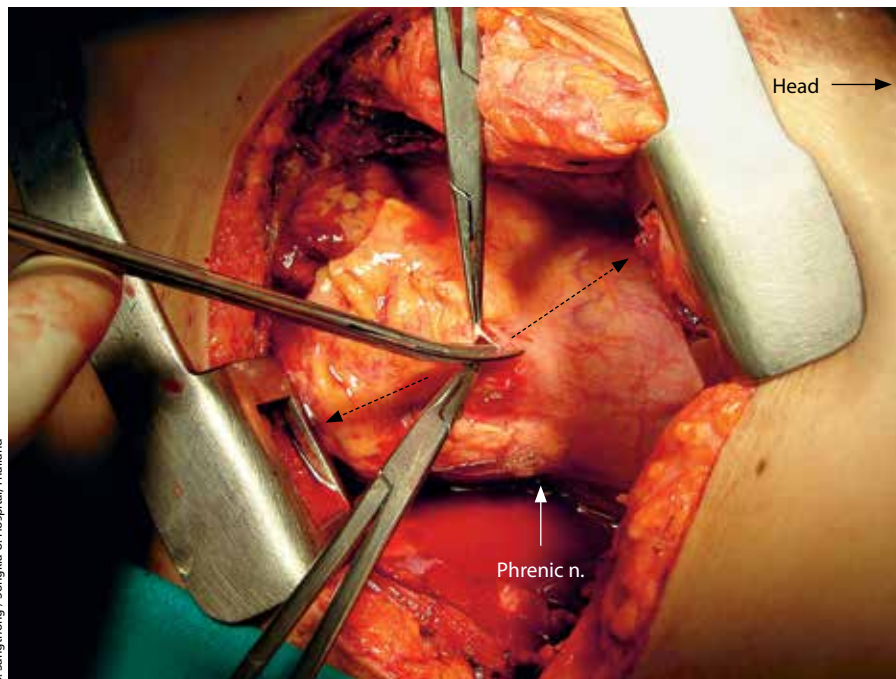
Opening in the pericardial-diaphragmatic triangle.

Repair of the myocardium in the tight confines of a pericardial window is difficult. It is better to extend the subxyphoid incision into an anterolateral thoracotomy by cutting through a costal cartilage.

### 31.11.3 Anterior thoracotomy and injuries to the heart

The usual approach is through an anterior thoracotomy. Whether a subxyphoid window or a thoracotomy is used, great care must be taken to identify and avoid injury to the phrenic nerve as the pericardium is opened.

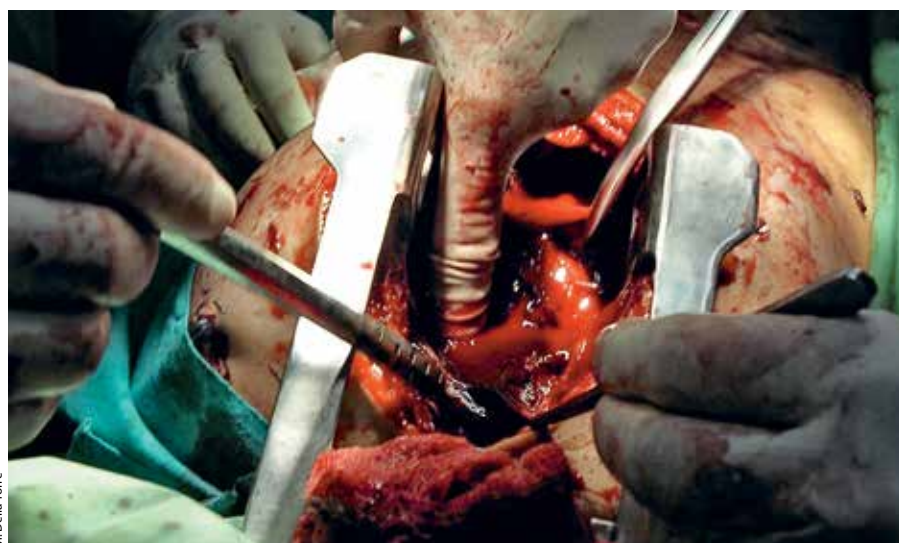**Figure 31.33**  
Opening the pericardium away from the phrenic nerve.



B. Sangthong / Songkila U. Hospital, Thailand

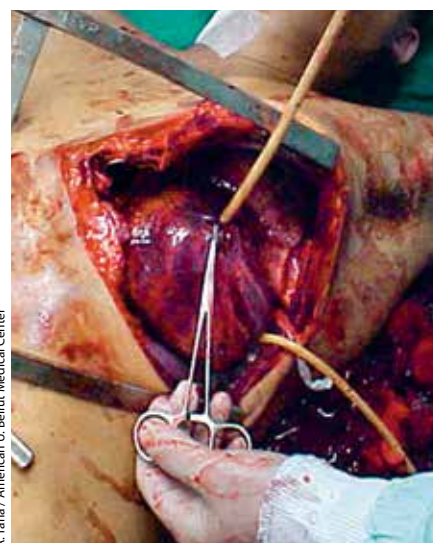
Once the pericardium is opened, the clot is evacuated and a finger placed to plug any hole in the myocardium. Alternatively, a small Foley catheter may be inserted in the hole and the balloon inflated with saline, but excessive traction should be avoided to prevent a small hole from becoming a large laceration. The release of the haemopericardium allows the patient's physiology to improve.

Never injure the phrenic nerve when opening the pericardium.



M. Della Torre

**Figure 31.34**  
Putting one's finger on the hole in the myocardium.



A. Taha / American U. Beirut Medical Center

**Figure 31.35**  
Foley catheter tamponade of the lacerations in the heart.



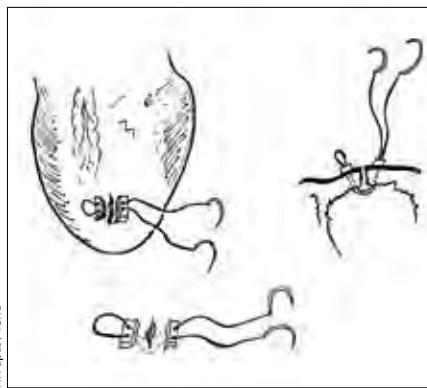
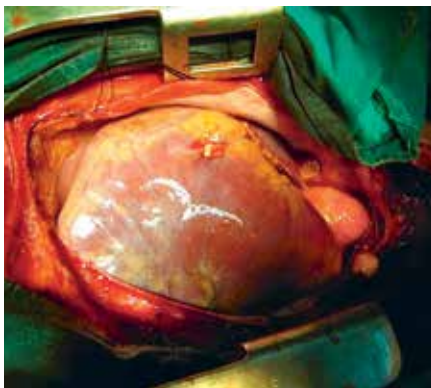
### 31.11.4 Myocardial suture

Repair differs according to the heart chamber injured. The right atrium is akin to a large vein and a Satinsky side-biting clamp can usually be placed and repair performed using a typical continuous vascular suture. It is best to commence the suture in intact healthy tissue and proceed into the lesion. To facilitate the tying of the knot the assistant should pinch closed the vena cava for a few seconds with the fingers in order to deflate the heart. In the case of a very small lesion, a purse-string suture can be used.

When suturing the thicker parts of the myocardium it is important to use a *large non-cutting* needle and a 3/0 or 4/0 non-absorbable suture to avoid lacerating the tissues; a 2/0 suture can be used in thick ventricular myocardium. A common error is to use small sutures which frequently convert a small tear into a large, stellate laceration.

Never include a coronary vessel when suturing the myocardium.

Horizontal mattress sutures are best, while taking care not to include a coronary artery in the suture. If the myocardium is oedematous and friable or simply very thin, it is preferable to place the sutures through reinforcing pledgets made up of a piece of tissue cut from the pericardium. The sutures should be tied very gently and carefully; they can so easily cut through the myocardium if they are pulled too vigorously.



Figures 31.36.1 and 31.36.2  
Myocardial mattress suture through a pledget.

Many a non-specialist surgeon will find the task of suturing a moving object disconcerting. A good trick for the surgeon is to rock back and forth in unison with the beating heart – the moving surgeon then becomes “stationary” in relation to the moving object.<sup>7</sup> The sutures are then placed between beats.

Once the anterior wound has been controlled, the back of the heart must be inspected as well. Through-and-through wounds by a small fragment tend to have a posterior opening that is smaller and easily overlooked.

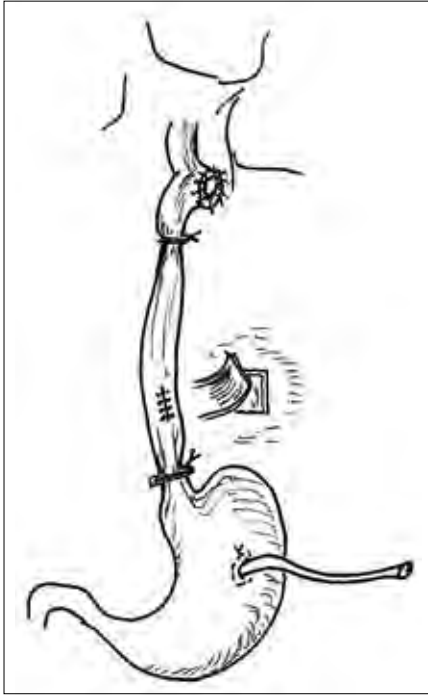
Pericardial closure with a few sutures must be complete enough to prevent herniation of the heart into the left pleural cavity but loose enough to permit drainage. A drain is placed in the pericardial sac and another retrosternal; drains are removed after 24 – 48 hours.

### 31.11.5 Azygous venous system

In the rare instances when an injury to the azygous veins is encountered during an emergency thoracotomy, an anterior incision is unsatisfactory for proper visualization. The patient must be repositioned to perform a formal posterior thoracotomy and enter the posterior mediastinum where the bleeding vessels can be ligated.

<sup>7</sup> This is a basic principle of Einstein's theory of special relativity.

## 31.12 Oesophageal injuries



**Figure 31.37**

Primary repair with oesophageal exclusion: proximal oesophagostomy and mucous fistula with distal gastrostomy. The repair should be covered with a flap of pleura or intercostal muscle.

Oesophageal injury is rare and all untreated patients die of mediastinitis and septic shock. Occasionally, the patient is diagnosed and operated on in the first 12 hours, but it is unusual for the patient to be sufficiently haemodynamically stable to allow for primary repair as can be performed for the cervical oesophagus. Thus, a damage-control approach is justified in most cases.

The upper and mid-thoracic oesophagus is approached through a right posterolateral incision in the 4th intercostal space (the azygous veins are ligated). The lower oesophagus is accessed by means of an extension of a left anterior incision after other injuries have been brought under control.

The same surgical principles apply as for the cervical oesophagus: local debridement, wide drainage and direct two-layered repair (mucosa and muscle) with a pedicle intercostal muscle or pleural flap graft as reinforcement. Primary repair should be attempted only within 12 hours of injury and only if the lesion is small with minimal inflammation. The patient's condition must be stable; otherwise only drainage should be instituted. In both cases, bilateral pleural and mediastinal drains are placed and the oesophagus excluded.

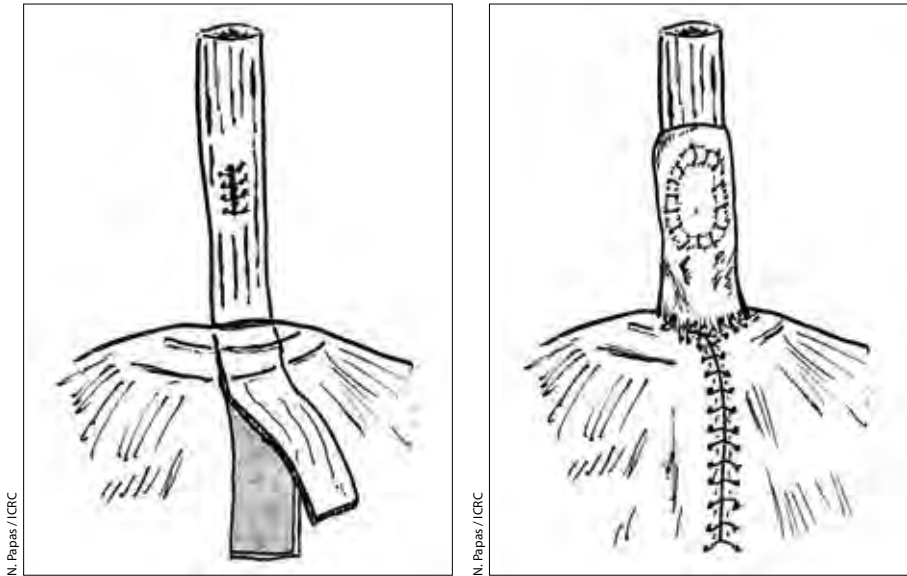
If *primary repair* has been performed, temporary defunctionalization is provided by proximal cervical oesophagostomy with a pharyngeal mucous fistula and diversion by a feeding gastrostomy. A ligature is placed distal to the oesophageal stoma in the neck to prevent dribbling of saliva into the oesophagus and distal to the lesion to prevent any regurgitation from the stomach. After two weeks, the patient is re-operated and the ligatures removed. A methylene blue or barium test verifies the repair and patency, and transit can then be re-established by closing the proximal defunctioning oesophagostomy and distal feeding stoma.

### Please note:

If chromic catgut is used for the ligatures, after two weeks they will have been absorbed and will not require re-operation for removal. Chromic catgut is no longer an ICRC standard because of possible ethical concerns associated with bovine spongio-encephalopathy – so-called “mad-cow disease” (see Annex 1.A). It is still available and used in many countries.

If *primary repair is not possible*, drainage must be adequate. A wide-bore drain (rectal tube, thoracic drain or “T”-tube) is passed through the lesion into the proximal oesophagus and brought outside to create a controlled fistula. One or two stitches or a purse-string suture are passed to close the perforation around the drain as much as possible. If a suction drainage system is available, this is best. As an extra security measure, the oesophagus can be excluded proximally and distally as per primary repair. Definitive surgical repair is considered after 2 – 3 weeks when the patient's condition has stabilized and any infection and inflammation has resolved.

For lesions of the lower third of the oesophagus, a gastric fundal-patch or diaphragmatic flap may be used. More radical reconstructive procedures for loss of a large segment of the oesophagus may need to be considered at a later date, but these involve specialist procedures.



Figures 31.38.1 and 31.38.2

Mobilization of a flap from the diaphragm.

In all instances, the patient is kept NPO and antibiotics given (ampicillin, metronidazole, and gentamycin) for at least a week. Nutritional support through the feeding gastrostomy is essential. Mediastinitis due to oesophageal leakage is invariably fatal when working with limited resources.

### 31.13 Other injuries

#### 31.13.1 Thoracic duct

Injury to the thoracic duct presents as chylothorax: yellow and fatty discharge through a chest tube. Initial management is conservative with prolonged chest tube drainage and a non-fat diet. However, the condition usually requires right posterior thoracotomy and perhaps a left supraclavicular incision, depending on the exact site of the lesion, and ligation of the fistula – the thoracic duct ascends on the right side of the vertebral bodies before passing behind the oesophagus to gain its left side in the superior mediastinum and then arches over the dome of the left pleura to enter the junction of the left internal jugular and subclavian veins.

The patient should have a fatty meal the night before surgery to help identify the fistula.

#### 31.13.2 Thymus

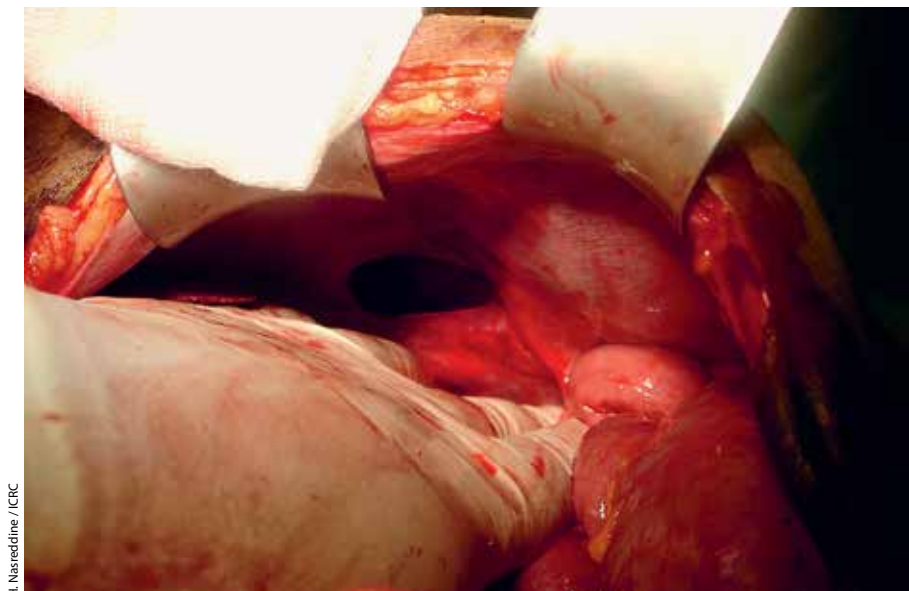
In children, the thymus may be very large and quite susceptible to injury. Its importance in developing the immune response means that every attempt should be made to preserve as much of it as possible. Debridement and oversewing of the cut edges are usually all that are required. A mediastinal drain is left in place for 24 hours.

#### 31.13.3 Diaphragm

Diaphragmatic rupture due to a projectile *is not* an indication for thoracotomy. Injury to the diaphragm indicates a thoraco-abdominal wound and repair should be accomplished via a laparotomy. Lavage of the pleural cavity is usually possible through the diaphragm without having to resort to a separate thoracotomy incision. A missed penetrating wound to the diaphragm results in a small perforation that often takes some time, even years, to develop into a diaphragmatic hernia. Details of diaphragm repair are given in Section D.4.

**Figure 31.39**

A large hole in the diaphragm.



H. Nasreddine / ICRC

### 31.14 Thoracic damage control

Emergency room thoracotomy may be considered a damage-control procedure. Its limitations have already been discussed. Most descriptions of thoracic damage control are not really mere temporizing measures but rather definitive repairs that are rapid and relatively simple. The goal of abbreviated thoracotomy is to stop bleeding and restore a survivable physiology; contamination is not usually a problem.

As with the abdomen, an “open” thorax during thoracotomy results in the loss of a great deal of body heat. Operating time should be as short as possible in these critical patients and the ambient temperature adjusted accordingly. Pleural lavage should be with warmed saline. Hypothermia must be avoided at all costs.

A comfortable temperature for the operating team may be fatal for the patient.

There are few damage-control techniques that are applicable to thoracic injuries. Unlike the abdomen, it is not possible to pack the pleural cavity or mediastinum in a way that does not grossly interfere with the normal physiology of respiration and circulation. Perhaps the only place where such packing may be useful to control bleeding is in the apex of the pleural cavity. This is similar to the procedure for controlling haemorrhage in Zone I injuries of the neck at the thoracic outlet (see Section 30.8.2). Otherwise, for a bleeding track in the chest wall, a Foley catheter tamponade may be attempted. The balloon is inflated and the catheter pulled just hard enough to obtain the required effect and then clamped at the skin surface. It is left in place for several days until the artery undergoes thrombosis.

Techniques that have already been described include the “hilum-twist”, the two-stage repair of an oesophageal injury, and closure of a chest wall defect using the “Bogotá bag” technique.

### 31.15 Post-operative care after thoracotomy

The principles of care for a chest tube also apply to the post-thoracotomy patient, only more so. The patient is in a more critical clinical state and requires close observation and monitoring. A ward designated as an “intensive nursing ward” is best for this purpose, with a high ratio of nursing staff to number of patients (see Part F.3).

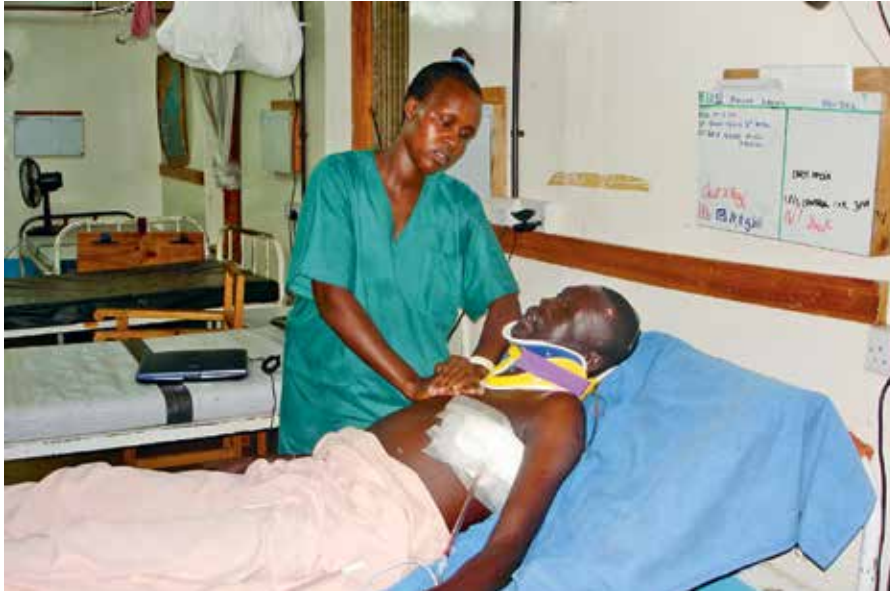

Figure 31.40

Chest physiotherapy in the intensive nursing ward of the ICRC Lokichokio Hospital, northern Kenya.

In the absence of mechanical ventilation, some patients are better off with a tracheostomy to better secure the airway, decrease the effort of breathing, and achieve tracheal toilet. There are relatively few specific indications for ventilation. One particularly useful procedure is to alternate short periods of manual ventilation by Ambu® bag with spontaneous breathing. The presence of sufficient trained personnel to allow for bagging a patient over a sustained period of time depends on the hospital's staffing.

Suction machines are essential, especially for tracheostomy care but are also useful for the chest tube. Analgesia without provoking respiratory depression is particularly important and intercostal nerve blocks are a valuable adjunct (see Annex 31.A). Good analgesia allows for intense chest physiotherapy, which is indispensable. Supplemental oxygen should be humidified.

### 31.16 Retained haemothorax

Apart from late evacuation of patients, the principal cause of empyema is failure to achieve complete evacuation of a haemothorax and re-expansion of the lung. If these are not achieved, antibiotics and other measures will seldom be enough to prevent infection. A retained haemothorax clots and then becomes organized into a thick and dense fibrinous collection of protein-rich fluid, which becomes infected and/or fibrotic, forming adhesions to the lung and pleura. Serial X-rays confirm the diagnosis.

Prevention of a retained haemothorax is based on a few simple measures: the use of a large diameter chest drain that functions correctly and good analgesia with proper physiotherapy.

#### Please note:

The control of pain must be stressed. The presence of a large calibre intercostal chest tube in itself causes pain. The patient while sitting in bed tends to bend the torso over towards the injured side in an attempt to find relief. This makes the ribs above and below the drain act as a clamp, closing off the drainage. Pain also decreases the amplitude of chest movements with respiration and prevents coughing and the adequate breathing exercises needed to fully expand the lung.

If a retained haemothorax develops less than seven days post-injury, it should be evacuated by thoracotomy; the sooner the better. If the patient is first seen after this period, and infection has not supervened, then lung entrapment has already occurred. In this case, it is better to wait 4 – 5 weeks to allow the clot to organize and the membranes to soften and mature, thus resulting in less bleeding during decortication

to free the lung. The delay also permits observation of the extent of encroachment on lung capacity. Pleural decortication is indicated if more than the equivalent of one lung lobe is non-functional; smaller clots are left as they are, to be absorbed slowly or become fibrotic.

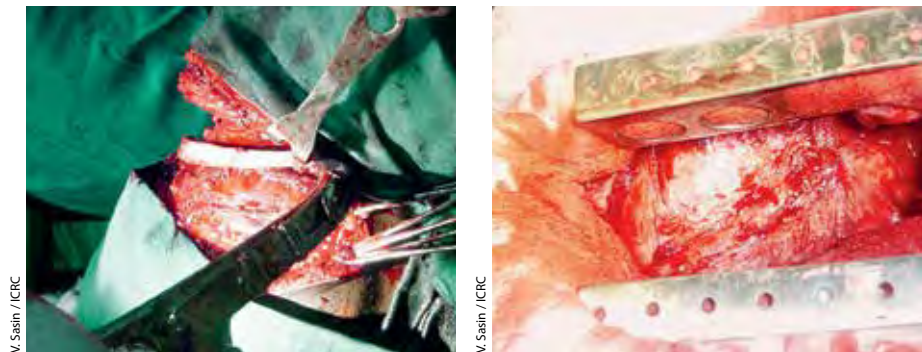
During decortication, careful dissection of the medial reflection of the parietal pleura posteriorly is required; it is very easy to enter an adherent aorta or oesophagus. The same careful dissection must be accomplished over the reflection of the diaphragm to avoid perforation. Decortication is a bloody and messy operation in these cases and, all too often, an empyema has resulted in the meantime.

### 31.17 Empyema

If empyema occurs, or if the patient presents late with frank infection, closed chest tube drainage should be attempted at first. If this fails, as is often the case, it can be followed by the well-established technique of chest fenestration: segmental resection of one or two ribs posteriorly and open thoracostomy drainage. This can be accomplished under local anaesthesia with minimal operative risk, in what is often a septic and malnourished patient.

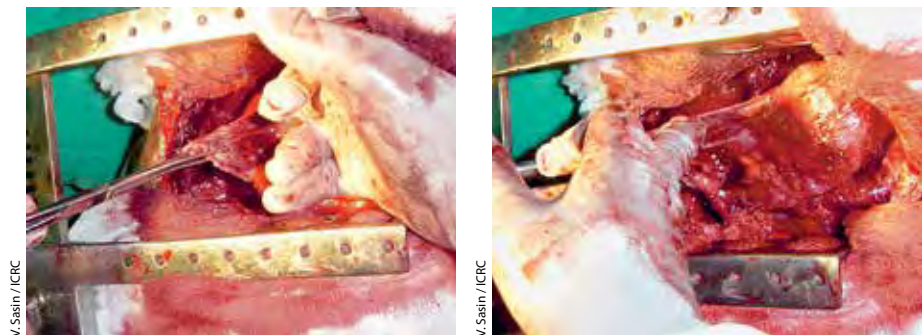
An erect X-ray is taken immediately before the procedure, radio-opaque markers having been placed on the skin to facilitate the determination of the exact position and extent of the infected collection. A thoracocentesis, with aspiration of pus, is performed to confirm the location. An incision is then made over the most dependent rib overlying the collection and continued down to open the periosteum. A subperiosteal segment of the rib, 10 cm long, is resected.

Figures 31.41.1 – 31.41.4  
Chest fenestration.



Figures 31.41.1 and 31.41.2  
The thick fibrotic envelope of the empyema is apparent.

The empyema cavity is entered by blunt dissection through the intercostal muscles just superior to the lower rib. Pus is evacuated and any foreign body removed. The cavity is washed out with a hypochlorite solution (0.25%: diluted bleach) or warm saline. The lung does not collapse, because of the presence of adhesions.



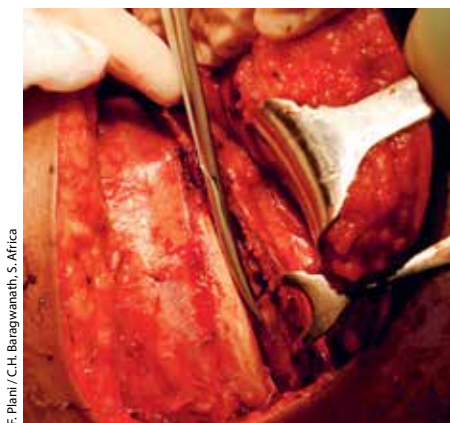Figures 31.41.3 and 31.41.4  
The cavity is entered and pus and fibrotic material are evacuated.

The muscles are sutured to the edge of the parietal pleura forming a simple fistula. A large, shortened chest drain is placed and the cavity packed with a strip of iodoform gauze. The dressing is changed after 24 hours, the chest tube and gauze removed, and twice-daily irrigations begun with hypochlorite solution or saline. The cavity is then packed with dry sterile gauze or pieces of foam cut from a mattress, packed in brown paper and passed through an autoclave as for decubitus ulcers to absorb the secretions (see Section 36.12.1).

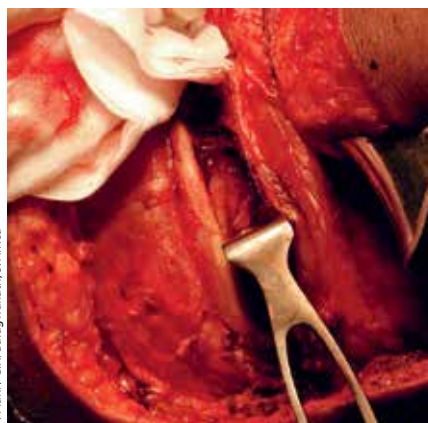
This simple procedure of rib resection and open thoracic window, still the operation of choice for post-pneumonia empyema in children, usually allows for the slow, gradual and complete resolution of the underlying empyema cavity and re-expansion of the lung. The lung comes to fill the cavity while fibrosis and contraction close the fistula. The skin heals over the open wound by secondary intention.

### 31.17.1 Decortication of empyema

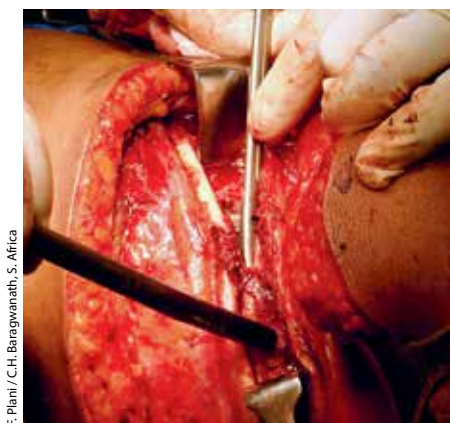
Failure of resolution after 20 days of open treatment is an indication for thoracotomy and decortication. However, patients suffering empyema are often critically ill and malnourished and not usually candidates for major surgery, such as a decortication: a difficult operation with much blood loss and a high risk for the septic patient. First, the nutritional status of the patient must be improved and the anaemia corrected. Only if this can be achieved and blood for transfusion is available should operation be contemplated.



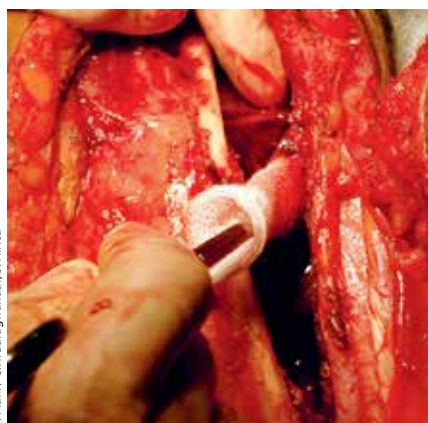
**Figure 31.42.1**  
Incision of the thick fibrotic envelope of the empyema.



**Figure 31.42.2**  
The empyema cavity is entered.

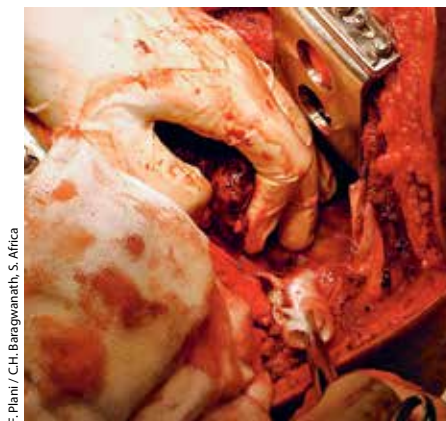

**Figure 31.42.3**  
Pus and fibrotic material are evacuated by aspiration.



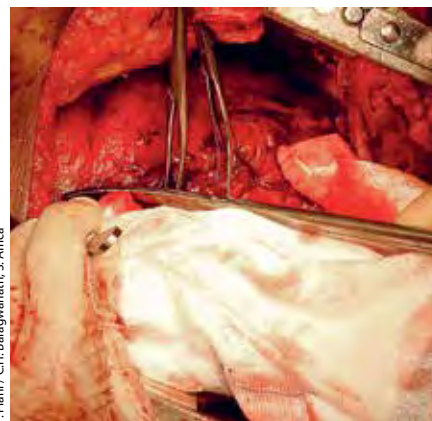**Figure 31.42.4**  
Compress dissection of the fibrotic parietal wall of the cavity.

**Figures 31.42.1 – 31.42.8**  
Decortication of an empyema.



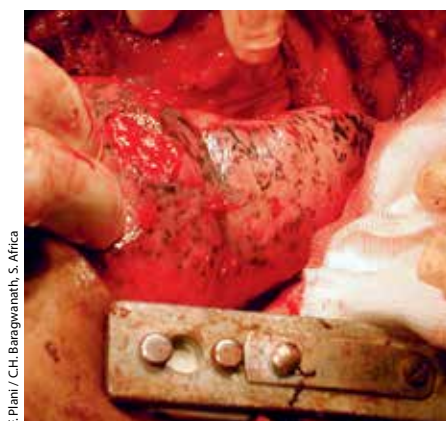F. Plani / C.H. Baragwanath, S. Africa

**Figure 31.42.5**  
Blunt finger dissection of the visceral wall of the cavity.



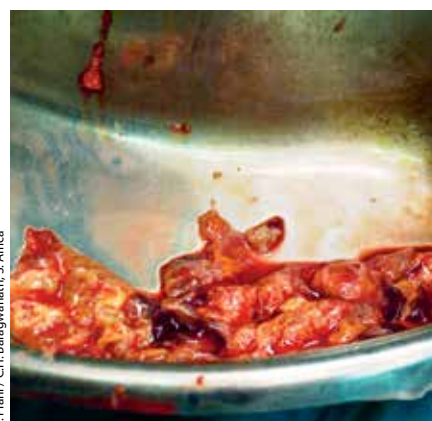F. Plani / C.H. Baragwanath, S. Africa

**Figure 31.42.6**  
Sharp dissection of the visceral wall of the cavity.



F. Plani / C.H. Baragwanath, S. Africa

**Figure 31.42.7**  
The lung is liberated from the empyema.



F. Plani / C.H. Baragwanath, S. Africa

**Figure 31.42.8**  
The evacuated malodorous pus and fibrotic material.

Antibiotics are usually required in the early stages when systemic signs and symptoms of infection are present, particularly fever and leukocytosis. Bacteriological study is indicated: at least a simple gram stain of an aspirate if more sophisticated means of culture and sensitivity are not available. On the other hand and in the absence of culture and sensitivity, if the patient has been receiving ampicillin/amoxicillin according to protocol, this should now be replaced by gentamycin – metronidazole, or chloramphenicol, or a cephalosporin. In countries where tuberculosis is endemic this should be taken into account in the differential diagnosis and, if indicated, specific therapy established.



## ANNEX 31. A Intercostal nerve block

Intercostal nerve blocks are useful methods of analgesia for all kinds of chest wall pain. Lidocaine 1% or 2% with adrenaline is normally used; it is effective for two to three hours. Maximum dose for an adult is 6 mg/kg with adrenaline, and 3 mg/kg without. Bupivacaine 0.5% with adrenaline is an alternative; maximum dose for an adult is 2 mg/kg and is effective for six to twelve hours. Bupivacaine has a much longer duration of action than lidocaine, but is much more expensive and not always available.

Since the analgesia lasts for only a few hours, repeated blocks are necessary. Still, it is a much better alternative than epidural analgesia, which is not used in the practice of ICRC surgical teams owing to concerns regarding hygiene and infection. Indeed, epidural anaesthesia is a technique that requires considerable expertise and monitoring to be used safely.

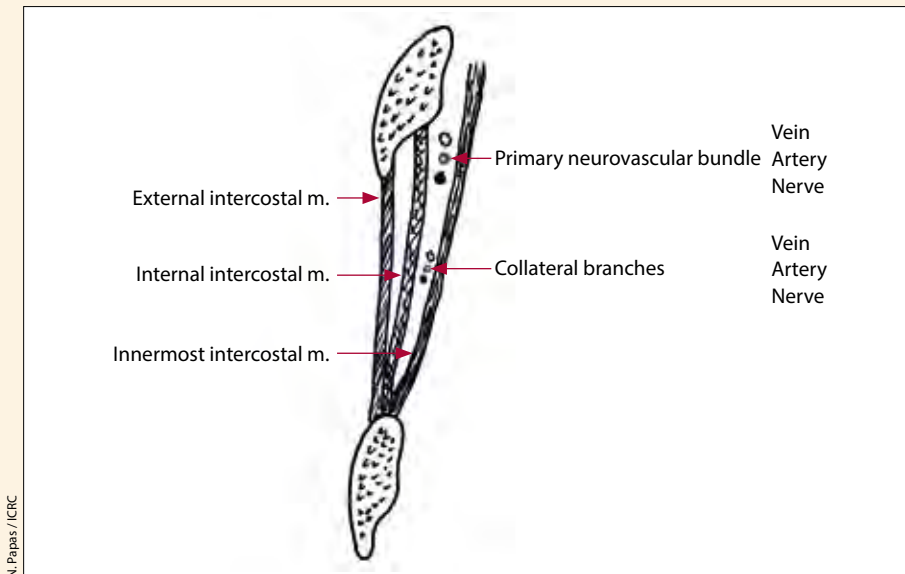


Figure 31.A.1

Vertical section of an intercostal space.

The injection site should be anywhere between the edge of the sacrospinalis muscle and the posterior axillary line. A wheal is raised at the lower border of the rib and the needle is then pushed through it. When contact with the rib is felt, the syringe is angled and the needle advanced about 3 mm behind the lower border of the rib. An aspiration test is carried out to ensure the needle is not in a vessel or intrapleural and the local anaesthetic injected.

The procedure is repeated 2 – 3 intercostal spaces above and below the injured area.

### Intra-operative nerve block

At the end of a thoracotomy and before closure of the chest wall, an injection of bupivacaine around the intercostal nerve posteriorly in the incision space as well as the intercostal spaces above and below the incision is a good adjunct.

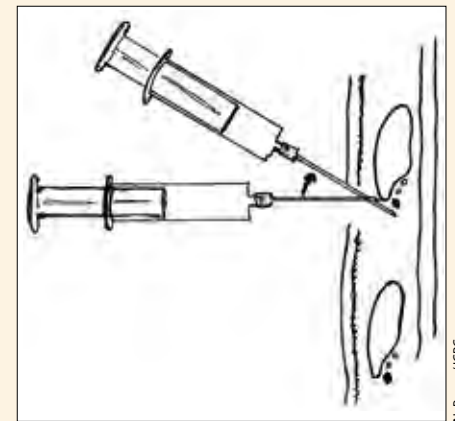


Figure 31.A.2

Angling of the syringe to reach the neurovascular bundle at the lower border of the rib.

## ANNEX 31. B Intercostal chest tube

### 31.B.a Insertion of midaxillary (basal) chest tube

The “safe area” of the chest wall for chest tube insertion is located between the lateral border of the pectoralis major muscle, avoiding the tail of the breast in women, and the mid-axillary line, in the 4th or 5th intercostal space horizontal to the nipple line. A simple rule of thumb, particularly useful in a stressful situation and with obese adults, is to place the hand horizontally in the apex of the axilla: the safe area is to be found just below the hand.

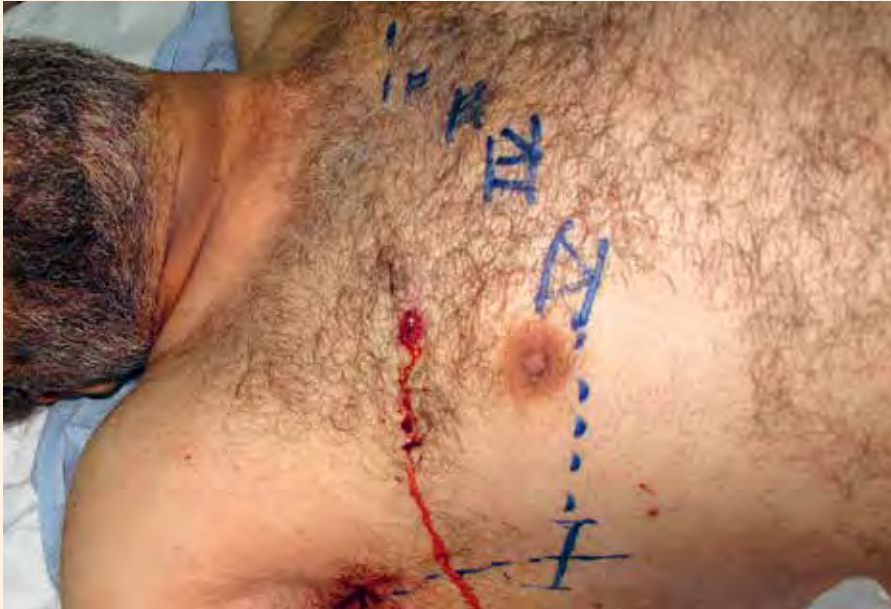

Figure 31.B.1

Site for placement of a basal intercostal chest tube.

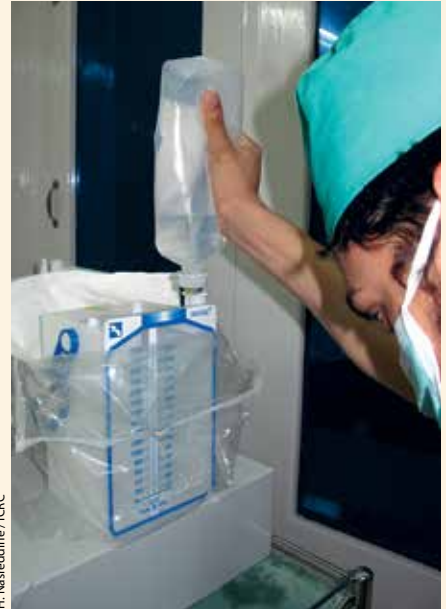

Figure 31.B.2

Preparing the chest bottle: normal saline should be used and not ordinary water in case autotransfusion is to be employed. Ordinary water is hypotonic and causes haemolysis.

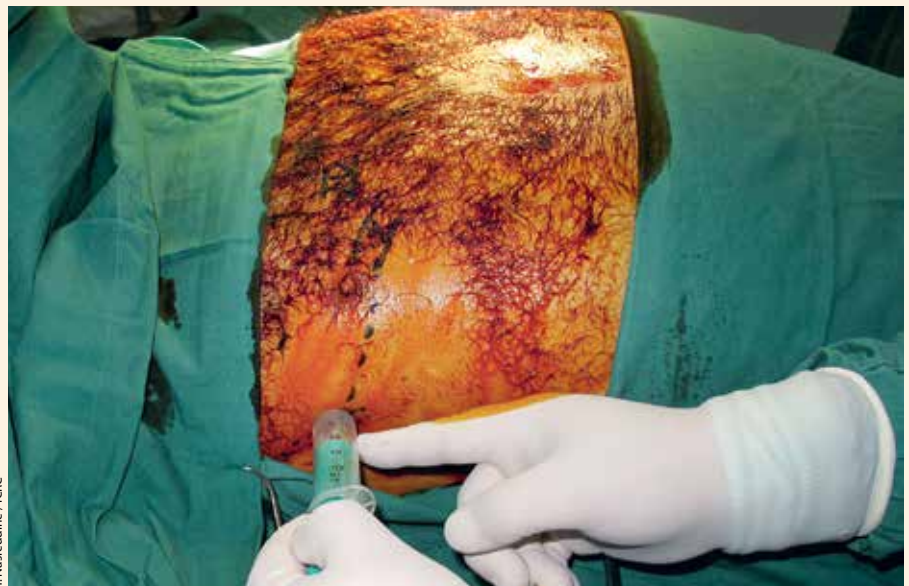A straight, large tube (32 F – 36 F in adults and 28 F in children) is used to promote rapid decompression of the pleural space.

#### Figures 31.B.3 – 31.B.19

A patient suffered multiple gunshot wounds with a right pneumothorax and left haemothorax; his condition was stable.

1. The patient is placed supine with a pillow below the shoulder of the injured side to slightly rotate the torso, and the arm flexed and folded behind the head. The skin is cleaned and the site prepped. The chest wall is anaesthetized with 1% lidocaine with adrenaline, from the skin to the parietal pleura, including the intercostal neurovascular bundle.

Figure 31.B.3



H. Nasreddine / ICRC

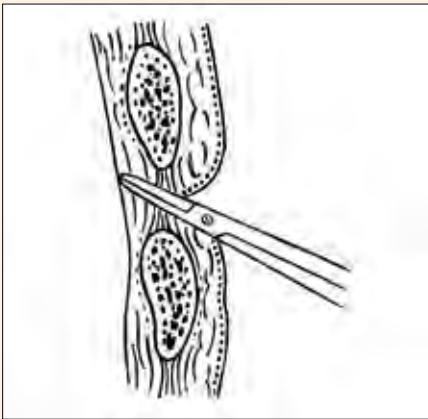
2. A horizontal skin incision large enough to admit a finger is made just anterior to the mid-axillary line at the fourth or fifth intercostal space.

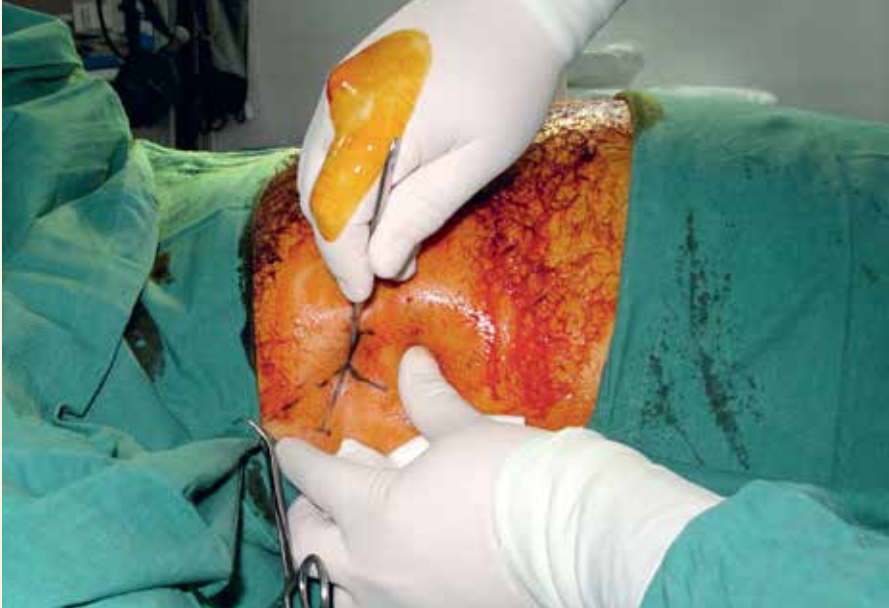
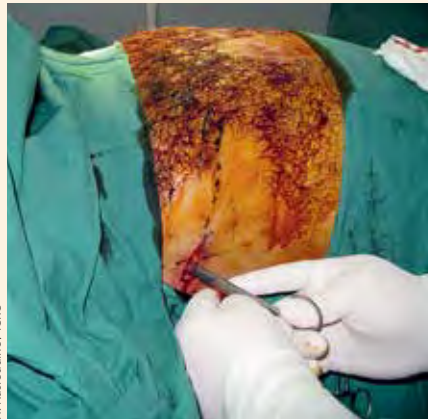
Figure 31.B.4

H. Nasreddine / ICRC

3. Using a curved haemostat, blunt dissection is continued through the intercostal muscles, hugging the upper border of the rib very closely.

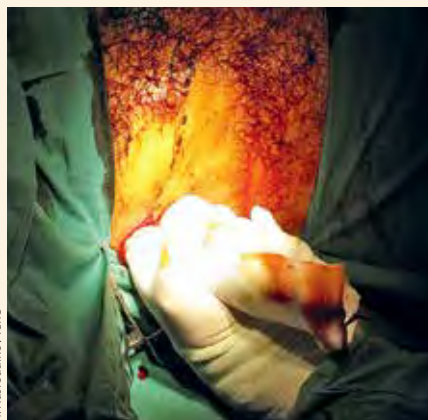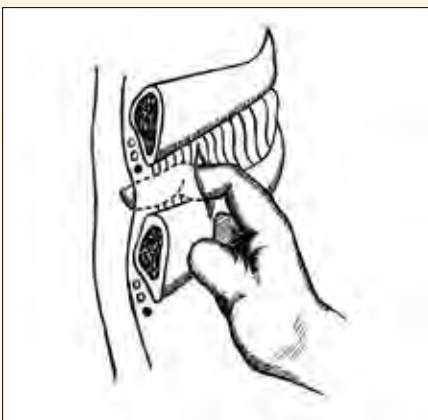


Figures 31.B.5 and 31.B.6

N. Papas / ICRC

H. Nasreddine / ICRC

4. The parietal pleura is entered by blunt dissection and a finger inserted; there is a gush of blood and/or air.



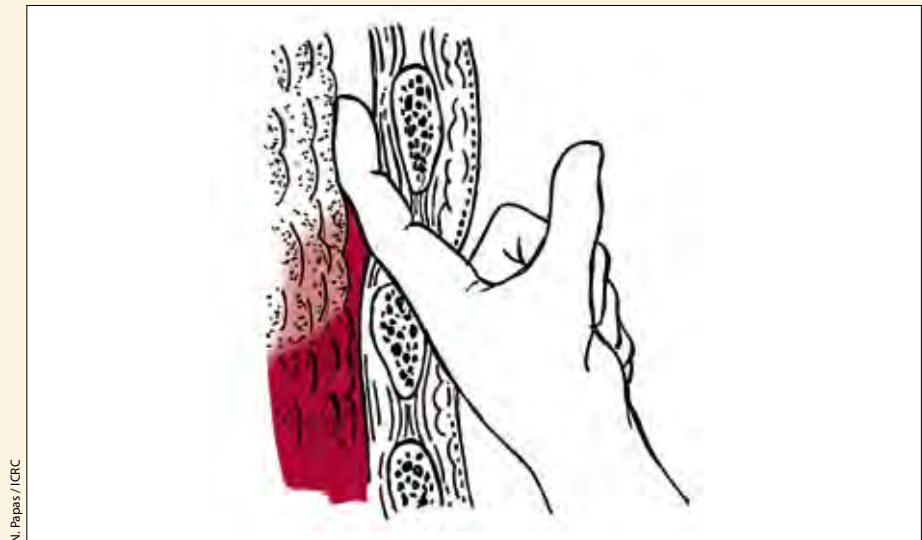Figures 31.B.7 and 31.B.8

N. Papas / ICRC

H. Nasreddine / ICRC

5. Inspection of the pleural space: the finger is swept around to make certain that pleuropulmonary adhesions are not present.

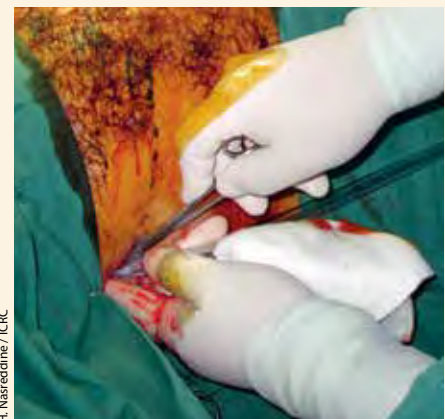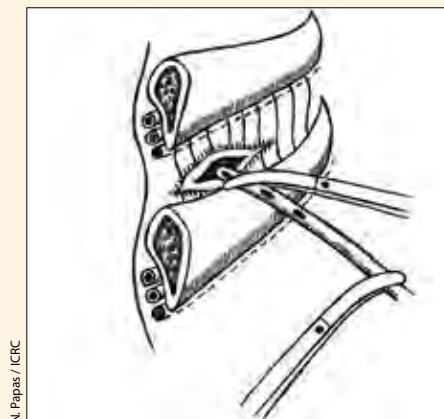Figure 31.B.9



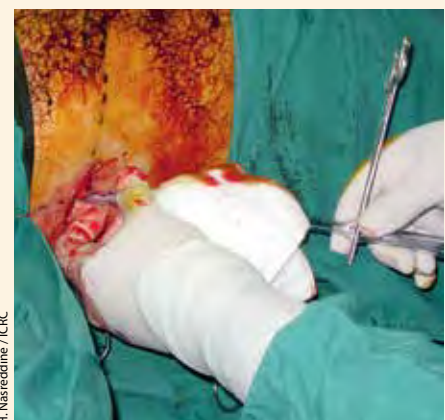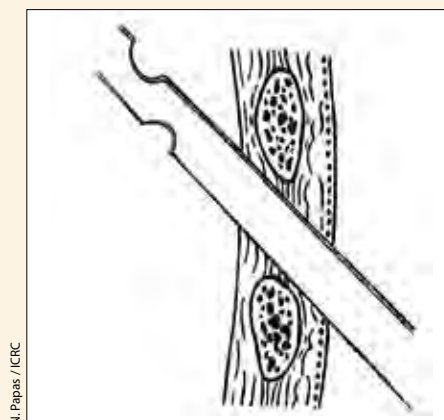
If there are adhesions that are not readily separated by digital exploration, steps (1) to (5) should be repeated in another intercostal space.

6. The tip of the clamped chest tube is grasped with a curved haemostat and introduced in a cephalad and posterior direction. The tube is advanced into the thoracic cavity until the side holes are well inside the pleural space and then rotated 360 degrees.

Figures 31.B.10 and 31.B.11

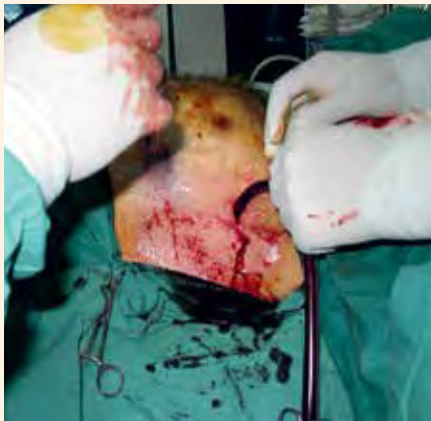

Figures 31.B.12 and 31.B.13




While an assistant holds the chest drain in place, it is connected to bubble tubing leading to a closed drainage system with an underwater seal containing normal saline.

- The clamp on the tube is then opened to check if fluid or air is discharged synchronously with breathing. As much blood and air as possible should be removed quickly into the drainage system by having the patient cough and breathe deeply.



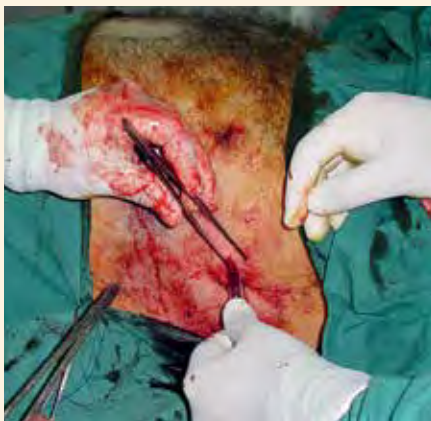H. Nasreddine / ICRC



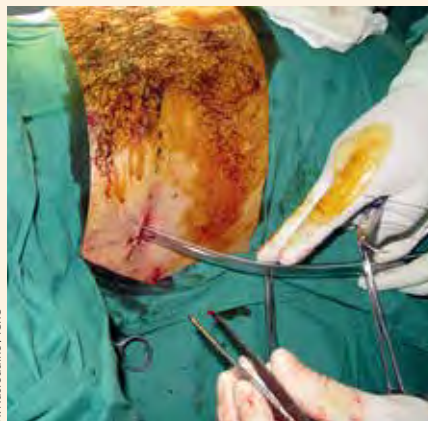
H. Nasreddine / ICRC

Figures 31.B.14 and 31.B.15

- A mattress suture closes the skin incision air-tight around the tube and secures it in place. One or two more mattress sutures can be inserted at the level of the drain and fixed to it with adhesive tape, to be tied shut when the tube is removed.



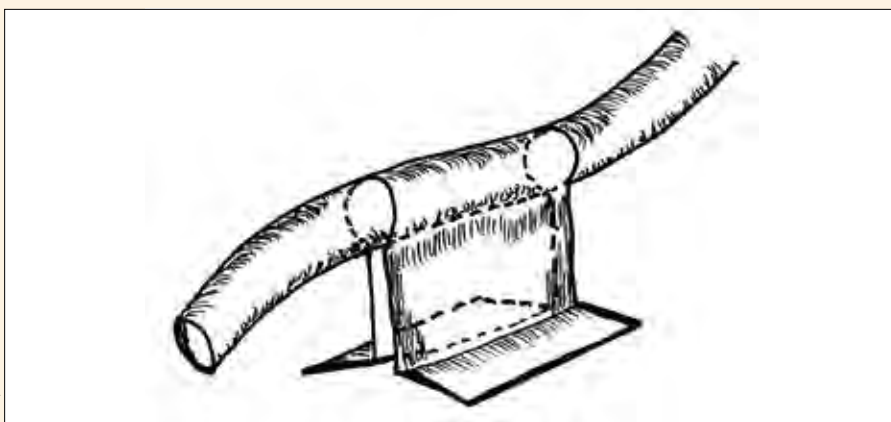
H. Nasreddine / ICRC



H. Nasreddine / ICRC

Figures 31.B.16 and 31.B.17

- All connections are secured with adhesive tape. The chest tube is further fixed to the chest wall by means of adhesive tape in the form of a "mesentery" that allows some movement.



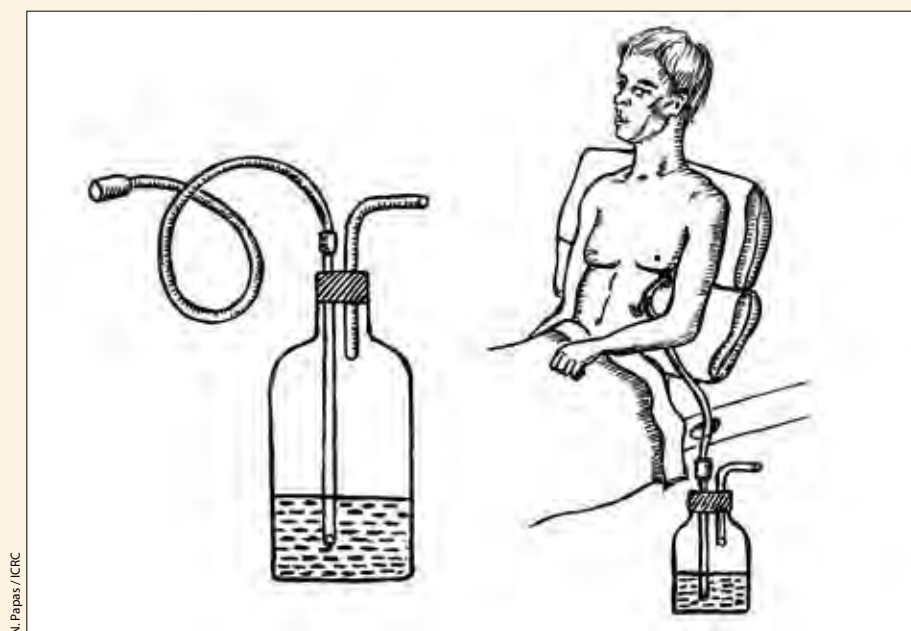N. Papas / ICRC

Figure 31.B.18

- The air exit of the chest bottle can be attached to a high-volume low pressure suction apparatus if available (10 – 20 cm of water of negative pressure), but this is usually not necessary.

Figure 31.B.19

Chest bottle with underwater seal.



### 31.B.b Insertion of midclavicular (apical) chest tube

A size 20 F or 24 F tube (16 F in children) is inserted through the second intercostal space (using the angle of Louis as an anatomic landmark) in the mid-clavicular line anteriorly, using the same technique as for a mid-axillary tube. The tube is advanced upwards to the apex of the pleural space.

### 31.B.c Removal of chest tubes

The removal of a chest tube is based on a number of factors.

- Auscultation and percussion confirm that the lung has re-expanded;
- AND there is no active bleeding;
- AND drainage consists of serous fluid of less than 250 ml/24 hours, which is simply a foreign body reaction to the presence of the tube;
- AND the fluid level of the underwater seal has stopped swinging *but is not blocked*.

If X-rays have been taken, there should be radiographic evidence that the lung has adequately expanded and collections have drained to a minimum. Air leak and chylothorax are absolute contraindications to removal until the underlying condition has been dealt with first.

The decision to remove a chest tube is primarily based on a clinical assessment of the patient's condition.

These criteria are sufficient in experienced hands, especially for a straightforward haemothorax. If there has been a significant *air leak* however, a safe protocol is to clamp the drain and observe the patient for 6 hours for respiratory embarrassment. After unclamping the tube there should be no bubbling. The drain may then safely be removed.

The procedure for removal of the chest drain involves measures to prevent an iatrogenic pneumothorax.

1. The stay suture is cut and the drain is rotated to free it from any fibrinous adhesions.
2. The patient performs a Valsalva manoeuvre during tube removal to ensure that no air is sucked in through the chest wall before the opening can be closed.
3. A sharp pull is exerted on the tube.
4. Children may not be able to cooperate in performing the Valsalva manoeuvre. The subcutaneous tunnel should be closed by finger pressure during removal of the chest tube or the surgeon can pinch the child to make him cry and pull on the tube at the appropriate moment.
5. The skin incision is closed either by pulling tight the sutures placed at the time of chest tube insertion or by placing a new suture.

A control X-ray is taken after 4 – 6 hours, especially if there has been air leakage or an intrapulmonary haematoma.

Physiotherapy should be continued for two weeks at home after discharge.

## ANNEX 31. C Thoracic incisions

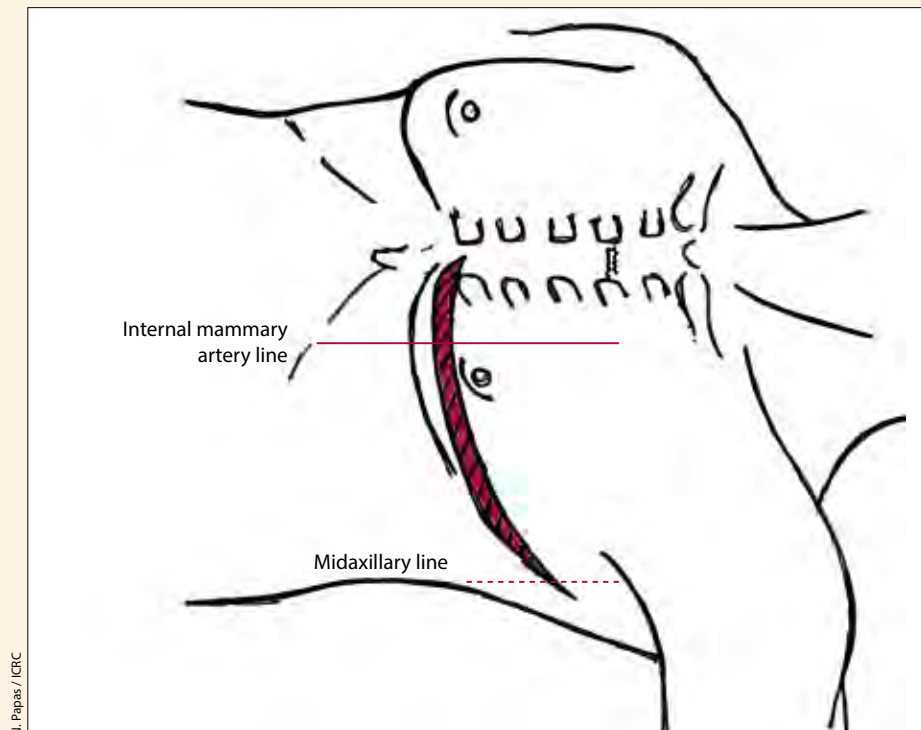
Several thoracotomy incisions are possible depending on the objective of the operation and the experience of the surgeon.

### 31.C.a Antero- and posterolateral incisions

The operative technique in both the anterior and posterior incisions is similar; only the position of the patient to allow greater posterior access is different.

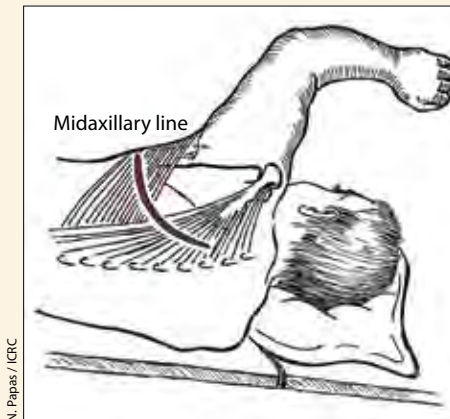
For the anterolateral approach, the patient is supine with the hemi-thorax slightly raised on a pillow or sandbag and the arms abducted 90° (Figure 31.C.1). The anterior incision begins lateral to the sternum in the 4th intercostal space and follows the inframammary fold to avoid breast tissue in women and then extends to the midaxillary line posteriorly. Care should be taken to isolate the internal mammary vessels. Improved access can be obtained by cutting the 4th costal cartilage to allow wider spreading of the rib retractor or by sternal division after tying off and sectioning the internal mammary vessels. The sternum can be divided by a Lebsche sternal knife or bone chisel and hammer.

**Figure 31.C.1**  
Anterior thoracotomy incision.

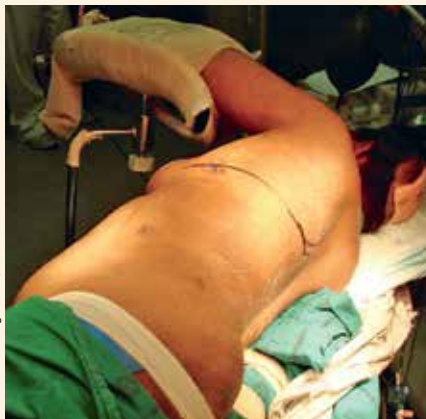

For the posterolateral approach, the patient lies on the side with the arm raised in a stirrup; the torso is steadied by means of various stirrups and straps. The posterior incision begins in the 6th intercostal space at the midaxillary line and extends posteriorly around the tip of the scapula and then proceeds cephalad cutting through the latissimus dorsi. This incision can be extended anteriorly; posterior access can be improved if necessary by the subperiosteal resection of 2 cm of a rib posteriorly, close to the paraspinal muscles.

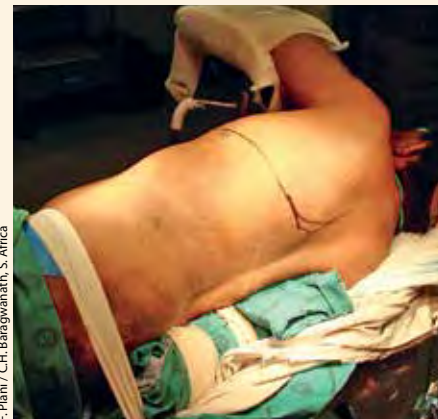



N. Papas / ICRC



F. Plani / C.H. Baragwanath, S. Africa



F. Plani / C.H. Baragwanath, S. Africa

**Figures 31.C.2 – 31.C.4**  
Posterolateral thoracotomy incision.

The incisions are made rapidly with a scalpel for skin and fascia, while muscles are divided in the line of their fibres by cautery or by scalpel. The easiest and quickest approach is to cut through the intercostal space just above the rib, thus avoiding the main and collateral intercostal neurovascular bundles. All muscle layers are cut through quickly until the shining surface of the pleura is reached. This is entered bluntly and a finger inserted to make certain that the lung has fallen away from the chest wall and that there are no adhesions. The pleura is then cut with scissors through the full length of the skin incision. An appropriate retractor (Finochietto rib spreader) is placed and the ribs separated. If a Finochietto is not available, deep abdominal retractors can be used or simply the assistant's hands in an emergency.

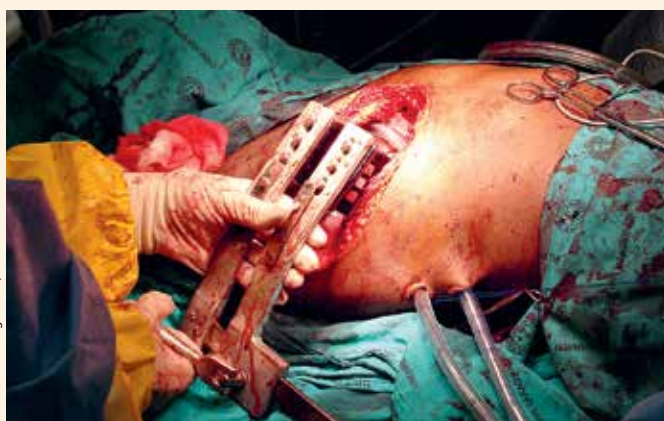

T. Gassmann / ICRC

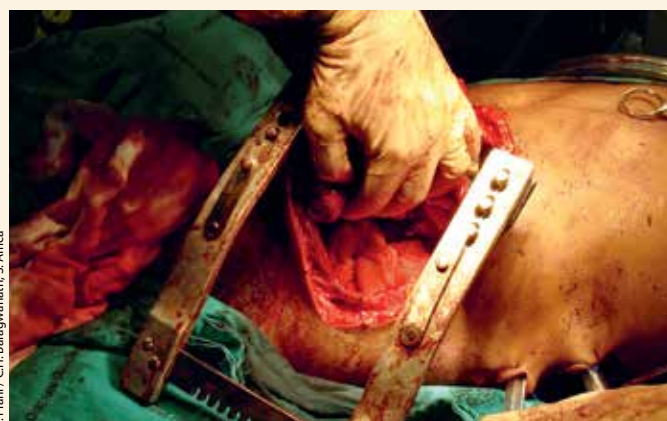

T. Gassmann / ICRC

**Figures 31.C.5 and 31.C.6**  
Basic essential equipment: Finochietto rib retractor, top view and underside.



F. Plani / C.H. Baragwanath, S. Africa



F. Plani / C.H. Baragwanath, S. Africa

**Figures 31.C.7 and 31.C.8**  
Finochietto retractor in use during an anterolateral thoracotomy.

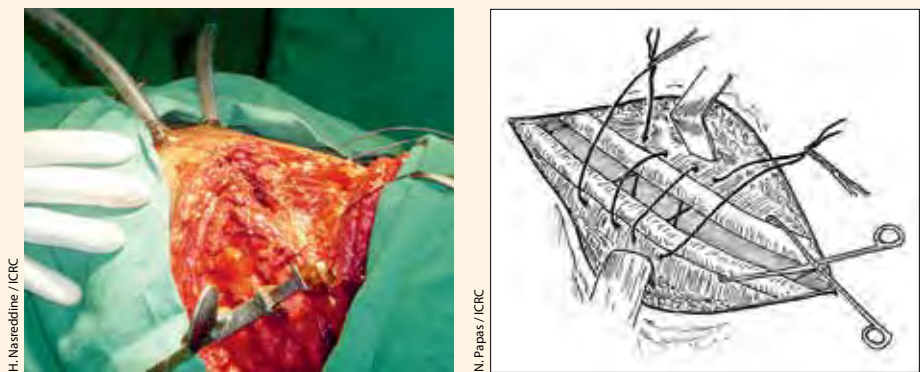
**Closure of anterior and posterior incisions**

At the end of the operation, pleural toilet involves washing out the cavity with warm saline, removal of any clots and foreign bodies, and the placement of a chest tube under direct vision in the 7th or 8th intercostal space, a *different intercostal space* from the one chosen for the initial incision. The internal mammary artery should be identified before closure and preserved; but if sectioned, it should be ligated.

Three or four vertical mattress sutures of thick absorbable material are passed through the intercostal spaces above and below the incision, but not tied until all sutures are in place. The ribs are then re-approximated using widely spread towel clips to grasp the rib above and below the incision. Then, the parietal pleura and the first layers of the intercostal muscles are taken up together and closed by an air-tight interlocking continuous suture of 2/0 synthetic absorbable material, thus recreating a functional pleural cavity. To reinforce this, the next layer of muscles and the fascia are picked up and closed as a second layer, also with a continuous suture. Finally, the skin is closed with a continuous suture that is quicker to perform than interrupted sutures and is not prone to any complications. In the posterior incision, the divided latissimus dorsi is repaired separately by suturing the sectioned ends.

**Figures 31.C.9 and 31.C.10**

Mattress sutures are passed through the spaces above and below the incision but not tied until all sutures are in place.

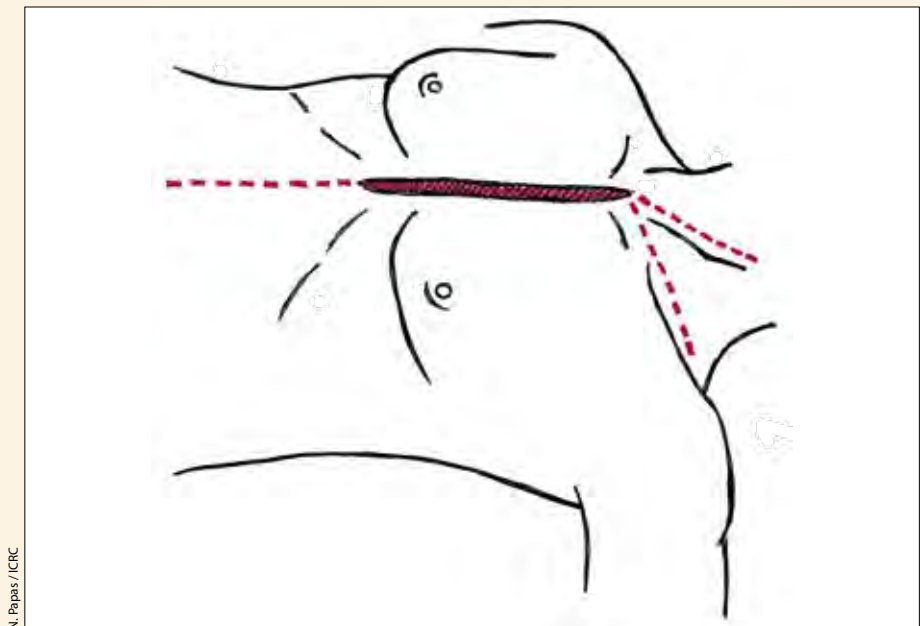


**31.C.b Median sternotomy**

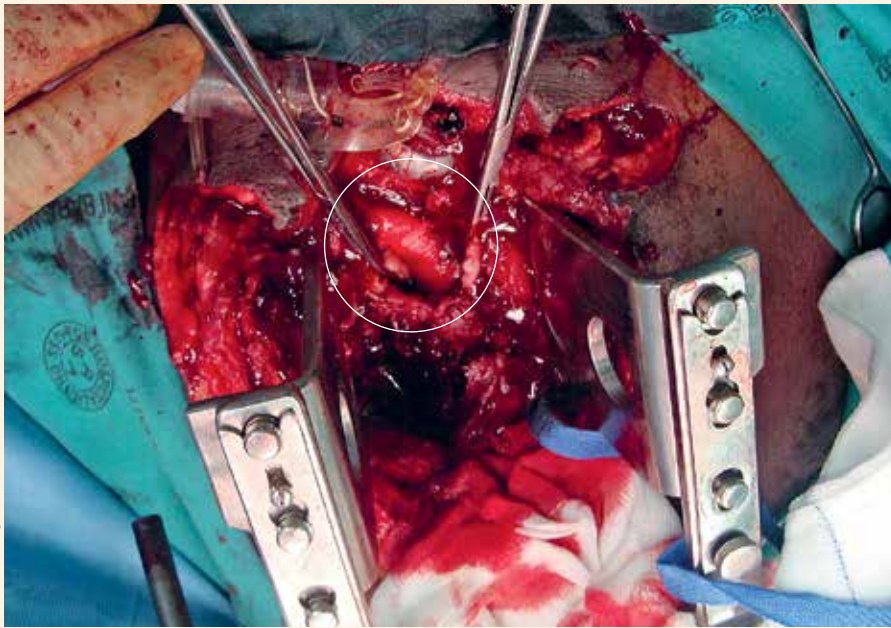
The patient should be placed supine with a pillow or roll placed between the scapulae and the arms tucked in at the sides. The incision extends from the suprasternal notch down to just beyond the xyphoid process, going all the way through to the periosteum of the manubrium and sternum. Bleeding from the periosteum is controlled by gauze compress pressure and cauterization.

**Figure 31.C.11**

Median sternotomy incision: the dotted lines depict possible extension for a laparotomy, into the neck as an SCM incision, or as a supraclavicular incision.



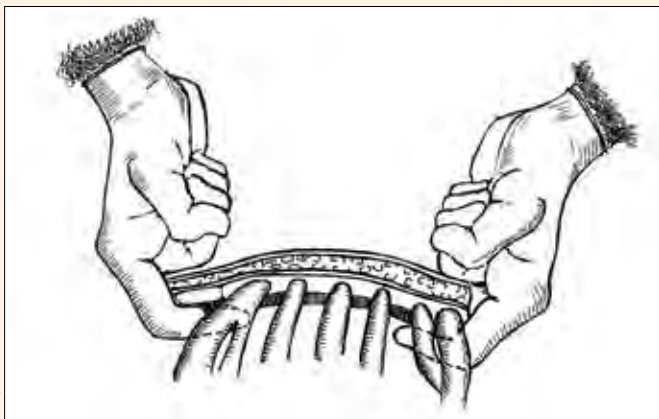
Small connecting veins crossing the sternal notch and the xyphoid are clamped and ligated. The sterno-clavicular ligament is carefully incised; the brachio-cephalic trunk lies just under the joint. Distally, the xyphoid process can be resected.



**Figure 31.C.12**  
Clamping and dividing the connecting veins crossing the sternal notch.

F. Plani / C.H. Baragwanath, S. Africa

Finger dissection separates the soft tissue from the under-surface of the sternum. A long curved abdominal or pelvic haemostat is passed under the sternum and a Gigli wire pulled through; the bone is then cut using the protective metal strip that comes with the kit. Alternatively, a hammer and bone chisel or Lebschke knife can be used to split the sternum. If available, a special oscillating electric sternal saw is preferred and makes the opening easier; it is best if the anaesthetist stops ventilation during the cutting.



N. Papas / ICRC

**Figure 31.C.13**  
Finger dissection of the soft tissue underlying the sternum.



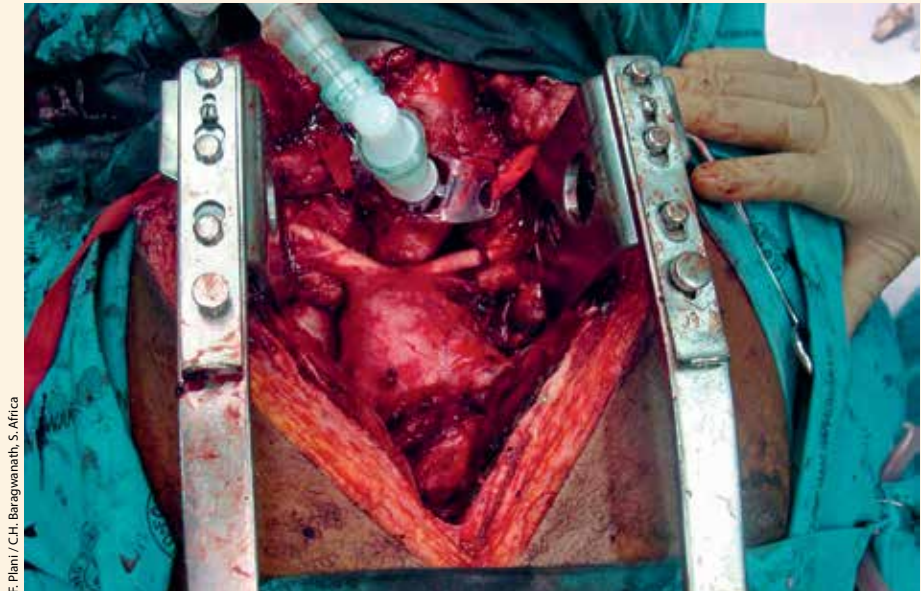
F. Plani / C.H. Baragwanath, S. Africa

**Figure 31.C.14**  
Essential equipment for cracking the sternum: a mallet and a Lebschke sternotomy knife (sternum chisel).

Care must be taken to incise the sternum exactly in the middle, creating two symmetrical halves. The cut should begin at the midpoint of the suprasternal notch and then pass through the centre-point of the manubrio-sternal juncture where the sternum is at its narrowest. Bleeding from the cut edges is controlled by pressure with a gauze compress or bone wax. The two sides are then pulled apart manually to expose the upper mediastinum and a retractor placed.

Figure 31.C.15

Sternotomy for exposure and repair of the trachea.



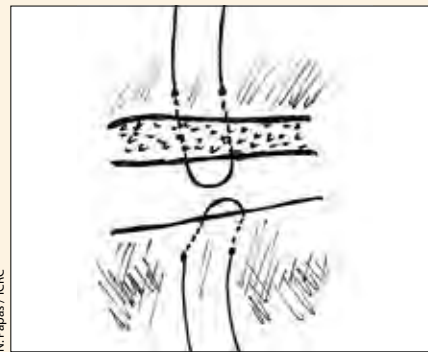
F. Plati / CH, Baragwanath, S. Africa

**Closure of median sternotomy**

Closure of the cut bone is accomplished with large-gauge stainless steel wire; two stitches for the manubrium and three or more for the rest of the sternum. Holes are drilled one centimetre from the cut edge of the bone and the wires passed through, crossed, and twisted.

Figures 31.C.16 and 31.C.17

Closure of median sternotomy: mattress sutures.



N. Papas / ICRC

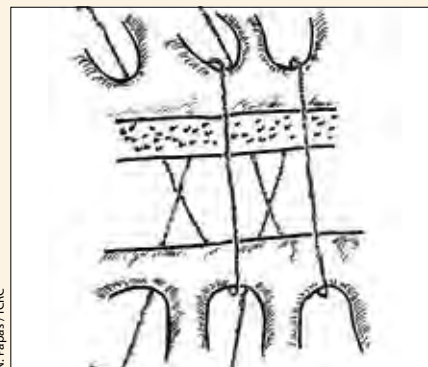


N. Papas / ICRC

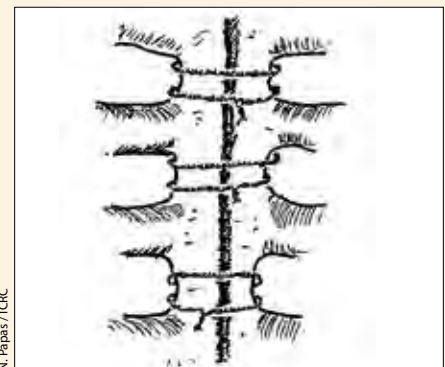
Three or four other wires or thick monofilament nylon (fishing tackle) are placed through the intercostal spaces at the lateral edge of the sternum.

Figures 31.C.18 and 31.C.19

Peristernal stitch.



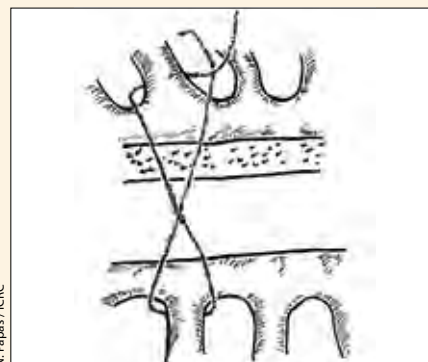
N. Papas / ICRC



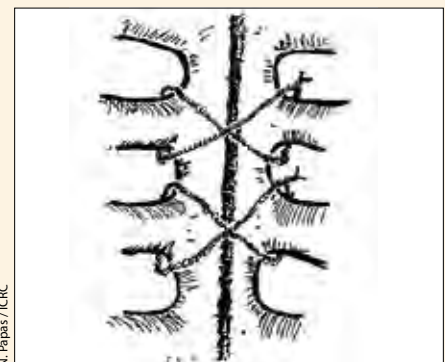
N. Papas / ICRC

Figures 31.C.20 and 31.C.21

Pericostal stitch.



N. Papas / ICRC

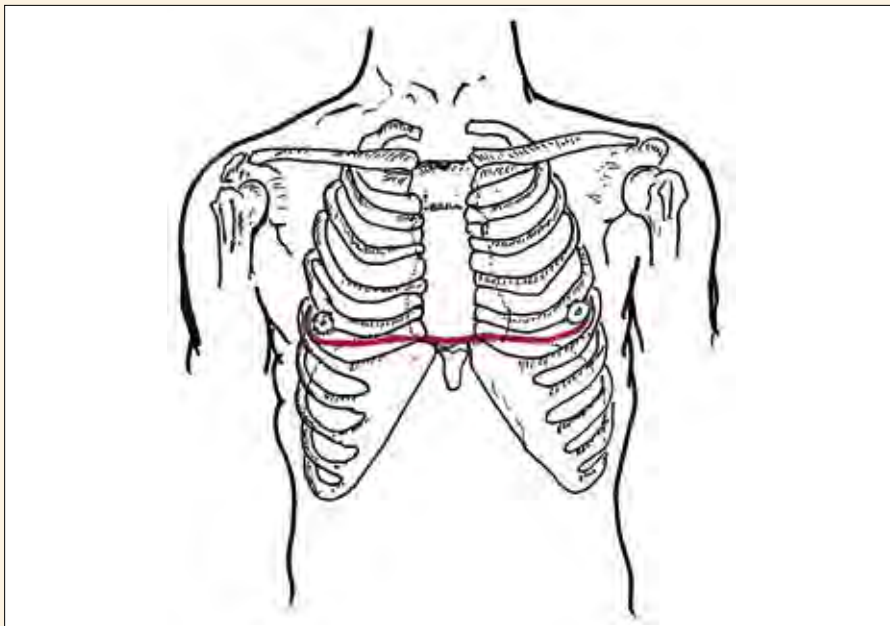


N. Papas / ICRC

Before tightening the wires and closing the incision, chest tube drains are placed in the mediastinum and brought out through the epigastrium, and the internal mammary vessels on each side are inspected; any injury to them is treated by ligation.

### 31.C.c “Clamshell” incision

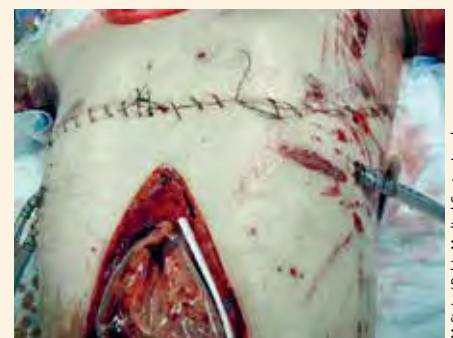Although a seemingly “radical” approach, this incision can be performed very quickly and safely by the general surgeon for a patient *in extremis*. It consists of bilateral anterior thoracotomies joined by a division of the sternum.<sup>8</sup> The patient is supine with the arms abducted and a small pillow placed under the lower thoracic spine. Two incisions are made in the 5th intercostal spaces, left and right, as for placing a chest tube and a finger is inserted in each to make certain that the lung has fallen away. A deep skin incision following the 5th intercostal space is then made to connect the two incisions. The intercostal muscles and pleura are incised using a strong pair of scissors. The sternum, or xyphoid depending on the individual’s anatomy, is then cut across using the strong scissors, bone cutters, a Lebschke sternal knife or bone chisel, or a Gigli saw.



M. Stein / Rabin Medical Centre, Israel

Either the two hemithoraces are then manually pulled apart by an assistant, or two rib spreaders are placed for retraction. The internal mammary vessels are sectioned and ligated bilaterally. Closure of the intercostal spaces is as with the anterior incision; the sternum is closed with steel wire in an “X” suture passing above and below adjacent ribs as for a median sternotomy.

Figure 31.C.22  
“Clamshell” incision.



M. Stein / Rabin Medical Centre, Israel

Figure 31.C.23  
“Clamshell” incision of the chest. A Bogotá bag covers the laparotomy incision.

<sup>8</sup> For details see: Wise D, Davies G, Coats T, Lockey D, Hyde J, Good A. Emergency thoracotomy: “how to do it”. *Emerg Med J* 2005; **22**: 22 – 24.



## **Chapter 32**

# **INJURIES TO THE ABDOMEN**

<b>32.</b>	<b>INJURIES TO THE ABDOMEN</b>	
<b>32.1</b>	<b>Introduction</b>	<b>421</b>
<b>32.2</b>	<b>Wound ballistics</b>	<b>421</b>
32.2.1	Hollow viscera	422
32.2.2	Solid parenchymatous organs	422
32.2.3	Particular organ injuries	423
32.2.4	Pelvis and buttocks	423
32.2.5	Extraperitoneal bullet trajectory, intraperitoneal damage	424
32.2.6	Primary blast injury	424
<b>32.3</b>	<b>Epidemiology</b>	<b>425</b>
32.3.1	Incidence of abdominal injuries	425
32.3.2	Mortality	425
32.3.3	Mortality risk factors	427
32.3.4	Frequency of organ injuries	427
32.3.5	Negative and non-therapeutic laparotomy	429
32.3.6	Role of the wounding mechanism	430
32.3.7	Scoring systems	431
<b>32.4</b>	<b>Clinical presentations</b>	<b>432</b>
32.4.1	Diagnosis	432
32.4.2	Presenting syndromes	432
32.4.3	Clinical examination	432
32.4.4	Paraclinical investigations	433
<b>32.5</b>	<b>Emergency room management</b>	<b>434</b>
32.5.1	Resuscitation	434
32.5.2	Evisceration	435
32.5.3	Impalement	435
<b>32.6</b>	<b>Decision to operate</b>	<b>436</b>
32.6.1	Criteria for consideration	437
<b>32.7</b>	<b>Preparation of the patient and anaesthesia</b>	<b>437</b>
<b>32.8</b>	<b>General plan of surgery</b>	<b>438</b>
32.8.1	Incision	438
32.8.2	Exploration	438
32.8.3	Massive haemorrhage	439
32.8.4	Mild to moderate haemorrhage	440
32.8.5	Controlling contamination	440
32.8.6	Finishing and closure	442
<b>32.9</b>	<b>Damage control: abbreviated laparotomy</b>	<b>442</b>
32.9.1	Temporary abdominal closure	444
<b>32.10</b>	<b>“Frontline laparotomy” and late-presenting patients</b>	<b>445</b>
<b>32.11</b>	<b>Midline great vessels</b>	<b>446</b>
32.11.1	Access to the aorta: left-sided medial visceral rotation (Mattox manoeuvre)	447
32.11.2	Access to the inferior vena cava: right-sided medial visceral rotation	448
32.11.3	Management of arterial injuries	448
32.11.4	Management of venous injuries	449
<b>32.12</b>	<b>Liver and biliary tract</b>	<b>450</b>
32.12.1	Severity of injury	450
32.12.2	Management of simple liver lacerations	451
32.12.3	Management of larger wounds of the liver	451
32.12.4	Through-and-through wounds of the liver	453
32.12.5	Management of complex liver injuries	453
32.12.6	Drains	457
32.12.7	Complications	457
32.12.8	Extrahepatic biliary tract	458
<b>32.13</b>	<b>Pancreas, duodenum and spleen</b>	<b>458</b>
32.13.1	Injuries to the head of the pancreas	459
32.13.2	Injuries to the duodenum	461
32.13.3	Treatment of injuries to the distal pancreas	463
32.13.4	Treatment of injuries to the spleen	464
32.13.5	Post-splenectomy prophylaxis of infection	464
<b>32.14</b>	<b>Stomach</b>	<b>465</b>
<b>32.15</b>	<b>Small bowel</b>	<b>466</b>
<b>32.16</b>	<b>Colon</b>	<b>468</b>
32.16.1	General principles of treatment	468
32.16.2	Right colon	471
32.16.3	Transverse colon	471
32.16.4	Left colon and intraperitoneal rectum	472
32.16.5	Retroperitoneal missile tract	472
32.16.6	Complications	473
32.16.7	Colostomy care	473
32.16.8	Colostomy closure	473
<b>32.17</b>	<b>Pelvis</b>	<b>474</b>
32.17.1	Pelvic fractures	475
32.17.2	Injury to the iliac vessels	476
32.17.3	Sacral venous injury	476
32.17.4	Extraperitoneal rectum and anus	477
<b>32.18</b>	<b>Abdominal drains</b>	<b>478</b>
<b>32.19</b>	<b>Post-operative care</b>	<b>479</b>
<b>32.20</b>	<b>Post-operative complications</b>	<b>480</b>
Annex 32. A	Abdominal compartment syndrome	482



## Basic principles

Thoraco-abdominal injuries are common.

Examine the whole torso: front and back and sides, and the perineum.

Patients usually present with one of two main syndromes: haemorrhagic or peritoneal.

Do not perform unnecessary paraclinical investigations.

Better to open and look than to wait and see.

Be systematic when exploring the inside of the abdomen.

Missed injuries can kill the patient.

Injury to the great vessels usually presents as a contained retroperitoneal haematoma in survivors arriving at hospital.

The Pringle manoeuvre for liver injuries can be life-saving.

Drainage is essential in injuries of the pancreas and/or duodenum.

In war surgery, injury to the spleen requires splenectomy.

Be suspicious of an odd number of intestinal perforations.

The proper treatment for injuries of the colon depends on the judgement and experience of the surgeon.

Adequate nutrition must be maintained for severely-injured patients: a feeding stoma is an appropriate procedure.

### 32.1 Introduction

Abdominal war wounds have the strangest history of all injuries suffered in times of armed conflict. Leaving behind the long-held belief and fatalistic approach that all such wounds were inevitably lethal and that operative intervention was fruitless, surgeons have moved on to a modern aggressive approach of damage control and staged multiple-operation surgery. Of all major life-threatening injuries, wounds in the abdomen are the most amenable to surgical intervention likely to produce good results and the return of the patient to a productive life. Mortality has gone from near 100% down to around 10% in one century, probably the greatest improvement in the surgical care of the war-wounded.

War wounds of the abdomen include penetrating intraperitoneal lesions and retroperitoneal injuries to the abdomen and pelvis. Occasionally, extraperitoneal wounds of the abdominal wall may also produce intraperitoneal lesions, as can primary blast injury. A better understanding of wound ballistics, and the realization that not every bullet or fragment hits something important, helps explain why not all abdominal wounds are equal.

### 32.2 Wound ballistics

When considering wounds in the abdomen, the patient's individual anatomy is important. Given enough tissue substance, a stable high-energy FMJ bullet tumbles and demonstrates all three phases of the shooting channel. Thus, a bullet striking a thin individual whose lateral diameter of the abdomen is barely 30 cm and antero-posterior diameter 20 cm will not have the same effect as a bullet hitting an obese individual with an 80 cm lateral and 50 cm antero-posterior diameter.

High-energy fragments can cause large defects in the abdominal wall with considerable intraperitoneal damage. On the other hand, small fragments with just enough energy to pierce the abdominal wall may cause little intraperitoneal damage: a superficial haemorrhage of the liver that has already stopped bleeding when the peritoneum is opened; a small puncture wound of the intestine that seals spontaneously without any peritoneal soiling. These small punctures are the most problematic and may give an ambiguous clinical picture.

Despite the large number of different organs contained in the abdomen and pelvis, in terms of wound ballistics they comprise only three large categories of structures:

- hollow viscera;
- solid parenchymatous organs;
- muscular and bony structures of the retroperitoneum and pelvis.

### 32.2.1 Hollow viscera

Hollow organs may suffer direct crush and laceration resulting in a small punctate wound with a very narrow zone of contusion around it. A single projectile may hit several loops of intestine causing multiple perforations, or strike parallel to and along the length of the bowel creating a large laceration.

Cavitation effects on hollow organs depend on whether the organ is empty or full. Section 3.4.3 describes the “boundary effect” of the wall of the stomach, intestines, and bladder. An empty organ is relatively elastic and resists damage due to stretch. Conversely, when the organ is full, any cavitation occurring within its fluid contents can have an “explosive” effect owing to the rapid rise in hydraulic pressure.

A temporary cavity in the midst of the abdominal cavity causes a brutal radial displacement of loops of bowel. The intestines resist the resulting stretch, but stretch of the mesentery and mesocolon can provoke multiple petechiae and haemorrhagic bullae and, in extreme cases, rupture of the blood vessels. The petechiae do not require surgical treatment, but ruptured vessels with a haematoma in the mesentery or mesocolon do – they can cause local ischaemia resulting in necrosis and perforation a few days later.

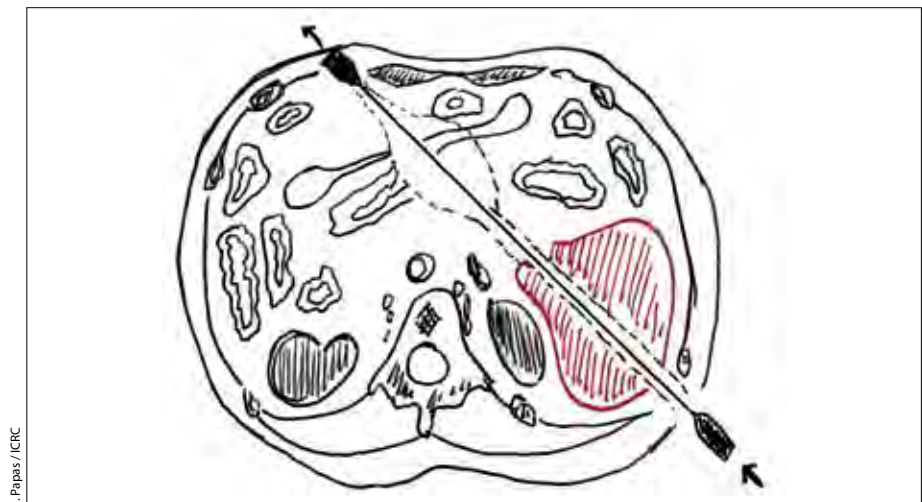
### 32.2.2 Solid parenchymatous organs

Solid organs contained within a strong connective tissue capsule, such as the liver, spleen, kidney, or pancreas have the same specific gravity as muscle but are not elastic and do not tolerate cavitation; they are also subject to boundary effect within their capsule. The slightest cavitation effect destroys their cellular and connective tissue matrix and tends to shatter them.

The trajectory of a missile is thus very important: two examples are given in Figures 32.1.1 and 32.1.2 of the same trajectory of a high-energy FMJ bullet but with opposite entry and exit sites.

**Figure 32.1.1**

The entry wound is located in the right flank: the liver is affected by the initial narrow channel with crush and laceration only. Cavitation occurs within the general peritoneal cavity amongst loops of intestine that can better absorb the stretch.



N. Pappas / ICRG

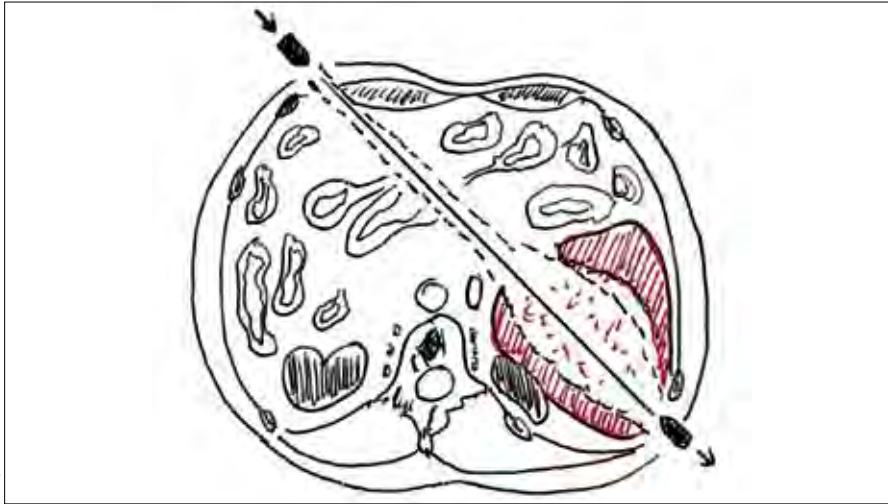


Figure 32.1.2

The entry wound is anterior and para-umbilical with the exit in the right flank: cavitation occurs within the liver, thus producing a shattering effect.

Damage from a fragment or destabilized ricochet bullet is greatest at the entry and then tapers off as it penetrates.

### 32.2.3 Particular organ injuries

Major vessels are usually injured by direct hits. The fixed retroperitoneal vessels are at greater risk from cavitation than those in the mesos: violent lateral displacement of the fixed aorta and vena cava ruptures them. The coeliac trunk, mesenteric and colic vessels are anatomically more mobile.

The retroperitoneal muscles react like all muscles and ballistic damage can be minimal or severe. As with skeletal muscles, small punctate wounds caused by low-energy fragments do not require debridement, while large and ragged wounds do. Projectiles traversing the colon can theoretically carry contaminants with them, injecting bacteria into the retroperitoneal tissues. Apparently not much contamination occurs with small fragments; studies have shown that the bacteria found in most wounds immediately after injury have not penetrated beyond the first centimetre and the body is usually capable of dealing with them. With greater tissue damage and time, however, bacteria may spread through the necrotic tissue of the projectile tract.

### 32.2.4 Pelvis and buttocks

The pelvis and buttocks include a bony enclosure (including the proximal part of the femur), large muscle masses, and an important region of extraperitoneal areolar tissue containing blood vessels and hollow viscera such as the bladder and ano-rectum. The gravid uterus reacts like a muscular mass or hollow organ depending on the gestational age and the quantity of amniotic fluid, which determine the extent of cavitation effects and resistance to stretch.

The ballistic effects are variable: a projectile can pass through the buttocks and pelvis without injuring any vital structure or it may cause devastating damage.

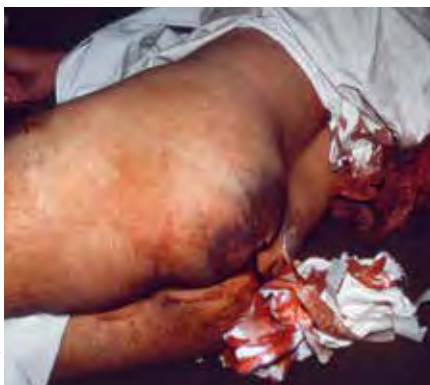

Figure 32.2.1

Major GSW of the buttocks, but involving the soft tissues only.

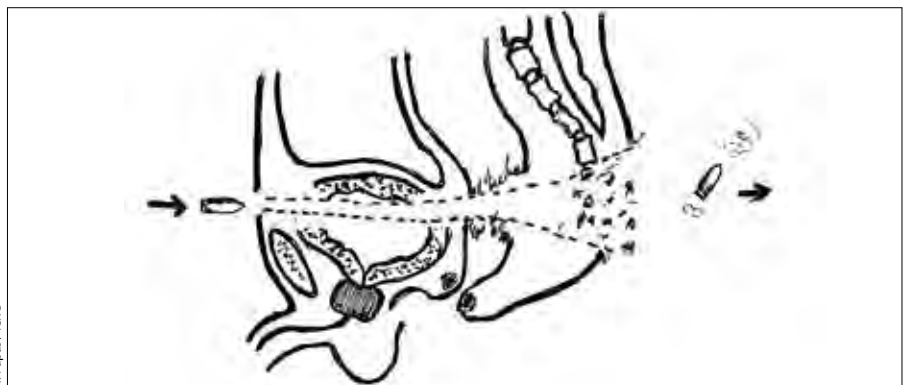


Figure 32.2.2

Schematic diagram of abdomino-pelvic wound. Cavitation occurs at the sacral exit with devastating damage.

### 32.2.5 Extraperitoneal bullet trajectory, intraperitoneal damage

A bullet with a tangential trajectory, passing entirely within the muscles of the abdominal wall for a long enough distance, can create a temporary cavity. It is this cavitation effect that can affect intraperitoneal organs. Most often, in what remains a relatively rare occurrence, the stretch of the mesentery provokes an area of ischaemia in a small segment of the bowel, which then proceeds to necrosis and perforation. The perforation occurs several days after the injury and therefore diagnosis is delayed. The patient may have been kept under observation and then discharged from hospital only to return two or three days later with an acute abdomen. The patient's condition is seldom critical and most reported cases do well after laparotomy.

Even rarer are cases where the perforation is instantaneous without stretch of the mesentery. Such patients do not always present immediately with symptoms if the opening is small and no faecal contamination occurs. It is obviously not known how many patients suffer from lesions like these that heal spontaneously. Some however do arrive with an acute abdomen.

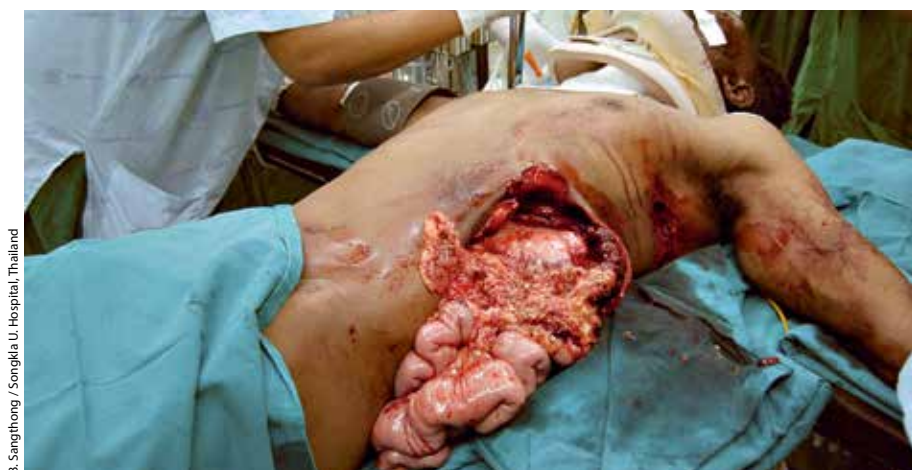In all reported cases of tangential wounds with intraperitoneal lesions, and in the experience of ICRC surgeons, the bullet has penetrated the deep fascia of the abdominal wall. Therefore, a "superficial" tangential wound of the abdomen should be diagnosed with reference to the deep fascia rather than the peritoneum. If the deep fascia has not been penetrated, the patient's wound can be safely diagnosed and treated as a "superficial" injury. This does not mean that absolutely all wounds penetrating the deep fascia require a laparotomy, but rather that the important clinical point the surgeon must remember is to recognize the possibility of a late presentation and advise the patient accordingly.

### 32.2.6 Primary blast injury

As described in Section 19.4.1, primary blast affecting a solid organ is rarely seen in survivors; most die of exsanguination shortly after injury. On the other hand, injury to a hollow viscus is well documented and seen especially after explosions occurring under water or in an enclosed space. Rupture of the testes has also been described. Most abdominal injuries, however, are due to the secondary blast mechanism of fragments.

Figure 32.3

Thoraco-abdominal evisceration due to bomb blast: survival is rare.



B. Sangthong / Songkila U. Hospital, Thailand

Immediate perforation is due to the direct effect of the pressure wave and most commonly affects the ileo-caecal region. Late perforation develops in stages. Changes begin and are most significant in the mucosal layer; they then spread centrifugally through the submucosal, muscular and serosal layers. The intramural haematoma leads to an area of ischaemia, then infarction, and finally necrosis with perforation.

Another mechanism of bowel ischaemia is the shearing force on the mesentery causing rupture and thrombosis of small vessels. Necrosis begins about 6 hours after injury and it usually takes three to five days for perforation to occur, but it can start as early as 24 hours or as late as 7 days.

A high degree of suspicion is necessary when diagnosing any early perforation and any late presentation. The important clinical observation at operation is that any serosal injury means that the entire intestinal wall is involved and the lesion requires debridement and repair.

Patients affected by a bomb explosion and discharged after observation without surgery should be given strict instructions to return to hospital immediately on the appearance of any abdominal signs or symptoms.

## 32.3 Epidemiology

### 32.3.1 Incidence of abdominal injuries

Given the large surface area of the abdomen, it comes as no surprise that about 20% of battlefield-injured patients suffer abdominal wounds. The immediate lethality of projectile abdominal wounds – about half the wounded die shortly after injury – means that about 10% of the patients brought to a hospital alive have wounds in the abdomen (see Table 5.6). The percentage may be much smaller where transfer to hospital is lengthy or where soldiers wear body armour.

#### ICRC EXPERIENCE

The actual incidence of hospitalized patients suffering from abdominal wounds depends on a number of factors, particularly in a civilian context.

The ICRC field hospital in Beirut in 1976 was obliged to treat many patients on an ambulatory basis for security reasons; they would have been hospitalized under different circumstances. In addition, most penetrating head injuries were transferred to other Beirut hospitals. As a consequence, 26% of the 505 hospitalized patients were admitted for abdominal wounds and underwent a laparotomy, a far higher percentage than what would normally be expected. Indeed, the ICRC hospital had become a local referral centre for patients suffering abdominal injuries.

### 32.3.2 Mortality

Mortality figures for abdominal wounds in the surgical literature suffer from all the problems of methodology, definition, and data collection described in Chapter 5: superficial injuries and negative laparotomies included or not, for example. Data collection is certainly neither uniform nor standardized.

Nonetheless, a broad and clear trend has emerged, thanks to improved medical care and a more aggressive surgical approach. General post-operative mortality has decreased from around 67% in the late stages of World War I to 25% in World War II, down to 12% for US medical services in Korea and 8.5% in Viet Nam. Various more contemporary studies report between 10% and 15% mortality. Only well-structured military services with forward surgical teams and rapid evacuation of patients achieve lower rates. Table 32.1 gives an indication of peri- and post-operative mortality, both military and civilian, in widely differing tactical situations and with very different evacuation systems.

Conflict / Source	Number of laparotomies	Post-operative mortality
<b>CLASSICAL ARMIES</b>		
USA – Viet Nam 1966 – 67; American military hospitals Hardaway, 1978.	1,350	4.5%
Israel – Egypt 1973; Israeli military hospitals Kleinman & Rosin, 1979.	151	20% at forward hospital 5% after transfer to rear hospital
<b>URBAN CONFLICT</b>		
Chad 1980; Mission humanitaire française Dumurgier et al., 1982.	210	22.5%
Lebanon 1975 – 86; American University of Beirut Medical Center Nassoura et al., 1991.	1,314	9.5%
Bourj el-Barajneh refugee camp, Beirut 1985 – 87; Palestine Red Crescent Society hospital Cutting & Agha, 1992.	69	17.4%
Former Yugoslavia 1991 – 1995; Karlovac General Hospital, Croatia Šikić et al., 2001.	93	10.8%
Gaza Strip 2000 – 03; Shifa Hospital Kandil, 2005.	230	7.4%
Mosul, Iraq 2006; Al-Jumhuri Teaching Hospital Borhan & al-Najafi, 2008.	153	33.3%
<b>RURAL GUERRILLA CONFLICT</b>		
USA – Viet Nam 1966 – 67; Bien Hoa Provincial Hospital Dudley et al., 1968.	28	14.3%
Zimbabwe – Rhodesia 1976 – 78; Harare Central Hospital Dent & Jena, 1980.	110	19%
Eritrea 1980 – 82; Eritrean People's Liberation Front hospitals Fekadu, 2006.	692	16.8%
Afghanistan 1989 – 90; ICRC hospital Kabul Morris & Sugrue, 1991.	70	14.5%

**Table 32.1 Post-operative mortality in a number of contemporary conflicts. Source references are to be found in the Selected bibliography.**

The major and most immediate cause of death is haemorrhage. Many casualties, however, have only intestinal or urinary tract injuries; septic peritonitis develops within six to eight hours, but takes much longer to kill the patient. The main source of infection is the bacteria in the gastro-intestinal tract. A second source is brought in by foreign bodies and other contaminants, defects in the abdominal wall, or prolonged evisceration and exposure of the intestines.

The two main syndromes seen in abdominal injury:  
haemorrhagic and peritoneal.

The principal causes of death: haemorrhage and septic shock.

Today, death within the first 24 hours is still primarily due to haemorrhage and irreversible shock, but with improved pre-hospital and operative care death now occurring between 24 and 48 hours after injury is usually due to hypothermia, acidosis, and coagulopathy. After 48 hours, peritonitis and septicaemia predominate as the cause of death. The critically injured patient, who has managed to survive long enough, may later succumb from multiple organ failure.

### 32.3.3 Mortality risk factors

Mortality depends on a large number of factors which inevitably make an amalgamation of “abdominal wounds” inconsistent. Besides purely aetiological and medical factors, there are always those associated with poverty and limited resources: malnutrition, lack of blood, inadequate pre-hospital care and evacuation, and precarious working circumstances.

- Mechanism of injury: high-energy projectiles are often rapidly fatal. The majority of patients with abdominal lesions reaching hospital alive will have been injured by low-energy missiles. Primary blast affecting the parenchymatous organs leaves few survivors.
- Pathophysiological status: haemorrhagic or septic shock.
- Specific organ injured: exsanguinating haemorrhage is an obvious consequence of a significant injury to the major vessels or solid organs. Colorectal injuries are found in up to 85% of the patients who die. Injuries to the ureter and bladder are often missed, resulting in delayed diagnosis and sepsis.
- Extent of tissue damage: the severity is an indication of the effective transfer of kinetic energy to the tissues.
- Number of organs injured: once the number reaches three or more, the rate of complications and mortality rises exponentially.
- Associated injuries: 50 to 60% of the patients suffering abdominal wounds have associated injuries with a higher mortality rate; between 15% and 25% suffer thoraco-abdominal injuries.

### 32.3.4 Frequency of organ injuries

As mentioned, there are two major syndromes associated with abdominal injury: haemorrhagic and peritoneal. There is a remarkable difference in the relative frequency of these presentations between civilian studies in industrialized countries and statistics from the battlefield, where delay in evacuation is common. This is also evident in studies of armed conflict where first aid and transport are very efficient, especially during urban conflict or with forward projection of field surgery where evacuation times can be very short.

In general, the small intestines are injured in about half the patients, the colon in about a third, and the liver in about one quarter. Tables 32.2.1 – 32.2.3 present the frequency of injury to various organs in very different tactical situations.

Conflict / Source	USA – Viet Nam 1966 – 67 Hardaway, 1978.	Israel – Egypt 1973 Kleinman & Rosin, 1979.*	
		Forward hospital	Rear hospital
Number of laparotomies (Positive findings)	1,350 (1,751)	30 (91)	121 (165)
Liver	16.4 %	8.8 %	15.2 %
Gall bladder & extra-hepatic	–	0	4.8 %
Major vessels	1.5 %	3.3 %	4.2 %
Minor vessels	–	–	–
Spleen	9.1 %	13.2 %	14.5 %
Stomach	7.4 %	8.8 %	4.2 %
Pancreas	1.5 %	3.3 %	3 %
Duodenum	25.9 %	5.5 %	3 %
Small intestine		15.4 %	15.8 %
Colon	25.4 %	20.9 %	26.1 %
Rectum			
Kidney	7.8 %	15.4 %	5.5 %
Ureter	1 %	0	1.2 %
Bladder	2.6 %	4.4 %	1.2 %
Urethra	1.4 %	0	1.2 %
Adrenal	–	1.1 %	0
Bone	–	–	–
Diaphragm	–	–	–

\* Forward evacuation hospital operating only on the most critically injured with imminent threat to survival. Others evacuated to rear hospital.

**Table 32.2.1 Significant organ injuries found at laparotomy; percentage of total positive findings: classical armies.**

Conflict / Source	Chad 1980 Dumurgier et al., 1982.	Lebanon 1975 – 86 Nassoura et al., 1991.	Bourj el-Barajneh, Beirut 1985 – 87 Cutting & Agha, 1992.	Former Yugoslavia 1991 – 95 Šikić et al., 2001.	Sarajevo 1992 – 96 Versier et al., 1998.	Gaza 2000 – 03 Kandil, 2005.	Mosul, Iraq 2006 Borhan & al-Najafi, 2008.
Number of laparotomies (Positive findings)	210 (319)	1,314 (2,208)	69 (133)	93 (190)	72 (128)	230 (419)	130 (257)
Liver	10.7 %	14.3 %	12.8 %	9.5 %	8.5 %	8.8 %	10.9 %
Gall bladder & extra-hepatic	0	2 %	1.5 %	0	0	0.5 %	2.7 %
Major vessels	0.8 %	2.5 %	5.3 %	4.2 %	0	8.8 %	3.5 %
Minor vessels	–	–	–	–	–	–	9.7 %
Spleen	7.3 %	6.2 %	6 %	4.7 %	5.1 %	6.2 %	4.3 %
Stomach	6.5 %	9.3 %	7.5 %	8.4 %	5.1 %	10.5 %	4.7 %
Pancreas	1.7 %	2 %	2.3 %	3.7 %	5.1 %	2.6 %	1.2 %
Duodenum	2.5 %	24.7 %	1.5 %	2.1 %	15.2 %	26.7 %	2.3 %
Small intestine	30.5 %		27.1 %	27.9 %			21.4 %
Colon	18.6 %	21.2 %	16.5 %	28.4 %	22 %	17.9 %	18.7 %
Rectum & anus	2.5 %		1.5 %		10.2 %		
Kidney	5.1 %	6.1 %	10.5 %	4.7 %	10.2 %	5 %	3.9 %
Ureter	0.6 %	0.9 %	0	1.6 %	1.7 %	0	1.9 %
Bladder	1.7 %	2.8 %	3 %	4.7 %	3.4 %	3.6 %	2.3 %
Urethra	0.6 %	0		–	0	–	0
Uterus & adnexae / Gonads	0.8 %	0	0.8 %	0	1.7 %	1.7 %	0
Bone	–	–	–	–	–	–	5.1 %
Diaphragm	9.9 %	7.9 %	3.8 %	–	11.7 %	7.6 %	7.4 %

**Table 32.2.2 Significant organ injuries found at laparotomy; percentage of positive findings: urban conflict.**



Conflict / Source	USA – Viet Nam 1966 – 67 Dudley et al., 1968.	Zimbabwe – Rhodesia 1976 – 78 Dent & Jena, 1980.	Eritrea 1980 – 82 Fekadu, 2006.	Afghanistan 1989 – 90 Morris & Sugrue, 1991.
Number of laparotomies (Positive findings)	28 (49)	110 (206)	692 (1,126)	70 (114)
Liver	6.1%	8.7%	15.1%	14.9%
Gall bladder & extra-hepatic	0	1.5%		0.9%
Major vessels	2%	4.4%	–	2.6%
Minor vessels	2%	–	–	–
Spleen	8.2%	3.4%	5.2%	0.9%
Stomach	4.1%	5.3%	5.2%	8.8%
Pancreas	4.1%	0.5%	1.9%	0
Duodenum	2%	1.9%		28.9%
Small intestine	30.6%	30.1%	32.6%	30.7%
Colon	20.4%	29.1%	23.6%	
Rectum & anus	2%		1.9%	
Kidney	0	3.9%	2.1%	4.4%
Ureter	0	0		0.9%
Bladder	6.1%	4.9%	4%	2.6%
Urethra	0	0		0
Uterus & adnexae / Gonads	2%	0	1%	0
Bone	–	–	–	–
Diaphragm	10.2%	6.3%	6.5%	4.4%

**Table 32.2.3 Significant organ injuries found at laparotomy; percentage of positive findings: rural guerrilla conflict.**

	Most commonly injured organ.
	Second most commonly injured organ.

Only about 10% of abdominal injuries involve the perineum, buttocks or thighs which are particularly vulnerable to APM blast mines; and another 10% involve primarily the lumbar region or retroperitoneal space. The iliac vessels are at particular risk, either from the wounding projectile itself or from bone fragments. Obviously, perineal wounds may also involve the external genitalia.

### 32.3.5 Negative and non-therapeutic laparotomy

A negative laparotomy refers to patients who undergo a laparotomy on the suspicion of intraperitoneal injury, and in whom there are *no* significant findings. Usually, the trajectory of the projectile is tangential and no penetration of the peritoneum has occurred. More rarely, the bullet or piece of shrapnel penetrates and is found floating free in the peritoneal cavity without having injured any organ.

A non-therapeutic laparotomy is different: while it includes the former, it also describes patients who suffer an intra-abdominal injury the extent of which does not require a surgical repair, for example a liver injury not requiring suturing. Historically, the rate of negative or non-therapeutic laparotomy varies greatly, from a few per cent to as many as 20%, as described in Table 32.3.

Study	Number of laparotomies	Negative exploration
Hardaway, 1978.	1,350	19.2 %
Kleinman & Rosin, 1979.	121	10.7 %
Dent & Jena, 1980.	110	3.6 %
Dumurgier et al., 1982.	210	4.8 %
Nassoura et al., 1991.	1,314	9.7 %
Cutting & Agha, 1992.	69	2.9 %
Morris & Sugrue, 1991.	70	11.4 %
Šikić et al., 2001.	93	4.3 %
Kandil, 2005.	230	6.5 %
Borhan & al-Najafi, 2008.	153	15 %
Dudley et al., 1968.	28	7.1 %
Fekadu, 2006.	692	11.8 %

Table 32.3 Frequency of negative laparotomies in a number of contemporary conflicts.

An influx of mass casualties tends to result in a higher level of negative laparotomies. There is not enough time to implement a full diagnostic protocol and there is “pressure” to start clearing patients.

### 32.3.6 Role of the wounding mechanism

The lethality of the various wounding agents has often been described (see Section 5.7.4). Numerous studies show that, for patients treated in the same hospital and thus all other factors being equal, the mortality rate for abdominal wounds is three to four times higher with high-kinetic energy bullets than with low-energy bullets and fragments. Comparison with primary blast injury must also be taken into consideration, but is rendered more difficult because most survivors of explosions also suffer from fragment injuries: a secondary blast effect. Nonetheless, there is a notable difference in severity between a simple fragment wound and one suffered within the radius of the primary blast effect.

Two studies are exemplary in their comparison of different wounding mechanisms with respect to abdominal injuries. Both were conducted in an urban environment with relatively short evacuation times and involved a major referral hospital.

During the Lebanese civil war, one study from the American University Hospital in Beirut compared two groups of patients with abdominal injuries, due to fragments in the one group (presumed to be low-kinetic energy) and to gunshot wounds in the other (presumed to be high-kinetic energy). Table 32.4 sums up the results.

Indicator	Group A: fragments n = 133	Group B: GSW n = 166	Significant
Negative laparotomy	11.3 %	5.4 %	p < 0.05
Mortality	2.3 %	7.2 %	p < 0.01
Post-operative complication rate	7.5 %	8.4 %	NS
Number of intra-abdominal organs injured: excluding major vessels	1.56	2.05	p < 0.05
Associated extra-abdominal injuries	26 %	21 %	p < 0.05

Table 32.4 Comparison of various indicators between patients with abdominal wounds caused by fragments versus GSW. <sup>1</sup>

The negative laparotomy rate was greater with fragment wounds, thus confirming first the idea that in survivors these injuries are of low kinetic energy, and second the difficulty in ascertaining the occurrence of peritoneal penetration or not in such patients. Bullets tend to have higher kinetic energy, leading to more severe overall injuries with a higher mortality rate but lower negative laparotomies because the abdominal signs and symptoms tend to be more pronounced and easier to diagnose.

<sup>1</sup> Adapted from Georgi BA, Massad M, Obeid M. Ballistic trauma to the abdomen: shell fragments versus bullets. *J Trauma* 1991; **31**: 711 – 715.

Another study from the Hadassah University Hospital in Jerusalem compared abdominal injuries according to the aetiology: blunt, gunshot and blast following bomb explosions.<sup>2</sup> The first observation is the much higher frequency of abdominal injuries incurred with the weapons of war. The second is that blast causes the most severe overall injury. Blast and blunt injuries tend to involve the entire body with a more diffuse transfer of energy, while gunshot wounds represent a concentrated transfer of kinetic energy along the projectile's trajectory. More than 85% of blast and 60% of blunt trauma victims had injuries to two or more regions apart from the abdomen, in contrast to less than 30% for GSW. In this series, however, post-operative complications and the mortality rate (19%) were similar in all three groups.

### 32.3.7 Scoring systems

Several scoring systems have been devised in an attempt to quantify the severity of abdominal trauma: abbreviated injury scale (AIS), the penetrating abdominal trauma index (PATI), etc. These can be rather complicated and require good administrative clerical support, which is not readily available where resources are limited.

In the Red Cross Wound Score system,  $V = A$  if there is peritoneal penetration. The RCWS attempts to refer tissue damage to the effective transfer of kinetic energy and, consequently, organ damage from the cavitation effect without peritoneal perforation counts as a positive. It does not include organ injury from primary blast since this score only refers to penetrating injuries.

The RCWS leaves much to be desired when dealing with vital injuries, as noted in Section 4.5. For wounds of the abdomen, no attempt is made to differentiate the extent of damage sustained by an organ or the number of organs affected. Nonetheless, empirically, the system does provide a quick and simple method of grading abdominal wounds that appears to have some prognostic value.

#### ICRC EXPERIENCE

A study of patients listed in the ICRC war-wounded database looked at 335 patients with isolated abdominal wounds and 195 with isolated pelvic wounds; those wounded in multiple regions were excluded.<sup>3</sup> Among the 530 abdominal or pelvic wounds, 48.5% did not have peritoneal penetration or organ injury ( $V = 0$ ). Among the patients with a  $V$  component, Grade 2 wounds ( $n = 106$ ) were more lethal than Grade 1 ( $n = 167$ ): 14.2% versus 6.6%, which is statistically significant.

Only 11 patients presented with isolated Grade 3 wounds and they all survived. Their survival is readily explained by the more or less tangential nature of the injury causing a large wound in the abdominal wall with only moderate kinetic energy affecting the abdominal contents. It is assumed that most casualties with Grade 3 wounds involving important abdominal organs died before reaching hospital.

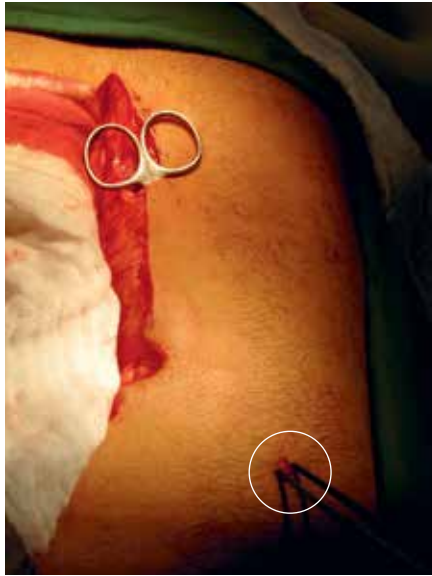2 Bala M, Rivkind AI, Zamir G, Hadar T, Gertsenshtein I, Mintz Y, Pikarsky AJ, Amar D, Shussman N, Abu Gazala M, Almogy G. Abdominal trauma after terrorist bombing attacks exhibits a unique pattern of injury. *Ann Surg* 2008; **248**: 303 – 309.

3 Coupland R. Abdominal wounds in war. *Br J Surg* 1996; **83**: 1505 – 1511.

## 32.4 Clinical presentations

### 32.4.1 Diagnosis

The important issue is not to determine pre-operatively the exact extent of intra-abdominal injury or which organ is injured, but rather to decide whether or not surgery is warranted.



ICRC

**Figure 32.4**

Difficulty in diagnosis: a patient suffered fragment injuries to the thigh, foot, forearm and hand from a bomb blast. In addition, there was a small wound in the epigastrium; however, the abdomen was soft, not tender, and bowel sounds were present. The patient was not cooperative and it was decided to explore. During the laparotomy incision, the surgeon noticed a small nodule in the subcutaneous tissue. The scissors have been passed through the fragment track and the tip of the forceps indicates the site of the fragment. Clinical examination had not been meticulous.

Abdominal diagnosis in war surgery:  
the decision to operate, or not to operate.

Meticulous clinical examination is essential but can be difficult in the presence of a depressed level of consciousness due to severe shock, an associated head injury, or intoxication. Moreover, extraperitoneal injuries can cause diagnostic ambiguities: even a non-significant retroperitoneal haematoma may cause abdominal tenderness because irritation of the posterior peritoneum can be projected anteriorly, whereas diagnostic delay can result from injuries to retroperitoneal structures such as the duodenum, rectum, bladder or ureters.

Furthermore, a patient with wounds due to multiple fragments tends to have intra-abdominal lesions if more than three body regions are injured: an important indicator in triage situations.

### 32.4.2 Presenting syndromes

As demonstrated in the discussion of epidemiology, there are two large cohorts of patients: those presenting with a haemorrhagic syndrome and those with a peritoneal syndrome. Many patients have injuries to both parenchymatous and hollow viscera, but one syndrome usually predominates. It should be noted that a small amount of blood can also provoke a response of peritoneal irritation – peritonism – but this is usually overshadowed by the symptoms due to the haemorrhage if it is at all extensive. Two subgroups of patients have little or no presenting symptoms on arrival at hospital: minimal bleeding has stopped or holes in the bowel are covered by fibrin with little contamination.

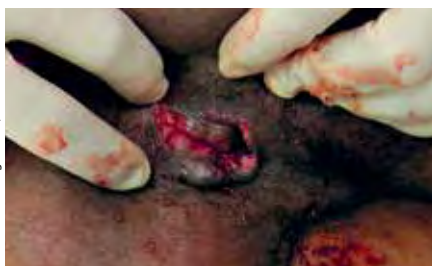There is another small cohort of patients with injury to hollow viscera who usually present late and do not have a picture of frank peritonitis. They may have suffered a small extraperitoneal perforation of the colon, rectum, bladder or ureter with sequestration of faecal or urinary spillage in a small space giving few generalized clinical signs. Primary blast injury and cavitation effect that have produced delayed perforation also present late, but demonstrate a syndrome of peritonitis.

### 32.4.3 Clinical examination

After dealing with the airway and breathing, and any circulation problems from peripheral haemorrhage, the surgeon's attention should focus on the abdomen where circulation is the most important component.

The complete examination of the abdomen must include the following elements.

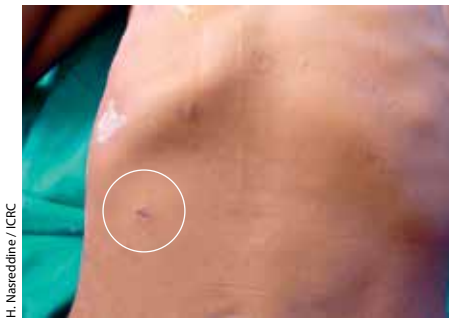1. Careful examination of the *front and back* of the abdomen, chest, perineum, buttocks and upper thighs.
2. Recording the *number and nature* of the wounds; this may vary from multiple small punctate holes, to a single gaping entry wound, and even to evisceration of intra-abdominal organs.
3. Estimation of the projectile's *trajectory* to determine the probability of deep fascia or peritoneal penetration.



F. Phani / C.H. Baragwanath, S. Africa

**Figure 32.5**

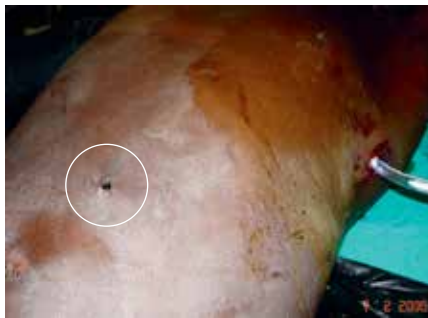Perineal gunshot wound.



H. Nareddine / ICRC

**Figure 32.6**

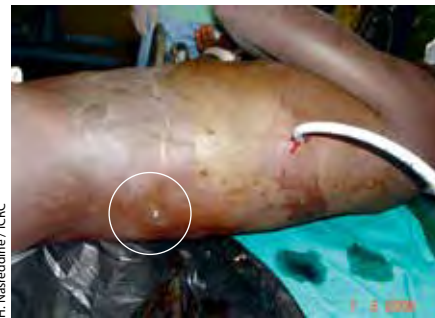Non-penetrating fragment wound in the right hypochondrium.



H. Nareddine / ICRC

**Figures 32.7.1 and 32.7.2**

Penetrating thoraco-abdominal gunshot wound.

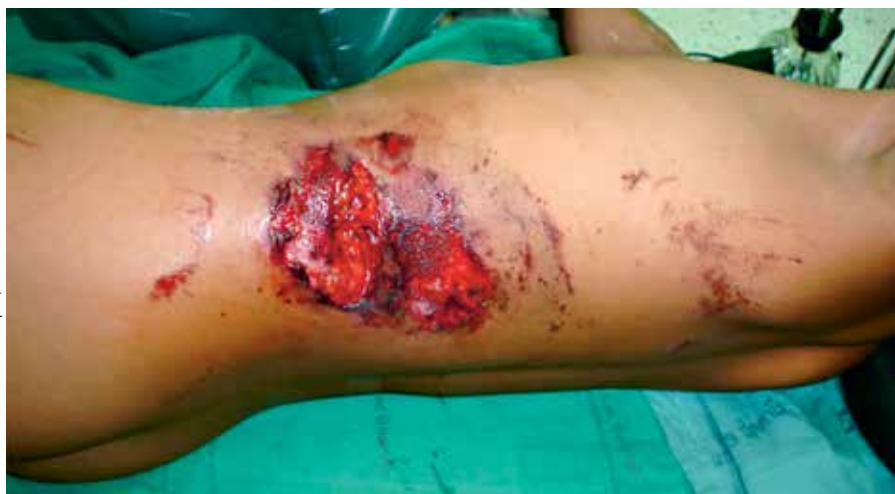

H. Nareddine / ICRC

**Figure 32.8**

Blunt injury to the flank: tertiary blast effect after a bomb explosion.

4. Consideration of the possibility of a *closed abdominal injury*, caused by primary blast injury or blunt trauma if the patient was blown over by an explosion.



R. Saleah / Pattani Provincial Hospital, Thailand

Observation, palpation, percussion and auscultation all play an important role in determining the presence of intra-abdominal injury. A rectal examination (PR) may show blood on the examining finger.

A urinary catheter should be placed, with the standard precautions for urethral injury in the event of any perineal haematoma, and the urine checked for gross haematuria. The naso-gastric tube should also be checked for the presence of blood.

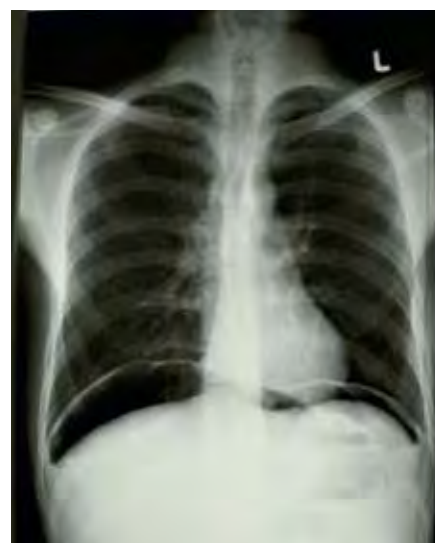#### 32.4.4 Paraclinical investigations

Haemodynamically unstable patients require only a minimum of pre-operative tests: haemoglobin, blood grouping, and urine pregnancy test for women. Performing these should not delay surgical treatment. Plain radiographs of the chest and abdomen should be performed only if time allows.

In the stable patient, erect and lateral decubitus plain X-rays of the abdomen should be taken to look for projectiles and intraperitoneal free air. An erect X-ray of the chest should be taken as well. Whether an intravenous pyelogram (IVP) is undertaken or not depends on the capacity of the hospital and clinical condition of the patient.

*Wound exploration* performed under local anaesthesia can be a simple and effective means to diagnose or rule out peritoneal penetration but should not be performed as a routine. Wound exploration is justified in GSW *only* when the trajectory appears to be tangential and in fragment wounds that appear to be superficial.

If intraperitoneal injury can be ruled out on clinical grounds, blood on PR or a wound trajectory involving the pelvis calls for examination by *anal speculum*. Otherwise, just like sigmoidoscopy, it is not necessary.



ICRC

**Figure 32.9**

GSW of the abdomen: intraperitoneal free air under both cupulae of the diaphragm.

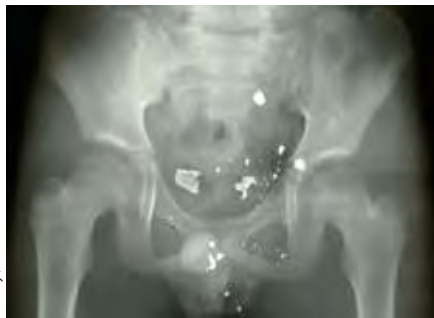

Figure 32.10

Disrupted bullet indicating a large transfer of kinetic energy and severe damage to the tissues.

*Focused Assessment Sonography in Trauma (FAST)* is a non-invasive screening tool; it has proven better for haemopericardium than for haemoperitoneum in which it has been found unreliable. *Diagnostic peritoneal lavage (DPL)* is of value in blunt trauma but is not needed for projectile injuries. In addition, it spreads any gastro-enteric contamination and does not detect retroperitoneal injuries. These techniques are not used in the practice of ICRC surgical teams.

*CT scanning* is not available when working with limited resources. However, even in situations where it is, it should never be used for an unstable or potentially unstable patient.

“All of these tests require clinical judgment. They cannot be used in isolation of other physical examination and laboratory findings. The eye scan – looking at the patient – and the finger scan – physical examination with the fingers – are both still a very important part of patient assessment.”

Dr Norman McSwain<sup>4</sup>

## 32.5 Emergency room management

The most important aspect of emergency room care for abdominal injuries is resuscitation and early disposition of the patient; the choice of strategy depends on the general physiological status.

### 32.5.1 Resuscitation

The haemorrhaging group comprises the patients who have bled significantly or are still actively bleeding. Death from haemorrhage depends to a large degree on the rate of blood loss. The therapeutic possibilities are limited for those with uncontrolled major bleeding and whose systolic blood pressure is less than 90 mm Hg; they require urgent surgery for resuscitation to succeed. The availability of blood for transfusion is essential and this may pose problems in a resource-poor environment. The surgeon may have to resort to intra-operative autotransfusion (see Section 34.5.2).

The basis of resuscitation = stop the bleeding.

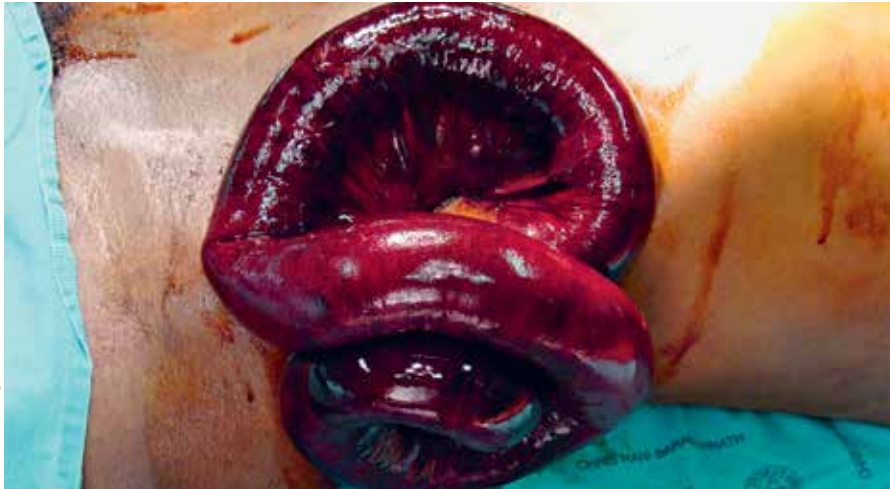Patients with ongoing, slow blood loss over several hours or who have stopped bleeding altogether are good candidates for hypotensive resuscitation (see Section 8.5.4). Hypotension decreases the amount of haemorrhage and tends not to dislodge any formed clot.

The peritonitis group suffers hypovolaemia from a number of causes: blood loss, third space sequestration of fluids, and simple dehydration. This is especially pronounced if there has been a delay in evacuation. These patients require i.v. fluids to improve their haemodynamic status and provide an adequate urine flow prior to anaesthesia. Further measures include supplemental oxygen, adequate analgesia, tetanus prophylaxis and antibiotics according to protocol.

4 Comment by Dr Norman E. McSwain Jr, (Professor, Tulane University School of Medicine, Trauma Director, Spirit of Charity Trauma Center, New Orleans, USA) on the surgical forum *trauma.org*, with permission.

### 32.5.2 Evisceration

Some patients may present with a small piece of omentum or loops of intestine protruding from the wound. Any extruded organs should be covered with a large moist compress or sterile towel; no attempt should be made to put them back into the abdominal cavity.



F. Plani / C.H. Baragwanath, S. Africa

**Figure 32.11**

Severe case of evisceration with strangulation and ischaemia of the bowel.

### 32.5.3 Impalement

A patient may present with a projectile, a knife, bayonet, or other object impaled in the abdomen. The foreign body should not be removed and no force should be placed upon it. It must be immobilized *in situ* until the patient is taken to theatre. The distal pulses should be checked.

Immobilization of the object can be accomplished by surrounding it with bulky bandages (laparotomy packs or dressings used for amputation stumps) and then protecting these with a scaffold made of a simple cardboard box large enough to cover the dressings. The box is held in place by cutting "V-notches" into its upper edges and tying a bandage passing through them, over the box, and under the patient.



C. Giannou / ICRC

**Figure 32.12**

Cardboard box scaffolding to immobilize a penetrating object.

## 32.6 Decision to operate

“Penetrating injuries below the nipples, above the symphysis pubis, and between the posterior axillary lines must be treated as injuries to the abdomen and mandate exploratory laparotomy.”

D.E. Lounsbury et al.<sup>5</sup>

The general approach to abdominal war wounds has become mandatory exploration, an approach favoured by many surgeons. The common-sense exception, with little or no ambiguity, is the patient who reaches hospital several hours or even days after injury and who is and remains clinically asymptomatic.

### ICRC EXPERIENCE

In 1985, ICRC surgeons working in Quetta (Pakistan) in a hospital for Afghan war-wounded, received many patients several days after injury, including 17 with intra-abdominal wounds. “In five patients penetrating foreign bodies could be demonstrated intraperitoneally in the abdominal cavity. As these injuries were several days old and the patients had no clinical signs of continuous bleeding or infection they were treated conservatively and discharged after some days of observation. One old subphrenic abscess was drained.”<sup>6</sup>

Indeed, some patients with very recent abdominal wounds remain asymptomatic and, as a consequence, the basic war-surgery principle of mandatory exploration has been called into question in recent years in civilian practice. An expectant and non-operative approach has thus gained favour, in the attempt to avoid a negative laparotomy which is not without its complications.

A more conservative approach to laparotomy depends to a large degree on the “active process” of good monitoring of selected patients by the nursing staff and serial examinations by the attending surgeon. The availability of sophisticated diagnostic technology makes this approach easier.

The aim of the surgeon working with limited resources and under precarious circumstances should be never to miss an injury and not delay diagnosis, while maintaining the rate of negative laparotomy as low as possible. This requires good clinical judgement since, as described, a penetrating wound by a high energy FMJ bullet is not the same as one caused by a small fragment.

Do the best under the existing circumstances. The best is defined as no missed injuries with the fewest possible negative exploratory laparotomies.

There are definite advantages to mandatory laparotomy, apart from a low rate of missed injuries and no delay in diagnosis: the surgeon’s mind is put at ease – very important for the harried and tired surgeon who needs sleep, not knowing when the next arrival of mass casualties will occur.

However, there are also disadvantages to mandatory laparotomy. There can be a substantial rate of non-therapeutic operations, with the possibility of unwarranted complications. Operating theatre facilities, time, equipment and personnel are used unnecessarily, a particularly important consideration when receiving a mass influx of wounded.

5 Lounsbury DE, Brengman M, Belamy RF, eds. *Emergency War Surgery Third United States Revision*. Washington, DC: Borden Institute, US Department of Defense; 2004.

6 Rautio J, Paavolainen P. Afghan war wounded: experience with 200 cases. *J Trauma* 1988; **28**: 523 – 525.



### 32.6.1 Criteria for consideration

In addition to frank presentations of haemorrhagic shock or peritonitis, certain conditions calling for a laparotomy are clear-cut:

- the presence of free air in the peritoneal cavity on plain X-ray;
- difficulty in performing proper abdominal examination: thoraco-abdominal injury with compromised breathing, an associated spinal cord or head injury, etc.

In a mass-casualty triage situation, the stable patient with an abdominal wound should be placed in Category II and wait for surgery in any case. The attendant delay allows time for any injury to develop clear symptoms. The haemorrhaging patient is clearly a Category I.

#### Old lesson for new surgeons

When in doubt, *look* and see rather than *wait* and see, especially when working with limited resources.

In principle and in general, all penetrating abdominal wounds should be explored, and as soon as possible, especially in resource-poor settings. The mortality of a negative laparotomy is near-zero whereas an unoperated intra-abdominal injury can be fatal.

## 32.7 Preparation of the patient and anaesthesia

A laparotomy is a major operation requiring the full range of OT staff. The anaesthetist may require an “extra pair of hands”, especially if autotransfusion is to be performed. The surgeon may not only require one “extra pair of hands”, but perhaps two if extended retraction of the abdominal wall is to be accomplished.

1. The patient is placed supine with both arms abducted. The operation site is prepared so that the incision can be extended upwards to the thorax and downwards to the groin in case a saphenous vein graft is needed. The field is draped from the xyphoid to the pubis.
2. Good muscle relaxation is essential for good abdominal surgery. This can be accomplished even with ketamine anaesthesia, muscle relaxants and intubation. In extreme circumstances, spinal anaesthesia combined with local infiltration of the abdominal wall has been used successfully.
3. As many intravenous lines as necessary should be placed in the upper limbs or external jugular vein.
4. The anaesthetist should activate the system for providing blood for transfusion before the operation begins.
5. When working with limited blood resources, transfusions should be administered only once haemorrhage has been controlled (see Section 8.6). The material necessary for autotransfusion should be made ready (see Section 34.5.2).
6. Prolonged laparotomy for haemorrhage is notorious for pushing the patient into hypothermia, acidosis and coagulopathy. The recording of the temperature during operation has not been the usual practice in hospitals with limited resources; the anaesthetist should *regularly* record the patient’s temperature as well as the routine blood pressure and pulse measurements. A proper thermometer reaching below 35° C is necessary; if not available, once the mercury drops below the 35° C mark, the surgeon and anaesthetist should only continue operating with great caution.

## 32.8 General plan of surgery

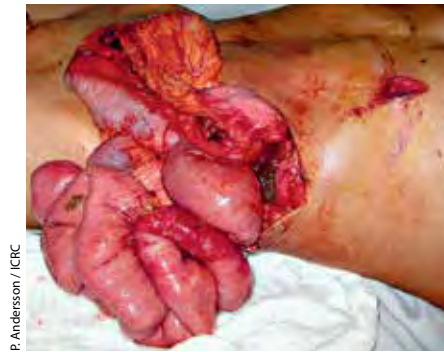Whether the surgeon is performing a “routine” laparotomy or one *in extremis*, a certain number of basic operative gestures should be carried out. This Section deals with general principles. The treatment of individual organs is discussed in subsequent Sections.

### 32.8.1 Incision

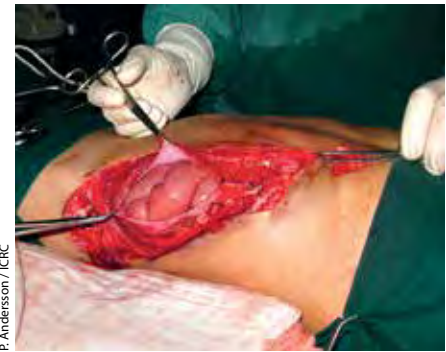A midline xyphoid to pubis incision is preferred. This is rapidly performed and provides excellent access. As a general rule, an extension of the abdominal wound itself is used only in the case of a large defect in the abdominal wall where the midline incision would compromise the vascularity of the intervening tissues. Furthermore, separate abdominal and thoracic incisions are preferred to a thoraco-abdominal incision.

Figures 32.13.1 – 32.13.4

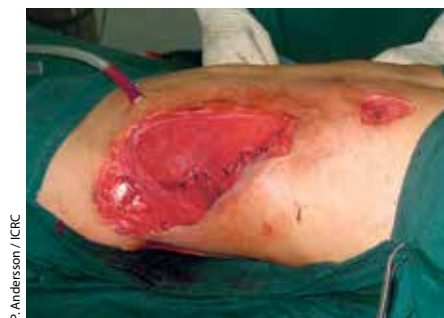Tangential wound with evisceration: the laparotomy was performed through an extension of the wound because a midline incision would have compromised the vascularity of the intervening segment of the abdominal wall.



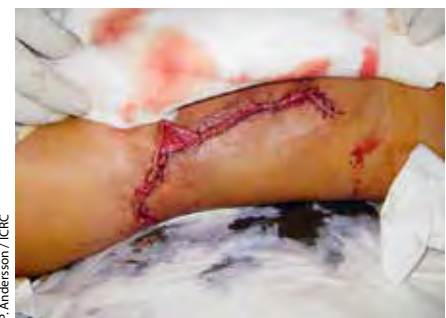P. Andersson / ICRC



P. Andersson / ICRC



P. Andersson / ICRC



P. Andersson / ICRC

### 32.8.2 Exploration

The surgeon should follow a *routine* for the proper exploration of the contents of the abdomen to inspect all intraperitoneal and retroperitoneal organs. Missed injuries can prove fatal for the patient. Obvious haemorrhage must be controlled first. If there is no overt bleeding, the surgeon should pass a hand quickly over the liver, spleen and, pulling the intestines first towards him and then away, inspect the retroperitoneum. Attention then turns to any contamination by a meticulous inspection of the entire gastro-intestinal tract. If the injury is thoraco-abdominal, a chest tube should have been placed prior to laparotomy; if not done, one is inserted intra-operatively and the diaphragm repaired to re-establish proper ventilation.

Once exploration of the peritoneal cavity has been accomplished, further control of haemorrhage and contamination and definitive repair depend on the physiological status of the patient. The vast majority of patients are sufficiently stable for the surgeon to proceed normally with the operation.

#### Haemorrhagic syndrome

Stop the bleeding, by direct ligation or by damage-control procedures if necessary. Then inspect the liver, spleen, retroperitoneum and mesenteric vessels.

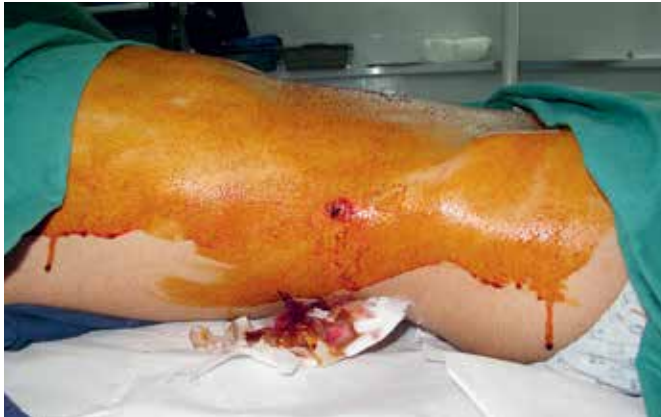#### Peritoneal syndrome

Meticulously inspect – centimetre by centimetre – the entire gastro-intestinal tract, including the retroperitoneal duodenum, colon and rectum.

### 32.8.3 Massive haemorrhage

The efficacy of resuscitation depends on stopping the haemorrhage. The haemodynamically unstable patient with massive bleeding that is difficult to control except with temporary measures is the prime candidate for the damage-control approach of an abbreviated laparotomy. The key to successful damage control is to recognize the need *early* in the operation and to *quickly* perform only those procedures that are absolutely necessary. Speed is of the essence.

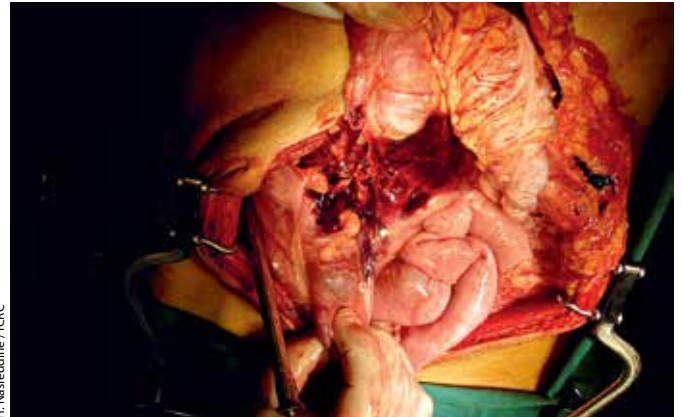
Massive intraperitoneal haemorrhage may occur from an organ or from a retroperitoneal haematoma involving the midline great vessels or kidney. The haematoma may be contained by a tamponade effect, in which case the patient is usually stable. However, when the surgeon enters the abdomen and decompresses the haematoma, free and massive bleeding may occur.



H. Nasreddine / ICRC

**Figure 32.14.1**

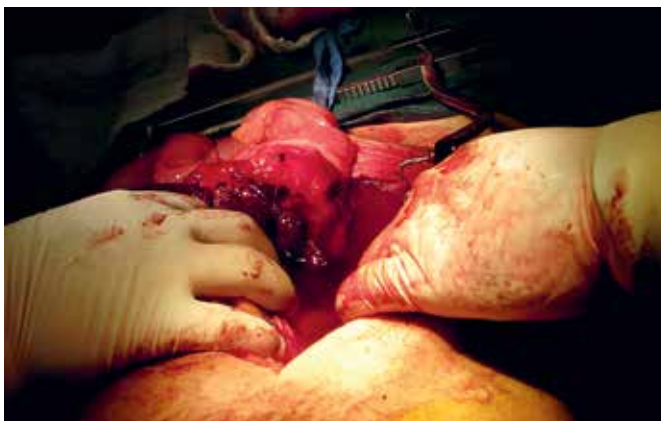The patient suffered a GSW to the right flank five hours before admission, at which point the BP was 110/70 and the pulse 78. The abdomen was soft and the bowel sounds present.



H. Nasreddine / ICRC

**Figure 32.14.2**

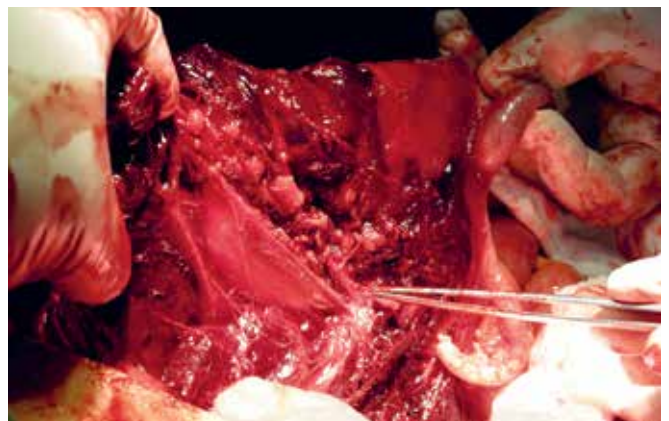
On opening the abdomen, a large retroperitoneal haematoma was seen in the infracolic area.



H. Nasreddine / ICRC

**Figure 32.14.3**

Manipulation resulted in decompression of the haematoma and brisk bleeding from the inferior mesenteric vessels.



H. Nasreddine / ICRC

**Figure 32.14.4**

Apart from the large haematoma in the root of the mesentery, shown in this photograph, there was a small perforation of the jejunum.

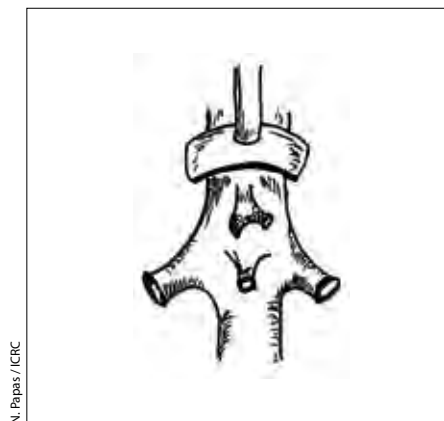
Lesions of the great vessels are usually fatal before arrival at hospital and are rarely seen in war surgery except at forward military hospitals and in urban combat. Still, there are some cases with retroperitoneal tamponade controlling the haemorrhage who do survive to operation. A severely ruptured liver or spleen may also have stopped bleeding by the time of arrival. Even so, this is difficult surgery and many patients die of exsanguination "on table". Large quantities of readily available blood for transfusion are necessary for any surgery to prove successful.

Obviously, in a mass casualty situation, patients suffering such injuries with significant hypotension are "triaged out" and do not proceed to surgery.


The exsanguinating patient with blood overflowing from the abdomen tends to cause everyone in the theatre to panic: the key is for the surgeon to stay calm, and

impose calm. Proper preparation of the OT staff is essential and must include adequate operative and anaesthesia assistance, blood for transfusion and material for autotransfusion, and proper vascular instruments and sutures.

If there is a gush of blood upon opening the abdomen the surgeon should use the “two-handed scoop” technique to quickly empty blood and clots (into a large basin or kidney dish if autotransfusion is to be performed) and then eviscerate the intestines rapidly. Bleeding from the liver or spleen is readily recognizable. Otherwise, the assistant applies digital pressure to the aorta and vena cava, proximally at the aortic hiatus below the left hepatic lobe and distally at the bifurcation, while the surgeon searches for the source of bleeding and applies direct pressure with either the fingers or a laparotomy pad. If the site of bleeding cannot be localized, the four abdominal quadrants are packed off with laparotomy pads, which also help to absorb remaining blood. The assistant’s digital pressure may be replaced by an abdominal retractor placed vertically or an aortic compressor.



**Figure 32.15.1**  
Aortic compressor.



**Figure 32.15.2**  
Compression using a Deaver abdominal retractor.

If the bleeding is retroperitoneal, several more pads are applied and compressed. Once dissection has exposed the great vessels, appropriate vascular clamps replace the assistant’s fingers or a ruptured kidney is removed. If it is the liver that is severely injured, it should be packed off and the Pringle manoeuvre applied before attacking the lesion. A ruptured spleen is controlled by immediate splenectomy.

Whatever the lesion, massive haemorrhage is either readily amenable to a simple procedure – ligation, splenectomy, or nephrectomy – or else, a damage-control approach should be adopted. Exploration of a contained retroperitoneal haematoma is dealt with in Section 32.11.

#### **32.8.4 Mild to moderate haemorrhage**

Most wounded patients who have survived transport to a hospital do not have life-threatening haemorrhage and the approach should be quick but systematic. The most common source is from a vessel in the small bowel mesentery or mesocolon, and ligation suffices. The next most common sources are the liver, spleen and the major divisions of the great vessels. Simple surgical measures for haemostasis are discussed in subsequent Sections.

#### **32.8.5 Controlling contamination**

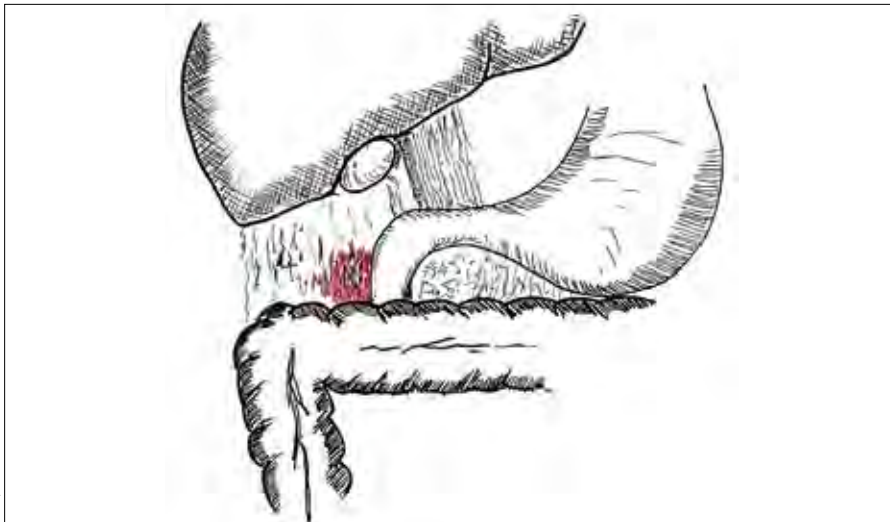On opening the abdomen the surgeon must make a mental note of any free intestinal contents in the peritoneal cavity and any faecal odour.

All viscera must be meticulously inspected.  
Any perforation, however small, can be fatal.

The entire alimentary tract must be carefully inspected from the abdominal oesophagus to the anal canal. The surgeon must find and treat all perforations. They may be very small and in unexpected places, but all are potentially fatal. Again, the surgeon should follow a logical routine for exploration: starting at the gastro-oesophageal junction and working down, then working backwards from the rectum to double-check. Definitive repair should wait until all lesions have been identified, but intestinal holes must be clamped to avoid further contamination.

A wound in the anterior surface of the stomach is often accompanied by a lesion of the posterior surface, which must be inspected by opening the gastro-colic omentum. The lesser sac must be inspected carefully for any injury to the pancreas.

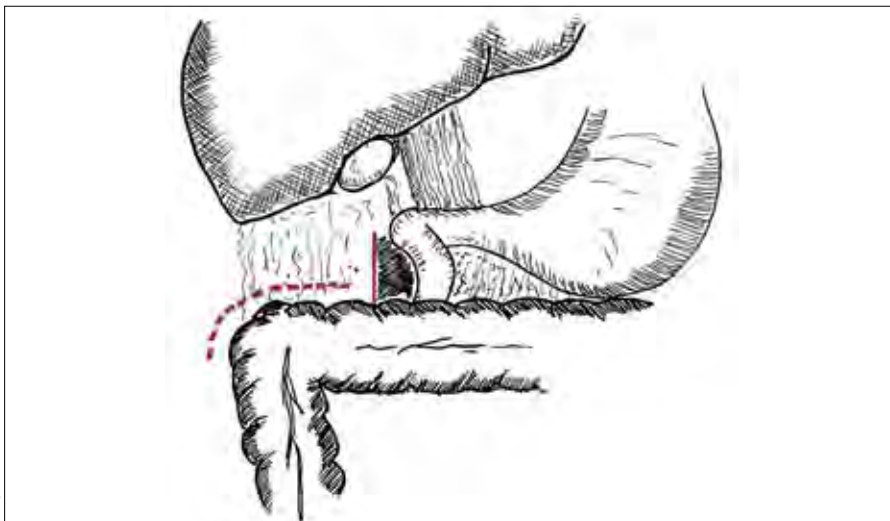
The surgeon then moves on to the duodenum, looking for any bile staining that might indicate pancreatic or duodenal injury. The Kocher manoeuvre is used to visualize the second part of the duodenum if necessary. Similarly, the third part is visualized by opening the mesocolic omentum and incising the duodenojejunal ligament.



**Figure 32.16**

Blood and bile staining in the triangle between the liver, the colon and the duodenum suggest a retroperitoneal pancreatic and/or duodenal lesion. Surgical emphysema may indicate a retroperitoneal colonic or duodenal injury.

N. Papas / ICRC



**Figure 32.17**

Kocher manoeuvre: the second part of the duodenum is mobilized via an incision in the peritoneum lateral to the duodenum. The duodenum is reflected medially so that the posterior surface can be inspected. The manoeuvre can be facilitated by first mobilizing the hepatic flexure of the colon (dotted red line).

N. Papas / ICRC

The small bowel is the most frequently injured organ. Its whole length must be examined centimetre by centimetre, from the duodenojejunal junction at the ligament of Treitz to the caecum, and backwards again. All injuries must be localized and marked with Allis or Babcock forceps, preferably over a surgical compress to protect the intestinal wall. Final repair should be postponed until all injuries have been located, since resection and anastomosis is preferable to multiple direct repairs. The mesentery must be checked carefully and any haematoma adjacent to the intestine unroofed and investigated.

The anterior surface of the colon is readily available for inspection. A retroperitoneal haematoma, emphysema in the area of the ascending or descending colon, or a faecal smell, must lead to careful examination for lesions to the retroperitoneal surface.

If necessary, the left and right colons are mobilized to expose the retroperitoneal surface for inspection. The integrity of the ureters must be checked at the same time.

A faecal smell may be the only indication of a colonic injury.

Finally, the uterus, rectum and urinary bladder should be examined. An extraperitoneal injury to the rectum or anal canal should have been diagnosed by PR prior to surgery. In addition, injury to the bladder should be suspected if bloody urine has been seen during the insertion of the urinary catheter. An intraperitoneal perforation of the bladder must be examined with a finger to search for an exit wound or a retained projectile. Extraperitoneal haematoma or surgical emphysema both require incision of the peritoneum lateral to the rectum and bladder for proper exploration of the surroundings.

### 32.8.6 Finishing and closure

At the end of the operation, the abdominal cavity is cleaned by thorough and copious irrigation with warm normal saline and the subhepatic and splenic spaces and pouch of Douglas sucked dry. Drains are placed as necessary.

#### Old lesson for new surgeons

No time should be wasted looking for projectiles!

The abdominal wall is closed preferably by a continuous mass suture including peritoneum and fascia. It is safe to close the skin if there has been minimal or no intestinal contamination. Otherwise, the skin and subcutaneous fat of the laparotomy incision should be left open for delayed primary closure.

Projectile wounds in the anterior abdominal wall are dealt with after the abdominal surgery; wounds in the *back must not be forgotten*. Missile entry and exit wounds must be well debrided and the peritoneum and fascia closed sufficiently to avoid herniation; the soft tissues should be left open for delayed primary closure.

Large defects may be difficult to close and rotation flaps may be necessary. Whether this is performed as a primary operation or delayed depends on the status of the patient. In some cases, the abdominal wall should be left to granulate and then covered with a split-skin graft.

## 32.9 Damage control: abbreviated laparotomy

Section 18.1.1 discusses damage control surgery in general terms. The basic idea is to abbreviate the initial laparotomy to prevent and overcome hypothermia, acidosis and coagulopathy. Continued resuscitation and aggressive correction of the “lethal triad” are undertaken in the intensive care unit to *restore the physiology*. The length of this second stage depends on the correction of the physiological parameters and can last 12 to 48 hours. The patient is then returned to the operating theatre for the third-stage definitive repair of injuries to *restore the anatomy*.

The patient who usually requires an abbreviated laparotomy is the one with massive bleeding that is difficult to control except with temporary packing or Foley catheter tamponade. The need to shorten the operation must be diagnosed early, before hypothermia and coagulopathy set in. Only procedures that are absolutely necessary to control haemorrhage and contamination, however temporarily, should be performed, and performed quickly. This is all the more necessary as exposure of the open peritoneum is the most important factor in the body’s continuing loss of heat. *Average heat loss* during laparotomy in the usual cold environment of an air-

conditioned operating theatre is 4.6° C per hour.<sup>7</sup> Irretrievable physiological damage may result after an operation lasting only 60 to 90 minutes.

Many other factors are involved in the development of the lethal triad, some of which are iatrogenic. The most common and easily correctable include the use of cold i.v. fluids and blood for transfusion and cold saline to wash out the abdomen. It is imperative to assume that hypothermia is likely to occur and to take the necessary measures to prevent it.

Proper damage control surgery requires the full panoply of readily-available blood for transfusion in ample quantity, an intensive care unit with mechanical ventilation and sophisticated patient monitoring, and specialized personnel in sufficient numbers. Where both human and material resources are scarce, it is probably better to speak of “resuscitative surgery with a damage-control approach”. The specific circumstances of the hospital determine to what extent the full damage-control approach can be entertained.

#### Basic principles of a damage-control approach

1. Rapidly expose and control haemorrhage by the most appropriate means.
2. Decide to implement a damage-control approach.
3. Pause the operation to allow anaesthesia to “catch-up” with resuscitation if necessary, including autotransfusion if feasible.
4. Control contamination temporarily by the most appropriate means.
5. Stop the operation.
6. Close the abdomen using an appropriate technique.
7. Transfer the patient to an intensive nursing ward.
8. Keep the patient warm.
9. Obtain fresh whole blood from family and friends to complete haemodynamic stabilization.
10. Re-operate for definitive repair.

The indications for “resuscitative surgery with a damage-control approach” are not always all that obvious where resources are limited, but a simple series of conditions can be summed up as follows.

- Diagnosis of coagulopathy on table: the patient’s shed blood stops clotting.
- Absence of a proper thermometer: only continue operating with great caution once the patient’s temperature reaches the 35° C mark.
- Shocked patient with multiple system injuries.
- Delayed presentation with established peritonitis and shock.

The surgeon and anaesthetist should be aware that severe liver injury may provoke coagulopathy on its own without the patient going into hypothermia.

<sup>7</sup> Burch JM, Denton JR, Noble RD. Physiologic rationale for abbreviated laparotomy. *Surg Clin North Am* 1997; **77**: 779 – 782.

The usefulness of damage control surgery when faced with mass casualties in a resource-poor setting is debatable.

Whether or not damage control surgery is appropriate during the reception of mass casualties is debatable, and depends on the specific hospital context: number of wounded, likelihood of a fresh influx of casualties, number and competency of staff, availability of blood and intensive nursing care. In general, the surgeon should err on the conservative side and not use up excessive supplies on “futile” operations with little chance of success – thus applying the basic logic of triage.

#### Damage-control techniques: a summary

##### 1. Stop haemorrhage:

- clamp and ligature;
- temporary shunt;
- balloon catheter tamponade;
- abdominal packing;
- rapid removal of spleen or kidney.

##### 2. Stop contamination:

- clamp, suture or tie shut the gastro-intestinal tract: no anastomoses or formal stomas;
- drainage of pancreas, duodenum, and common bile duct.

##### 3. Temporarily close the abdomen

**Further operative details on damage-control techniques are given in each relevant section.**

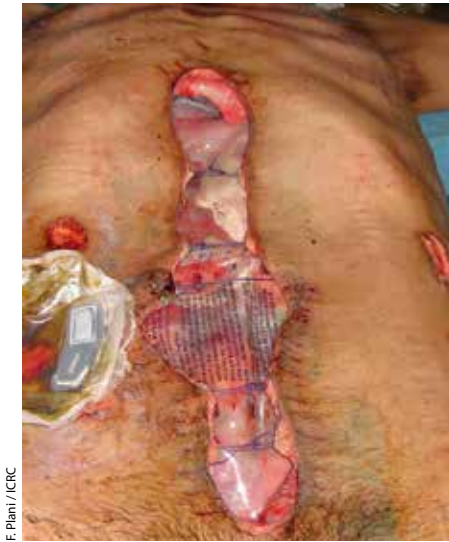### 32.9.1 Temporary abdominal closure

The abbreviated laparotomy is an incomplete operation; the abdomen will be re-opened shortly for definitive repair. Consequently, a simple and easily reversible technique for closure of the abdominal wall is sufficient. One possibility is a continuous suture of the skin only, with thick monofilament nylon. An alternative is to use a series of surgical towel clips placed 1 – 2 cm from the skin edge and 1 – 2 cm apart for the entire length of the incision. In either case, the fascia is not included but left open for later definitive closure.

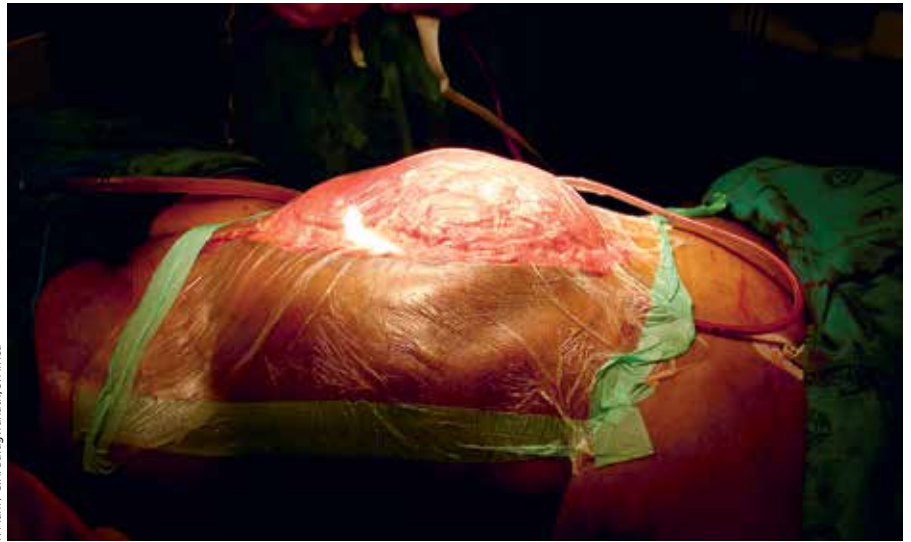Abdominal packing or oedema of the intestines at the first or second laparotomy may increase the intra-abdominal contents to such an extent that closure is not possible without tension resulting in excessive abdominal hypertension. This can lead to an *abdominal compartment syndrome* of the same pathophysiological nature as the more common syndrome seen in the limbs (see Annex 32.A). In this instance, the abdominal incision must be left completely “open” to accommodate the increase in intra-abdominal pressure.

The intestines must, nonetheless, be covered and the simplest method is the modified “Bogotá bag”. A large sterile plastic drape is placed between the intestines and the abdominal wall, generously extending laterally to maintain a barrier between the viscera and the parietal peritoneum to prevent adhesion formation. Tube drains are placed in appropriate positions intra-abdominally. An empty but still internally sterile three-litre urology bag, or one or two similar i.v. fluid bags, can be slit open and then sutured to the skin only, not the fascia. The bag may be covered with an adhesive Steri-Drape® or Opsite®, if available. This technique may also be used in patients with excessive loss of tissue of the abdominal wall.





F. Phani / ICRC



F. Phani / C.H. Baragwanath, S. Africa

**Figures 32.18.1 and 32.18.2**

“Bogotá bag” using i.v. fluid bags and with an outside covering of adhesive Steri-Drape®.

Closure of the abdominal incision at definitive repair – in effect a delayed primary closure – is usually not difficult for a straightforward laparotomy. In the event of abdominal hypertension, the timing of definitive closure is strictly related to the chances of success. Published experiences suggest that about one week is the threshold. Beyond this, closure becomes more complicated and requires special techniques. Closure may have to be performed over several days in a staged manner, each operation tightening the sutures and closing the incision a little at a time, allowing gradual re-expansion of the abdominal wall until visceral oedema subsides sufficiently. Sometimes, simple skin suturing without the fascia must be performed resulting in a programmed incisional hernia. In other cases, reconstructive procedures with rotation flaps are required. Special commercial meshes or vacuum pack dressings are not readily available where resources are limited.

### 32.10 “Frontline laparotomy” and late-presenting patients

ICRC surgeons have on numerous occasions received patients who had been operated “somewhere in the field” and arrived in a septic state with obvious intestinal or urinary leakage, missed injuries, or retained surgical compresses. These patients invariably die, even after a “second look” operation by a competent surgeon.

“Frontline laparotomy” falls under the category of mismanaged wounds of Chapter 12. This expression does not refer, of course, to a competent laparotomy performed by a well-staffed forward surgical team for the severely-injured patient who would not otherwise survive evacuation.

For the great majority of patients without significant haemorrhage, i.v. fluids, antibiotics and analgesics are sufficient even in the face of prolonged delay in evacuation.<sup>8</sup> A frontline laparotomy performed by a surgeon with limited experience, instead of appropriate first-aid stabilization, usually results in greater mortality than no operation at all.

It is more important to provide competent first aid and render the injured fit for transport than to perform risky surgery under precarious conditions.<sup>9</sup>

8 Coupland RM. Epidemiological approach to surgical management of the casualties of war. *BMJ* 1994; **308**: 1693 – 1696.

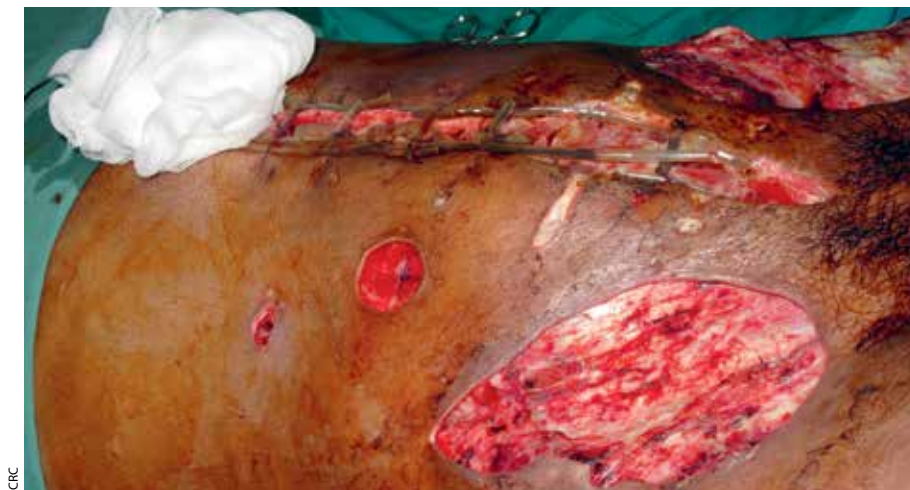9 Adapted from *Chirurgie de guerre*. [War Surgery] Bern: Federal Department of Defence, Swiss Army; 1970. [Translation by the authors.]

The patient arriving after lengthy evacuation may present asymptotically or with a lesion readily amenable to relatively simple surgery as noted above by the ICRC surgical team in Quetta or, on the other hand, may be severely septic. After adequate rehydration, resuscitation and antibiotics, a laparotomy may be undertaken if deemed necessary to at least provide proper drainage of any leakage. There is no rush with a patient who was injured one to three days ago.

In the presence of severe sepsis, a damage-control approach can be adopted and the abdomen left open using a temporary closure technique.

**Figure 32.19**

Patient was received three days after a field laparotomy; the abdomen was distended, no bowel sounds present, and obviously septic. At re-exploration a jejunal anastomosis and ileostomy were observed and the caecum was found to be necrotic. An extended right hemicolectomy was performed.



### 32.11 Midline great vessels

Injury to the midline vessels usually presents at operation as a contained retroperitoneal haematoma; free-flowing haemorrhage is rapidly fatal. Proper measures must be undertaken to control the aorta and inferior vena cava proximally and distally, starting with manual compression of the aorta, just under the diaphragm and distally (see Figure 32.15).

Any contained retroperitoneal haematoma should be inspected to see if it is stable, pulsatile, or expanding. A pulsatile and expanding retroperitoneal haematoma requires early exploration. Only a stable haematoma poses an operative predicament for the surgeon.

Observe if the retroperitoneal haematoma is stable, pulsatile or expanding.

A pulsatile or expanding haematoma calls for exploration.

A supramesocolic haematoma should be explored because of the likelihood of significant duodenal or pancreatic injury. An inframesocolic haematoma, on the other hand, can generally be managed expectantly.

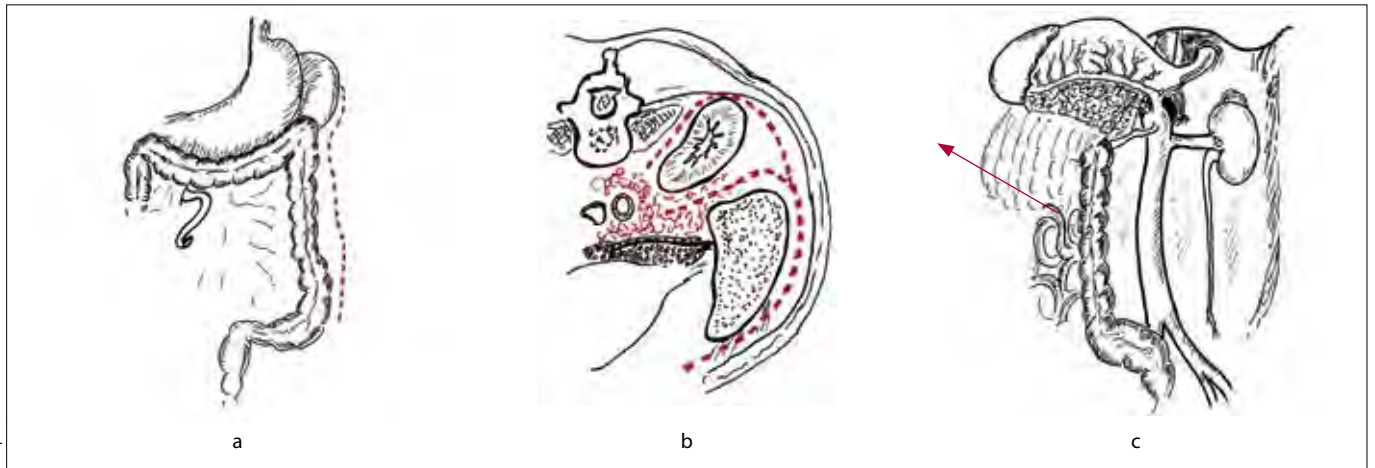
A stable haematoma involving the kidney presents the surgeon with a dilemma and a selective approach may be undertaken (see Section 33.5.2).

Even with injuries to the major vessels the basic principles of vascular surgery apply: adequate exposure; proximal and distal control; minimal debridement of the vessel wall; irrigation with a heparin-saline solution; and meticulous repair with a monofilament vascular suture using a thin needle and avoiding stenosis of the vessel. Certain vessels coming off the aorta and most of their accompanying veins can be ligated.

Rapid access to the retroperitoneal great vessels is the great surgical challenge, best obtained by a lateral approach, right or left.

### 32.11.1 Access to the aorta: left-sided medial visceral rotation (Mattox manoeuvre)

For access to the proximal aorta and its major anterior branches, the left colon is mobilized as for a left colectomy by cutting through the white line of Toldt in the paracolic gutter. The colon and small bowel together with the spleen and pancreas are then all pulled medially: medial visceral rotation. The left kidney can be included to fully expose the aorta or left in place if its vascular pedicle is the intended goal. During the dissection, care must be taken not to injure the left ureter or spleen and their integrity should be verified at the end.



N. Papas / ICRC

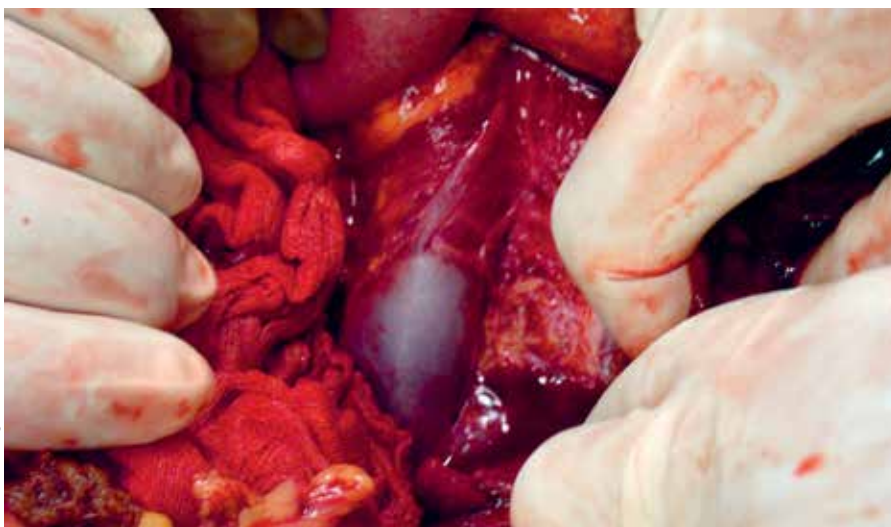**Figure 32.20**

Left medial visceral rotation.

- Incision along the white line of Toldt in the paracolic gutter extending up to the spleen.
- Line of cleavage behind the spleen and in front of the left kidney for access to the aorta; behind the kidney to access directly the renal artery. The dissection is facilitated by the presence of the haematoma which opens up the plane.
- The colon, small intestines, spleen, pancreas and stomach are all swept to the patient's right exposing the aorta.

To facilitate proximal control the left crus of the diaphragm can be cut. Blunt finger dissection isolates the aorta, which can be clamped if necessary, replacing the manual compression.

The aorta, normally a pulsating and obvious cylinder, collapses when clamped. It can be difficult to identify the flat and empty tube in the midst of a haematoma. To isolate it properly the surgeon may have to release the cross-clamp from time to time while carefully finger dissecting through the dense pre-lumbar connective tissue.



F. Plant / C.H. Baragwanath, S. Africa

**Figure 32.21**

Exposure of the aorta and inferior vena cava.

### 32.11.2 Access to the inferior vena cava: right-sided medial visceral rotation

For access to the infrahepatic vena cava, right kidney and renal pedicle, the same dissection is performed through the right paracolic white line of Toldt as for a right-hemicolectomy, and continued on around the duodenum via a Kocher manoeuvre (Figure 32.17). The caecum and right colon, duodenum and head of the pancreas, along with the small bowel are swung to the patient's left. The incision can be extended around the caecum and along the root of the mesentery of the small intestines freeing it from the posterior abdominal wall: the Cattell-Braasch manoeuvre.<sup>10</sup>

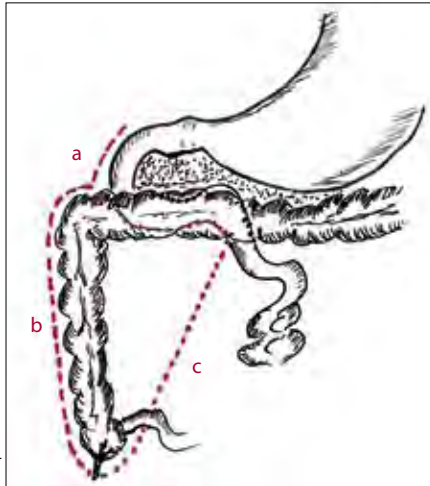


Figure 32.22.1

Right medial visceral rotation.

- Kocher manoeuvre: incision lateral to the duodenum.
- Extended Kocher manoeuvre: the incision is continued into the paracolic gutter along the white line of Toldt.
- Cattell-Braasch manoeuvre: the incision rounds the caecum and continues along the root of the mesentery until the ligament of Treitz.

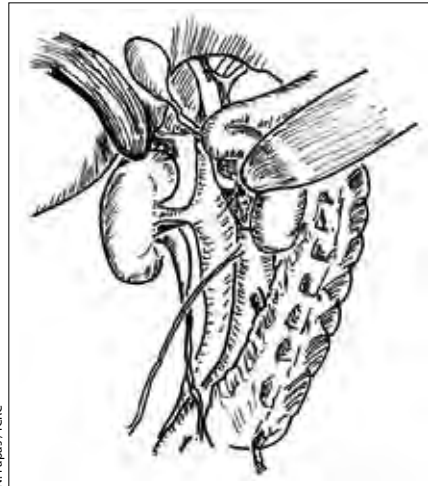


Figure 32.22.2

Extended Kocher manoeuvre: the duodenum and colon are retracted toward the patient's left, the liver to the right.

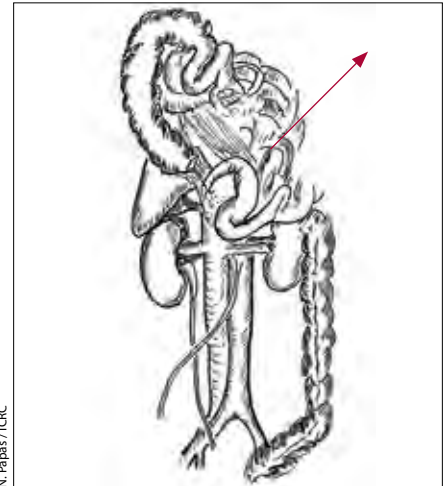


Figure 32.22.3

Cattell-Braasch manoeuvre: the caecum, transverse colon and small intestines are mobilized up and to the patient's left exposing the entirety of the inferior vena cava.

### 32.11.3 Management of arterial injuries

For incomplete lesions of the aorta, a partial occluding vascular clamp is applied (side-clamping), which allows for suture, resection or patching. The aorta requires minimal trimming of the edges and a transverse continuous repair with 3/0 or 4/0 non-absorbable monofilament suture.

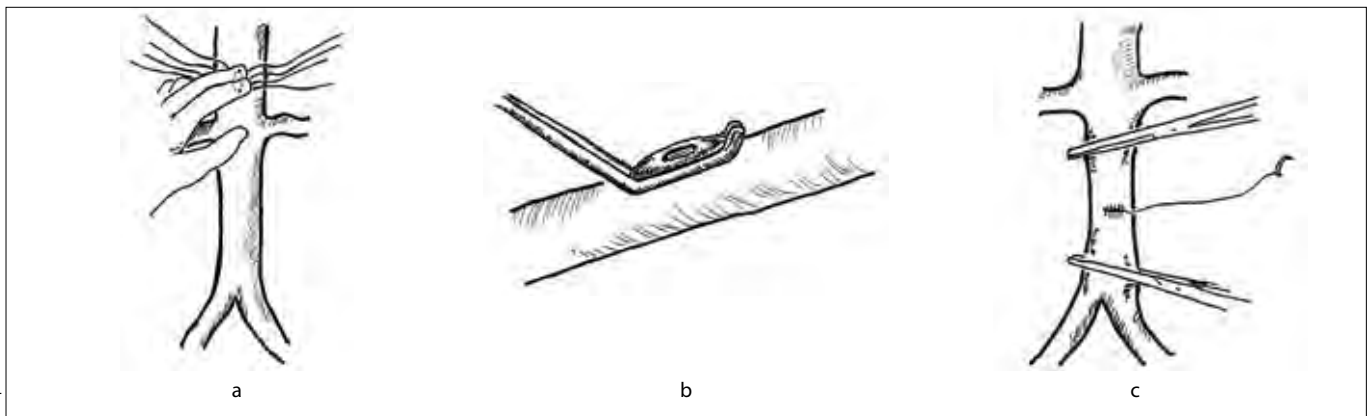


Figure 32.23

Repair of the aorta.

- Small wound: digital pressure to control bleeding and suture of the aorta as the fingers are removed.
- Alternatively, a side-clamp is applied.
- Larger wounds: total occlusion of the aorta by proximal and distal vascular clamps.

10 Cattell RB, Braasch JW. A technique for exposure of the duodenum. *Surg Gynecol Obstet* 1960; **133**: 378 – 379.

The coeliac trunk, left gastric, inferior mesenteric and splenic arteries can be ligated; the latter then proceeding to splenectomy. Treatment of a lesion to the superior mesenteric artery (SMA) is difficult and controversial.

Repair of the SMA if at all possible is the best approach; ligation is an extreme measure. A temporary shunt can be very useful to gain time. If the injury is close to the aorta, two procedures are available in this difficult situation.

- If very short, the proximal stump of the artery can be ligated and the distal stump re-implanted into the aorta lower down below and away from the pancreas.
- A saphenous vein graft bypass can be inserted between the SMA stump and the aorta.

Simultaneous repairs to the artery and the pancreas should be separated by a peritoneal flap to avoid a fistula eating away at the anastomosis.

Injury to the renal vascular pedicle usually requires a nephrectomy (see Section 33.5.2).

#### Summary of the management of injuries to major arteries of the abdomen<sup>11</sup>

VESSEL	REPAIR VERSUS LIGATION
Aorta	Repair
Splenic	Ligation followed by splenectomy
Common hepatic	Saphenous vein graft Ligation possible but only if portal vein intact Ligation followed by cholecystectomy
Right / left hepatic	Ligation Ligation of right artery followed by cholecystectomy
Coeliac	Ligation
Superior mesenteric	Temporary shunt for damage control Saphenous vein graft Re-implantation into aorta Ligation only for exsanguinating haemorrhage
Inferior mesenteric	Ligation possible
Renal	Nephrectomy (first confirm existence of other kidney)
Common iliac	Repair, followed by fasciotomy of the lower limb
External iliac	Repair, followed by fasciotomy of the lower limb
Internal iliac	Ligation

#### Please note:

Repair versus ligation: repair of an artery by either direct suture or interposition vein graft is always preferable. Suture for repair should always be synthetic monofilament with a thin non-traumatic needle. However, certain arteries can be ligated with relative impunity.

### 32.11.4 Management of venous injuries

Access and repair of the inferior vena cava (IVC) are difficult and the surgeon may have to revert to packing for temporary control. Control of the IVC is best achieved by direct digital pressure followed by clamping with vascular or sponge forceps proximal and distal to the injury. Alternatively, Foley catheters inserted proximally and distally and then inflated can provide temporary intraluminal control of haemorrhage, which allows for the proper placement of a vascular side-clamp.

<sup>11</sup> Adapted from Lam L, Inaba K. Major Abdominal Arteries. In: Velmahos GC, Degiannis E, Doll D, eds. *Penetrating Trauma: A Practical Guide on Operative Technique and Peri-Operative Management*. Berlin Heidelberg: Springer-Verlag; 2012: 381 – 389.

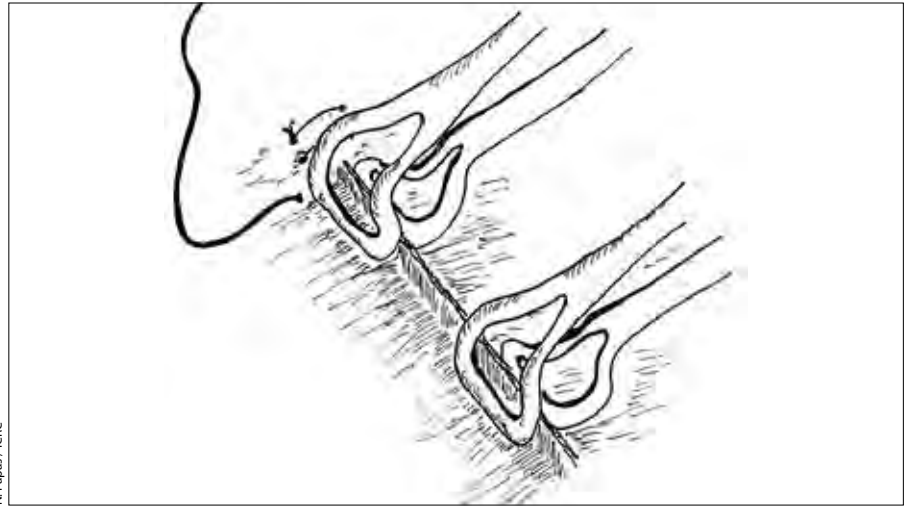
Ligation of the *suprarenal* vena cava may provoke renal failure and therefore injuries must be repaired. The *infrarenal* vena cava can be ligated if repair proves impossible, which is often the case. In the latter instance, the legs should be elevated and the patient should wear some sort of compression stockings for two weeks post-operatively.

#### Repair of the inferior vena cava

Repair is accomplished by minimal trimming of the edges followed by direct suture or a vein patch to overcome any defect, and fashioned from an autologous vein. In the midst of welling blood, the wall of the IVC can be difficult to see and suture without creating a larger tear. A simple technique after applying proximal and distal pressure involves grasping the edges of the laceration with Allis or Babcock clamps and then running a suture from the *intact* vein through the hole. If clamps cannot be applied, the suture is run as the fingers blocking the hole or any inserted Foley catheters are removed. If control of a through-and-through wound of the IVC can be achieved, then it is better to repair the posterior surface from within first.

Figure 32.24

Suture technique for the IVC: Babcock clamps hold the edges of the laceration. The suture begins in the intact vein.



The hepatic and inferior mesenteric veins can be ligated, as well as the left renal vein (venous drainage is assured by gonadal and adrenal veins); ligation of the right renal vein requires nephrectomy. Splenic vein ligation is accompanied by splenectomy. The superior mesenteric or portal veins should be repaired if at all possible since ligation provokes bowel engorgement and ischaemia, and the subsequent fluid sequestration and drainage can be massive, and require copious i.v. fluids. In the case of the portal vein, ligation is possible only if the hepatic artery is intact.

“Do not lose too much blood trying to repair veins: ligate.”

L. Riddez<sup>12</sup>

## 32.12 Liver and biliary tract

Haemorrhage from the liver can be arterial, venous, coagulopathic, or a combination of any of these.

### 32.12.1 Severity of injury

Hepatic injuries vary in severity from superficial lacerations to a shattered liver. Liver tissue is particularly susceptible to cavitation effect. Several classification systems have been used to describe the severity of hepatic damage, but they tend to be complicated and more readily applicable post-operatively to better define the injury in epidemiological studies. Very often, wounds of the liver are given straightforward descriptive names: simple, deep or stellate laceration, deep cavity, etc.

12 Louis Riddez, Associate Professor of Surgery, Karolinska Institute University Hospital and senior Red Cross surgeon.

On table however, the surgeon is confronted with one of two basic presentations:

- relatively simple wounds that are readily amenable to definitive repair or even just drainage;
- severe injury of the liver or its vasculature with quickly exsanguinating haemorrhage.

Proper assessment of the injury might require mobilization of the liver and access to its upper surface, especially if the hepatic exit and entry wounds are not well visualized or haemorrhage is not easily controlled by manual means. This is accomplished by division of the ligamentum teres and falciform ligament anteriorly and the right and left coronary and triangular ligaments laterally and medially. However, there are exceptions when mobilization should *not* be performed:

- perihepatic packing is to be used;
- lesion of the retrohepatic veins;
- thoraco-hepatic wound presenting as a massive haemothorax (see Section 31.7.2).

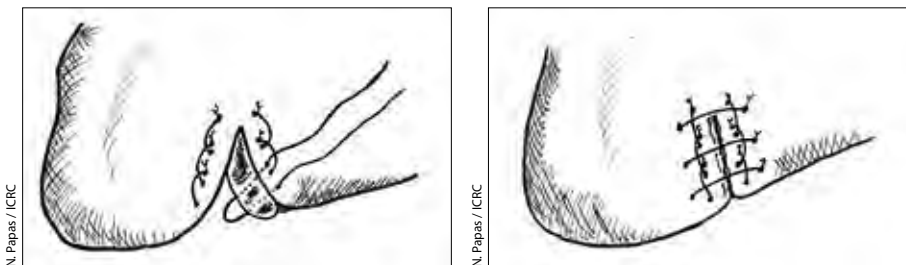
### 32.12.2 Management of simple liver lacerations

A small laceration that has stopped bleeding on opening the abdomen should be left as is. Any manipulation will disrupt the natural haemostatic process and cause bleeding to start again. However, this applies only if the patient is normotensive.

Capsular bleeding can be controlled by:


- direct compression for a few minutes;
- cauterization with electric diathermy;
- local pressure and simple suture;
- application of a topical haemostatic (Gelfoam® or Surgicel®) if available.

A jagged, deeper laceration oozing blood should be treated with mattress sutures of thick absorbable suture material (No. 0 or 1) on a blunt hepatic needle placed parallel to the edges of the laceration – “liver suture”. Any cavity is closed by horizontal sutures that approximate the two raw surfaces, pulling gently on the sutures to avoid tearing through the friable hepatic tissue.



Figures 32.25.1 and 32.25.2

Hepatic haemostatic mattress sutures: “liver suture”. The first mattress sutures overlap and the edges are brought together with horizontal sutures.



Figures 32.26.1 and 32.26.2

If the hepatic needle is not long enough, or is not available, one can be improvised by threading a thick suture through a spinal needle held in place by crimping the needle. The plastic end is then snapped off and removed.

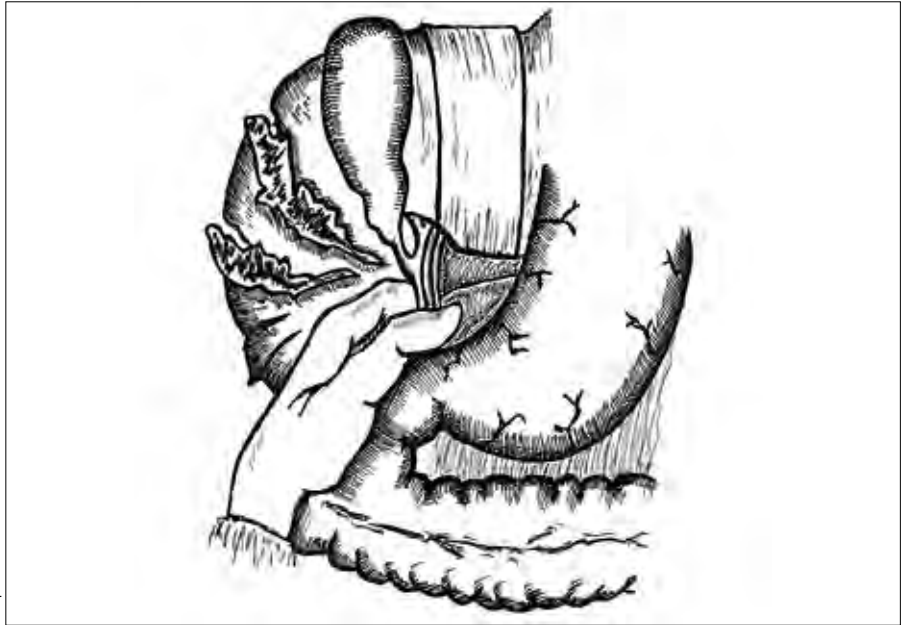These straightforward injuries constitute about 80% of all liver injuries encountered during operations for the war-wounded and the simple measures described suffice.

### 32.12.3 Management of larger wounds of the liver

Larger, actively bleeding wounds may require the application of the Pringle manoeuvre to temporarily control haemorrhage first. The Pringle manoeuvre occludes circulatory inflow to the liver and controls haemorrhage originating from the intrahepatic branches of the portal vein and hepatic artery. Failure to control massive haemorrhage indicates injury to the retrohepatic vena cava or hepatic veins.

**Figure 32.27**

Pringle manoeuvre: the porta hepatis is compressed with the fingers in the free edge of the lesser omentum. If this succeeds in stopping the haemorrhage, a hole is punched through a nonvascular part of the lesser omentum and the fingers replaced by a vascular clamp or a non-crushing intestinal clamp. The maximum period of occlusion is not known with exactitude, but it should not be prolonged beyond 30 minutes at a time.

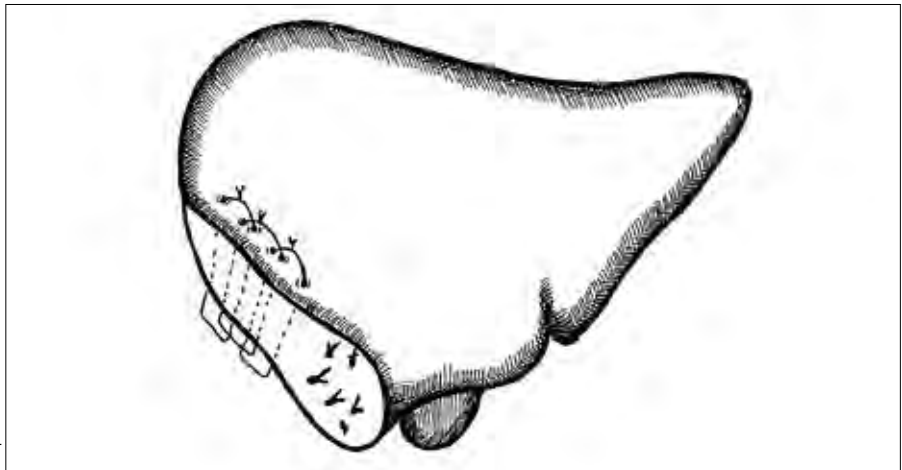


N. Papas / ICRG

Large lacerations near the edge of the organ are treated by resectional debridement and liver suture. Even greater disruption of a large portion of a hepatic lobe usually necessitates a sublobar or lobar resection. Full-thickness hepatic mattress sutures are placed first, followed by finger-fracture dissection and selective lobar portal triad ligation.

**Figure 32.28**

Partial resection of the liver: haemostatic hepatic mattress sutures and individual ligation of vessels and biliary radicles.



N. Papas / ICRG

**Finger-fracture dissection<sup>13</sup>**

The normal capsule is incised or cut through by diathermy and the parenchyma broken down by squeezing it between the thumb and index finger. When a strong resistant “thread” is felt instead of the crumbling parenchyma, the surgeon has come upon a lobar portal triad: the biliary radicles and intrahepatic branches of the portal vein and the hepatic artery. The triad is selectively clamped, divided, and suture-ligated. Any large raw surface can be covered by omentum stitched to the edges of the hepatic capsule.

13 Ton THat Tung, Nguyen Duong Quang. A new technique for operating on the liver. *Lancet* 1963; **281** (7274): 192 – 193.



### 32.12.4 Through-and-through wounds of the liver

Some through-and-through wounds of the liver have stopped bleeding by the time the abdomen is entered. In this case, the liver should be compressed between two hands and then released to see if active bleeding recommences. If not, the entry and exit wounds should *not* be sutured closed. This can create an intrahepatic haematoma and bile leakage with the possibility of abscess formation or haemobilia; instead a simple drain should be placed.

If bleeding does start again or active haemorrhage is present, several options are available.

- A relatively shallow wound tract can be laid open by the finger-fracture technique and the damaged parenchyma debrided and haemostasis assured by liver suture.
- Tamponade can be achieved by means of a Sengstaken-Blakemore tube passed through the tract. The stomach balloon is inflated first, outside the liver to hold the tube in place. Then, the oesophageal balloon is gently pulled tight by its extrahepatic tip and inflated. The free end of the tube is brought outside the abdomen through a separate stab incision and clamped. After two days the balloons are deflated; if the patient remains stable under observation for 6 – 8 hours the tube is removed.
- If a Sengstaken-Blakemore tube is not available, one can be improvised using a Foley catheter and a long Penrose drain fashioned into a balloon.<sup>14</sup> The Foley catheter is passed through the drain with its balloon protruding and the drain tied closely around it, thus resembling the gastric balloon of the Sengstaken-Blakemore tube. The drain and Foley are then passed through the missile track. The Penrose is inflated with saline and the end closely tied around the Foley catheter to act like the oesophageal balloon. The catheter is brought out of the abdomen and clamped as with the Sengstaken-Blakemore tube. Care should be taken not to pull the drain-tamponade out of the liver.
- A Penrose drain inserted into the wound cavity can be packed tightly with surgical compresses using a long haemostat. The presence of the latex drain prevents tearing away the haemostatic clot covering the raw surface on removal. However, removal of a Penrose drain-tamponade using compresses, or one that is filled with saline and cannot be exteriorized, requires re-operation.

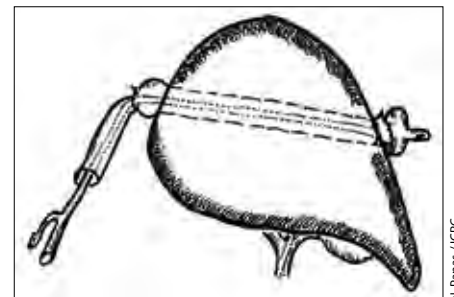
**Please note:**

The balloons of the Sengstaken-Blakemore tube or Foley catheter should always be tested before being used to create a tamponade.

### 32.12.5 Management of complex liver injuries

These are the few severe hepatic injuries that present massive bleeding on opening the abdomen. The surgeon should immediately think of a damage-control approach. The availability of blood and autotransfusion is often crucial.

First, the active haemorrhage must be stopped as quickly as possible. This is best accomplished by having the assistant apply external two-handed compression on the liver downwards and backwards to bring the shattered tissues together, while the surgeon performs the Pringle manoeuvre. Then, perihepatic compression by laparotomy pads – “liver packing” – replaces the assistant’s hands. Packing of the liver is a good temporary measure while preparing for definitive control during the same operation or to cut short the laparotomy and proceed to a damage-control approach. Packing in itself may prove therapeutic in many cases.



N. Papas / ICRC



T. Gasmann / ICRC

**Figures 32.29.1 and 32.29.2**

Improvised Penrose-drain-Foley-balloon for tamponade of a through-and-through wound of the liver.

14 Adapted from Morimoto RY, Birolini D, Junqueira AR Jr, Poggetti R, Horita LT. Balloon tamponade for transfixing lesions of the liver. *Surg Gynecol Obstet* 1987; **164**: 87 – 88 and Poggetti RS, Moore EE, Moore FA, Mitchell MB, Read RA. Balloon tamponade for bilobar transfixing hepatic gunshot wounds. *J Trauma* 1992; **33**: 694 – 697.

### Perihepatic compression packing

Packing must always be “around” the liver, never into the laceration, which simply keeps the bleeding wound open. Proper packing involves placing folded laparotomy pads above and below the liver, laterally, and between the liver and the anterior chest and abdominal wall. The aim is to wrap the liver in such a way as to restore the normal liver form and outline, thus compressing the torn tissues together.

If a large raw surface of the liver is exposed, a sterile plastic i.v. fluid bag or the mobilized omentum can be placed between the liver and the pack to facilitate removal later and not provoke reactionary haemorrhage.

Overuse of laparotomy pads causes an increase in intra-abdominal pressure: abdominal compartment syndrome (see Section 32.9.1 and Annex 32.A). Therefore only as many pads as necessary to stop bleeding should be used. Care should also be taken not to occlude the inferior vena cava, as this leads to decreased cardiac output or renal failure.

Further surgical management then depends on the exact injury and the physiological status of the patient. One possibility is to end the operation and close the abdomen leaving the liver packing in place. On re-operation, the packs should be soaked with warm normal saline to ease their removal and the Pringle manoeuvre re-applied if necessary. Repair is then carried out using the appropriate technique in addition to debridement of any remaining necrotic tissue.

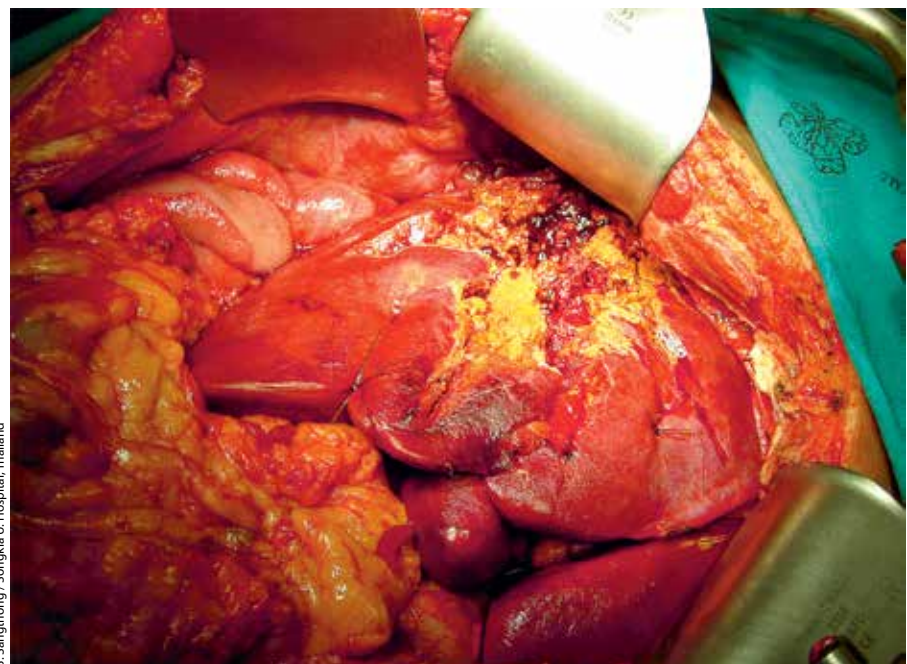
The decision to cut short the laparotomy should be made early, and is preferable to repeating the sequence of “pack and peek” – packing the liver, resuscitating, and removing the pack to look again with a view to repair – only to have the patient bleed again and require re-packing.

### Stellate fracture or shattered liver

A large stellate fracture or shattered liver with blood welling up from the depths, but controlled by the Pringle manoeuvre, indicates bleeding from branches of the portal vein or hepatic artery. Definitive surgical control involves finger-fracture into the depths of the cavity, releasing the Pringle to identify the bleeding points, and then ligation or suture repair of the vessels depending on their size.

**Figure 32.30.1**

Stellate lesion of the liver: bleeding has stopped and the lesion is covered with fibrin – often the case with those patients who survive to reach hospital.



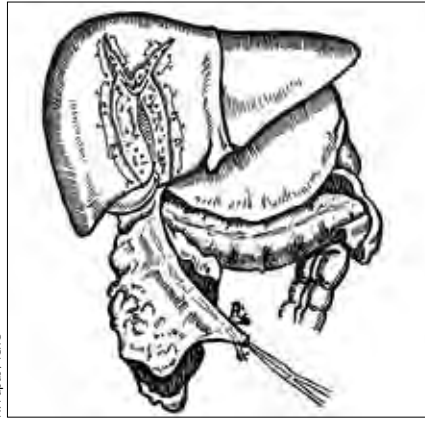
B. Sangthong / Songkla U. Hospital, Thailand



N. Papas / ICRC

**Figure 32.30.2**

Stellate laceration of the right lobe: a vascular clamp has replaced the surgeon's fingers to maintain the Pringle manoeuvre. Finger-fracture of the hepatic parenchyma reveals blood vessels and bile ducts.



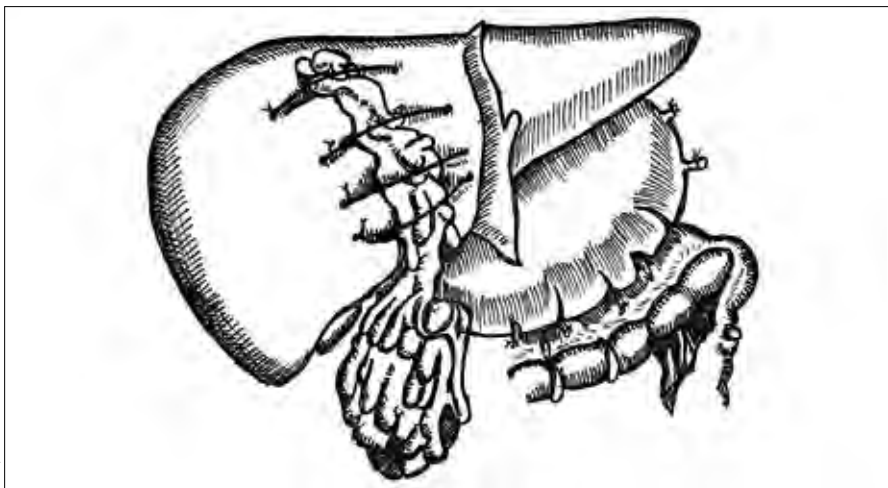
N. Papas / ICRC

**Figure 32.30.3**

Devitalized tissue has been excised, portal triads ligated and hepatic mattress sutures inserted. Omentum from the stomach and transverse colon has been mobilized, maintaining a pedicle on the patient's right.

If the bleeders cannot be found and the blood is bright red, individual *selective occlusion* of the right or left hepatic artery may localize one or other as the feeding vessel and this alone can be ligated. These are not end arteries and their individual ligation does not result in hepatic necrosis. Attention should be paid to a possible anomalous origin of these arteries from the superior mesenteric or left gastric artery, which is encountered in 20% of people. If control can only be obtained by common hepatic artery occlusion, this is ligated. Ligature of the common hepatic artery is associated with high mortality and should be avoided unless the situation is desperate. Sometimes portal circulation can sustain the liver long enough for it to recover. If the common or right hepatic artery is ligated cholecystectomy should be performed at definitive repair.

After control of haemorrhage and debridement of the liver wound, an omental plug is inserted into the cavity to fill in the dead space and help tamponade minor oozing from the raw surface of the hepatic parenchyma.



N. Papas / ICRC

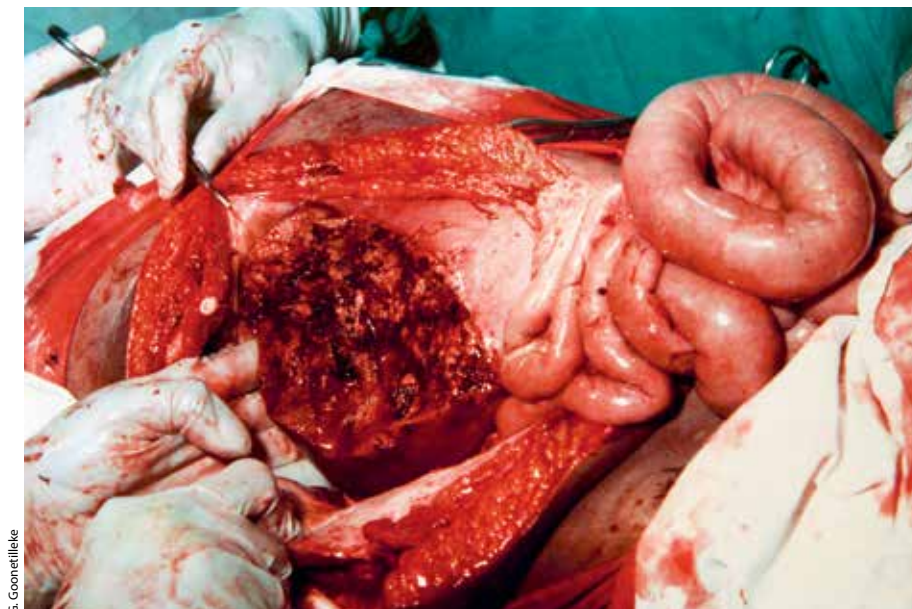
**Figure 32.30.4**

The liver laceration has been plugged by a mobilized omental pedicle and deep horizontal sutures inserted to hold it in place.

Inability to control haemorrhage within the 30-minute period of Pringle occlusion is a good indication for a damage-control approach.

Figure 32.31

Shattered liver: the patient rarely survives.



G. Gornelleke

### Retrohepatic vena cava and hepatic veins

Haemorrhage from the depths of a cavity not controlled by the Pringle manoeuvre, or welling up from behind the liver indicates injury to the retrohepatic vena cava or hepatic veins. It is usually best to adopt a damage-control approach and abort the operation.

The retrohepatic haematoma must *not be explored* and the liver must *not be mobilized*; instead the right coronary and triangular ligaments should be left intact to provide a proper scaffold for the tamponade to be effective. Packing is best performed by unrolling a sterile gauze bandage and stuffing it in place laterally and posteriorly. Further packing is added anteriorly. The weight of the liver when the patient is in the decubitus position adds to the tamponade effect on the vena cava.

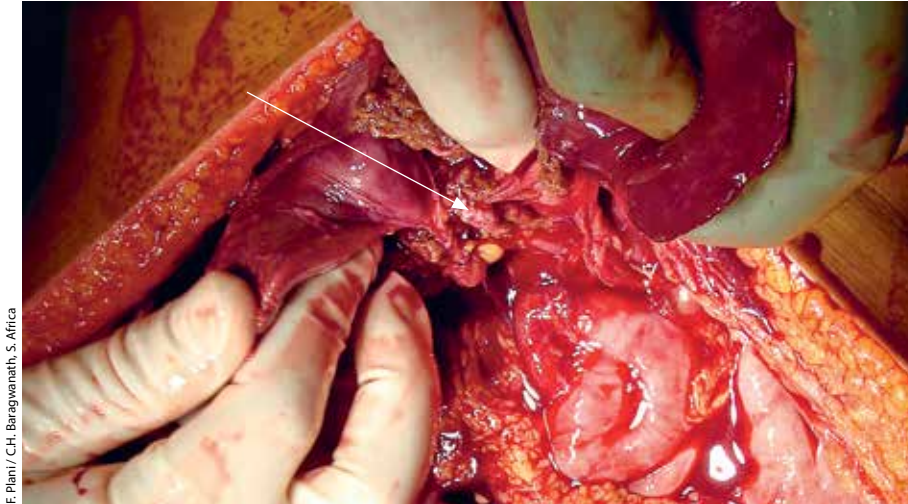
If the first attempt at packing does not stop the bleeding, control necessarily involves clamping the inferior vena cava below the liver and above through a thoracotomy, followed by cross-clamping of the aorta. The liver is then mobilized to visualize the retrohepatic area: a radical and risky procedure under any circumstances.

On re-operation after liver packing, the surgeon should also be prepared to cross-clamp the aorta and perform a thoracotomy after removal of the tamponade. With no bleeding after removal of the pack, nothing more should be attempted. Usually, the only successful cases are those that respond positively to the initial packing.

As mentioned, if a massive haemothorax has been diagnosed and thoracotomy reveals a gush of blood coming through the diaphragm, the hole in the diaphragm should be closed to restore a closed space allowing tamponade of the vena cava or hepatic veins to occur. Subsequent laparotomy involves simple lateral packing without mobilizing the liver.

### Porta hepatis injury

Injury to both the portal vein and hepatic artery is rarely encountered in survivors. Direct injury to vessels within the porta hepatis usually involves the major bile ducts as well.



**Figure 32.32**  
Injury to the porta hepatis.

First, a Pringle manoeuvre is performed and the porta hepatis dissected to identify the lesion. Every effort should be made to restore portal circulation to the liver; a saphenous vein interposition graft may be required. A temporizing measure to control haemorrhage is to insert two thin Foley catheters into the vein, one going to the left branch and one to the right, and then inflating the balloons. If repair is not possible, the vein should be ligated and the consequences accepted: the acute interruption of the portal vein is invariably fatal.

The right or left hepatic artery can be ligated. Common hepatic artery injuries should be treated by repair if possible; however ligation is acceptable as long as the portal venous flow is intact.

Complex injuries to bile ducts frequently require an enteric-duct anastomosis as a secondary procedure on re-operation (see Section 32.12.8).

In all such complex injuries, coagulopathy should be anticipated. The common error is to continue to attempt definitive surgical control while the patient is exsanguinating, receiving multiple transfusions, and reaching a coagulopathic state.

#### Emergency management of severe active bleeding from the liver

- No one single algorithm suffices to cover the variety of liver injuries.
- Press, Pringle, pack, plug, and pause: patience while anaesthesia catches up.

### 32.12.6 Drains

Blood and bile oozing from a raw surface rapidly subside and are decreased by covering with a patch of omentum. Insofar as possible, drains should be a closed system, not an open Penrose or corrugated rubber drain. A Nelaton catheter can be brought out posteriorly through the right flank and attached to a sterile urine collection bag. Most drains can be withdrawn after 24 – 48 hours. T-tube drainage of the common bile duct is indicated only if the biliary tree is injured. It is not necessary and should not be done for liver injuries alone.

### 32.12.7 Complications

Complications of liver injuries include secondary haemorrhage; subphrenic, intrahepatic or subhepatic abscess; and biliary fistula. They are usually caused by inadequate excision of devitalized parenchyma or unrecognized associated injuries to other surrounding structures such as the biliary ducts, duodenum, the pancreas and, especially, the colon. Infectious complications are also common after perihepatic packing as a damage-control technique. When a major liver resection has been performed there is nearly always post-operative jaundice. This resolves spontaneously after 8 to 10 days.

### 32.12.8 Extrahepatic biliary tract

Injury to the extrahepatic biliary tract is uncommon and never occurs in isolation.

A lesion of the gallbladder requires cholecystectomy.

Injury to the common bile duct with minor loss of tissue is closed over a T-tube using 4/0 absorbable sutures, as practised following exploration for gallstones. Major loss of tissue invariably requires a staged procedure: primary temporary drainage followed by reconstruction.

For injuries below the cystic duct two choices for drainage exist:

- ligation of the common bile duct proximally and distally with a cholecystostomy around a Foley catheter;
- choledochostomy: end-tube drainage-fistulization of the proximal end of the common duct and ligation of the distal end.

On re-operation, several reconstructive procedures are available depending on the expertise of the surgeon:

- direct cholecysto-jejunostomy;
- Roux-en-Y cholecysto-jejunostomy;
- Roux-en-Y choledocho-jejunostomy stented by a T-tube.

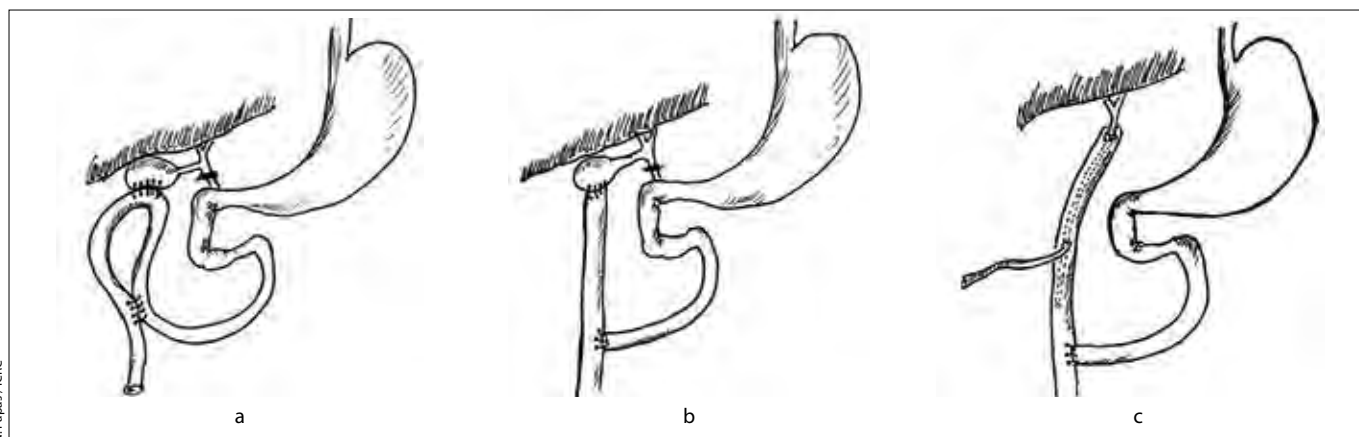


Figure 32.33

Possible reconstructive procedures.

- Direct cholecysto-jejunostomy with entero-anastomosis.
- Roux-en-Y cholecysto-jejunostomy.
- Roux-en-Y choledocho-jejunostomy stented by a T-tube.

For injuries above the cystic duct, choledochostomy followed by a Roux-en-Y choledocho-jejunostomy with an internal stent as a definitive repair is the procedure of choice.

Injury to the right or left hepatic ducts is even more difficult and complicated to deal with. If only one duct is damaged, it should be ligated and any atrophy of the lobe dealt with at a later stage. If both ducts are injured, they should be canalized with thin catheters brought outside the abdomen for drainage. Definitive reconstruction requires a Roux-en-Y hepato-jejunostomy.

### 32.13 Pancreas, duodenum and spleen

Treating the pancreas as a single organ makes little sense in trauma surgery. Injuries to the tail or head of the pancreas differ greatly in their inherent problems and appropriate surgical approach. It is best to consider the duodenum-head-of-the-pancreas complex to the right of the mesenteric vessels as a single surgical unit. Similarly, the distal pancreas to the left of the vessels should be taken together with the spleen.

Major injuries to the head of the pancreas are rarely seen in survivors owing to the nearby presence of the great vessels. Minor injuries are *invariably* associated with trauma to the duodenum. Injuries to the duodenum are also rarely isolated because of the numerous structures in close proximity.

Projectile injuries to the tail of the pancreas usually occur in conjunction with trauma to the splenic vessels or spleen. Similarly, wounds of the spleen are often associated with injury to the tail of the pancreas on the one hand, or to the colon, diaphragm and chest on the other. In addition, injury to the spleen may present as a haemothorax in a patient with a thoraco-abdominal wound, just as in the case of a bleeding liver.

### 32.13.1 Injuries to the head of the pancreas

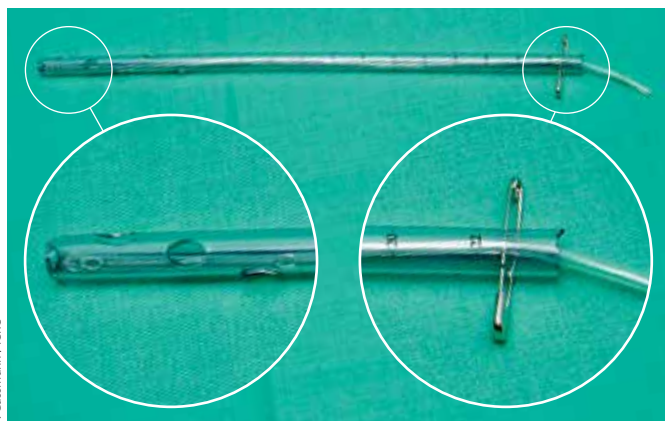
Recognizing an injury to the pancreas or duodenum may be difficult; often just a simple haematoma may hide a severe lesion. Retroperitoneal bile staining is pathognomonic. Proper exposure of the pancreas involves going through the gastro-colic omentum to enter the lesser sac and opening the peritoneum over it to reveal the nature of the haematoma and the depth of the lesion. The Kocher manoeuvre to mobilize the duodenum may be required.

Injury to the pancreatic duct – the essential structure – may be difficult to diagnose. Any deep central injury to the pancreas should be considered an injury to the duct and dealt with accordingly.

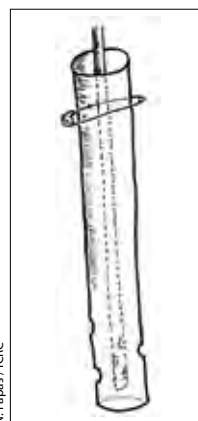
The principles of treatment are haemostasis, excision of dead tissue, and drainage. More than one drain, and preferably sump drainage, should be placed. If the duct is intact, simple suture of the pancreatic capsule in addition to drainage is all that is required. If the duct is disrupted, drainage is the mainstay of treatment until a later Roux-en-Y reconstruction can be performed.

Adequate drainage is vital in pancreatic injuries.

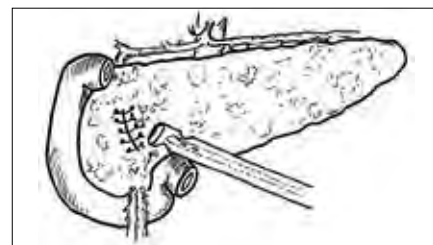
If a suction pump is available, sump drainage, using a naso-gastric tube placed through a large rectal or chest tube, is helpful; if not, then whatever drain available that ensures adequate drainage. If the laboratory can provide amylase analysis, then drainage should continue until the effluent amylase is less than the serum amylase.



T. Gassmann / ICRC



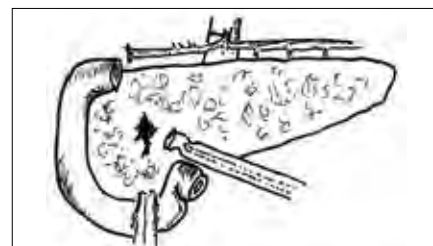
N. Papas / ICRC



N. Papas / ICRC

Figure 32.34.1

Simple laceration, intact pancreatic duct: suture and drainage.



N. Papas / ICRC

Figure 32.34.2

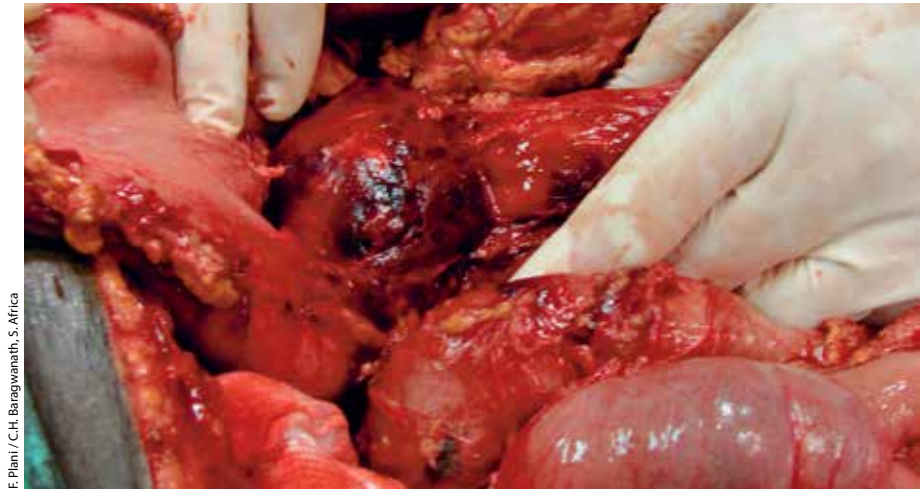
Deep injury with possibility of injury to the pancreatic duct: drainage is the mainstay of treatment.

Figures 32.35.1 and 32.35.2

Sump drainage: a large chest tube with multiple perforations at the distal end is placed close to the injured pancreas. A naso-gastric tube is inserted through the chest tube without extending beyond its end and is then fixed to it. The chest tube is sutured to the patient's skin. If the naso-gastric tube becomes obstructed it can easily be replaced, leaving the outer tube *in situ*.

Figure 32.36.1

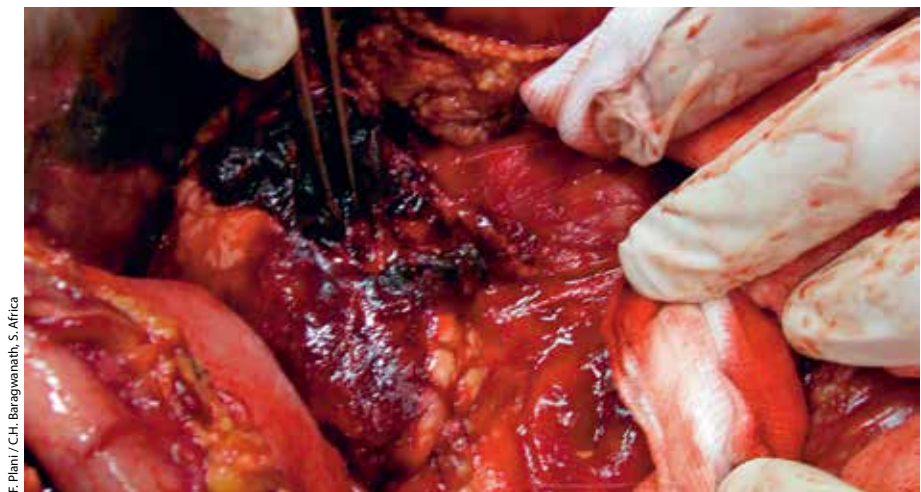Large haematoma overlying the head of the pancreas.



F. Plani / C.H. Baragwanath, S. Africa

Figure 32.36.2

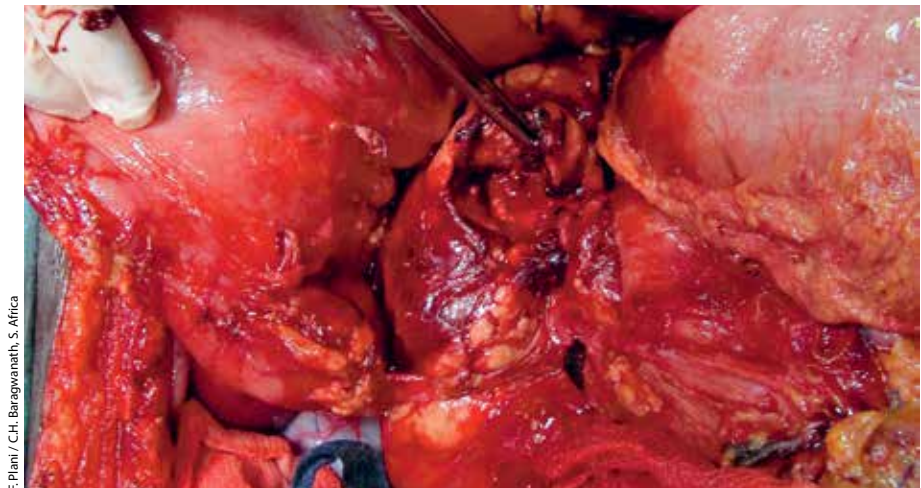
Verifying the pancreatic duct.



F. Plani / C.H. Baragwanath, S. Africa

Figure 32.36.3

Debridement of the wound and control of the duodenum and pancreatic duct.



F. Plani / C.H. Baragwanath, S. Africa

More severe injuries including the duodenum are extremely difficult to treat and are usually accompanied by severe haemorrhage. Haemostasis by packing tamponade may be necessary as a damage-control procedure. Pancreatico-jejunostomy and duodeno-pancreatectomy should *not* be attempted. Efficient drainage, local repair of the duodenum, and gastric diversion are the basis of treatment.

#### Complications

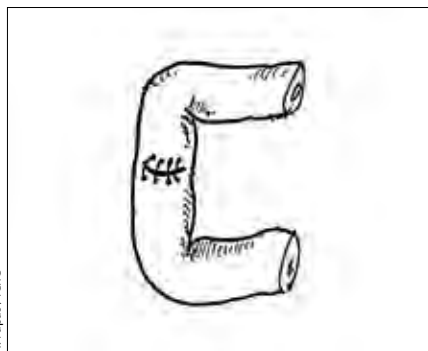
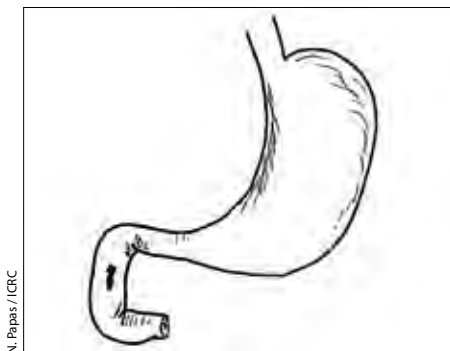
Complications are multiple and include a fistula, pancreatitis, pseudocyst, and abscess formation. Mild pancreatitis occurs in up to a fifth of patients post-operatively; conservative management is usually sufficient. Careful observation is important and, if the patient's condition deteriorates, re-operation to remove necrotic tissue and control pancreatic duct leakage may be necessary. Drainage, again, is the basis of treatment.



### 32.13.2 Injuries to the duodenum

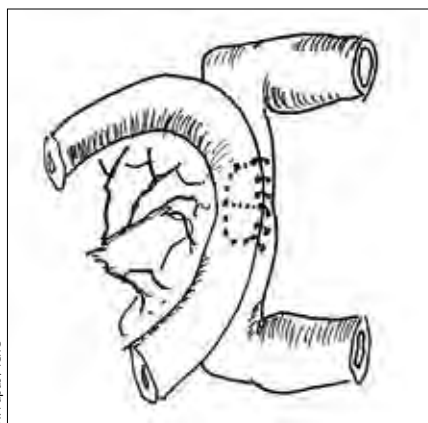
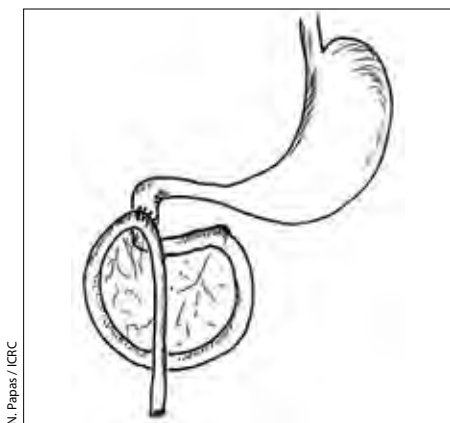
Given the proximity of major vessels and other organs, there are two categories of injuries that the surgeon encounters: simple ones that lend themselves to direct repair and complex ones involving several nearby organs, usually in a haemodynamically unstable patient.

Most wounds are minor, involving less than 40% of the circumference. They can be closed by suturing transversely to the duodenal axis to avoid stenosis. The suture line should be reinforced by a jejunal loop-patch or a healthy thick omental pedicle.



Figures 32.37.1 and 32.37.2

Simple laceration of the duodenum sutured transversely.

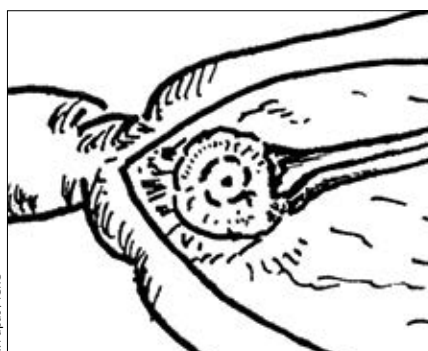
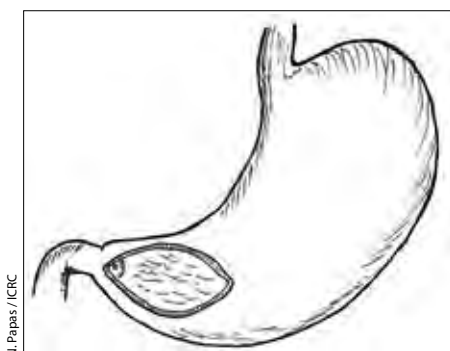


Figures 32.37.3 and 32.37.4

The repair is covered with a jejunal loop.

For larger lesions, the duodenum should be mobilized by the Kocher manoeuvre for debridement, resection and anastomosis. Repair suturing should begin on the medial pancreatic surface. Access to lesions of the posterior aspect of the second part of the duodenum is facilitated by an anterior duodenotomy with repair from the inside.

Decompression of the duodenum is most readily accomplished by a Levin naso-duodenal tube passed beyond the suture line. A difficult primary repair or anastomotic suture is usefully protected by pyloric exclusion and a gastro-jejunostomy and truncal vagotomy. Pyloric exclusion is accomplished by pulling the pyloric ring through the gastrotomy incision and closing it with a thick absorbable No.0 purse-string suture, which absorbs on its own within 3 – 4 weeks. A non-cutting stapler, if available, can be placed from the outside across the pylorus, care being taken not to divide the pylorus. The staple line opens by itself within 2 – 3 weeks.



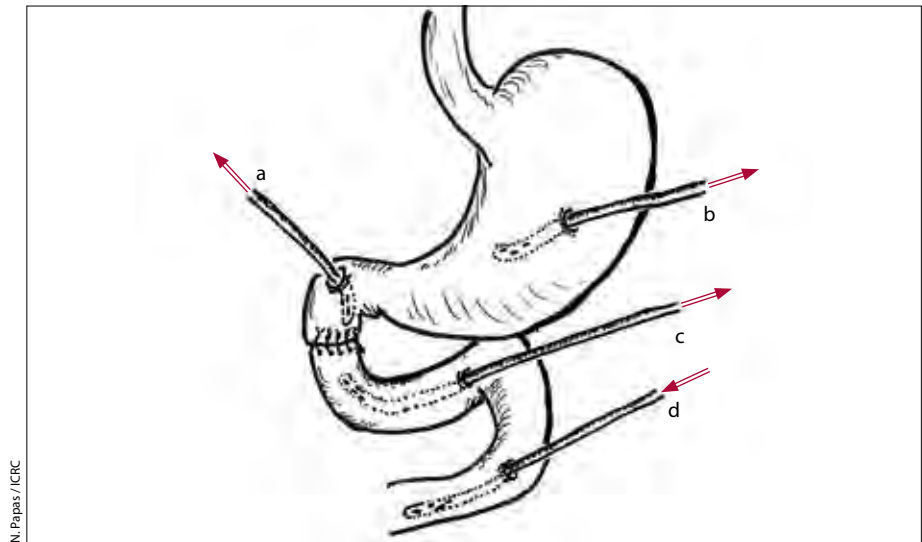
Figures 32.38.1 and 32.38.2

Pyloric exclusion: the pylorus is exteriorized through a gastrotomy and closed with a purse-string suture.

**Figure 32.39**

Alternative procedures for decompression of the duodenum and protection of the anastomotic line:

- a. tube duodenostomy.
- b. gastrostomy.
- c. decompressive jejunostomy.
- d. feeding jejunostomy.

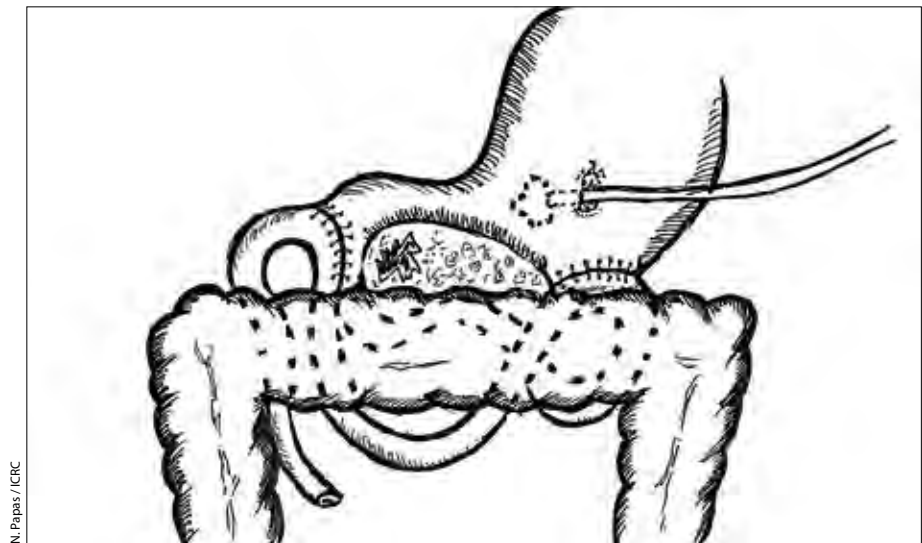


For complex injuries in an unstable patient, a damage-control approach is preferable because of the notoriously high rate of duodenal suture line dehiscence and the complexity of reconstructive procedures. After haemostasis, the simplest procedure to control contamination from the duodenal injury is used: tying off the injured ends; direct suture; or inflated Foley catheters inserted proximally and distally and fixed in place by purse-string sutures. The stomach is decompressed by gastrostomy at a site appropriate for a future gastro-jejunostomy and pyloric exclusion performed.

At the operation for definitive repair a number of procedures are available according to the lesion.

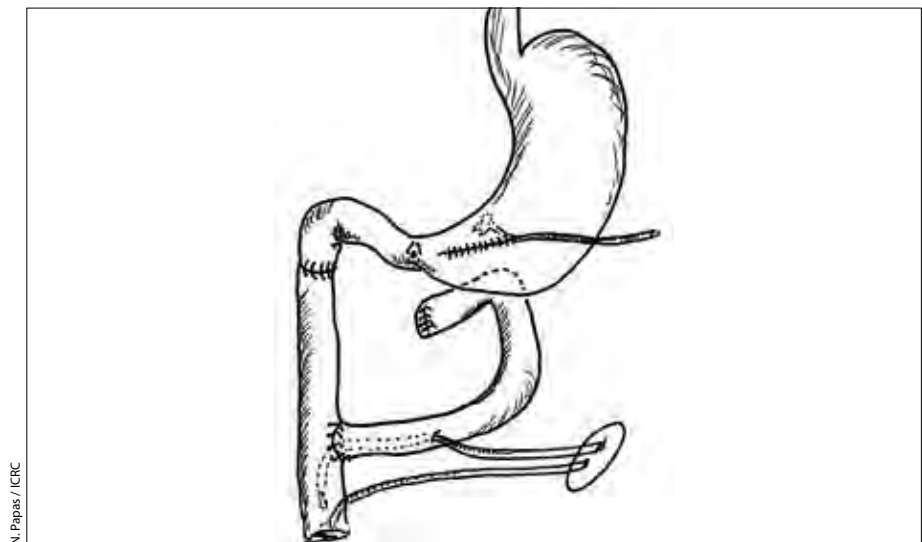
**Figure 32.40**

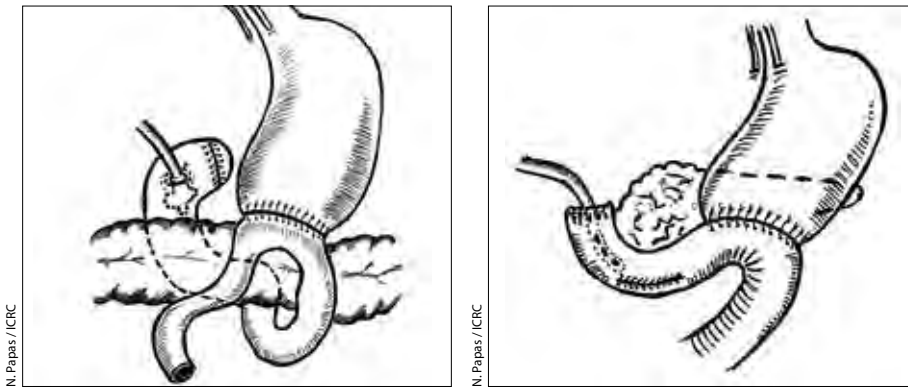
Large wounds leaving a defect not amenable to direct suture or anastomosis can be closed with a jejunal loop patch. The serosa exposed to the duodenal contents is eventually resurfaced by mucosa. The duodenum should be decompressed by gastro-jejunostomy and tube gastrostomy. Both anastomoses are retrocolic. Any injury to the head of the pancreas is treated by haemostasis and drainage.



**Figure 32.41**

An alternative for a severe lesion is resection of the damaged part and repair using a jejunal end-to-end Roux-en-Y duodeno-jejunostomy. Pyloric exclusion and gastrostomy are good adjuncts to protect the suture lines. A feeding jejunostomy tube should be threaded distal to the last anastomosis either through the loop or beyond depending on the patient's anatomy.





Figures 32.42.1 and 32.42.2

Extensive injury to the first or second part of the duodenum and/or pylorus may require a diverticulization of the duodenum and Billroth II antrectomy with gastro-jejunostomy and vagotomy. There are alternative procedures for decompression of the duodenal stump: lateral- or end-tube duodenostomy.

A distal feeding jejunostomy at a safe distance is advisable in most of these procedures, especially if extensive pancreatic injury is present. Good drainage should be instituted for any duodenal suture line, in good proximity and in a dependent position but not in direct contact.

Adequate nutrition must be maintained for these patients: feeding jejunostomy is an appropriate procedure.

The main complications are duodenal fistula and infection; the more complex the reconstructive procedures, the higher their incidence. Control of a duodenal fistula requires drainage duodenostomy. Most mortality, however, results from haemorrhage and injury to the pancreas.

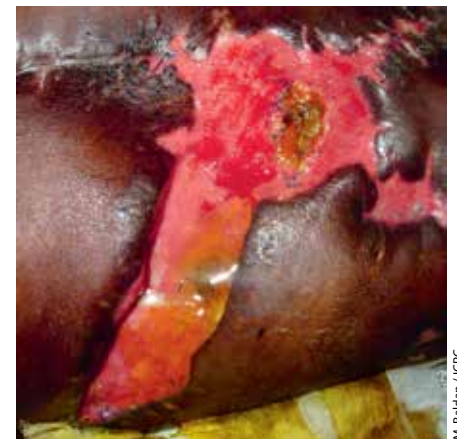

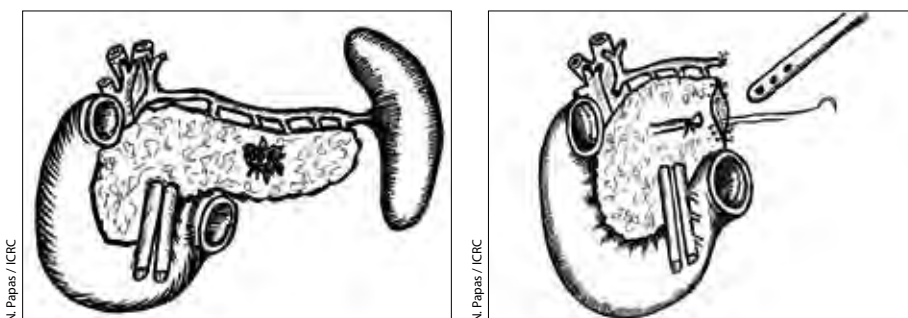
Figure 32.43

Duodenal fistula showing bile-stained discharge.

### 32.13.3 Treatment of injuries to the distal pancreas

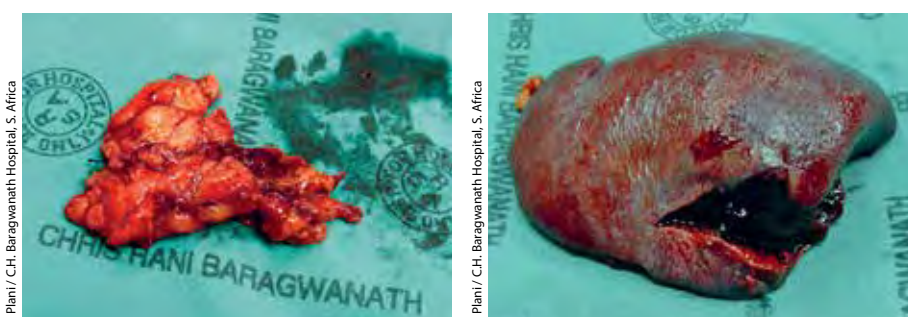
Minor injuries, with an intact pancreatic duct, are adequately treated with minimal debridement and haemostasis and dependent drainage through the posterior flank via a wide-bore drain or two.

In major injuries to the pancreatic body or tail involving the pancreatic duct, distal resection and splenectomy should be performed. The spleen is mobilized and the plane of cleavage continued behind the pancreas to bring the entire bloc out of the abdomen. The splenic vessels are clamped. The pancreas is held in a non-crushing bowel clamp and then transected and removed together with the spleen. The pancreatic duct is sought and separately ligated. Meticulous haemostasis is performed after slowly releasing the bowel clamp, and the resected surface is closed with 3/0 non-absorbable mattress sutures. Adequate drainage is vital.



Figures 32.44.1 and 32.44.2

Major injury to the pancreatic tail: distal resection of the pancreas with ligature of the duct and splenectomy.



Figures 32.44.3 and 32.44.4

Injury to the tail and spleen: distal resection and splenectomy.

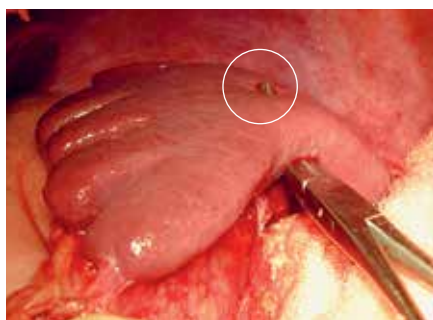
Injuries involving the body and tail of the pancreas and with suspected or direct evidence of pancreatic duct disruption require distal pancreatectomy and splenectomy.

The damage-control approach in a haemodynamically unstable patient is to tamponade the lesser sac by packing it and to place one or more drains to convert the traumatic pancreatic fistula into a controlled one. Basically: haemostasis and drainage.

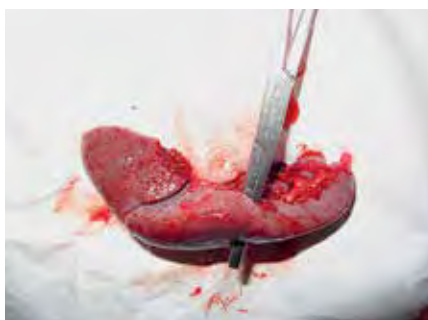### 32.13.4 Treatment of injuries to the spleen

In war surgery, injuries to the spleen should be treated by splenectomy.

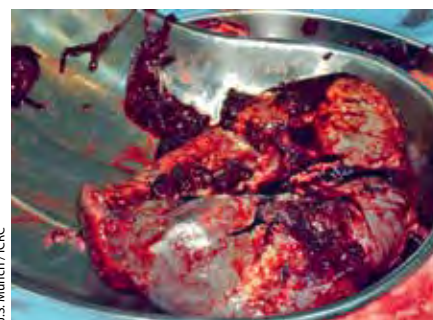In war surgery, the management of an injury to the spleen or splenic pedicle is by splenectomy. This is the only safe approach. Various techniques for splenic repair are described. However, these are inappropriate for a surgeon who is not specially trained in the procedure and is working in a hospital where post-operative care is limited.



ICRC



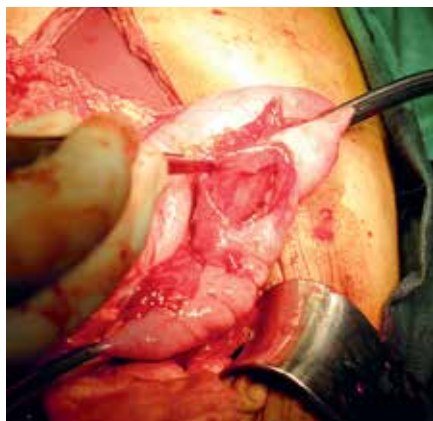ICRC



J.S. Munch / ICRC

Figures 32.45.1 – 32.45.3

Small or large, in war surgery injury to the spleen requires splenectomy.



ICRC

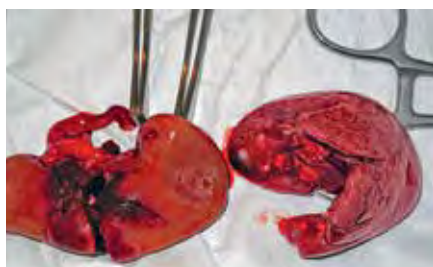The spleen should be mobilized out of the abdomen while pinching the splenic vessels in the hilum between the fingers – the “splenic Pringle manoeuvre”. This usually controls any haemorrhage as the vessels are being dissected out. The vessels should be ligated close to the spleen to avoid damage to the pancreas or stomach and the artery and vein double-ligated or suture-ligated separately. No drain is required after an isolated splenectomy.

In countries where endemic diseases characterized by splenomegaly are prevalent, such as malaria, leishmaniasis or schistosomiasis, etc., many people develop perisplenic adhesions. Mobilization of the organ may be difficult and lateral extension of the abdominal incision may prove necessary. Alternatively, an anterior approach to secure the splenic vessels may be required *before* mobilization of the spleen.

### 32.13.5 Post-splenectomy prophylaxis of infection

Infants and children are far more susceptible to infections after splenectomy than adults, except for those suffering immune depression (HIV/AIDS in particular). Reportedly, a syndrome of overwhelming post-splenectomy infection (OPSI) can occur any time from the immediate post-operative period up to decades post-splenectomy, although direct evidence is inconclusive. The true incidence of OPSI after traumatic splenectomy is not known. It usually presents with an upper respiratory tract infection and fever and progresses within hours to shock, disseminated intravascular coagulation, and multiple organ failure. Infection is usually due to capsule-forming bacteria and fatality can be over 50%.

Heterotopic autologous transplantation of splenic tissue has been advocated in an attempt to provoke an artificial splenosis to try to overcome any possible deficit in the immune system or occurrence of thrombo-embolic phenomena. Several techniques have been described, involving the harvesting of about 50 g of tissue without the



ICRC

Figures 32.46.1 and 32.46.2

A common association: concomitant injury to the splenic flexure of the colon, spleen and kidney.

capsule from as close as possible to the splenic hilum and implanting it between the two layers of the omentum. Results have been inconclusive, but the procedure is probably most indicated in children.

Certain prophylactic measures are called for. A standard protocol for prevention in both children and adults includes penicillin or ampicillin intra- and post-operatively. Post-splenectomy immunization for infants and children, and adults suffering from compromised immunity or a blood dyscrasia such as sickle-cell anaemia, is advisable.

A pragmatic scheme for settings with limited resources would appear to be a model currently in use in several hospitals in South Africa.

- Pneumovax-23 vaccine (*Streptococcus pneumoniae*) at day 14 post-injury or on day of discharge, whichever comes first (Heptavalent vaccine is not effective).
- *Haemophilus influenzae B* vaccine only if the patient is under 13 and not immunized.
- Meningococcal vaccine (*Neisseria meningitides*) only in endemic areas as the Pneumovax-23 cross-covers well.

Re-vaccination after five years should be offered to children if they are 10 years old or younger.

The efficiency of long-term antibiotic prophylaxis has not been conclusively demonstrated. Benzathine penicillin i.m. monthly may be considered only for infants and children on the same premise as prophylaxis for rheumatic heart disease and, perhaps, for adults who are immune depressed; patient compliance can be difficult in low-income countries. Both adults and children should be covered for a week before and after a dental procedure and if they develop any serious respiratory infection. Particularly in rural populations, having a “starter pack” of a three-day course of amoxicillin-clavulanic acid (1 gram TID) is a practical and realistic common sense practice: the patient can take it if signs of an acute upper respiratory tract infection or septic syndrome develop while on the way to receiving medical assistance.<sup>15</sup>

Even more importantly, patients should be given appropriate information and warning on the need to present quickly for medical consultation with the development of even a “minor” respiratory tract infection. For patients living in regions where malaria and meningitis are endemic and animal and tick bites common, extra care and appropriate prophylactic measures should be taken.

Splenectomized patients should take extra care in areas where malaria is endemic.

## 32.14 Stomach

The stomach provides a large surface susceptible to injury. Whether the stomach is empty or full is of great consequence as described previously; the same projectile may create a small puncture wound or a large laceration with widespread dissemination of the full stomach's contents. The contaminating contents of the stomach are important: the pH of fasting gastric juice is bactericidal; conversely, during digestion the pH is neutralized and bacteria then flourish. Therefore, fasting patients do much better than those with a full stomach.

Lesions in the abdominal oesophagus or the cardia may be difficult to identify. They require mobilization as for a vagotomy and may necessitate raising a gastric pedicle flap for closure. The damage-control approach for an injury of the abdominal oesophagus is to insert Foley catheters and stitch them in place.

<sup>15</sup> The approach used in South Africa was developed because of cost, uncertain patient compliance, and the benefit ratio because the evidence for long-term prophylaxis is still not conclusive. Personal communication from Dr Timothy C. Hardcastle, Head of Trauma Surgery and Deputy Director Trauma Unit and Trauma ICU, Inkosi Albert Luthuli Central Hospital, Durban, South Africa.

If a lesion is found in the anterior surface, the posterior wall of the stomach must be thoroughly inspected through the lesser sac. A wound in the posterior surface may be the only lesion in patients wounded from behind.

Because of the rich vascularization of the organ, wounds of the body should be closed in two layers to control oozing of blood. Any repair leaving a narrowed lumen in the antrum or the pylorus requires a pyloroplasty or gastro-jejunostomy. Occasionally, a partial gastric resection may have to be performed because of extensive damage, especially to or near the pylorus or first part of the duodenum (Figures 32.42.1 and 32.42.2). Damage control for the stomach is provided by a strong continuous interlocking suture to ensure haemostasis and prevent contamination.

The peritoneal cavity and, in the case of thoraco-abdominal wounds, the pleural cavity must undergo thorough toileting if either has been contaminated by gastric contents. Isolated wounds of the stomach do not require a drain.

### 32.15 Small bowel

The small intestines occupy a large volume of the peritoneal cavity and are consequently the most common site of injury. Occasionally, perforations may be small and sealed off by protruding mucous membrane or, if old, covered by fibrin and adhesive omentum. The only evidence of perforation at laparotomy may be a small amount of blood without intestinal content. On the other hand, some lesions may be large lacerations with manifest contamination of the peritoneal cavity. The presence of associated injury to other abdominal organs significantly affects the clinical presentation and outcome of small bowel injury.

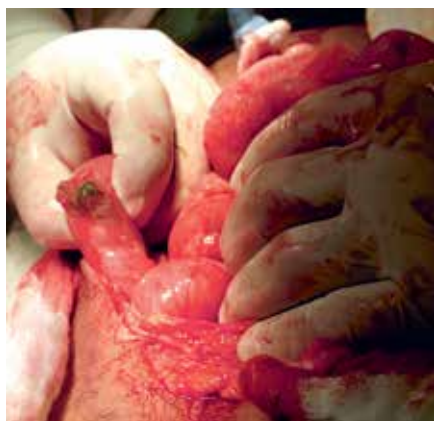

Figure 32.47.1

Small punctate wound with protruding mucosa.

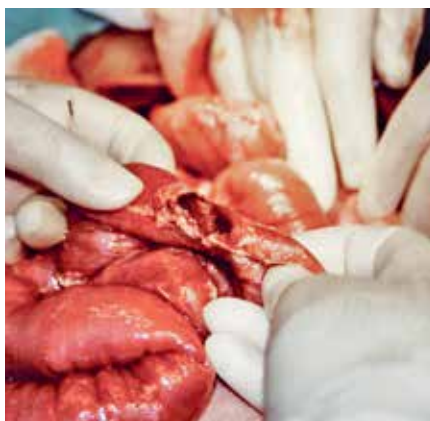


Figure 32.47.2

Large horizontal laceration.

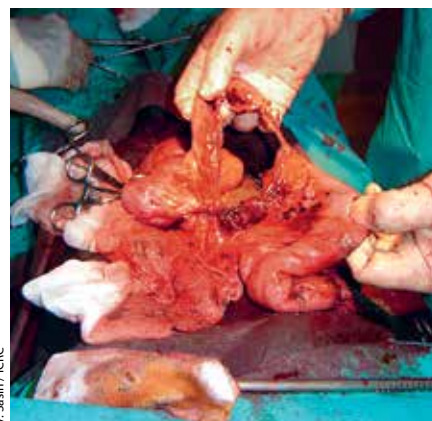

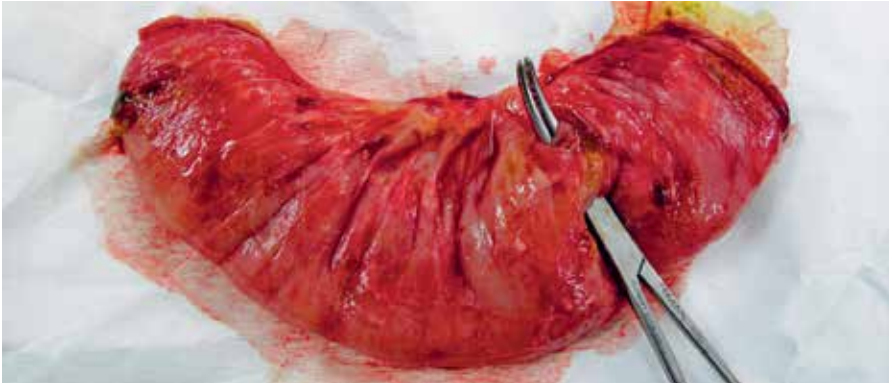
Figure 32.47.3

Severe devascularizing injury of the bowel.

As mentioned, the small bowel must be inspected carefully throughout its entire length twice before making any final decision whether to repair or resect. Perforations should be even in number; only occasionally, if a projectile has been retained within the bowel lumen or proceeds tangentially along the bowel length, is the number odd.

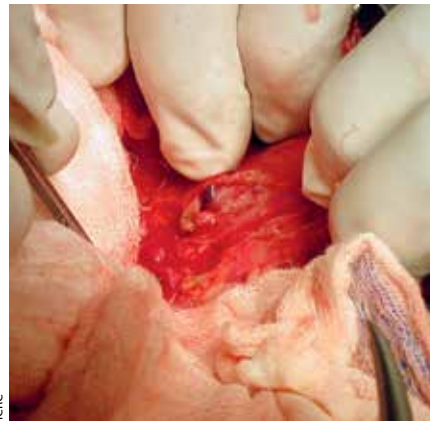
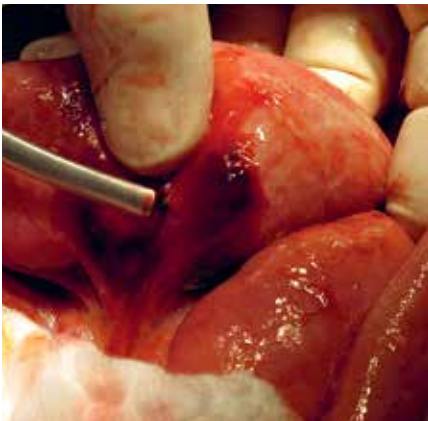#### Old lesson for new surgeons

Be suspicious of an odd number of perforations!

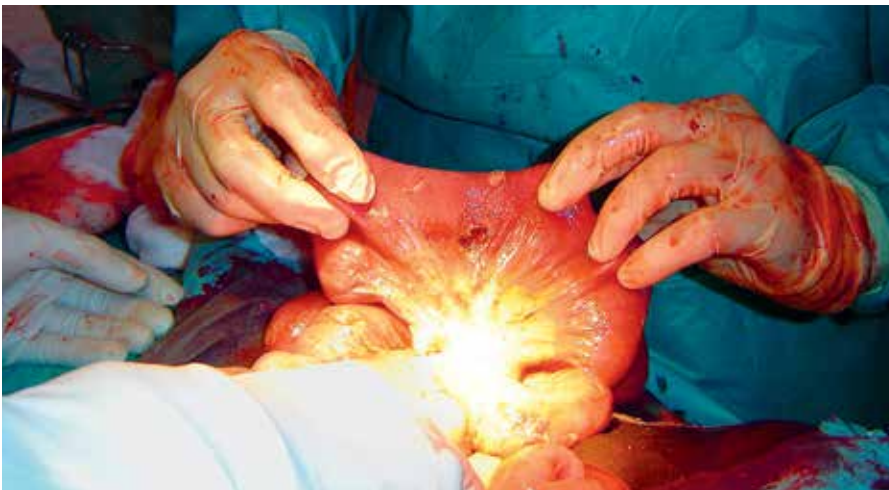

**Figure 32.48**  
Even number of perforations.

The mesentery must be checked carefully and bleeding spots sutured rather than ligated after incision of the overlying peritoneum. This is particularly the case for a haematoma in the root of the mesentery, which must be controlled by finger pressure, the peritoneum dissected, and the bleeding vessel identified. As anywhere in the body, blind clamping is to be condemned. Furthermore, a haematoma adjacent to the bowel may hide a small perforation.



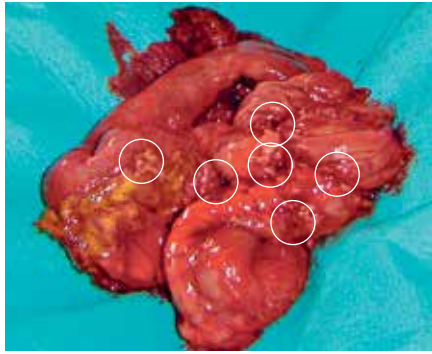
**Figures 32.49.1 – 32.49.3**  
Mesenteric haematoma adjacent to bowel wall.



Take care not to miss hidden small perforations near the ligament of Treitz and at the mesenteric border of the bowel.

Superficial serosal lesions due to a projectile should be sutured, subserosal haematomas unroofed, and small isolated perforations closed by suture in one or two layers after debridement of the edges. Small bowel resection and anastomosis is necessary for:

- a large laceration;
- multiple small perforations found over a short length (one anastomosis is better than multiple closely-spaced suture repairs);
- disruption of the bowel along the mesenteric border; or
- mesenteric injury compromising the blood supply to a segment.



V. Sasin / ICMC

**Figure 32.50**

Resection of a long segment of intestine with multiple perforations.

The technique of small bowel anastomosis – one layer or two – depends on the surgeon's training and experience, and the use of a stapling device on its availability.

Primary blast injury to the small intestines begins in the mucosa, as mentioned previously. Consequently, any serosal lesion indicates damage to the full thickness of the intestinal wall and requires excision.

Damage-control techniques for the small bowel include simple ligation proximal and distal to any perforation or ligation of the ends of resected bowel without anastomosis.

Isolated small bowel injuries treated by either direct repair or resection-anastomosis do not warrant drainage of the peritoneal cavity. Passage of a nasoduodenal tube helps to decompress the intestines.

## 32.16 Colon

Given its large volume, the colon is the most frequently injured organ in war trauma along with the small bowel. Injuries to additional structures are common and greatly influence the management and prognosis. Besides catastrophic haemorrhage, colonic injury – because of its potential for sepsis – is the main factor that determines morbidity and mortality, which is seldom less than 15% in contemporary war surgery.

Upon opening the abdomen, injury to the visible colon is obvious, but there may be very little evidence of a lesion in the retroperitoneal colon. Suspicion is the rule if there is any *faecal smell* or *retroperitoneal haematoma*, especially if associated with *surgical emphysema*. Similarly, the posterior wall of the transverse colon, although intraperitoneal, is easily overlooked because it is "hidden" under the overlying omentum. As always, the surgeon should count the number of perforations. And, as with the small bowel, any subserosal haematoma, especially at the mesocolic border, should be unroofed to check the integrity of the intestinal wall. Mesocolic injuries are particularly serious because the blood supply to the damaged segment is often compromised; the vasculature of the colon is much more fragile than that of the small bowel.

Once again, be suspicious of an odd number of perforations!

### 32.16.1 General principles of treatment

During World War II, surgical dogma decreed that any injury to the colon required a colostomy. There was good reason for this given the high mortality following colonic lesions in an era of limited antibiotics and resuscitation. Subsequently, civilian surgeons faced with increasing numbers of low-energy handgun wounds, and benefiting from the time and relative comfort of working in specialized centres, called this dogma into question – again with good reason. Many studies have been published promoting the more conservative techniques of primary repair or resection-anastomosis, thus avoiding a colostomy.

"No two trauma victims are the same and penetrating colonic wounds are associated with the complete spectrum of severity: from small isolated low energy transfer wounds with no obvious peritoneal contamination seen shortly after injury, to the high energy transfer wound causing extensive colonic damage, massive faecal contamination and multiple associated injuries having lain on the battlefield for many hours."

C.A.J.P. Royle<sup>15</sup>

16 Royle CAJP. Colonic trauma: modern civilian management and military surgical doctrine. *JR Soc Med* 1995; **88**: 585 – 590.



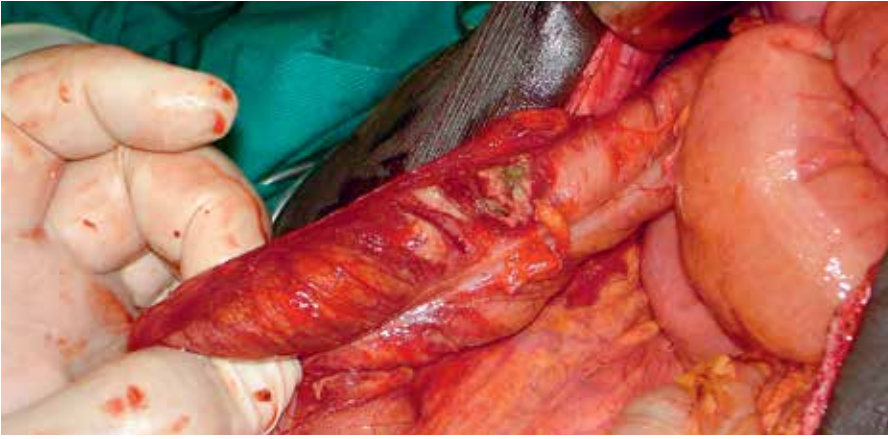

Figure 32.51.1

Very small perforation near the splenic flexure of the colon with slight faecal contamination present: a low-energy transfer wound. The odour on opening the abdomen gives away the presence of the wound, which may not otherwise be obvious.

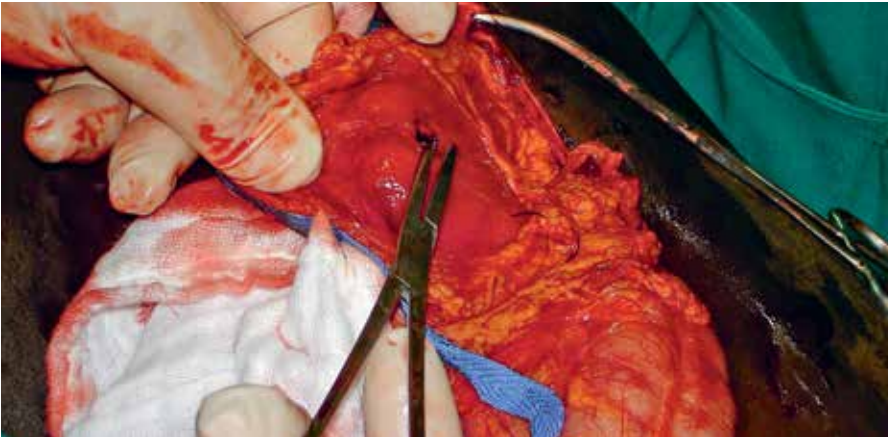

Figure 32.51.2

Larger hole in the splenic flexure of the colon.

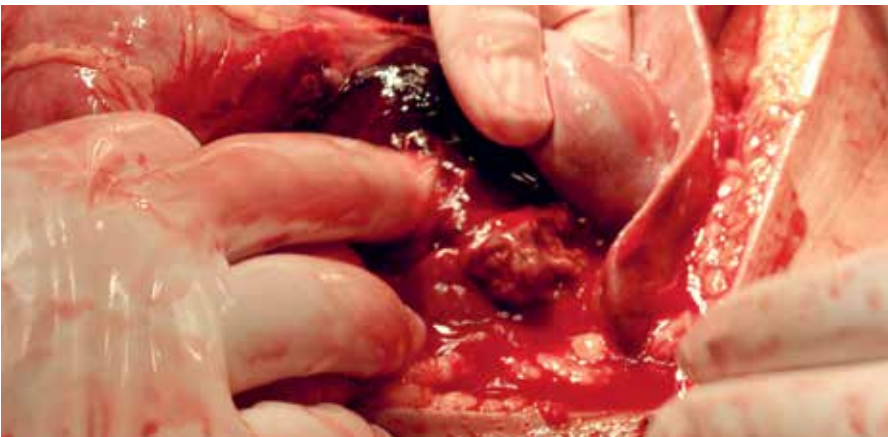

Figure 32.51.3

Large bloody laceration of the splenic flexure.

Today, with a better understanding of the pathophysiology, it is possible to differentiate lesions of the colon. They are not all the same, and many factors must be taken into consideration; although no single one is determinant, the overall picture is.

For a surgeon dealing with war trauma under limited resources, it is relevant to consider the following aspects.

- Age and general or nutritional status of the patient.
- Time since injury and the development of peritonitis.
- Total blood loss and presence of shock on admission.
- Right colon or left colon: fluid faeces or hard faecal mass with a much larger bacterial load.
- Degree of faecal contamination.
- Size and nature of the lesion: small puncture, large destructive laceration or devascularizing injury to the mesocolon.

- Mechanism of injury: small fragment, bullet with cavitation effect, or blast causing indeterminate thrombotic phenomena in the adjacent colonic tissues.
- Extent of local damage to the surrounding extracolonic tissues, perhaps indicating a high-energy lesion.
- Blood loss and haemodynamic stability on table.
- Availability of blood for transfusion.
- Need for damage-control approach.
- Number, extent and nature of other abdominal organs injured.
- Other extra-abdominal injuries.
- Mass casualties or few patients or a single patient.
- Experience of the surgeon!

A great many factors can influence the surgeon's decision to perform primary repair or diversion. A few are known for their absolute importance: shock; number of other abdominal organs injured; extent of faecal contamination; and time since injury.

The relative importance of the others has not been entirely determined by research or experience. Perhaps of greater consequence, the statistical significance of different combinations of these factors remains unknown. Hence the overriding importance of the experience of the surgeon.

The most important factor in determining the most appropriate operative procedure is the experience of the surgeon.

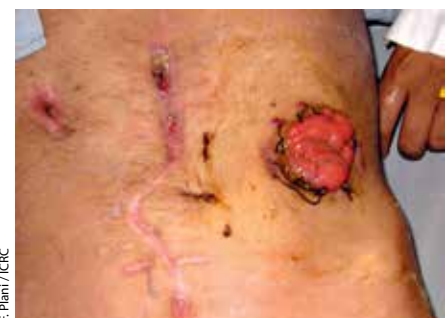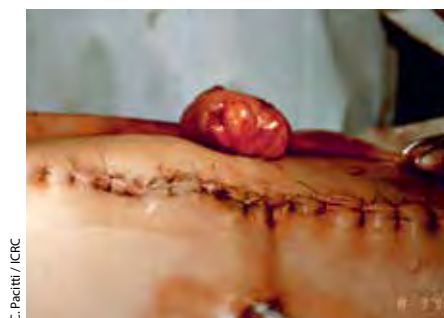It is the experience of the surgeon that permits a proper assessment of the significance of all the other factors and determines the most appropriate operative procedure for each particular patient: simple primary suture, resection-anastomosis, or diversionary colostomy.

Fit the operation to the patient, and the surgeon.

There are a number of technical operative points that are of particular relevance.

- Sero-muscular tears without penetration of the mucosa should be suture plicated.
- Colonic anastomoses should not be under tension and, therefore, the intestine must be adequately mobilized.
- The viability of the tissues around the direct lesion is critical for anastomotic security. These may be more contused and devitalized than is apparent, which is why the edges must be cut back to viable bleeding tissue – the antimesocolic edge even more than the mesocolic – resulting in an oblique cut.

Figures 32.52.1 and 32.52.2  
Well-fashioned colostomy.



Similarly, the creation of a proper colonic stoma requires considerable surgical competency and is not without its complications.

- A stoma should never be brought out through the exploratory midline incision; a separate flank incision should be made.
- The bowel must be properly mobilized, retraction of a stoma may occur all too easily following post-operative bloating of the abdomen or in an obese patient.
- When a proximal colostomy plus a distal mucous fistula are constructed, they should if possible be adjacent to each other to facilitate later closure.
- A stoma should not be used in damage control. The construction of a proper stoma takes time and a rapidly-fashioned one may easily retract with post-operative swelling and abdominal distension. Its presence also makes re-operation more difficult.

The peritoneal cavity should be copiously washed out and large dependent drains placed in the paracolic gutters when there is extensive faecal contamination of the abdominal cavity. Drains should not be placed adjacent to suture lines.

The damage-control procedure for wounds of the colon is either to tie off the bowel proximal and distal to the lesion with or without resection of the injured segment or to close the colonic wound with a running suture. At definitive re-operation, close examination of the bowel wall for oedema that might compromise an anastomotic line is necessary, in which case diversionary stoma is advisable, especially after blast injury.

Please note:

The following recommendations according to anatomic segment are intended as general guidelines, taking all the factors enumerated above into consideration.

### 32.16.2 Right colon


The right colon is easily mobilized and in many respects resembles the small intestine.

1. Under optimal conditions simple wounds of the right colon can be treated with primary suture.
2. In more problematic cases, any repair or suture line can be protected by a decompressive caecostomy. A wide-bore de Pezzer or Foley catheter is placed through the site of the appendix and held in place by a purse-string suture. The catheter is brought out in the flank and the caecum tacked to the abdominal wall. After a week, the catheter is removed and the faecal fistula closes spontaneously a week later.
3. If there is a significant disruption of the colon, right hemicolectomy and primary ileo-transverse colostomy is warranted.

### 32.16.3 Transverse colon

The transverse colon is the most accessible and mobile part of the organ, but part of it is "hidden" under the omentum.

1. Small lesions under optimal conditions can be treated by primary suture, with or without a caecostomy.
2. Large lacerations of the hepatic flexure or proximal third of the transverse colon may be treated by extended right-hemicolectomy and primary ileo-transverse colostomy.
3. Extensive injuries of the central or distal third of the transverse colon should either be exteriorized as a colostomy or undergo resection and anastomosis, protected by a caecostomy if necessary.



**Figure 32.53**  
Decompressive caecostomy.

### 32.16.4 Left colon and intraperitoneal rectum

The choice between primary repair and diversion is most problematic when dealing with lesions of the sigmoid colon and rectum. The left colon can easily be exteriorized, but adequate mobilization is mandatory to prevent stoma retraction.

1. Small lesions of the left colon may be sutured or undergo primary resection-anastomosis, but again only under optimal conditions. Otherwise, a protective transverse colostomy or caecostomy is advisable.
2. In extensive injuries under less than optimal conditions, the damaged segment should be resected and the ends brought out as a double-barrel colostomy.
3. Extensive rectal lesions may necessitate resection and a modified Hartmann's procedure: the proximal end is brought out as a colostomy and the distal stump sutured closed. If at all possible the distal stump should be stitched to the anterior abdominal wall by a non-absorbable suture, leaving the cut ends long to facilitate its identification at re-operation. Alternatively, the stump may be placed extraperitoneal under the closed peritoneum. Apparently it makes little difference whether the stump is emptied of faeces manually or not, since they tend to be expelled spontaneously afterwards.

Figures 32.54.1 and 32.54.2

Modified Hartmann's procedure.

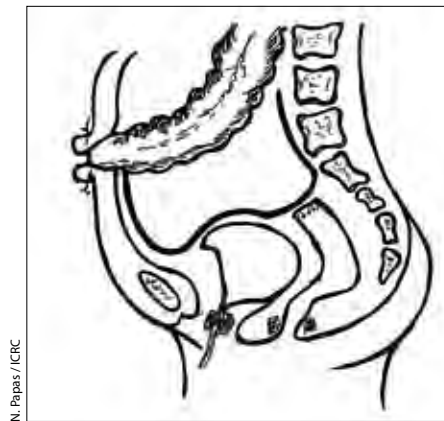


Figure 32.54.1

Upper rectum closed under the peritoneum.

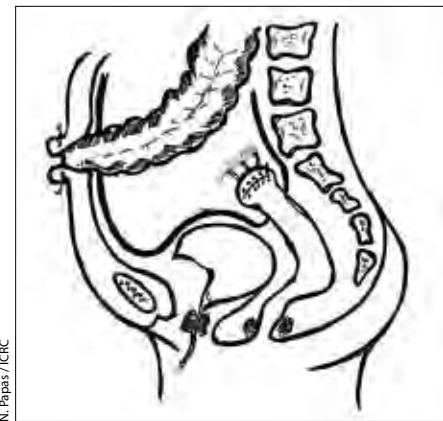


Figure 32.54.2

Upper rectum closed intraperitoneally and tacked to lateral abdominal wall.

The Hartmann's procedure should only be used if it is impossible to bring out the distal end as a mucous fistula. When it comes to closing the colostomy, finding and dissecting free the terminal stump can be a difficult and bloody operation should adhesions have occurred. A rectal tube inserted into the distal stump may also help identify and localize it.

For the inexperienced surgeon working under challenging conditions the simple rule is: when in doubt, divert, and make a colostomy.

### 32.16.5 Retroperitoneal missile tract

Any projectile passing through the colon and then into the retroperitoneal soft tissues is bound to carry some contamination with it. The degree of contamination is related to the energy of the missile; a low-energy fragment carries bacteria only into the first centimetre of the track. Like all other low-energy fragment wounds to soft tissue the retroperitoneal track does not require debridement. Antibiotics and the body's natural defence mechanisms are capable of dealing with the slight contamination present. Furthermore, unnecessary debridement of the retroperitoneal muscles significantly increases the rate of infection, ischaemia and suture dehiscence.

On the other hand, large wounds of the retroperitoneal muscles with much greater tissue damage and contamination caused by high-energy projectiles do require proper surgical excision and irrigation in order to prevent a retroperitoneal abscess and necrotizing infection.

### 32.16.6 Complications

Morbidity is particularly high with combat injuries of the colon. The most frequent and serious causes are infectious in origin, while others involve primarily the diversionary colostomy. They include:

- leak of an anastomosis or repair leading to faecal fistula and possibly an intra-abdominal abscess or diffuse peritonitis;
- bleeding from an anastomosis;
- wound infection and dehiscence;
- peristomal bleeding;
- retraction of a colostomy stoma;
- prolapse of a stoma;
- ischaemia and necrosis of a stoma;
- stenosis of a stoma and obstruction;
- parastomal hernia.

The surgeon should not hesitate to perform a second “re-look” operation if an infectious process is suspected. On the other hand, most faecal fistulae can be managed conservatively. Problems with the stoma should be dealt with as soon as possible.

### 32.16.7 Colostomy care

Even a temporary colostomy is psychologically difficult for the patient to accept and, for cultural and social reasons, in some societies even more so. Many patients have such an aversion to the colostomy that they believe that if they do not eat, the faecal flow will lessen. On the contrary, such behaviour simply prolongs the period of post-injury catabolism. The situation must be explained simply to the patient and family and the temporary nature of the colostomy made perfectly clear.

Furthermore, in many countries colostomy bags are not available for economic reasons. Even when available, proper fitting to avoid slipping and soiling or escape of gas, or irritation of the skin, make colostomy bags difficult to manage.

Good skin care around the stoma, simple washing with soap and water and drying, proper hygiene, and a good nutritious diet are the basis of nursing management. The diet can be adapted to avoid excess gas, constipation or fluidity of the faeces.

There is a simple alternative to sophisticated gums and gels and bags, based on the fact that the colon is a reservoir for faeces that does not need to be emptied continuously. Vaseline gauze is placed over the stoma and then covered with a piece of clean cloth. This is kept in place by a wide belt or elastic bandage tightened appropriately to serve as a girdle. The cloth and belt operate as a tamponade, effectively corking closed the colostomy stoma. The girdle is removed in the morning and in the evening to empty the bowel, the skin cleansed, and the simple apparatus re-applied.

### 32.16.8 Colostomy closure

Traditionally, closure of a colostomy is performed after three months once the patient has fully recovered. Recently, this practice has been called into question. Patients with a relatively minor burden of injury and an uncomplicated recovery can undergo colostomy closure after *two to three weeks*. Closure before discharge is particularly important in certain contexts of armed conflict where patients may easily be lost to follow-up.

When the post-operative course is complicated by a fistula or infection the closure should be postponed for as long as it takes for the patient to recover fully and regain weight. This might be as long as several months.

A prior barium enema is indicated only in cases of early closure of a proximal defunctioning colostomy to confirm healing of the distal injury. This is not necessary if the injured segment itself has been exteriorized as a colostomy.

Closure of the colostomy may be extra- or intraperitoneal; the latter is preferred. Significant oedema may be present in the limbs of a loop stoma and ischaemia may affect the part of the bowel wall traversing the abdominal wall. The colon should be cut back to good viable, bleeding edges.

### 32.17 Pelvis

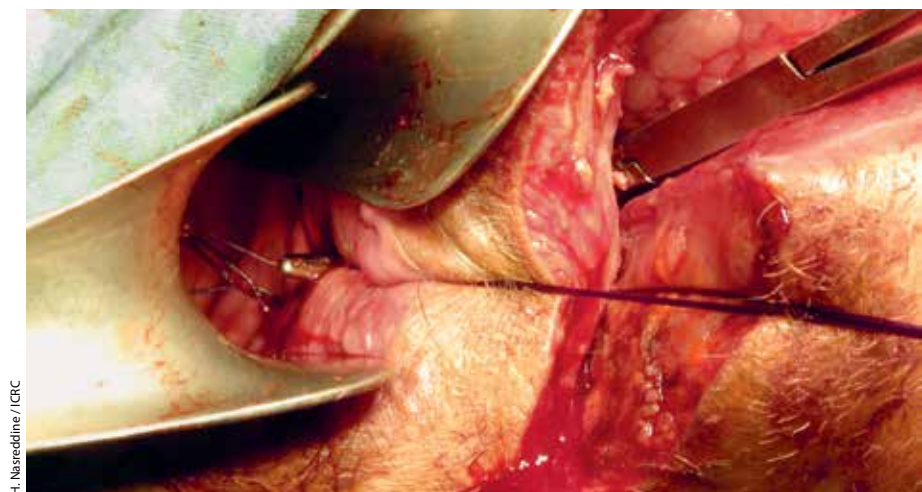
Wounds of the pelvis may involve the bony girdle or soft tissues. The important sources of haemorrhage are the iliac vessels and their branches and the presacral venous plexus. Contamination from the gastro-intestinal and urogenital tracts requires diversion and drainage. Wounds of the extraperitoneal viscera are associated with high morbidity because of the frequency of unrecognized injury and the commonly associated vascular damage in a small enclosed space. Furthermore, the cellular tissue of the perirectal space may develop rapidly spreading mixed aerobic and anaerobic infection.

The pelvis may be involved in wounds of the upper thighs, buttocks or perineum, as well as the abdomen. Close observation is especially necessary for injuries due to anti-personnel landmines; the characteristic Pattern 1 injury often includes the perineum.

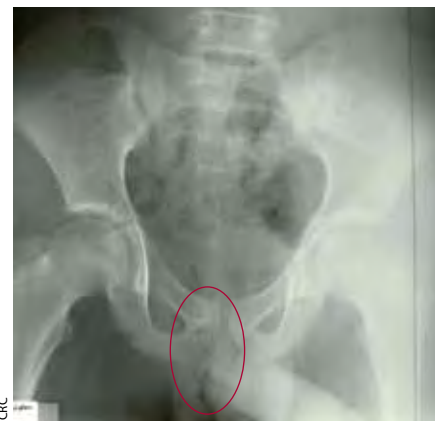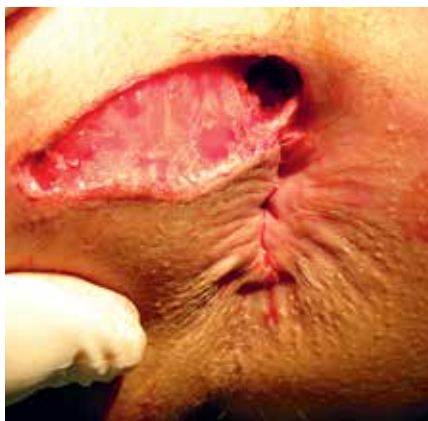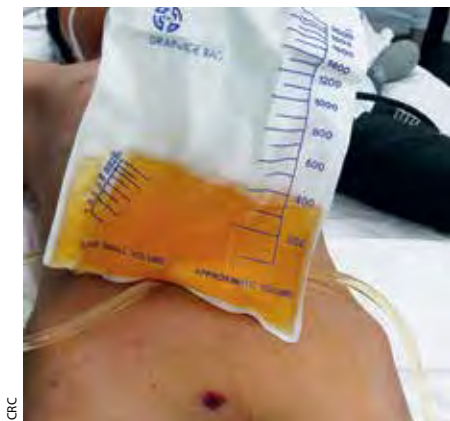
Digital rectal examination may reveal a defect or laceration of the rectal wall, a lack of sphincter tone, or bony spicules from a fracture, in addition to blood on the examining finger. Examination of the femoral pulse is essential.

**Figure 32.55**

Repair of a perineal wound extending into the anus.



H. Nasreddine / ICRG



Figures 32.56.1 – 32.56.3

GSW to the pelvis without any serious injury. The entry was suprapubic and the exit at the medial aspect of the right buttock; the left buttock was grazed. Only a simple fracture of the ischio-pubic ramus was detected.

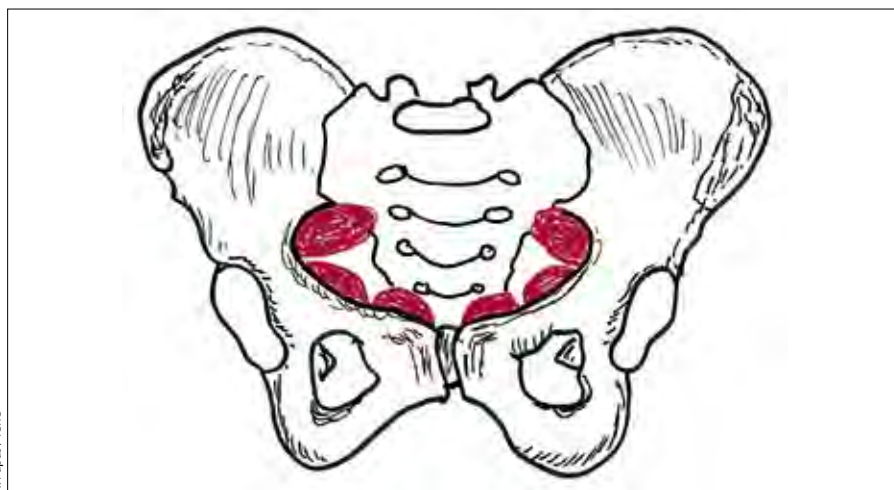
### 32.17.1 Pelvic fractures

After projectile injury, unlike after blunt trauma, unstable fractures are quite rare and displacement of the fragments seldom needs reduction. Fracture of the pelvic ring requires immobilization for eight to twelve weeks. The pelvis is bound in a bedsheet-sling passed across the greater trochanters and suspended from a beam, or simply placed circumferentially around the pelvis and clamped anteriorly. The use of external fixation is an advantage if the fracture is very unstable or to make nursing care easier in the presence of a colostomy stoma or perineal wound.

The major risk in pelvic wounds comes from bone fragments which penetrate the viscera and vessels in a confined space.

A retroperitoneal haematoma associated with a fracture of the pelvis should not be explored providing that injury to the extraperitoneal rectum and bladder can be excluded. Injury to the iliac vessels requires exploration, as does a lateral haematoma behind the colon and close to the ureter.

An alternative for significant bleeding from a pelvic fracture is extraperitoneal pelvic packing. This method has been described for blunt trauma and is usually performed before a laparotomy is attempted. It can be adapted and used during a laparotomy for penetrating trauma.



N. Papas / ICRC

Particular attention should be paid to any injury to the nearby hip joint in conjunction with an abdominal visceral injury. The joint should be considered contaminated and must be explored and treated as an open joint injury in order to avoid septic arthritis.

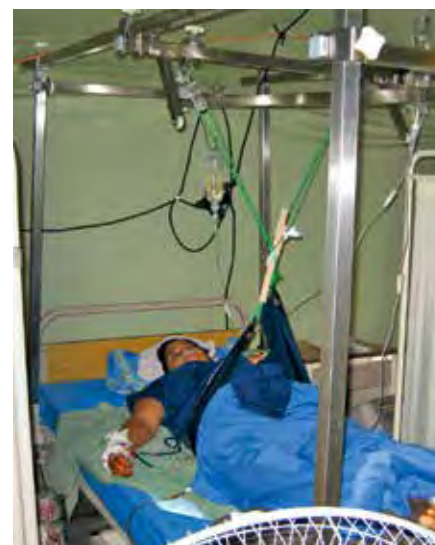

Figure 32.57

Bedsheet-sling immobilization of the pelvis.

Figure 32.58

Extraperitoneal packing: the first pack is placed below the sacro-iliac joint; the second at the middle of the pelvic brim; and the third in the retropubic space just lateral to the bladder. The packing is repeated on the other side.

The soft-tissue wound accompanying the fracture should not be neglected. It is often the cause of infectious complications and requires thorough debridement, irrigation, and drainage. As usual, it is left open for delayed primary closure.

### **32.17.2 Injury to the iliac vessels**

The internal iliac vessels can be ligated. Bleeding from the distal branches can be difficult to control even after bilateral ligation of the main trunks since there is an abundant collateral system. In some patients the source of bleeding may be outside the bony pelvis, and blood flows into the pelvis along the projectile track. In this case, a damage-control approach is warranted: Foley catheter tamponade is often successful; otherwise packing may be the only alternative to bring the bleeding under control.

The common and external iliac arteries should be repaired if possible. These vessels are very amenable to the use of a temporary shunt as a damage-control procedure. Ligation to stop life-threatening haemorrhage is a last resort – at the cost of limb ischaemia; a high percentage of patients go on to amputation. The accompanying veins should be repaired if at all possible, or temporarily shunted; mortality and morbidity rise greatly if the vein is ligated. A distal fasciotomy, elevation of the limb, and compression stockings post-operatively are always warranted no matter which vascular procedure is performed.

### **32.17.3 Sacral venous injury**

Profuse bleeding from the venous plexus subsequent to fracture of the sacrum is very difficult to control because the sectioned veins tend to retract under the bony surface and there are numerous communicating channels. The technical difficulty is compounded by having to work in the confined space of the pelvis. The haemorrhage can be exsanguinating.

During laparotomy the surgeon observes a large and expanding pelvic haematoma. There may or may not be a hole in the pelvic peritoneum, with blood issuing from it if present. If trauma to the iliac vessels, rectum or urogenital tract is diagnosed or cannot be excluded then the pelvic peritoneum must be opened for proper examination and control of the injuries.

The simplest technique to obtain control of haemorrhage coming from the sacral venous plexus is to pack the pelvic cavity with rolled abdominal pads over a piece of crushed muscle or a local haemostatic, if available. The pads can also be placed within empty sterile i.v. fluid bags to prevent adhesion to the raw surface and assist in their removal. To properly place the pack, the iliac vessels and ureter must be identified and retracted. The pelvic peritoneum should then be sutured closed to assist the tamponade effect.

If other injuries can be excluded, a simple and useful method to control sacral bleeding is to insert a Foley catheter through the peritoneal hole made by the projectile and tamponade the presacral space. The peritoneum is sutured tightly around the catheter in a purse-string fashion and the Foley brought outside the abdomen on the opposite side of a possible stoma. The outlet of the Foley is closed by a ligature to stop the exit of blood. After 48 hours, the outlet is opened and the balloon deflated for 6 hours. If haemorrhage recurs, the balloon is re-inflated; if it does not, the catheter can be withdrawn without a second laparotomy.

Many methods have been attempted for definitive control should haemorrhage recur after packing or Foley tamponade has been removed. These include inserting thumbtacks into the sacrum, plugging with bone wax or fragments of harvested muscle or a local haemostatic agent, electrocautery through a fragment of muscle, etc. Individual successful cases have been reported, but none of these techniques has proven universally satisfactory and control of haemorrhage may prove impossible to accomplish. The surgeon should rather resort to re-applying packing over a local haemostatic or piece of crushed muscle.

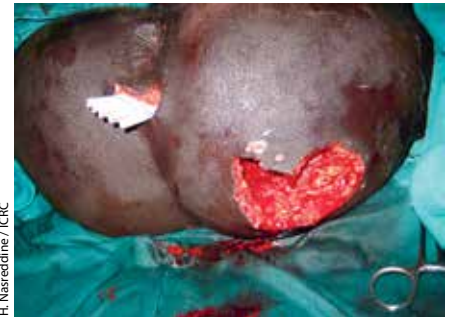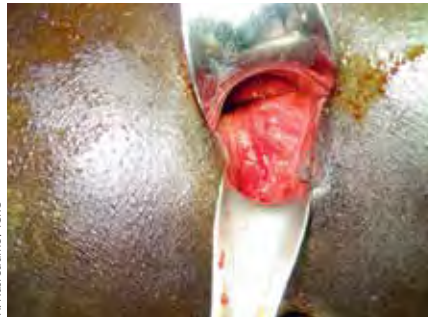

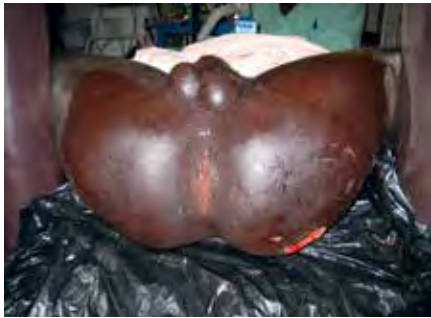
### 32.17.4 Extraperitoneal rectum and anus

Wounds of the extraperitoneal rectum and anus are accompanied by a very high rate of concomitant injuries to nearby structures. The resulting faecal contamination of the pelvic areolar tissues may lead to severe infection that can prove fatal. One consequence has been that operative management has long advocated the classic "4D's": divert, drain, direct repair, and distal washout.

As with injuries to the colon, some of these principles have recently been called into question. Minor, low-energy wounds involving less than 25% of the circumference of the rectal wall have been successfully managed in specialized trauma centres by observation, antibiotics and a clear liquid diet, without diversion or drainage. Nonetheless, given the almost universal damage to nearby structures and the risk of infection in combat injuries, the traditional "aggressive" management continues to be the safest approach when working with limited resources and is recommended by ICRC surgeons.

Injury to the rectum or anus is usually diagnosed pre-operatively by a simple rectal examination. However, if at laparotomy the pelvic peritoneum is found to be intact then it should not be opened unless there is a concomitant injury to other pelvic structures requiring access from above. Isolated rectal or anal injury can be managed from below in addition to a diverting colostomy.



Figures 32.59.1 – 32.59.3

Isolated injury to the anus managed from below with an accompanying colostomy.

#### Diversion

A proximal loop or double-barrel sigmoidostomy is considered to be the most critical part of management.

#### Direct repair

Access to the extraperitoneal rectum within the bony confines of the pelvis is difficult and does not lend itself to reliable repair. Exposure may be easier via the anus, especially for a very low lesion. Exposure for repair of other structures may permit debridement and repair of a rectal wound, which should be attempted if at all possible. Unrepaired small wounds heal by secondary intention.

#### Distal washout

Manual faecal evacuation *per anum* followed by irrigation of the bowel distal to the colostomy is appropriate only insofar as it helps to identify and repair the injury. Washing the distal rectum lessens the bacterial burden, but it may also force contaminants into the tissue planes. Therefore, mild pressure such as that from a running intravenous line is best. A large rectal tube may be left in place after anal dilatation, with or without distal washout, to assist in the spontaneous evacuation of any retained faeces.

There is one other instance in which emptying the rectum may be called for. Many soldiers are dehydrated and constipated, given their living conditions in the field. Impacted and hard faeces should be removed manually in these patients.

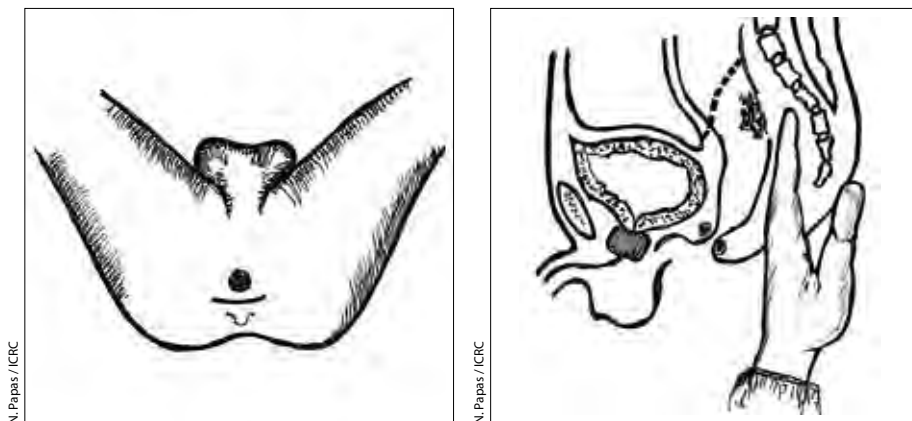
#### Drainage

Extensive faecal contamination of the perirectal tissues requires dependent drainage. An incision between the anus and coccyx permits drainage of the presacral space.

A debrided perineal wound may be sufficient for adequate drainage. Presacral drainage may have to be replaced by temporary packing in cases where the venous plexus has been injured.

Figures 32.60.1 and 32.60.2

Presacral drainage of an extraperitoneal rectal lesion via a transverse incision posterior to the anus. Removal of the coccyx may be helpful.



Serial debridements of anal and perineal wounds may be necessary; especially if, as is often the case, there is concomitant injury to the urogenital tract. Injury to the bladder or vagina requires individual repair of the different organs and an omental pedicle flap interposed between suture lines.

If detached, the anal mucosa should be stitched to the surrounding skin if at all possible. Particular attention should be paid to the anal sphincter; primary repair should be attempted for minor lesions. However, a staged reconstruction is required to deal with severe loss of tissue. Very extensive injuries with loss of the sphincter may require an abdominal-perineal resection and permanent colostomy. Uncontrollable bleeding may also necessitate such a drastic procedure.

## 32.18 Abdominal drains

The placing of intra-abdominal drains is a contentious topic. A generation ago, surgeons used to implement four-quadrant drainage after most major laparotomies: subhepatic, subsplenic, right paracolic gutter and Douglas pouch. The idea was to prevent the accumulation of any fluids that might lead to a peritoneal abscess. A better understanding of pathophysiology has shown that the presence of a drain, on the contrary, is more likely to result in infection. A drain is a foreign body and provokes an inflammatory peritoneal reaction by its mere presence, as well as providing a channel for the introduction of bacteria. Furthermore, a drain drains only its own track given the reactivity of the omentum and small intestines. Draining the entire peritoneal cavity is physiologically impossible. Consequently, a far more conservative policy of peritoneal drainage is more commonplace today.

Nonetheless, in certain cases a drain is necessary:

- extraperitoneal injuries;
- oozing surfaces (liver, visceral oedema fluid);
- a source of definitely deleterious fluids, for which drainage is a mainstay of treatment (pancreatic/duodenal injury or extrahepatic biliary leak);
- localized infection, for which drainage is again a mainstay of treatment (e.g. subphrenic abscess).

Care must be taken when placing a drain: if close to an intestinal anastomosis it is detrimental to the healing process and may cause a breakdown and leakage.

Whenever drains are used, they should be large-bore tube drains with several side holes and connected to urine bags, thus creating a closed system and rendering nursing care easier. They should be brought out through separate dependent incisions. If suction is available, sump drainage is useful when dependent drainage is not possible (Figure 32.35). Direct suction drainage is contraindicated: the negative pressure only helps to erode the intestines and create a fistula.



Figure 32.61

Some patients require multiple drains.

Drains should be removed as soon as possible and most can be removed after 24 hours, except for those draining the pancreas/duodenum, bile ducts, and extraperitoneal urinary tract.

Drains should be dependent and removed as soon as possible.

## 32.19 Post-operative care

### Antibiotics

Abdominal trauma carries a high risk of infection, particularly associated with increased age, injury to the colon, the presence of shock on arrival, a large number of units of blood administered at surgery, and a large number of injured organs.

The ICRC protocol for antibiotics calls for a five-day course and may be an exaggeration; many authors call for 24 hours only.<sup>17</sup> The most important factor is early administration: pre-hospital is best, pre-operatively if possible in the emergency room, or very soon intra-operatively at the latest.

### Analgesia

Adequate control of pain is important after major surgery to help combat shock and assist in physiotherapy and ambulation, as well as for the patient's comfort. Limited resources and combat trauma should not be an excuse for patient suffering.

### Physiotherapy

Physiotherapy and early mobilization of the patient are essential to avoid pulmonary complications, stiffness of joints, wasting of muscles, and deep vein thrombosis. Getting the patient out of bed, and deep breathing and coughing exercises are essential.

### Nutrition

As a general rule, naso-gastric tubes should be removed as soon as possible and intake of fluids and food by mouth started early. Normal peristalsis of the small intestine occurs within 12 – 24 hours, of the stomach within 24 – 48 hours and of the colon in 3 – 5 days. However, there is no need to wait for full peristaltic activity and the passage of flatus as traditionally taught. A change in the colour of naso-gastric aspirate from green to clear, denoting an absence of bile reflux into the stomach, is probably a sufficient indication of good bowel transit.

The best indicator is the patient's ability to feed without vomiting, bloating or pain. Oral fluids can usually be taken after 24 hours and small feedings the next day. In fact, small early feedings have been shown to stimulate the gastro-intestinal transit and promote the mobilization and diuresis of extracellular fluids.

Intravenous feeding with amino acids or fat solutions is rarely possible in conditions of limited resources. Enteral feeding of blenderized regular food through a feeding gastrostomy or jejunostomy is a useful and practical adjunct to some procedures.

### Urinary catheter

A urinary catheter for monitoring the patient's fluid balance should be removed as soon as possible to avoid ascending urinary infection, in most cases within 24 hours. In severely injured or dehydrated patients, however, it is wise to keep the catheter longer. After bladder injuries, the catheter should be kept for a week (see Section 33.7).

### Incisions and wounds

Dry dressings of the sutured laparotomy incision need not be changed until removal of sutures. If dressings have become soaked with blood or pus, the wound must be opened and thoroughly inspected. Dressings of excised wounds in the abdominal wall, like all soft-tissue wounds, should be left undisturbed until delayed primary closure.

17 The antibiotic protocol for abdominal wounds was updated by the Second ICRC Master Surgeons Workshop, Geneva, December 2010, and changed from 3 – 5 days to cover a full five days to make nursing orders easier (see Annex F.3).

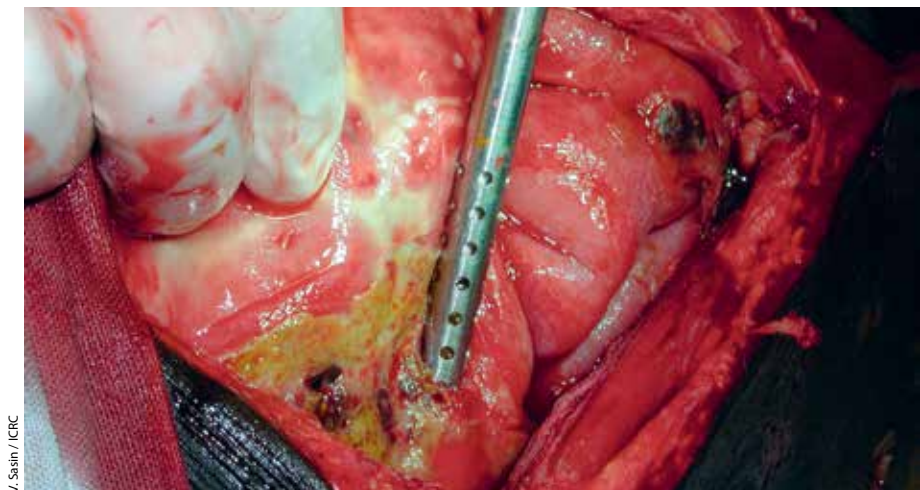
## 32.20 Post-operative complications

Complications occur in anywhere between 20% and 60% of the patients who have suffered abdominal trauma, depending on the severity of injury and general condition of the patient. The most important life-threatening conditions include continuing or recurrent haemorrhage, missed injuries giving rise to peritonitis or enteric fistulae, and multiple organ system failure and acute respiratory distress syndrome (ARDS).

Abdominal complications are numerous and many are common to all forms of abdominal surgery. Some are particular to projectile trauma; the most important include the following.

- Infection:
  - intra-abdominal abscess around a foreign body (shrapnel, bit of clothing, a stone, non-absorbable suture);
  - osteomyelitis (rib, pelvic bones and hip joint, lumbar vertebrae, or even a distal fracture);
  - meningitis if the spinal cord is also injured.
- Sinuses and fistulae:
  - caused by a foreign body;
  - low-output enteric fistula from shrapnel retained in the bowel wall.
- Intestinal obstruction:
  - due to adhesions around a foreign body;
  - following herniation of an abdominal organ through a wound of the diaphragm.
- Incisional hernia:
  - at the site of a colostomy stoma;
  - of an entry or exit wound.
- Post-traumatic acalculous cholecystitis in young males who have suffered severe injuries.

**Figure 32.62**  
Post-operative peritonitis.



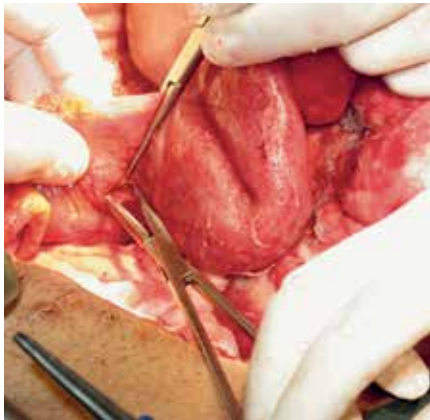
V. Sasin / CRC

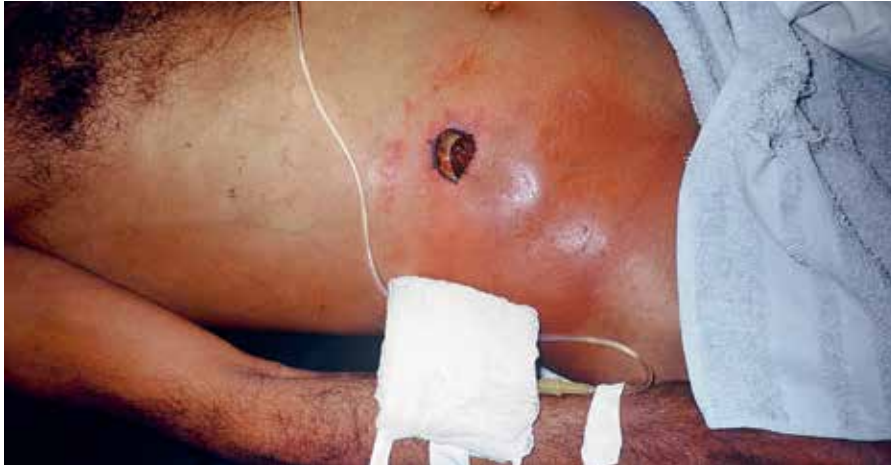
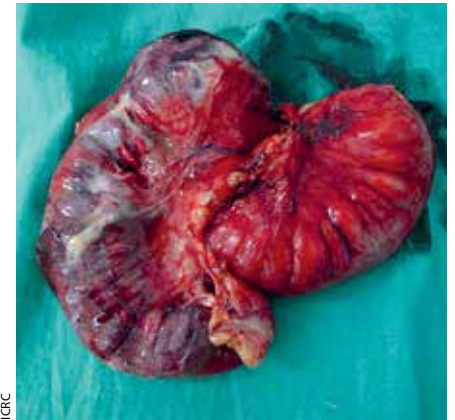
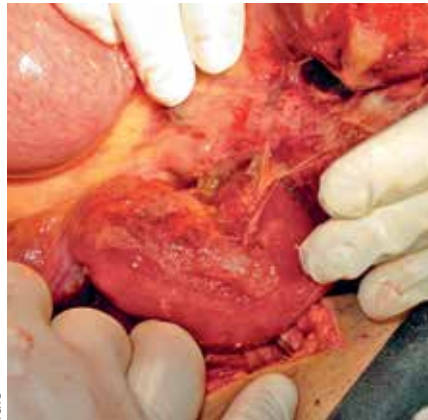Figure 32.63

Necrotizing fasciitis of the abdominal wall.

Some complications require immediate surgical intervention; others may be amenable to conservative treatment, such as enteric fistulae. Re-laparotomy for peritonitis is usually the result of a missed injury and carries a high risk of mortality unless performed very early.



Figures 32.64.1 – 32.64.3

Mismanaged and neglected patient injured by a bomb explosion three days prior to admission. Multiple superficial lacerations were sutured at a private hospital. At the ICRC hospital, femoral artery repair was undertaken and a laparotomy then performed. There was no generalized peritonitis, but a perforation of the jejunum and a localized abscess with many adhesions resulting in necrosis of the caecum. Right hemicolectomy and ileo-transverse anastomosis were performed. The patient survived.

#### Post-operative fever

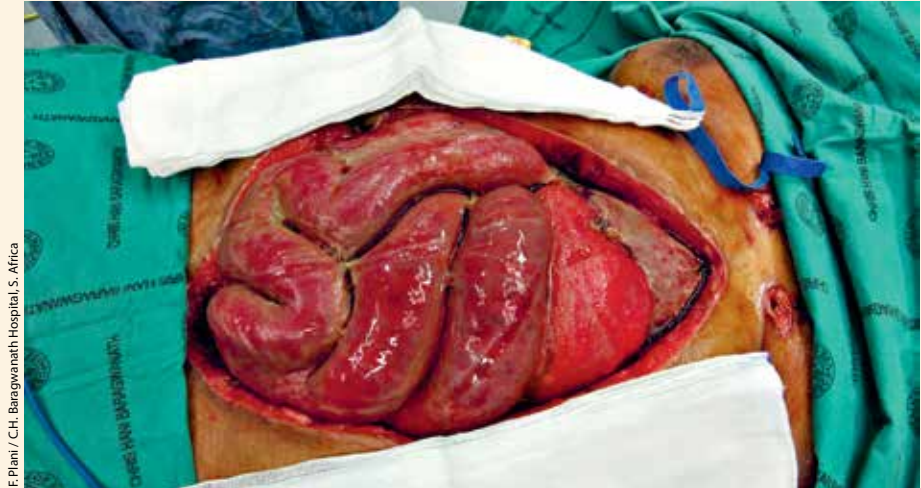Fever can result from well-known intra- and extra-abdominal causes, such as urinary tract infection, atelectasis or pneumonia, deep vein thrombosis, and sepsis. In countries where malaria is endemic, it is not unusual for the patient to have an acute attack 48 hours post-operatively after severe trauma. Even if a first malaria smear is negative, it may be wise to start malaria treatment preventively. Other endemic diseases such as typhoid fever must also be kept in mind.

## ANNEX 32. A Abdominal compartment syndrome

A compartment syndrome may affect any compartment of the body. It especially affects the abdomen after aggressive resuscitation with i.v. crystalloid fluids, which may be unavoidable when faced with a lack of blood for transfusion, and after major manipulation of the tissues, both leading to oedema of the viscera. An additional factor can be the presence of voluminous abdominal packs for tamponade of bleeding. Abdominal compartment syndrome has also been described in patients with extraperitoneal trauma and major burns.

Figure 32.A.1

Oedematous bowel: all too often the result of overzealous resuscitation with crystalloids.

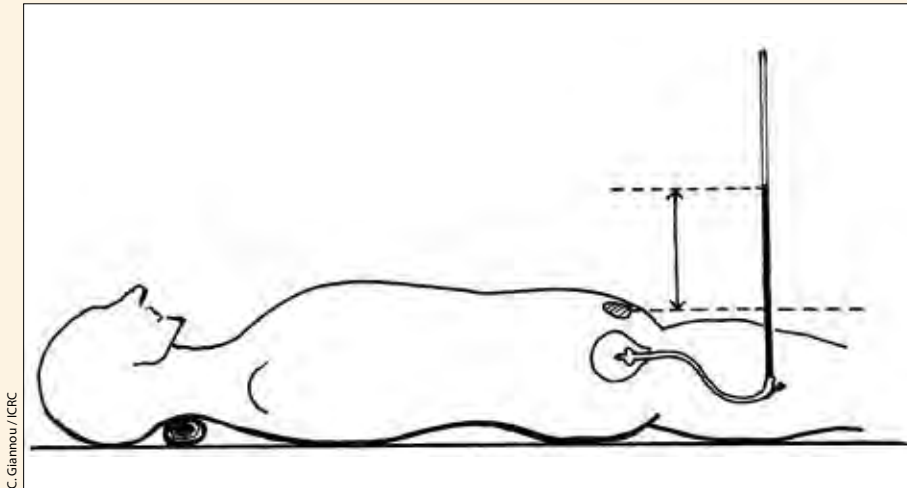


F. Plani / CH. Baragwanath Hospital, S. Africa

Clinically, increased intra-abdominal pressure is revealed by a distended, rigid, and tympanic abdomen; but clinical observation does not correlate well with actual pressures. A clinical compartment syndrome occurs, however, only when the raised pressure results in organ dysfunction. Sustained excessive abdominal hypertension produces multiple organ failure, which is first manifested by oliguria, difficult inspiration due to the raised diaphragm, and decreased cardiac output due to a compressed vena cava.

Intra-abdominal pressure is most easily measured indirectly via the intravesical pressure. Figure 32.A.2 demonstrates a simple method. The patient lies supine and relaxed with no abdominal muscle contractions. A Foley catheter empties the urinary bladder; 50 ml of normal saline are instilled by sterile technique. The catheter outflow tubing is raised and held 50 – 60 cm above the patient. The meniscus of the column of saline should fluctuate with respiration, and suprapubic pressure should raise its level. The measurement is taken one minute after instillation and at the end of expiration. The zero point is at the symphysis pubis in the midline.

Normal bladder pressure ranges between 0 and 5 mm Hg and normal post-laparotomy pressure is 10 – 15 mm Hg (1 mm Hg = 1.36 cm H<sub>2</sub>O). Measurements above 20 mm Hg (27 cm H<sub>2</sub>O) require urgent treatment. As with many physiological measurements, one absolute number is of little value; serial measurements denoting a trend is of greater clinical significance.



**Figure 32.A.2**

Measurement of intra-abdominal pressure via the intravesical pressure: indirect method. Height of column of saline from meniscus to symphysis pubis equals bladder pressure in cm of H<sub>2</sub>O.

Alternatively, if the bladder has been injured, measurements can be taken via a naso-gastric tube. The stomach is emptied and 50 ml of saline instilled. Measurements, taken from the midaxillary line, are  $\pm 2.5$  cm H<sub>2</sub>O of the bladder pressure.

Treatment for raised abdominal pressure is at first medical:

- naso-gastric and rectal tube for decompression;
- fluid restriction;
- diuretics;
- mannitol;
- sedation and analgesia.

Failure of medical treatment (the pressure continues to rise) or excessive abdominal hypertension (it is already high when first diagnosed) must be released by performing a *decompressive laparotomy* and leaving the abdomen "open" as after damage-control laparotomy. Should multiple organ failure have developed in a hospital with limited resources the outcome is usually fatal.





## **Chapter 33**

# **UROGENITAL TRACT INJURIES**

33.	UROGENITAL TRACT INJURIES	
33.1	Introduction	487
33.2	Wound ballistics	487
33.3	Epidemiology	487
33.4	Examination and diagnosis	488
33.5	Kidneys	488
33.5.1	Severity of injury	488
33.5.2	Surgical decision-making	490
33.5.3	Non-surgical management	490
33.5.4	Patient preparation, incision, and access	490
33.5.5	Surgical treatment	491
33.5.6	Nephrostomy	492
33.5.7	Nephrectomy	492
33.5.8	Partial nephrectomy and renorrhaphy	493
33.5.9	Bilateral renal injuries	494
33.6	Ureters	494
33.6.1	Diagnosis	494
33.6.2	Surgical decision-making	495
33.6.3	Surgical treatment of transected ureter	496
33.6.4	Surgical treatment of contused ureter	499
33.6.5	Delayed diagnosis and complications	499
33.7	Urinary bladder	500
33.7.1	Diagnosis	500
33.7.2	Surgical treatment	500
33.8	Prostate and posterior urethra	501
33.8.1	Diagnosis and ER care	501
33.8.2	Surgical treatment	501
33.8.3	Sequelae and complications	503
33.9	Male external genitalia and anterior urethra	503
33.9.1	Diagnosis	503
33.9.2	Surgical treatment	503
33.10	Female genitalia and urethra	506
33.10.1	Diagnosis	506
33.10.2	Surgical treatment	506
33.11	Post-operative care	507

## Basic principles

Many injuries are discovered only on table.

Many injuries of the ureters and bladder are missed entirely until they present with a complication.

The urine flow above the injury must be diverted and drainage should be dependent.

Kidney injuries are usually treated either conservatively by drainage alone or by nephrectomy.

### 33.1 Introduction

The urogenital tract (UGT) is part of the abdomen and pelvis and the examination of the patient for wounds of the UGT is part and parcel of the general abdominal examination. This separate chapter is for reasons of clarity only. Exploration of the great majority of UGT injuries is by the standard laparotomy.

Management of combat injuries of the urogenital tract follows the basic principles of war surgery *and* urology.

### 33.2 Wound ballistics

The kidney, like all other solid organs, is not elastic and will shatter if subjected to cavitation. Exposure to an explosion can result in contusion or laceration of the renal parenchyma, the pathology resembling that of blunt trauma. It is usually relatively minor and self-limiting in survivors.

The urinary bladder, like other hollow organs, reacts differently to a projectile depending on whether it is full or empty. A projectile will simply perforate the empty bladder through its elastic muscular wall. The full bladder displays a "boundary effect" (see Section 3.4.3) and cavitation within the fluid contents results in a great increase in the hydraulic pressure causing the organ to "explode".

The ureters are relatively mobile and tend to "flee" before a projectile. Nonetheless, their delicate segmental blood supply can be damaged by the cavitation effect causing thrombosis, ischaemia and late necrosis with the development of a urinary fistula. The same effect may be seen following primary blast injury.

The external genitalia and perineum are most often injured by direct projectile crush and laceration, particularly frequent following pattern 1 anti-personnel mine injury.

### 33.3 Epidemiology

Combat wounds of the urogenital tract are found in only 2 – 4% of all the wounded and constitute 10 – 15% of abdominal organ injuries (Table 32.2). Injuries to the kidneys are far more common than those to other parts of the UGT. The wearing of modern body armour, however, decreases the relative incidence of injury to the kidneys and ureters, but increases that of wounds to the lower urinary tract.

Projectile injuries to the urinary tract are rarely isolated: 75 – 90% of the patients have associated injuries. Particular note should be made of the high incidence of concomitant spinal cord injury and paraplegia suffered by up to 40% of patients with projectile wounds to the kidneys. Isolated injury to the kidneys tends to occur with tangential wounds or injuries to the back.

The external genitalia, more exposed, may be injured in isolation or in association with other structures of the perineum or pelvis, especially by APM.

### 33.4 Examination and diagnosis

The abdominal examination as described in Section 32.4.3 includes all the elements of the urogenital tract. Small projectile wounds in the skin folds of the perineum may not be obvious at first glance. Complete examination and ER care of the patient include a rectal and vaginal examination and the placement of a urinary catheter. Proper care in the insertion of the latter is warranted in case of injury to the genitalia and is contraindicated in avulsing injuries.

Haematuria due to UGT injury is irregular and may be difficult to detect owing to the oliguria of shock. It also correlates poorly with the degree of severity of the injury, except when frank haematuria with clots in the bladder is present. On the other hand, many patients with severe abdominal trauma not involving the UGT present microscopic haematuria.

Renal trauma due to projectiles causes gross haematuria only if the calyceal system is entered, and it can be exsanguinating. However, significant renal trauma, including injuries to the renal vascular pedicle, may occur in the absence of gross or even microscopic haematuria: this can be the case in more than half the patients. Trauma to the ureter has an even more unpredictable presentation of haematuria than the kidneys. Only bladder injury presents consistently with obvious haematuria.

In general, the severity of injuries to the torso keeps investigations to a minimum and only rarely can an intravenous pyelogram (IVP) be carried out pre-operatively if a urinary tract injury is suspected, even when the facilities are available. Diagnosis of the exact location of injuries to the UGT is almost never pre-operative. The patient undergoes laparotomy for other suspected abdominal injuries and the damage is discovered on table – or the injuries are missed, especially in the case of the ureter or extraperitoneal bladder, and discovered only when a complication develops.

Intra-operative one-shot high-dose IVP can be helpful and it has been used by many surgeons, but the facilities are not always to be had. The main points to look for when radiography is possible are:

- any extravasation of the dye;
- the presence and function of the non-injured kidney;
- any anatomic anomalies, either congenital or acquired (“horseshoe” kidney, hydronephrosis, hydro-ureter, etc.).

Another intra-operative diagnostic method is the direct visualization of excreted intravenous dye, such as methylene blue or indigo carmine. Retrograde instillation of a dye through a urinary catheter may assist in detecting a lesion of the bladder.

### 33.5 Kidneys

The main objectives in the management of renal injury are to control bleeding and preserve as much renal tissue as possible, as long as preservation of renal function is compatible with the need to deal with other life-threatening injuries. The preservation of at least 25% of the renal parenchymal mass is necessary to avoid dialysis.<sup>1</sup>

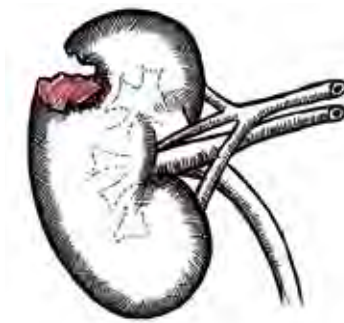
#### 33.5.1 Severity of injury

Severe projectile injury to the kidney is manifested by shock that requires immediate abdominal exploration. Most injuries present with a retroperitoneal haematoma and may be classified according to their severity. A simple grading system adapted to ballistic injuries is presented in Figure 33.1. More sophisticated grading systems exist, but are more pertinent to blunt trauma.

1 Carroll PR, McAninch JW. Operative indications in penetrating renal trauma. *J Trauma* 1985; **25**: 587 – 593.

**Grade A**

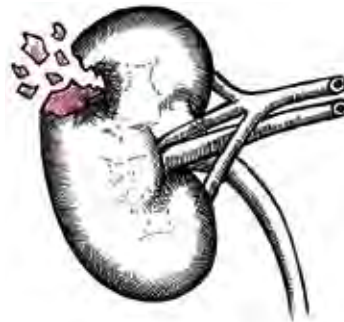Parenchymal contusion or laceration alone without extravasation of urine.



N. Papas / ICRC

**Grade B**

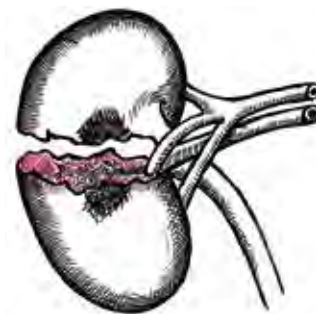
Deep laceration involving the calyceal system with extravasation of urine.



N. Papas / ICRC

**Grade C**

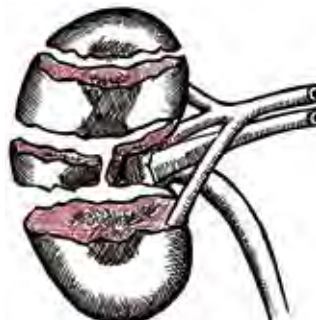Complete rupture of the kidney.



N. Papas / ICRC

**Grade D**

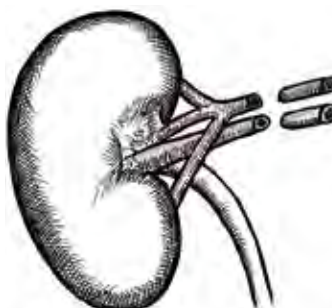Shattered kidney.



N. Papas / ICRC

**Grade E**

Injury to the vascular pedicle.



N. Papas / ICRC

**Figures 33.1.1 – 33.1.5**

Schematic drawings of renal injuries according to severity.

### 33.5.2 Surgical decision-making

**Haemorrhage from projectile wounds to the kidney can present in four different ways:<sup>2</sup>**

- free bleeding into the peritoneal cavity following disruption of Gerota's fascia;
- expanding perirenal haematoma;
- exsanguination into the renal collecting system presenting as haematuria and even with clots in the bladder;
- stable retroperitoneal haematoma.

The extent of renal damage is obvious only in the case of a shattered kidney, vascular lesion, or exsanguinating haematuria, all of which demand exploration of the kidney. Otherwise, the surgeon is faced with a perirenal haematoma (see Section 32.11).

Several options are possible depending on the nature of the haematoma and the status of the patient.

1. A small and stable haematoma in a stable patient can be left as it is (Grade A).
2. A moderate to large haematoma in a stable patient, denoting a Grade B or C injury, should be explored in order to repair and salvage the kidney.
3. If the patient is haemodynamically unstable owing to other injuries and a damage-control approach is chosen, it is better not to explore a haematoma over a Grade B or C injury; the kidney should in that case simply be packed. Later, when the patient is stabilized, an IVP can be performed and the second operation planned better.
4. A shattered kidney (Grade D) or injury to the vascular pedicle (Grade E) results in massive haemorrhage if free-flowing, or a rapidly-expanding haematoma if contained; both require exploration and usually nephrectomy.
5. If a stable patient has undergone an IVP and extravasation of urine is seen, exploration is mandatory since the injury is always accompanied by parenchymal tissue damage that requires debridement.

### 33.5.3 Non-surgical management

Some patients may suffer small low-energy fragment wounds to the flank or back and present with haematuria and/or a tender renal angle on palpation, but remain in a stable condition without other signs of abdominal injury. IVP generally confirms the isolated and limited renal injury, usually with no extravasation of urine. These injuries are more like stab wounds of the parenchyma and can be treated expectantly.

Kidney damage must always be suspected after explosive blast injury. Renal concussion presents clinically with flank pain. However, follow-up IVP studies are usually normal and therefore many times unnecessary.

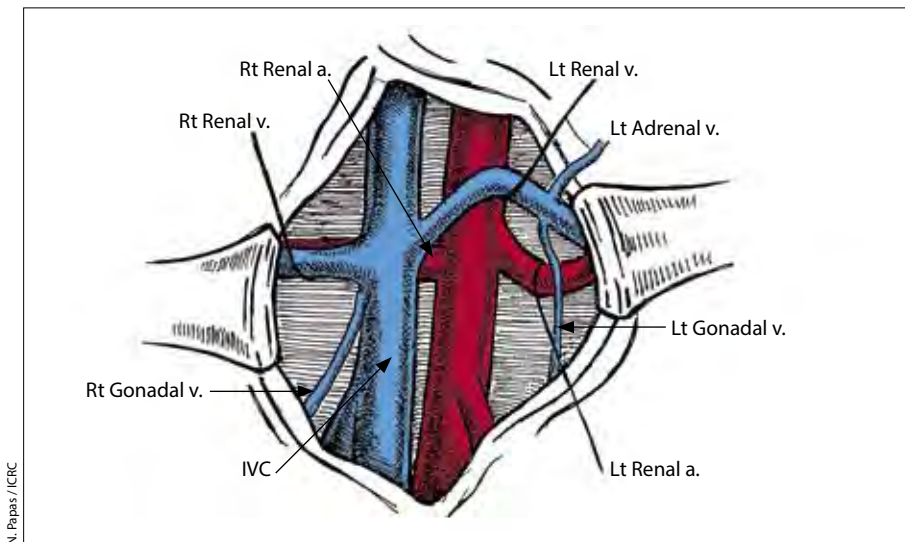
Both conditions can be managed with bed rest and adequate resuscitation ensuring a good urine flow. Close monitoring of such patients is warranted, as for blunt trauma, and surgery is indicated only if severe macroscopic haematuria persists over 48 hours and/or the patient becomes unstable as a result of blood loss.

### 33.5.4 Patient preparation, incision, and access

The patient should be prepared as for any laparotomy and the standard midline incision employed. The flank incision of elective urological procedures has no place in the emergency treatment of the war trauma patient since intraperitoneal injury cannot be ruled out.

2 Adapted from Schechter SC, Schechter WP, McAninch JW. Penetrating bilateral renal injuries: principles of management. *J Trauma* 2009; **67**: E25 – E28.

Access to the kidney should permit vascular control. Two approaches are available, depending on the patient's condition. In the first, the small intestines are retracted and the peritoneum incised over the aorta medial to the inferior mesenteric vein, approaching the renal vessels anteriorly (Figure 33.2). This requires time for dissection and should only be employed in a stable patient where repair and salvage of the kidney are the objectives. Medial-visceral rotation as for exposure of the great vessels is the preferred choice for the unstable patient (see Sections 32.11.1 and 32.11.2). Many surgeons prefer visceral rotation for any exploration of the kidney; the dissection is already accomplished by the haematoma and allows speedy control of the vessels. In both approaches, the renal pedicle is compressed between the fingers (renal Pringle manoeuvre) to control bleeding before the application of vascular clamps.



**Figure 33.2**

Exposure of the renal vessels medial to the inferior mesenteric vein and anterior to the aorta.

### 33.5.5 Surgical treatment

#### Grade A: superficial parenchymal laceration without extravasation of urine

A perinephric haematoma of variable size has developed. If the haematoma is small and stable it should be left as it is without opening Gerota's fascia. Extraperitoneal drainage of the renal area should be established. Later, in the post-operative recovery period, an IVP can be performed.

#### Grade B: deep laceration involving calyx/pelvis with extravasation of urine

A small to moderate sized haematoma is found or a urine leak cannot be ruled out. The kidney is explored; damaged parenchyma is debrided and haemostatic mattress sutures placed. Any raw surface is covered by approximation of the renal capsule, an omental pedicle flap, or a free peritoneal graft.

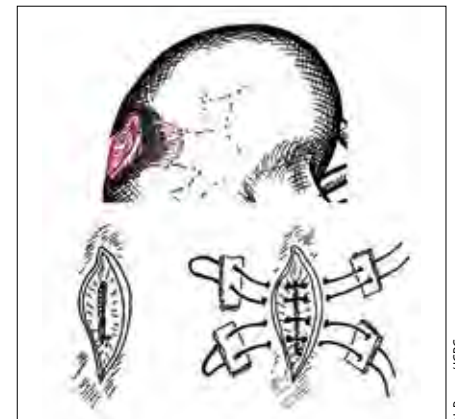
When, a minor laceration of a calyx is encountered, it should be repaired with a continuous watertight 4/0 absorbable suture. Retrograde injection of methylene blue into the ureter, while pinching it closed distally, helps determine any leak or unrecognized injury.

The surgeon more frequently finds a larger lesion of the parenchyma extending into the calyceal system. After debridement and placement of haemostatic sutures the edges are approximated as much as possible. If the parenchymal wound can be closed this should be done, covered with an omental or peritoneal flap, and a lower pole nephrostomy made (Figure 33.7). If the wound is too large to close sufficiently, it can serve as a nephrostomy: an appropriate catheter is inserted through the wound into the renal pelvis (Figure 33.4). However, this should be avoided as much as possible.

Dependent perinephric drainage is instituted in all cases.

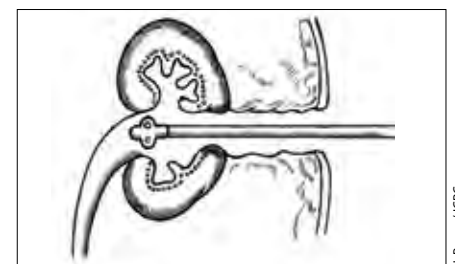
#### Grade C: complete rupture of the kidney

This lesion usually presents with a large and expanding haematoma. These injuries may be salvageable by partial nephrectomy, but only if the laceration occurs near a pole of the kidney. Partial nephrectomy and renorrhaphy are specialist techniques



**Figure 33.3**

Minor calyceal lesion debrided and repaired by a continuous watertight suture and haemostatic mattress sutures placed over peritoneal or fascial pledgets.

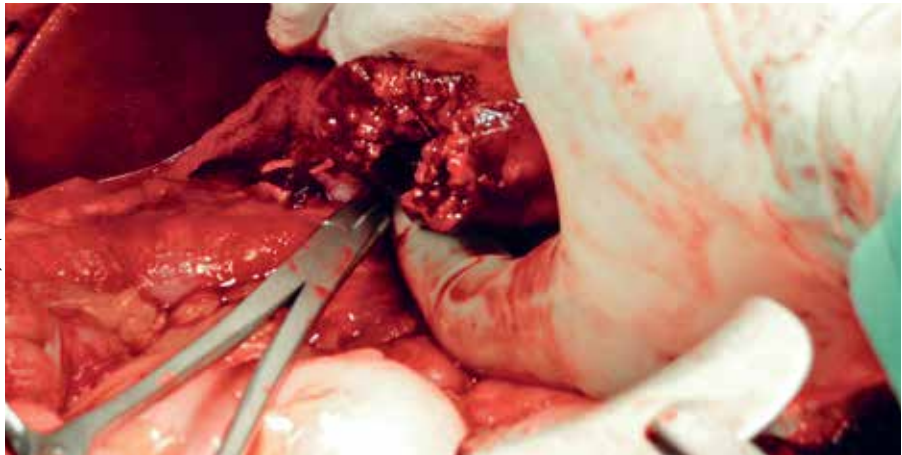

**Figure 33.4**

Nephrostomy through the renal wound itself; sometimes the only option.

Figure 33.5

GSW causing complete section of the inferior pole of the left kidney.



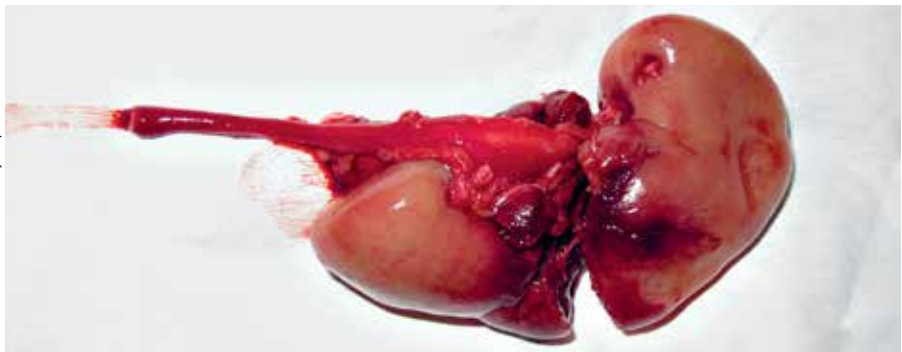D. Meckelbaum / McGill University Hospital

**Grade D: shattered kidney**

Nephrectomy is the only option.

Figure 33.6

The shattered kidney has been removed.



D. Meckelbaum / McGill University Hospital

**Grade E: injury to the vascular pedicle**

A pulsatile and expanding haematoma denotes vascular injury. Repair of the vessels can seldom be performed; nephrectomy is usually the outcome, if the patient does not die of exsanguination first. Only the left renal vein can be ligated with impunity since venous drainage is assured by the gonadal and adrenal veins.

**33.5.6 Nephrostomy**

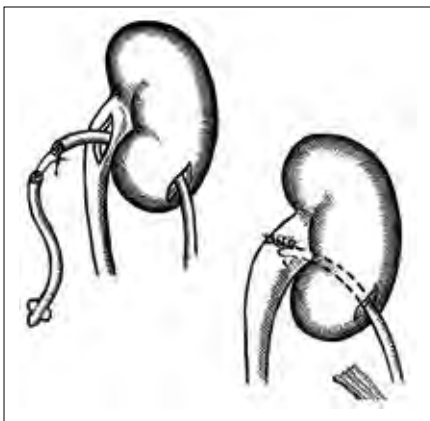
Percutaneous nephrostomy is rarely available when working with limited resources and the surgeon must resort to an open nephrostomy.

Nephrostomy is best performed through the renal pelvis to keep damage to the cortex to a minimum. An incision is made into the pelvis and a finger inserted into the lowest calyx. The renal cortex is then incised over the finger in the bloodless line of Brodel, lying 5 mm behind and parallel to the convex border. An appropriate catheter (Malecot, de Pezzer, or Foley) is placed through the incision into the calyx either directly or by the *chemin-de-fer* technique. The pelvis is repaired and the renal incision closed around the catheter by deeply placed interrupted absorbable sutures. A dependent drain is placed.

**33.5.7 Nephrectomy**

Nephrectomy is necessary for uncontrollable haemorrhage from a shattered kidney or irretrievable damage to the vascular pedicle. The surgeon must always ensure, by intra-abdominal palpation, the existence of a second kidney that “feels normal”.

If the patient’s condition permits and the facilities are available, an intra-operative single-dose IVP or i.v. injection of an excretable dye such as methylene blue is of great assistance in determining the status of the other kidney. Another, simple method is to see if the patient is still producing urine when the pedicle of the injured kidney is



N. Papas / ICRC

Figure 33.7

Nephrostomy: Cabot’s method through a pyelotomy.



clamped. If a second kidney cannot be found or is not functioning, partial resection must be performed, aiming to salvage at least 25% of the renal parenchymal mass.

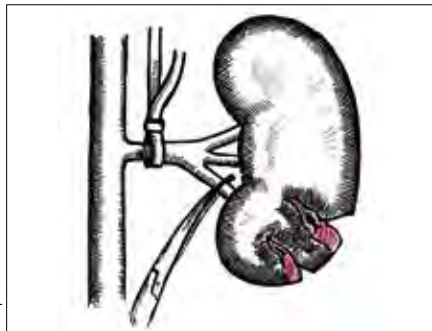
Nephrectomy is usually a “crash” procedure. The kidney is rapidly exposed by medial visceral rotation. The haematoma is entered laterally by incising Gerota’s fascia and the kidney scooped up by a hand passed behind it and brought medially. The renal pedicle is then simply pinched between the fingers before applying clamps. The procedure resembles the one used for a rapid splenectomy.

The vessels should be doubly ligated, preferably ligating the vein and artery separately and always ligating the artery first. The ureter should be divided and the distal end ligated.

### 33.5.8 Partial nephrectomy and renorrhaphy

Partial nephrectomy or renorrhaphy is not a simple operation and has a significant rate of complications such as urinary fistula and infection, often leading to delayed nephrectomy. If the patient is haemodynamically unstable, or the surgeon lacks the experience, it is best to proceed directly with nephrectomy, a technically easier procedure. The exceptions are the patient whose contralateral kidney is absent or where the renal function may be inadequate owing to a previous injury or disease, and the patient with bilateral renal injury.

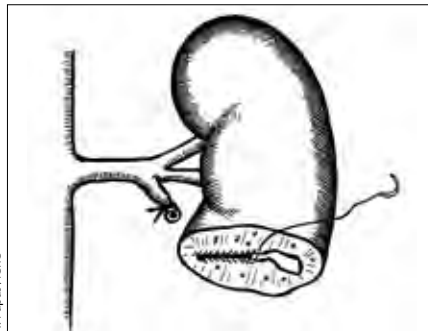
A partial nephrectomy is usually a “polar amputation” involving either the superior or the inferior pole of the kidney, but may also be used for a complete laceration of the middle of the kidney (Grade C lesion).



N. Papas /ICRC

**Figure 33.8.1**

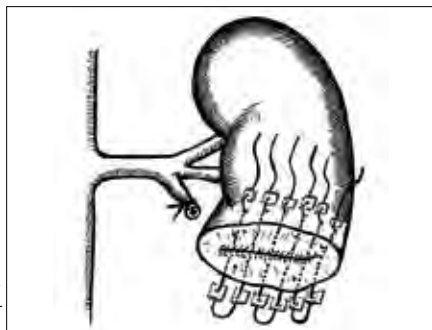
The sectoral artery to the damaged part of the kidney is clamped and divided. The main vascular pedicle is controlled by a vascular clamp or Rummel tourniquet.



N. Papas /ICRC

**Figure 33.8.2**

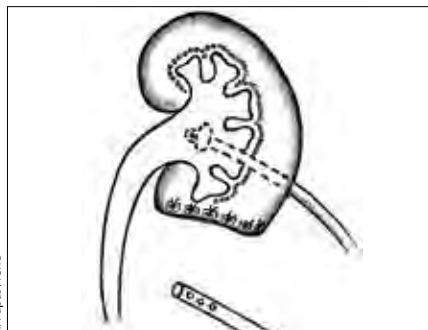
Debridement-resection is performed by finger-fracture. Meticulous haemostasis is assured by figure-of-eight suture-ligature with 4/0 absorbable suture. The pelvis and calyces should be closed watertight by a continuous 4/0 absorbable suture.



N. Papas /ICRC

**Figure 33.8.3**

The resected surface is compressed with mattress sutures over pledgets.



N. Papas /ICRC

**Figure 33.8.4**

The raw surface is covered with any remaining renal capsule or an omental pedicle flap or free peritoneal graft. The urinary flow is drained by means of nephrostomy. Dependent drainage of the kidney bed is instituted extraperitoneally and should not be removed until drainage has ceased.

**Figures 33.8.1 – 33.8.4**  
Partial nephrectomy.

According to some surgeons, Gerota's fascia should not be opened before the renal vessels have been exposed by the anterior approach and control of the vascular hilum obtained, since releasing the tamponade provided by the fascia may result in massive haemorrhage and an unnecessary nephrectomy. The full kidney is then exposed by medial visceral rotation. Many surgeons, however, prefer the medial visceral rotation in order to rapidly control the vessels.

### 33.5.9 Bilateral renal injuries

Injury to both kidneys is a dilemma and challenge even under the best of circumstances. As mentioned, at least 25% of the renal parenchymal mass is necessary to avoid dialysis, which is seldom available in low-income countries. Every effort must therefore be expended to preserve at least one-half of one kidney. In a stable patient, an on-table one-shot IVP can prove invaluable, if available. If a damage-control approach is adopted, both kidneys are packed and an IVP performed after resuscitation.

Different combinations of damage may appear.

1. Both kidneys have suffered severe damage, which is rapidly fatal owing to haemorrhage.
2. One kidney is severely injured and the other suffering only mild to moderate damage.

The bleeding kidney most probably requires immediate nephrectomy. The other kidney with mild to moderate injury should be loosely packed and the renal bed adequately drained extraperitoneally. An IVP is then performed post-operatively after resuscitation and the decision made to either observe, or re-operate to perform either partial nephrectomy or renorrhaphy.

3. Both kidneys show mild to moderate injury and stable perirenal haematomas. The patient's condition determines further management. If the patient is unstable because of other injuries the kidneys should be packed. Otherwise, the decision-making process should begin with the *smallest* haematoma first, in order to ensure at least one functioning kidney. Post-operative IVP helps determine further management in both cases.

A similar line of logic applies to the patient with injury to a single functioning kidney, whether the condition is congenital or derives from some other pathology.

## 33.6 Ureters

### 33.6.1 Diagnosis

Injury to the ureters is almost always associated with lesions to other intra-abdominal organs, which are more obvious and take precedence over the ureteric injury. Haematuria is often absent with ureteric injury, whether transection or contusion, and when present is usually microscopic.

Except in the rare instance of a pre-operative IVP revealing a transected ureter, the diagnosis is never made before exploration. In fact, the diagnosis of a ureteric injury is often missed during laparotomy and is made only post-operatively when a complication arises.

Delayed signs and symptoms include:

- persistent flank or abdominal pain;
- mass in the flank;
- urinary leakage as manifested by persistent high output from drains;
- haematuria;
- prolonged paralytic ileus;
- fever;
- elevated creatinine and blood urea nitrogen.

These denote the development of a complication: urinoma, urinary fistula, or infection. An IVP is called for and may show extravasation of urine or obstruction, ureteral deviation, dilatation, or non-visualization.

This emphasizes the need for a thorough exploration of all retroperitoneal peri-ureteric haematomas and all cases where a projectile trajectory passes near the ureter. Significant devascularization of the ureter can be caused by the cavitation effect of a high-energy missile or blast injury. Close inspection may show a transected or contused ureter.

Direct visualization of the ureter during operation is the best diagnostic tool.

An obviously bruised ureter with discoloration of the wall and absence of capillary refill denotes ureteric devascularization. In an undamaged ureter, a very gentle touch or squeeze elicits a vigorous peristaltic wave. Particular attention should be given to the state of the peri-ureteric tissues. Severe surrounding muscle damage indicates a high local release of kinetic energy; the surgeon should expect damage to a seemingly intact ureter to be greater than is first apparent to the naked eye. The contusion may resolve on its own, but it may well proceed to necrosis and fistula formation or to stricture if left untreated.

It should be noted that significant devascularization of the ureter can also be caused by iatrogenic crush from a haemostatic clamp or ischaemic injury from excessive dissection during hurried exploration of a haematoma.

If the haematoma precludes good visualization of the ureter an injection of methylene blue or indigo carmine, either intravenous or directly into the pelvis of the kidney through a fine needle, is a useful procedure. Of course, the patient's condition must be haemodynamically stable enough to carry this out.

An intra-operative one-shot high-dose IVP, even if available, is often not reliable. Only a complete IVP is accurate in diagnosing a ureteric injury. Contusion of the ureter often shows a normal IVP; a urinary fistula may develop in two days to two weeks post-injury, once the ischaemic segment has sloughed off.

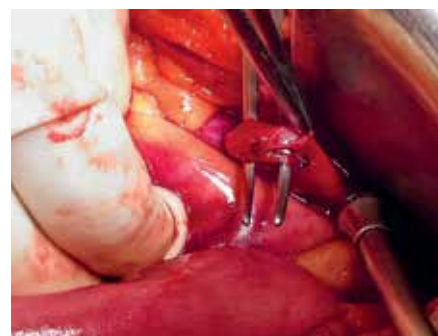
### 33.6.2 Surgical decision-making

The method of repair or diversion for the ureter depends on the haemodynamic stability of the patient since the urgency of the associated injuries usually predominates over the ureteric lesion. Transection and contusion of the ureter necessitate different approaches, as does the level of injury.

Transection of a ureter requires some form of repair or urinary diversion. Successful methods for ureteric repair are based on the level of the injury.

- Proximal third: uretero-ureterostomy (UU) or uretero-pyelostomy.
- Middle third: UU or transverse uretero-ureterostomy (TUU) or anterior bladder wall flap, also known as a cysto-ureteroplasty or Boari flap.
- Distal third: uretero-neocystostomy (UNC).

Minimal ureteric contusions can be treated successfully by ureteric stenting. Major contusions should be treated by resection of the damaged segment and then as for a transection.



**Figure 33.9**

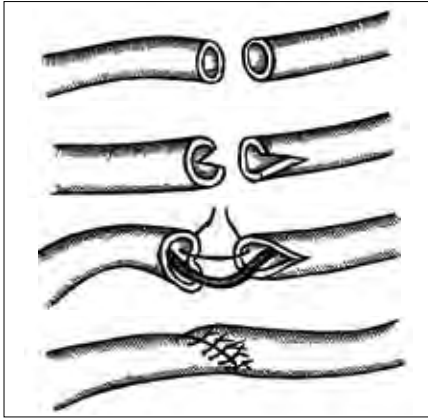
Direct inspection reveals a small laceration of the ureter surrounded by haematoma.

### 33.6.3 Surgical treatment of transected ureter

#### Proximal or middle third: abdominal ureter

Resection-anastomosis of the damaged segment (uretero-ureterostomy) is the preferred option for repair of injuries to the proximal and middle third of the ureter. Partial lacerations of the ureter have been treated with direct suture repair over a ureteric stent. However, the rate of stenosis is high and it is preferable to transform the partial laceration into a full transection through healthy tissue and perform a formal anastomosis.

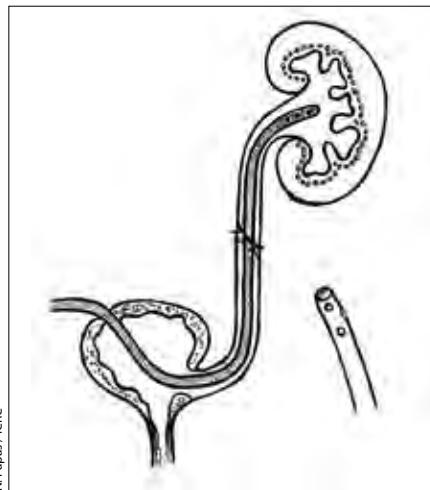
1. Any mobilization of the ureter to relieve tension must be performed by careful dissection and minimal handling to preserve the adventitia and to respect its segmental blood supply.
2. The ends are debrided back to healthy tissue with a bleeding edge.
3. The ends of the ureter are slit longitudinally to create oval openings: spatulation. The slits should be on opposite sides to reduce twists of the ureter when the anastomosis is completed.
4. Internal ureteric drainage is ensured by performing the anastomosis over a stent (JJ-ureteric stent, ureteric catheter, T-tube, paediatric feeding tube, i.v. perfusion line, according to availability).
5. Anastomosis is performed mucosa-to-mucosa with fine interrupted 4/0 absorbable sutures with the knots placed outside the lumen. The anastomotic line must be watertight and tension free.
6. The repair must be covered with an omentum or peritoneal flap to isolate the anastomosis.
7. The retroperitoneal peri-ureteric tissues are drained, with the drain placed close to, but not in contact with, the anastomosis.



N. Papas / ICRC

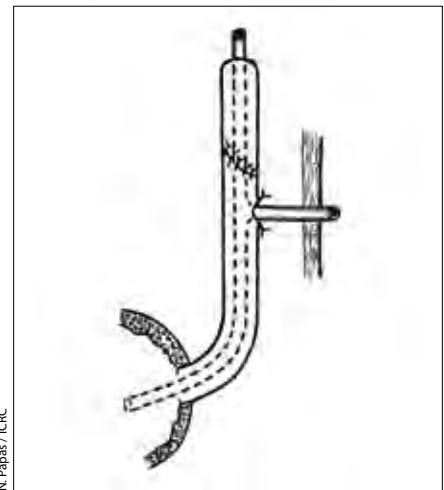
**Figure 33.10**  
Technique for ureteral anastomosis.

The use of internal stenting avoids the need for proximal urinary diversion; a nephrostomy should only be performed if no kind of stent is available. The ureteric stent can be left in the bladder to be removed by transurethral cystoscopy, if available. Otherwise, it is brought out in the suprapubic area by means of a small cystostomy.



N. Papas / ICRC

**Figure 33.11**  
Catheter stenting of ureteric repair. The catheter is passed out through a cystostomy. Dependent external drainage of the site has been instituted.



N. Papas / ICRC

**Figure 33.12**  
T-tube ureteric drainage through a ureterostomy in healthy ureteric tissue.

In cases of extensive damage and tissue loss precluding a direct anastomosis, the available options include:

- liberation of the kidney from Gerota's fascia to mobilize it distally in order to gain several extra centimetres, nephropexy is then performed as for nephroptosis;
- implantation of the damaged ureter into the opposite ureter (TUU);
- transposition of a loop of ileum to serve as a conduit (ileo-ureteroplasty).

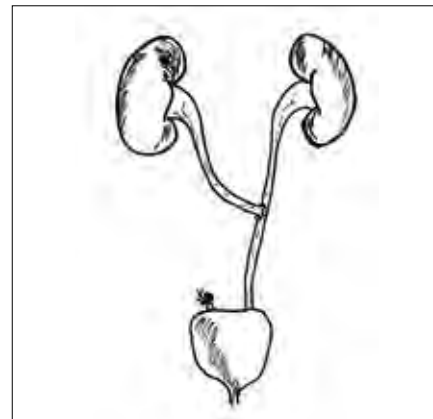
The latter two procedures are time-consuming and often difficult even in experienced hands, especially when there is significant damage to other abdominal organs. In addition, if any complication occurs with the TUU, the previously anatomically normal side has already undergone surgery.

The damage-control approach is to ligate both ends of the ureter with a non-absorbable coloured suture and tie them together, and then perform a defunctioning nephrostomy. Reconstruction is accomplished later when the patient's condition permits. An alternative is to catheterize the sectioned ureter and bring it out as a cutaneous ureterostomy. This formal uretero-cutaneous fistula is not recommended, as it can be time consuming, is prone to ascending infection, and makes definitive repair more difficult.

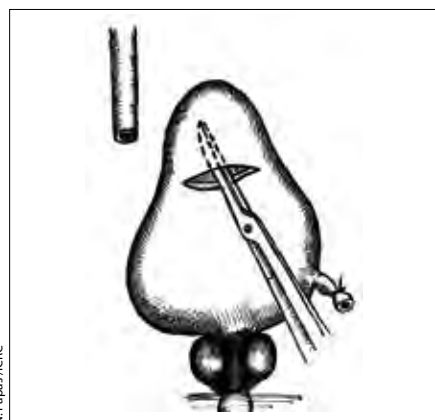### Distal third: pelvic ureter

Uretero-ureterostomy deep in the confined limits of the pelvis is technically challenging. Therefore, a distal lesion is best treated by re-implantation of the ureter into the bladder over a stent: uretero-neocystostomy.

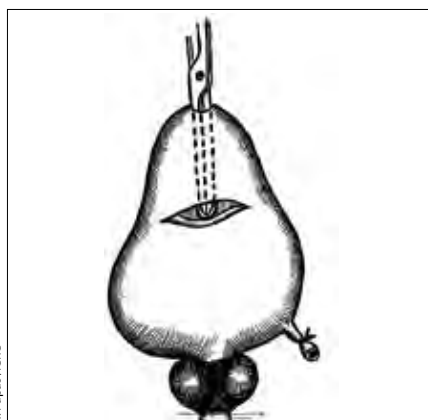
The distal end of the sectioned ureter is ligated and the proximal end is debrided and spatulated. A cystostomy is performed in the anterior wall and, working from inside the bladder, the proximal ureter is then pulled through a submucosal tunnel in the posterior bladder wall *medial* to the original hiatus and sutured in place. This creates the effect of a "non-return" valve and prevents urinary reflux. A stent is brought out through the cystostomy and a prevesical drain placed.



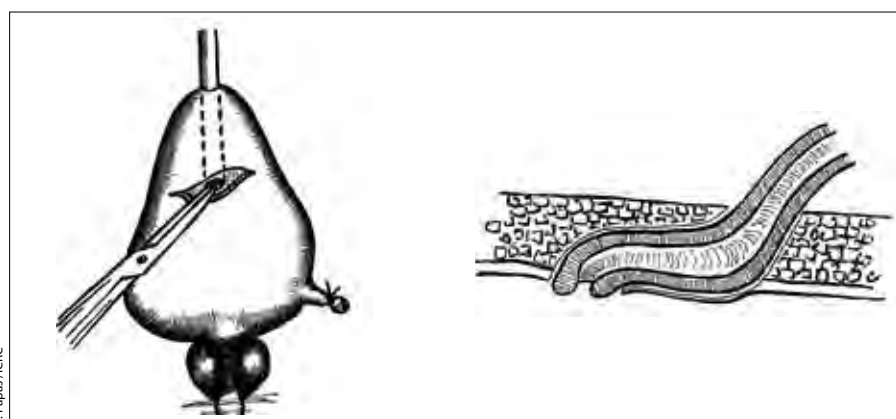
**Figure 33.13**  
Transverse uretero-ureterostomy.



**Figure 33.14.1**  
A horizontal incision is made 4 cm below the highest point of the bladder.

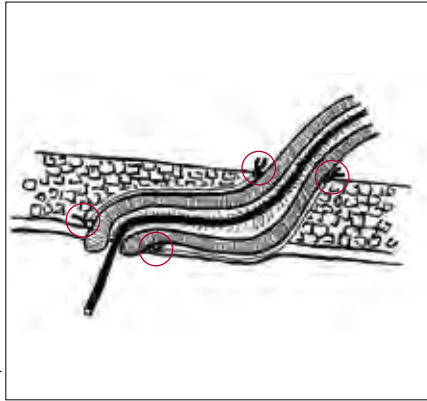


**Figure 33.14.2**  
A tunnel is created in the detrusor muscle and submucosa of the posterior wall.



**Figure 33.14.3**  
The ureter is pulled through the tunnel.

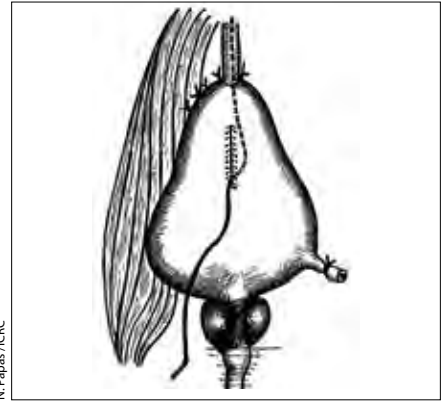
**Figures 33.14.1 – 33.14.5**  
Uretero-neocystostomy: re-implantation of the ureter in the bladder.



N. Papas /ICRC

**Figure 33.14.4**

Working from inside the bladder, the spatulated ureteric end is sutured to the bladder mucosa over a stent with 4/0 interrupted absorbable sutures, with the knots excluded from the mucosal surface. From the outside, the ureter is also sutured to the bladder wall.



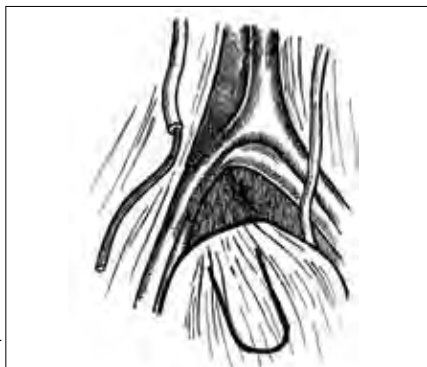N. Papas /ICRC

**Figure 33.14.5**

The cystostomy is closed at right angles to the incision and the ureteric stent externalized through it or through a separate incision. The top of the bladder is stitched to the psoas muscle. Division of the contralateral vesical pedicle may be necessary to mobilize the bladder in order to accomplish the psoas stitch (Figure 33.15.4).

Long defects greater than 2 cm or too far from the bladder for re-implantation usually require a cysto-ureteroplasty: Boari flap. A flap of the anterior bladder wall is fashioned into a circular tube around a catheter-stent. The ureter is re-implanted submucosally into the flap and the bladder closed. Mobilization of the kidney can help shorten the gap by a few centimetres. The Boari flap may be fixed to the psoas muscle to assist in the fashioning of the anastomosis and to maintain the position: psoas hitch (Figure 33.15.4).

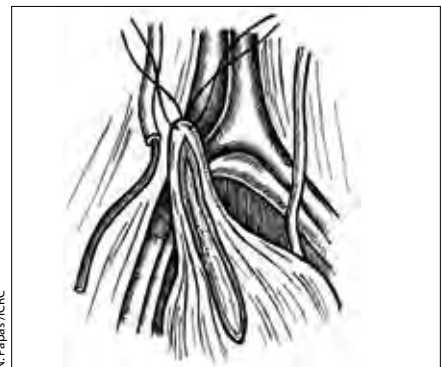
**Figures 33.15.1 – 33.15.4**  
Cysto-ureteroplasty: Boari flap.



N. Papas /ICRC

**Figure 33.15.1**

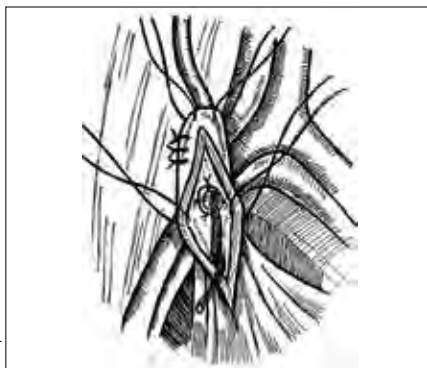The end of the ureter has been debrided and a stent inserted. A long flap is mobilized from the anterior bladder wall with its base on the same side as the injured ureter.



N. Papas /ICRC

**Figure 33.15.2**

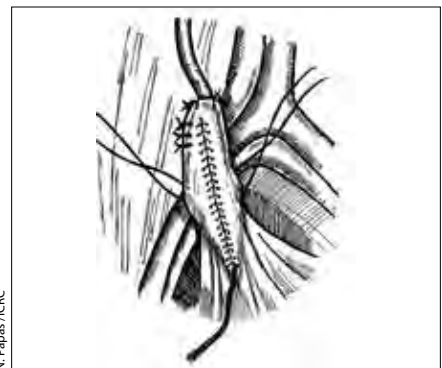The mobilized flap is pulled up to the ureter.



N. Papas /ICRC

**Figure 33.15.3**

The ureter is pulled through a submucosal tunnel and anastomosed to the bladder mucosa over the stent.



N. Papas /ICRC

**Figure 33.15.4**

The incision is closed with a continuous suture and the stent brought out either through it, or through a separate incision to the bladder. The Boari flap has been pulled up above the common iliac vessels and sutured to the psoas muscle: psoas hitch.

If neither of the above options is possible then the injured ureter should be implanted in the contralateral ureter (TUU).

All of these procedures require time. The damage-control approach, similar to the one used for the abdominal ureter, is the ligation of the ends with a non-absorbable coloured suture tied together, followed by a defunctioning nephrostomy. Reconstruction is delayed until the patient's condition permits.

### 33.6.4 Surgical treatment of contused ureter

Several approaches are proposed in the case of contusion of the ureter, depending on the extent and mechanism of injury. Untreated contusions often lead to complications such as delayed necrosis and urinary fistula or ureteric stricture, particularly after high-energy missile wounds.

1. Careful and expectant observation of very mild contusion: the area around the ureter is simply drained, and perhaps wrapped in a sleeve of omentum or peritoneum. The surgeon waits for the slightest urinary leak to operate.
2. Prophylactic splinting of the ureter, which is the preferred method. An appropriate catheter is passed through a cystostomy into the ureter and threaded in a retrograde fashion beyond the contused segment all the way into the pelvis of the kidney. The catheter is brought out in the suprapubic area and removed after 14 – 21 days. The area around the contusion is drained.
3. Severe ureteric contusions should be treated in the same way as a sectioned ureter: adequate debridement to healthy tissue, anastomosis or re-implantation, and drainage.

In all cases, adequate debridement of the surrounding ilio-psoas muscle is necessary. It is the status of the surrounding soft tissues as well as the general condition of the patient that are determinant.

Time spent on resection-anastomosis or splinting is determined by the general condition of the patient and the extent of damage to the nearby soft tissues.

### 33.6.5 Delayed diagnosis and complications

Missed diagnosis of ureteric injury is usually the result of an overlooked transection that presents with a urine leak immediately in the post-operative period. Otherwise, delay in clinical presentation is due to a complication. This may reveal itself relatively early after a leak of a primary anastomosis. On the other hand, a urine leak or ureteric stricture may present after several days or even weeks in the event of devascularization of a ureteric segment, either due to the mechanism of injury or to iatrogenic causes, such as excessive dissection or even crushing of the ureter by the surgeon.

The urinary leak may track into the peritoneum causing peritonitis: open laparotomy is then mandatory. On the other hand, a leak may be confined to the retroperitoneum creating a urinoma, which may become infected.

The safest and easiest procedure to control a urinary fistula is a nephrostomy. The placement of an antegrade ureteric stent brought out through a cystostomy in addition is preferable, if feasible. The urinary diversion and ureteric stent are often sufficient to allow for spontaneous healing of the leak. If not, the nephrostomy should remain until reconstruction of the ureter at a later date.

A retroperitoneal collection of urine can result from undiagnosed injury or inadequate drainage of the renal bed. The urinoma is sometimes diagnosed when a post-operative IVP is performed, but more frequently when it becomes infected. In the absence of imaging technology allowing a percutaneous approach, open surgical drainage should be performed through a lumbar incision.

Ureteric obstruction, usually diagnosed on post-operative IVP, should be dealt with by segmental resection and repair or re-implantation.

## 33.7 Urinary bladder

Wounds of the bladder may be intra- or extraperitoneal and are commonly associated with lesions of other pelvic and intraperitoneal organs.

### 33.7.1 Diagnosis

A high degree of suspicion is warranted when a projectile trajectory involves the pelvis, buttocks or perineum. Like for any wound of the abdomen and pelvis, rectal and vaginal examinations should be performed. In males, special note is taken of the position and integrity of the prostate.

Bladder injury should be suspected, but is not proven, if the passage of a catheter does not produce urine. Other possibilities include a patient who is oliguric or anuric or has a rupture of the posterior urethra and the catheter has not entered the bladder. However, up to 300 ml of urine may be retrieved from a bladder with small perforations, whether they are extra- or intraperitoneal. A thin bladder catheter (CH 14 – 16) is preferred, except when haematuria is likely.

Gross haematuria might be present but, not uncommonly, the injury is discovered only when the balloon of the urinary catheter is seen in the open abdomen at laparotomy. During exploration, close attention should be paid to the possibility of extraperitoneal wounds of the posterior surface and distal ureters. Although not as common as missed injuries of the ureter, extraperitoneal bladder injuries all too often present with a urinary leak post-operatively.

If the patient's condition permits, and if available, a retrograde cystogram or the instillation of a dye is a valuable adjunct. These procedures may also be performed intra-operatively.

### 33.7.2 Surgical treatment

Minor extraperitoneal lesions that are difficult to reach can be treated with an in-dwelling catheter and drainage of the prevesical retropubic space for a period of one week to ten days.

All other bladder wounds should be excised judiciously and sutured in two layers with an absorbable suture: a first running suture with minimal bites of the mucosa and generous bites of the submucosa; a second interrupted layer of the detrusor muscle, which should include the peritoneum in case of intraperitoneal injury. A large part of the bladder can be resected without subsequent problems of urine capacity.

Injuries in close proximity to the bladder neck risk compromising the ureteric outflow and caution must be exercised during these repairs, which should be performed from within the bladder. Sometimes it is difficult to assess the most distal part of the ureter and to identify the ureteric orifices because of bleeding or oedema. In these cases, retrograde ureteric catheterization via the bladder is useful. Injury to a ureteric orifice, or the intramural or very distal ureter, necessitates re-implantation.

After bladder repair, the retropubic space is drained and an in-dwelling urethral catheter left in place for 10 to 14 days. An additional suprapubic cystostomy is necessary only if:

- bladder repair is fragile;
- there is concomitant injury of the urethra;
- long-term catheterization is anticipated owing to other injuries, especially in males.

Concomitant injury to the rectum or vagina requires selective separation of the walls of the different organs and individual repair. An omental pedicle flap should be interposed between suture lines.



In a haemodynamically unstable patient, the damage-control procedure is to simply pack the bladder while urine is evacuated by perivesical drains. A useful adjunct is to catheterize the ureters and externalize the ends. Definitive repair is undertaken during the subsequent operation.

### 33.8 Prostate and posterior urethra

Projectile wounds of the prostate invariably involve the posterior urethra. Surgically, it is therefore best to consider them together, and separate from the anterior urethra and penis. Injury may involve the prostatic urethra at the bladder neck or the membranous urethra at the urogenital diaphragm. Blunt injury to the prostate and urethra is much more common than missile wounds, especially following a fracture of the pelvis.

#### 33.8.1 Diagnosis and ER care

Injury to the prostate and urethra in itself is never life-threatening; associated pelvic or abdominal injuries, however, can be.

Suspicious signs of injury include an inability to pass urine, bleeding at the external meatus, and a nearby projectile trajectory. A rectal examination often shows nothing more than a swelling due to haematoma and oedema. Sometimes a floating prostate can be palpated high in the pelvis: always an indication for immediate surgical intervention. Retrograde urethrocytogram, if available and if the patient's condition permits, is useful.

##### X-ray techniques

##### URETHROGRAM:

- retrograde
- 15 – 20 ml undiluted contrast
- No. 8 catheter
- 1.5 – 2 ml in balloon

##### CYSTOGRAM:

- retrograde
- 300 ml dilute contrast
- anterior, posterior, oblique and drainage views

If any injury is suspected, no attempt should be made to pass a urethral catheter before surgery, as there is a risk that a partial laceration may be made complete.

#### 33.8.2 Surgical treatment

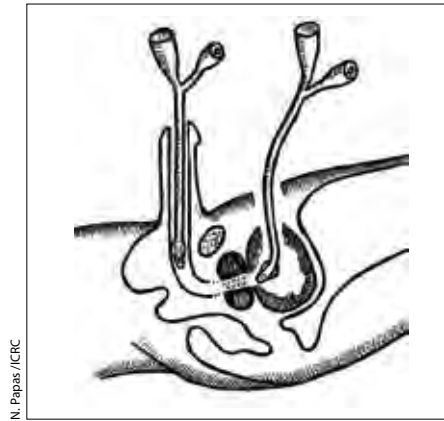
The best approach to the prostate and posterior urethra is *through the bladder*. A missile wound at the bladder neck requires debridement of the prostate and urethra and an in-dwelling catheter.

Injury to the membranous urethra at the urogenital diaphragm typically mimics the shearing injury of blunt trauma following a fracture of the pelvis. The urethra is sectioned and the bladder and prostate float upwards; continuity of the urinary tract is disrupted. Following debridement of the urethra and perivesical tissues, surgical treatment also follows the same lines as for blunt injury. The urine flow must be either diverted or re-established through an intact urinary tract.

The damage-control procedure is to pack the prostatic bed and prevesical space and perform a simple suprapubic cystostomy. In the stable patient, an attempt should be made to re-establish tract continuity – and this can be challenging. The best known method to achieve this is the *chemin-de-fer* (railroading) technique).

**Figures 33.16.1 – 33.16.4**

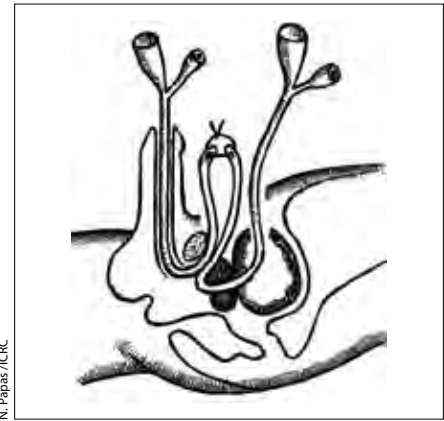
Steps illustrating the “railroading” (*chemin-de-fer*) procedure utilized for repair of a lesion of the posterior urethra.



N. Papas /ICRC

**Figure 33.16.1**

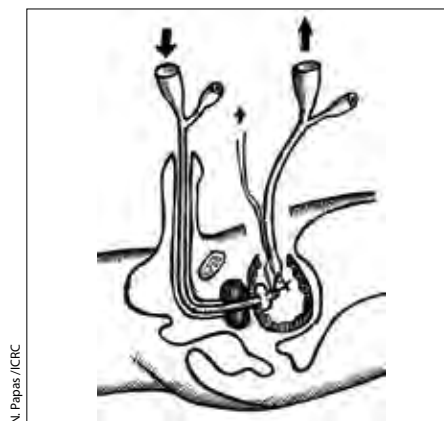
A urinary catheter (CH 16 – 18) is inserted through the penis. A second catheter (CH 20 – 24) is passed through a suprapubic cystostomy into the urethral orifice in the bladder.



N. Papas /ICRC

**Figure 33.16.2**

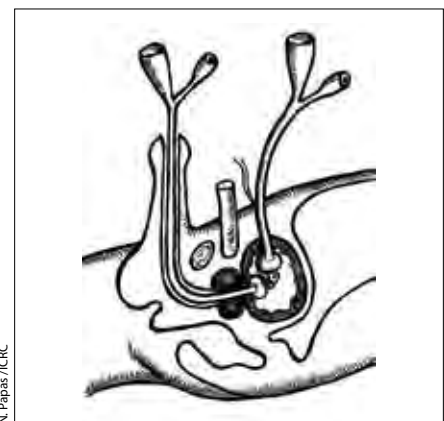
Both catheters are retrieved in the prevesical space and their tips are secured together with a ligature passed through the drainage openings.



N. Papas /ICRC

**Figure 33.16.3**

Traction is exerted on the bladder catheter to guide the penile catheter into the bladder and the balloon is inflated. A stout non-absorbable thread is tied to its tip and brought out through the abdominal wall. If the catheter slips out or gets blocked the thread can be used to guide a new catheter into the bladder past the site of the lesion.



N. Papas /ICRC

**Figure 33.16.4**

The bladder catheter is inflated and brought out as a suprapubic cystostomy. A drain is placed in the prevesical space.

Suture of the sectioned ends of the urethra is not possible; a *sutureless anastomosis* is performed by one or both of two variants.

1. In the first, strong non-absorbable mattress sutures are passed via the perineum through each side of the prostate and traction applied to pull down the prostate and approximate the two ends of the urethra. The sutures are tied over shirt buttons or plastic tubing in the perineum and removed after healing in two to three weeks.
2. In the second technique, direct lateral sutures are placed through the prostatic capsule and down into the para-urethral tissues on each side with No. 1 synthetic absorbable suture.

The prevesical space should be drained as long as there is urine coming through the cystostomy. The suprapubic catheter can usually be clamped after 5 – 7 days and, if there is no leakage of urine, removed the next day. The urethral catheter is removed after three weeks.

The patient should be informed about, and followed up for, sexual dysfunction; the wound may have caused injury to the pelvic nerves. Psychological support may be needed.

### 33.8.3 Sequelae and complications

The most important complications are infection and anastomotic stricture, the latter requiring dilatation and perhaps further reconstructive surgery. Extension of an infection follows any injured fascial planes and can involve the perineum and medial thighs, or up into the abdomen and chest. Infection may result in urethro-cutaneous fistulae or peri-urethral diverticulae and, more rarely but dangerously, necrotizing fasciitis (Fournier's gangrene; see Section 13.3.5).

Repair of both anterior and posterior urethral wounds might require dilatation at six weeks. Follow-up with an urethrogram after three months is obligatory to detect a stricture necessitating regular dilatation. If proper urethroplasty cannot be performed, the patient will require dilatation every three months for life.

## 33.9 Male external genitalia and anterior urethra

Contrary to a widespread myth, male genital injuries are not life-threatening, but can create long-term sexual and psychological damage and altered self-image.

### 33.9.1 Diagnosis

Lesions of the external genitalia are usually obvious. However, adequate physical examination may be difficult because of swelling and/or pain, especially in penile wounds where blood and urine may extravasate along fascial plains into the scrotum, perineum, or up into the pubic area. On the other hand, even a small projectile perforation of the scrotum may overlie complete disorganization of the testes. Primary blast injury with ruptured testes is a recognized entity. Pattern 1 blast mine injuries frequently injure the perineum and genitalia.

Just as for the posterior urethra, no attempt should be made to pass a catheter before surgery if any injury is suspected, as there is a risk that a partial laceration may be made complete.

### 33.9.2 Surgical treatment

Most wounds of the scrotum and penis may be closed primarily after debridement; one of the exceptions to the rule. A dependent drain is indicated because of the likelihood of haematoma collection and should be removed after 24 – 48 hours. However, injuries due to anti-personnel blast mines should always be left open for delayed primary closure, usually 48 hours in this case, no matter how minor.

#### Anterior urethra

Treatment of wounds in the anterior urethra depends on the patient's general condition and on the extent of tissue loss. In a haemodynamically stable patient, immediate treatment can be undertaken. If a damage-control approach is chosen because of associated injuries, delayed primary operation is undertaken later when oedema and inflammation have subsided sufficiently. Deferred treatment usually consists of reconstructive surgery three months later.

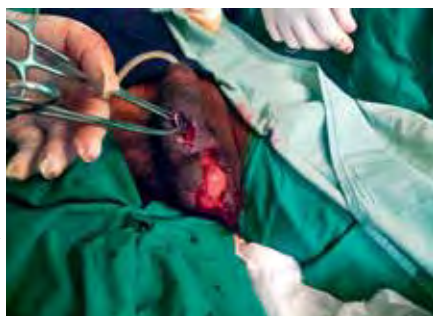

Figure 33.17.1

The patient suffered a GSW to the scrotum and penis. The bullet was a ricochet and fragmented but had already lost most of its kinetic energy.

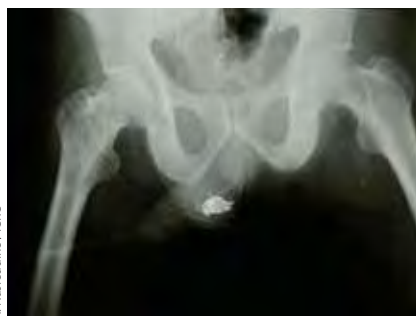

Figure 33.17.2

X-ray showing the presence of the deformed bullet.

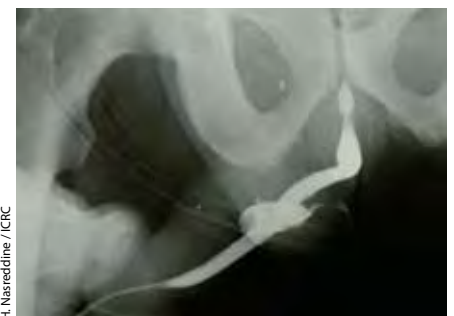


Figure 33.17.3

Urethrogram demonstrating a partial laceration of the anterior penile urethra.

Surgical management depends on the extent of the lesion. A silicone urinary catheter is preferable in all repairs, if available.

1. Partial laceration not larger than 2cm: direct suture at a right angle to the long axis of the urethra to prevent stenosis. The repair should be stented over a catheter (CH 12 – 14) and left in place for three to four weeks. Cystostomy is usually not necessary.
2. Complete division of the urethra with separation of not more than 4 cm following debridement: reconstruction by end-to-end anastomosis following mobilization of the proximal and distal ends.

Passage of catheters from the penis and the bladder as in the *chemin-de-fer* technique helps identify the urethral ends in the midst of a haematoma. The urethra is then debrided back to well-vascularized and healthy tissues that can hold sutures.

Both urethral ends are spatulated and the anastomosis completed with fine interrupted 4/0 absorbable sutures over a catheter. To immobilize the repair site and prevent anastomotic stenosis the mucosa and wall of the urethra are sutured bilaterally to the corpora cavernosa.

The final anastomosis should be splinted by a catheter for 14 days. A suprapubic cystostomy ensures urinary diversion to allow urethral healing. After four weeks, a trial of clamping the suprapubic catheter can be undertaken: if normal voiding is clearly re-established then it can safely be removed. If available, voiding cysto-urethrography is useful for deciding when the suprapubic catheter can be test-clamped.

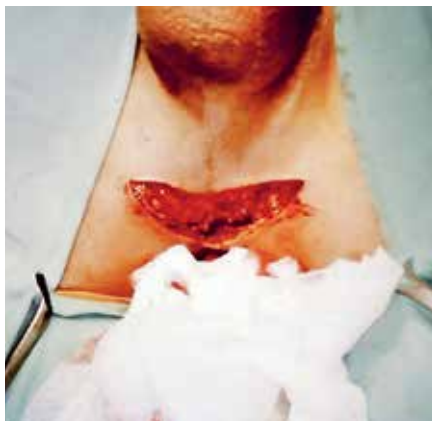3. Complete division with separation greater than 4 cm: primary anastomosis is not possible and a staged repair is necessary.

The wound is debrided and the corpora repaired. A surgical hypospadias is fashioned over an in-dwelling catheter. Urethroplasty is usually performed three months later and protected by a suprapubic cystostomy.

Follow-up urethrogram and dilatation as necessary follows the same protocol as for injuries to the posterior urethra.

Figures 33.18.1 – 33.18.5

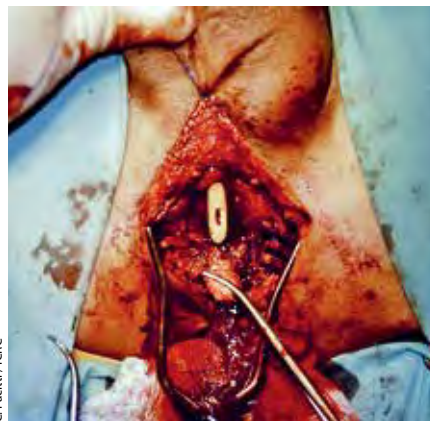Repair of a lesion to the bulb of the penile urethra.



C. Pacitti / IGRC

Figure 33.18.1

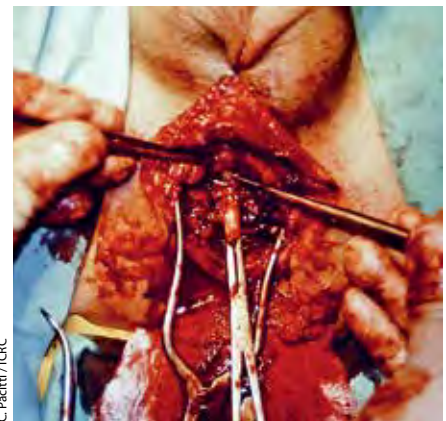
GSW to the bulb of the penile urethra approached through the perineum.



C. Pacitti / IGRC

Figure 33.18.2

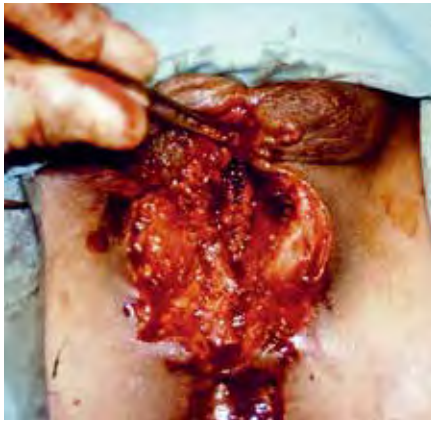Control of the proximal (indicated by the tip of the urinary catheter) and distal segments.



C. Pacitti / IGRC

Figure 33.18.3

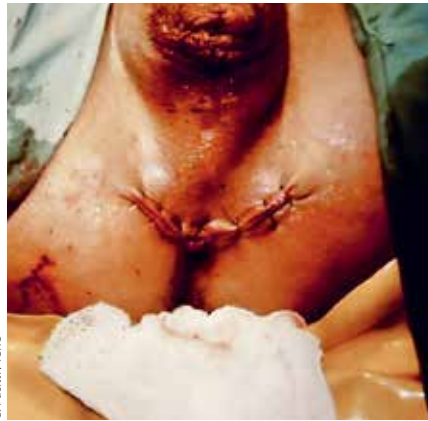The two segments can be approximated without tension.



C. Paoletti / ICRC

**Figure 33.18.4**

The repaired urethra will be covered with a tag from the bulbocavernosus.



C. Paoletti / ICRC

**Figure 33.18.5**

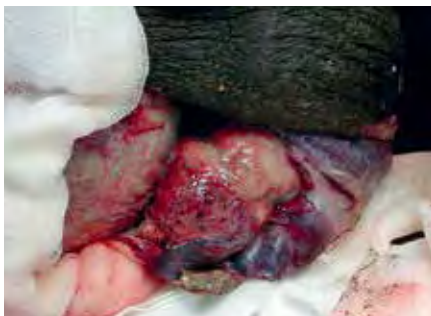Closure of the perineal wound.

### Penis

Concomitant urethral injury usually overshadows wounds in the penis. Debridement of the urethral and penile wound involves exploration and repair of the corpora cavernosa and corpus spongiosum. These structures can be repaired primarily after minimal debridement because of their excellent blood supply. The tunica albuginea of the corpora cavernosa in the flaccid state is 2 mm thick and easily holds sutures (interrupted 3/0 synthetic absorbable). The aim is to re-establish the anatomy as much as possible. The patient should be informed about and followed up for erectile dysfunction. Severe injuries may require staged-reconstruction procedures after conservative debridement, especially for the associated urethral injury. Amputation of the penile shaft is sometimes necessary in cases of massive injury.

### Scrotum and its contents

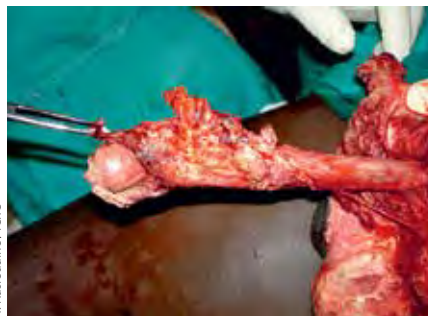Wounds of the scrotum require exploration. A severely disorganized testis requires orchidectomy. Incomplete lesions are debrided conservatively: extruded or necrotic seminiferous tubules are excised and the testis irrigated copiously. The tunica albuginea must always be closed carefully with a running 4/0 absorbable suture to prevent the development of a fistula. Bilateral lesions are common: in up to 33% of the patients with testicular injuries in the experience of ICRC surgeons. For reasons of hormonal physiology, it is important to leave some viable testicular tissue behind; otherwise replacement therapy must be instituted.



H. Nareddine / ICRC

**Figure 33.19.1**

GSW to the scrotum. The patient arrived several days after injury.



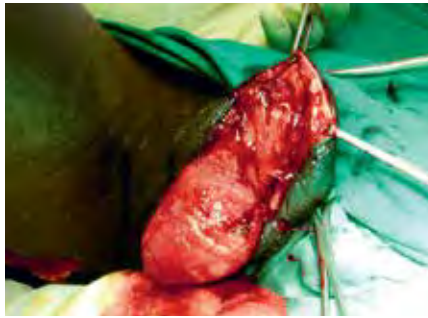H. Nareddine / ICRC

**Figure 33.19.2**

One testicle was totally disorganized and required orchidectomy. The wound was left open owing to the late presentation of the patient.

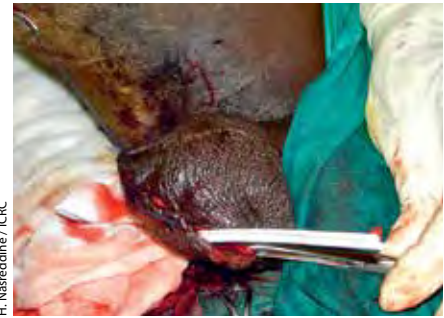**Figures 33.19.1 – 33.19.4**

Destruction of the testis and orchidectomy.



H. Nasreddine / ICRC

**Figure 33.19.3**  
The wound at DPC.



H. Nasreddine / ICRC

**Figure 33.19.4**  
Closure of the skin over a corrugated rubber drain.

Injuries to the epididymis or vas deferens are debrided and the structures ligated; and the consequences accepted. The blood vessels of the spermatic cord are ligated. The condition should be explained to the patient and psychological support offered as necessary.

The scrotal skin wound is then debrided and closed primarily. If viable testes are exposed because of a degloving injury to all the scrotal skin they may be managed with either saline-soaked dressings or an inguinal or femoral pouch of skin for temporary protection until definitive reconstruction. Reconstructive techniques include primary closure after stretching of the scrotal skin, skin grafting, an inguino-femoral rotation flap, or a combination of these methods.

### 33.10 Female genitalia and urethra

Projectile lesions of the female genitalia may involve any of the other pelvic structures. The external genitalia are well vascularized and considerable haemorrhage may ensue after trauma. However, as with the male genitalia, other more serious injuries usually take precedence.

#### 33.10.1 Diagnosis

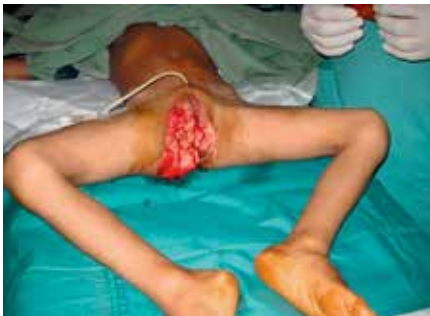Injuries may involve the vulva or vagina. Vaginal lesions may be simple or complex and implicate the urethra, bladder, ano-rectum, or urogenital diaphragm.

Meticulous vaginal examination using a speculum should be performed whenever blood or haematoma is noted in the vagina. This should not be confused with menstruation or overlooked because it is thought to be menstrual in origin. Often, vaginal examination is only possible under general anaesthesia. A rectal examination is also mandatory. An urethrocytogram is a useful adjunct if available.

#### 33.10.2 Surgical treatment

The non-pregnant uterus is a simple but very dense muscle amenable to suturing. A large disruptive laceration may require hysterectomy, subtotal if the cervix is not injured. Minor injuries to the ovaries or fallopian tubes may be sutured; otherwise, oophorectomy or ligature is performed.

Debridement of simple injuries of the vulva and vagina should be conservative and immediate primary closure may be practised in most cases. An attempt should be made to restore the normal anatomy by inserting a vaginal pack wrapped in vaseline gauze. A catheter must be placed even when there is no injury to the urethra since vulvar oedema can easily compromise the outflow of urine.



F. Imazy / ICRC

**Figure 33.20**  
Large GSW wound of the perineum involving the vagina and anus.

Complex injuries of the vagina require closure of the vaginal wall and bladder or rectum in layers, as for repair of vesico- and recto-vaginal fistulas, as well as restoration of the urogenital diaphragm. Injury to the bladder necessitates a suprapubic cystostomy and prevesical drainage; ano-rectal injury requires a faecal diversion. Again, a urethral catheter and vaginal pack are placed.

The female urethra is much shorter than that of the male and less amenable to mobilization. In addition it is closely adherent to the vagina and injury invariably involves the vaginal wall. Raising vaginal flaps may help mobilize the urethra sufficiently to carry out a direct anastomosis. Catheterization of the urethra helps diagnose the injury; a *chemin-de-fer* technique may have to be used and the first catheter passed retrograde via the bladder. Even where repair of the urethra is not possible, stenting over a catheter assists in its realignment. A suprapubic cystostomy should always be employed.

### 33.11 Post-operative care

Analgesia and antibiotics are given according to protocol. Usually the associated abdominal or pelvic injuries determine the rest of post-operative care.

The protocol for the management of an in-dwelling urinary catheter – whether urethral or vesical – after repair of some part of the urinary tract is similar to that for spinal cord injury patients (see Section 36.9.1). A urine flow of at least 1,000 ml per 24 hours is required to prevent catheter encrustation and infection. Cleaning around the catheter at the meatus with an antiseptic should be performed twice daily.





## **Chapter 34**

# **AUTOTRANSFUSION**

34.	AUTOTRANSFUSION	
34.1	Rationale of autotransfusion	511
34.2	Methodology of autotransfusion	512
34.3	Pathophysiological changes	513
34.4	Indications	514
34.5	Practical autotransfusion methods	515
34.5.1	Thorax	515
34.5.2	Abdomen and limbs	517
34.5.3	Enteric contamination	518
34.5.4	Filters	519
34.5.5	Use of anticoagulants	519
34.6	Complications and risks	519

## Basic principles

In circumstances where blood for transfusion is scarce, autotransfusion can be lifesaving.

Even when blood is in ready supply, autotransfusion for massive haemorrhage can be lifesaving.

Autotransfusion should be considered early in patients with major bleeding, especially from the thorax and abdomen.

Theatre nursing staff should be trained to handle the equipment.

Check that the necessary equipment is available in the OT.

### 34.1 Rationale of autotransfusion

The idea of replacing lost blood has been present in medical thinking for centuries. In the pre-modern era, attempts were made to transfuse blood from animals to humans and from humans to humans, usually with disastrous results. Autotransfusion itself is an old idea, invented and used successfully for the first time in 1818 by James Blundell.<sup>1</sup>

“All too often one sees several pints of blood thrown away from the body cavity of patients who are bleeding to death. It is our belief that this autogenous blood represents the most readily available, abundant, rapid and safe replacement therapy for these urgent cases.”

R.A. Griswold & A.B. Ortner<sup>2</sup>

However, since Landsteiner’s classification of blood groups at the beginning of the 20th century and with more modern techniques of blood collection and banking, donated blood has become a standard in medical care. As a result, the use of autotransfusion became sporadic; ordering blood from the blood bank was far easier than collecting it in the operating room and re-infusing it.

Nonetheless, intra-operative autotransfusion for massively haemorrhaging patients in an acute scenario has been “rediscovered” on numerous occasions by many surgeons working with limited resources, and especially during armed conflict. Even in modern up-to-date hospitals with better availability of blood and components, many surgeons still see advantages in autotransfusion. The blood is readily available, warm, poses no risk of the usual blood-transmissible diseases, and is physiologically closer to circulating blood than banked blood and its components.

“It is axiomatic that the only perfectly matched blood for use as a transfusion is the patient’s own.”

H.T. Langston, G. Milles & W. Delassandro<sup>3</sup>

The more widespread modern use of autotransfusion had to await the development of cardiac surgery and the advent of highly sophisticated equipment: cell-salvage technology. Much has been written recently about cell salvage and Cell Saver<sup>®</sup> techniques, whether for elective or emergency surgery. These depend on sophisticated technology and well-trained technicians to collect, centrifuge, rinse and filter shed blood, thus producing *processed blood*.

- 1 James Blundell (1791 – 1878), British obstetrician who recuperated blood from the vagina of patients suffering from postpartum haemorrhage and injected it by syringe.
- 2 Griswold RA, Ortner AB. The use of autotransfusion in surgery of the serous cavities. *Surg Gynecol Obstet* 1943; **77**: 167 – 177.
- 3 Langston HT, Milles G, Dalessandro W. Further experiences with autogenous blood transfusions. *Ann Surg* 1963; **158**: 333 – 336.

V. Sashin / ICRC



Figure 34.1

Autotransfusion has been “rediscovered” on many occasions by surgeons working in resource-poor settings: Dr Ahmed Mohamed Ahmed “Tajir”, head surgeon, Keysaney Hospital, Somali Red Crescent Society, Mogadishu.

For surgeons involved in the care of people wounded in armed conflict with its constraints and precarious circumstances, simple procedures for autotransfusion can help save lives. Many simple methods of recuperating and using *unprocessed* shed blood when dealing with trauma and obstetric patients have been described by various authors and used by ICRC surgical teams.

As frequently mentioned in this manual, working with limited resources often means a limited supply of blood for transfusion, or even none at all. When faced with a patient who has suffered a severe but survivable injury dying for want of blood for transfusion, the idea of autotransfusion forcibly springs to mind. Like all medical interventions, it has its advantages and disadvantages and potential complications, and these must be taken into consideration.

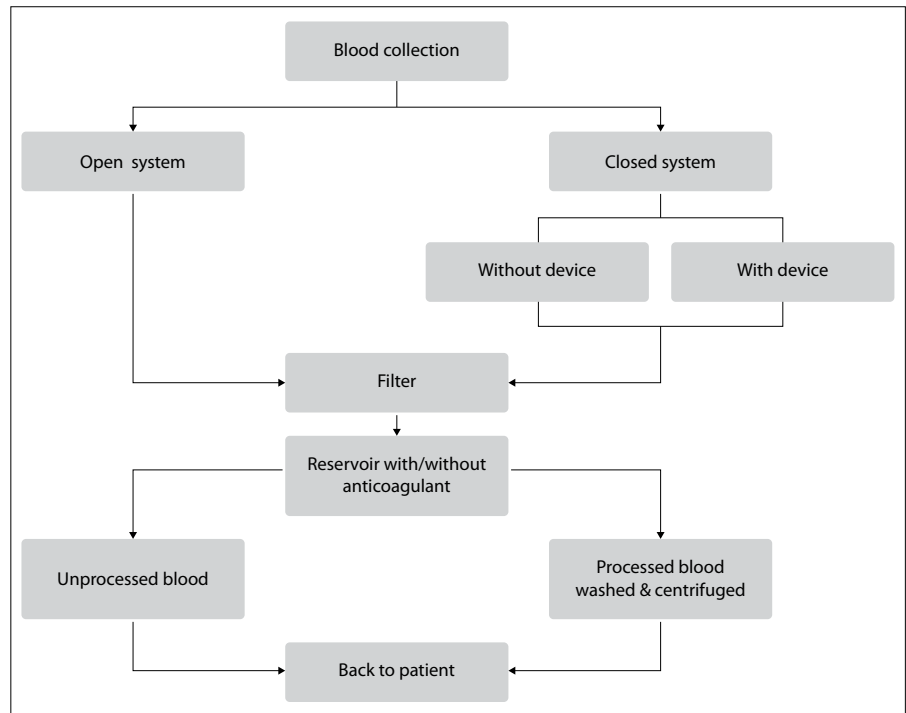
The “rediscovery” of autotransfusion is due to the occasional desperate need for blood.

### 34.2 Methodology of autotransfusion

Various methods and devices have been described for performing autotransfusion, from very simple and improvised to highly-sophisticated commercial ones. They all have certain points in common, nonetheless, and the process is a standard one. Figure 34.2 describes the generic methodology.

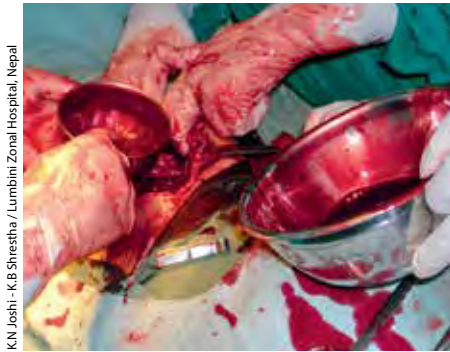
Figure 34.2

Process and methodology for autotransfusion.



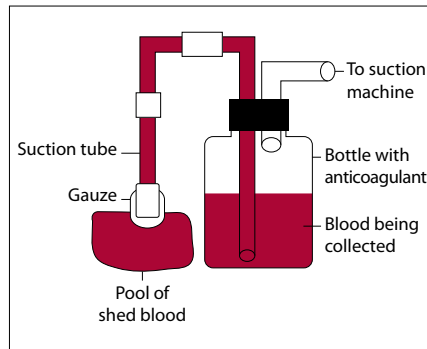
All systems describe some method for collecting the shed blood and putting it into some sort of reservoir from where it is then re-infused into the patient; filtration occurs at one or more stages in the process.

An open system exposes collected blood to the air. A closed system recuperates the blood either with a special collecting device, such as a suction apparatus, or without one, for instance with a chest tube by means of the normal evacuation of a haemothorax. Both systems then put the blood into some sort of reservoir with or without filtering it in some way.



**Figure 34.3.1**

Open system for blood collection using a gallipot.



**Figure 34.3.2**

Closed suction method of blood collection. Gauze compress is wrapped around the suction nozzle as a first filtration.

Unprocessed blood is crude shed blood. Processed blood is aspirated by the suction machine into a special apparatus that adds an anticoagulant, then filters, washes and centrifuges the blood, creating a concentrate of red blood cells with a haematocrit of 50% to 70%. Almost all plasma proteins, including clotting factors and platelets are removed in the washing process, and so are the free haemoglobin and cell debris, as well as the anticoagulant. The processing takes up to ten minutes. These mechanical systems unquestionably require expert personnel to ensure their proper functioning and maintenance.

From the reservoir, the blood – processed or unprocessed – is then given back to the patient after having gone through another filter or a series of filters.

**Unprocessed blood:** shed blood is collected, filtered, and returned directly to the patient.

**Processed blood:** a cell-washing stage is included that eliminates all serum proteins and platelets and returns only the concentrated RBC mass to the patient.

### 34.3 Pathophysiological changes

Shed blood differs in composition from circulating intravascular blood. The act of collection also alters its composition.

The vast majority of studies of the pathophysiological changes in autotransfused blood concern processed blood. It is not always possible to determine which changes are due to the autotransfusion itself and which to the process of washing and suspension. Some may be common to all forms of autotransfusion; others may depend on which technique is used.

It is certain that once some clotting has occurred, recuperated fluid blood has a decreased haematocrit owing to the trapping of red blood cells in the clots and increased haemolysis with a consequent raised level of free haemoglobin. Although such blood is “anaemic”, it is highly oxygenated with a near normal pH and retains near normal labile clotting factors and 2, 3-diphosphoglycerate (2, 3-DPG), as well as RBC survival when compared to banked blood.

The activation of the coagulation cascade uses up some platelets, fibrinogen, and other clotting factors. Contact with damaged tissue and serosal surfaces and, in the case of the thorax, the mechanical action of the lungs and heart, also bring about certain changes in the shed blood. The global results are prolonged prothrombin time (PT) and partial thromboplastin time (PTT), decreased fibrinogen, and increased fibrin split products in the autotransfused blood. These values return to normal within 24 to 72 hours.

Blood collected from the thorax usually does not clot because it is defibrinogenated and therefore the platelet count is near normal. However, if the haemorrhage is from the great vessels, there may be insufficient time for defibrination. In the peritoneal cavity, shed blood includes microaggregates of platelets, RBCs and particulate debris, which are known to provoke coagulopathy. In the case of rupture of an ectopic pregnancy, the trophoblastic products are known to favour disseminated intravascular coagulation (DIC). In blood recuperated from the limbs following fractures, the microaggregates include fat globules that may cause fat embolism.

Clinically, however, autotransfusion has proven safe and effective. It causes only transient haematological abnormalities that disappear within 72 hours post-operatively. Furthermore, autotransfusion is not associated with increased mortality, or haematological, cardiopulmonary, and renal complications above what is considered normal in these severely injured patients.

### 34.4 Indications

Autotransfusion must be placed in the context of a correct surgical approach to the haemorrhaging patient, which includes early control of bleeding and meticulous haemostasis. The *first and foremost indication* is the need for an emergency source of blood in acute and massive haemorrhage that is clinically diagnosed pre-operatively. This usually concerns a body cavity, either the thorax or the abdomen. A haematocrit value of less than 35% on admission and expected crystalloid requirements of more than 2,000 ml should alert the surgeon and anaesthetist to the need to prepare for possible autotransfusion. The most common use has been for ectopic pregnancy and massive haemothorax. The second indication is when substantial blood loss occurs once the operation commences, usually a laparotomy.

Rapid blood loss of up to 1,000 ml (20% of estimated blood volume) can be compensated by i.v. crystalloids and the body's homeostatic mechanisms. Above this amount, compensatory mechanisms gradually start to fail. Given that autotransfusion has potential complications, the availability of donor blood is a major factor in determining the threshold at which autotransfusion should be resorted to, especially in the case of rare blood types.

Consider autotransfusion for *rapid* blood loss over 20% of blood volume (i.e. 1,000 ml).

The situation presents differently in a patient who has suffered a *delay* in evacuation and whose total blood loss is 1,000 ml or more but who arrives in a relatively stable condition. The body has effectively compensated to a lesser or greater extent. The clinical picture in these patients is often complicated, however, by sequestration oedema subsequent to tissue trauma, and simple dehydration; any state of shock is hypovolaemic, but not entirely haemorrhagic. The initial treatment requires basic resuscitation with i.v. crystalloids prior to surgery, as discussed in Section 8.5.4 on hypotensive resuscitation. The threshold for and appropriateness of autotransfusion in such patients is not as obvious.

This also poses the question of the "safe" period for recuperation of blood shed into a body cavity. Reports differ, citing from several hours up to three days in war-related haemothorax.<sup>4</sup>

The degree of urgency and lack of any other source of blood would appear to define the deadline for autotransfusion more than anything else. Common sense demands that a patient dying on table with no other blood available should benefit from autotransfusion no matter how old the injury.

4 Roostar L. *Gunshot Chest Injuries*. Tartu, Estonia: Tartu University Press; 1996: p 34.

A shocked patient, but not actually *in extremis* and whose condition can be kept under control by i.v. crystalloids, plasma and plasma expanders, and what little blood may be available, demands good clinical judgment on the part of the surgeon and anaesthetist as to whether autotransfusion should be resorted to or not. In this latter instance, absolute contraindications include a very offensive smell and blood that is obviously haemolysed.

Practice in the ICRC has usually set the limit at six hours. However, there are so many different factors involved and each situation with each patient so particular that any more precise statement is not possible and ICRC surgeons cannot make a specific recommendation. A six-hour limit, nonetheless, covers most patients with acute haemorrhage who reach hospital alive yet may still require autotransfusion for resuscitation.

The third indication for autotransfusion is in the post-operative setting. Continuing blood loss can be recuperated from thoracic and mediastinal drains, as is done in acute cases, and re-infused, although this is rarely practised where resources are limited because it requires an impractical amount of monitoring and nursing care.

### 34.5 Practical autotransfusion methods

The best apparatus for conditions of limited resources should be simple, safe and inexpensive, not require a power supply, and demand minimal human resources. This manual will therefore only describe the elementary methods that do not require cell-salvage technology. The efficiency of autotransfusion greatly depends on the ability to recover blood quickly in a useable form. The necessary materials must therefore be prepared beforehand and be ready for use.

#### 34.5.1 Thorax

The most obvious and most common example of an autotransfusion system is an intercostal chest tube connected to some sort of collecting device.

In extreme cases of massive haemothorax (more than 2,000 ml) no time should be lost. The simplest method is the chest-bottle inversion technique. A sterile chest bottle containing 100 ml of normal saline collects the blood and is then disconnected and inverted to become the administration set. It is replaced by another chest bottle to collect more blood. *In extremis* ICRC surgical teams have used urine collection bags without saline to gather blood from a haemothorax; attention must be paid to any one-way valve. Both methods then filter the blood through a standard transfusion set.

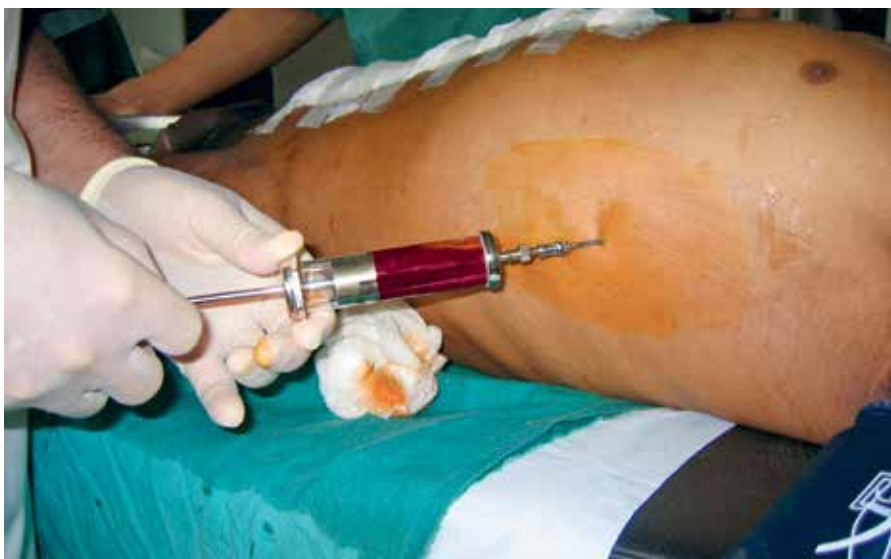

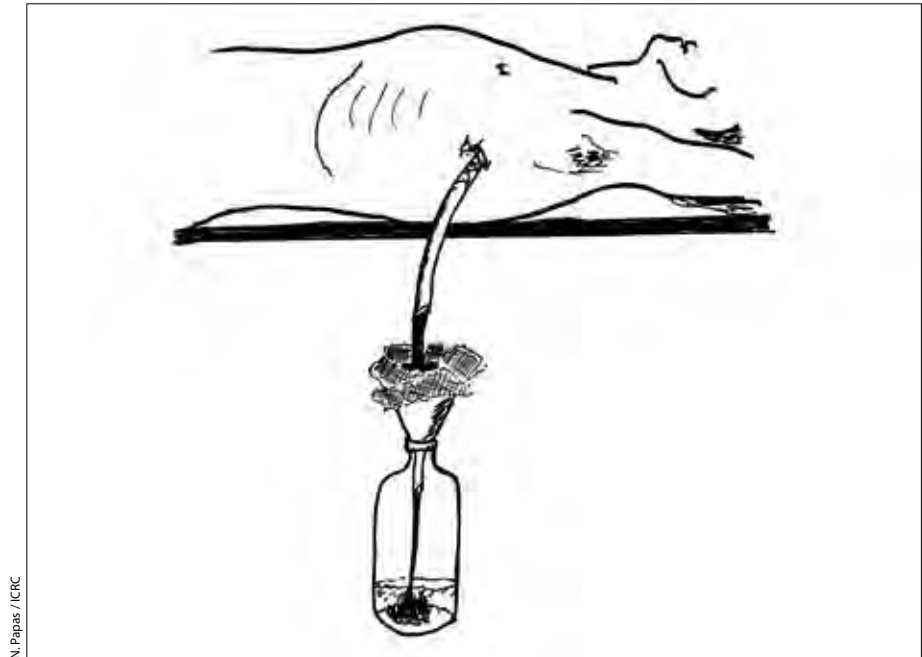
Figure 34.4

Collection of blood through a chest tube using a syringe.

With less urgency and under conditions more amenable to preparation, a double filtration system is preferable. The blood is first filtered through 6 – 8 layers of sterile gauze lining a sterilized metal funnel and collected directly from the chest drain into a sterile plastic or glass bottle. After the bottle is filled, the rubber stopper is inserted and the blood re-infused immediately.

**Figure 34.5**

Collection and filtration of blood from pleural cavity into a sterile glass bottle for immediate autotransfusion.

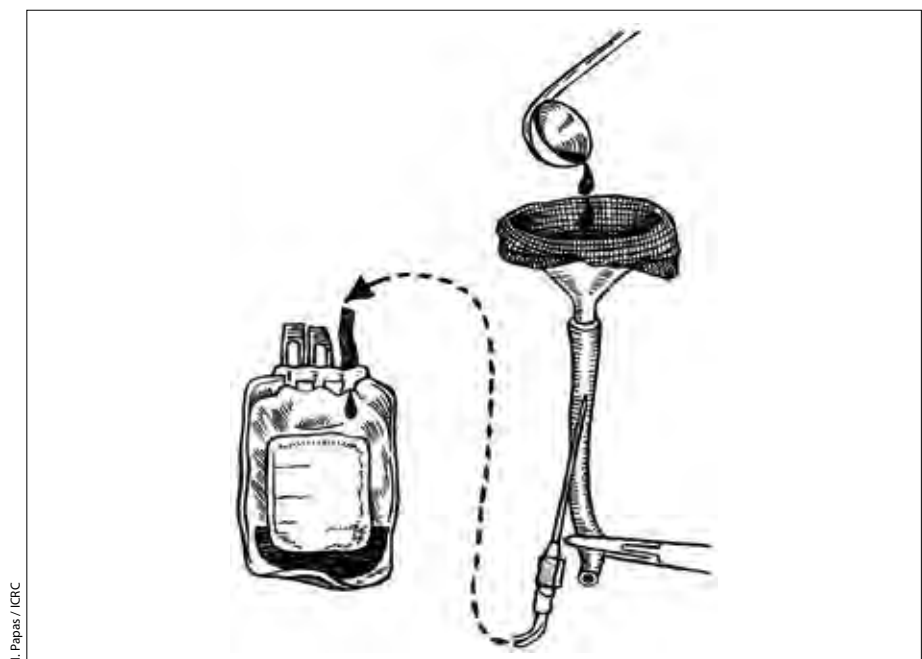

Please note:

Re-autoclavable glass jars (500 ml) are still widely used in rural and missionary hospitals that prepare their own intravenous fluids. They include a rubber stopper/membrane and an aluminium screw-cap top. Re-sterilizable plastic bottles are now available. Sterilized bottles should be packed individually and stored in the emergency department and operating theatre.

**Figure 34.6**

Filtration of blood and collection in a transfusion blood bag: an alternative system in the absence of appropriate bottles.<sup>5</sup>



In all such systems, a large enough calibre in all the tubing for rapid evacuation and administration of the recuperated blood is necessary. The use of a standard blood administration set with its incorporated screen filter is usual practice; however, a new drip set should be used with each unit of blood.

5 Contributed by S. Whitehead, Maua Hospital, Kenya, adapted from M. King, Primary Surgery.

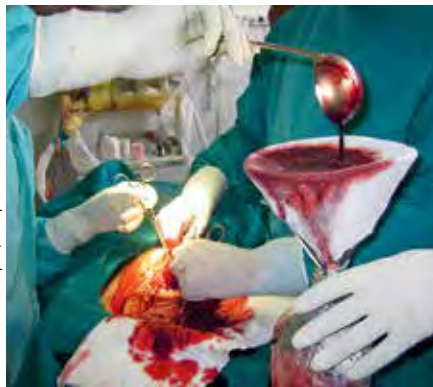

### 34.5.2 Abdomen and limbs

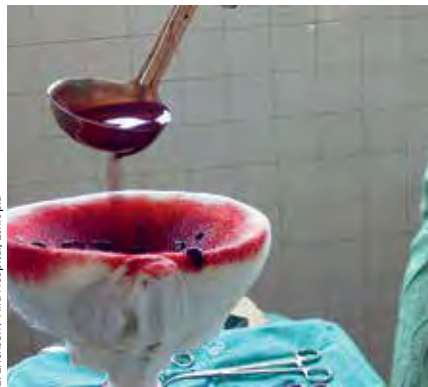Contrary to the chest where *one* filtration of collected blood is sufficient in extreme situations because most of the blood is fluid and micro-particulate matter is at a minimum, shed blood from the abdomen or limbs must be filtered *twice*.

The open method of scooping up blood into a basin or kidney dish with a soup ladle is simple, can easily be improvised, and causes little haemolysis. However, it is inefficient, time-consuming and awkward. When faced with an abdomen full of blood and ongoing active bleeding, the natural and correct reaction is to clear the field as quickly as possible to stop the haemorrhage. Recuperating the blood takes second place to haemorrhage control and ladling blood into a basin distracts the surgeon from the process of operative haemostasis. This method should only be used once haemostasis has been achieved – frequently the case with an ectopic pregnancy, ruptured spleen or packed liver. An assistant takes the basin and pours the blood through a gauze compress filter into a reservoir for re-infusion.

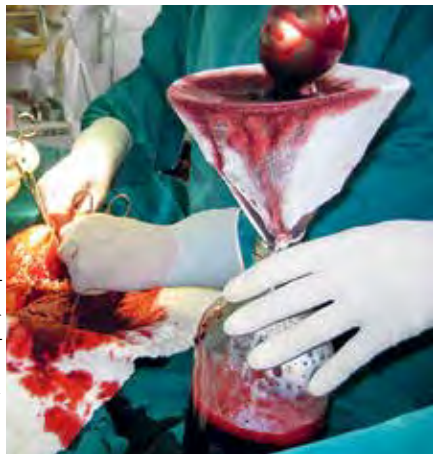Haemostasis takes precedence over collecting blood for autotransfusion.



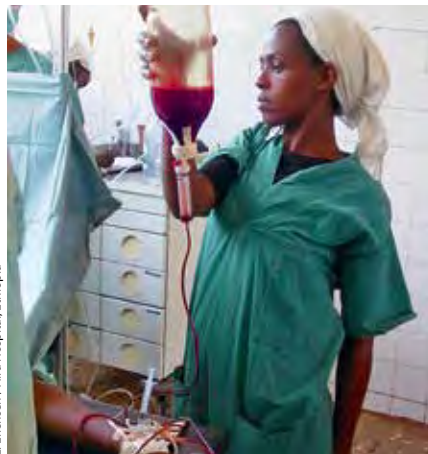E. Erichsen / Alra Hospital, Ethiopia



E. Erichsen / Alra Hospital, Ethiopia



E. Erichsen / Alra Hospital, Ethiopia

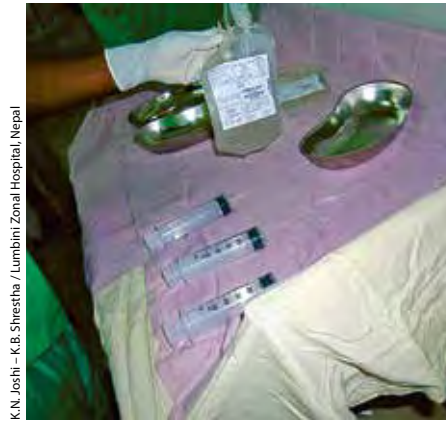

E. Erichsen / Alra Hospital, Ethiopia

Figures 34.7.1 – 34.7.4

Collection by sterile soup ladle and filtration into a glass bottle through several layers of gauze compress.

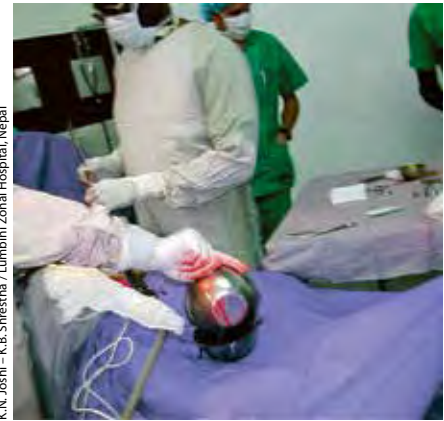Instead of ladling the blood, ordinary laparotomy suction may be used, but should be handled by an operating assistant while the surgeon proceeds with haemostasis. Low pressure must be employed because haemolysis is in direct proportion to the strength of the suction. The tip of the sucker must be kept immersed in the pool of blood to avoid a blood-air interface that causes frothing and haemolysis. Similarly, the sterile collection bottle containing an anticoagulant should hold a sufficient amount of normal saline to cover the air outlet tube, again to avoid frothing. The recuperated blood is then immediately filtered as before. One modification is to use “sump aspiration” as for drainage of the injured pancreas (Figures 32.35.1 and 32.35.2). The sump drain is placed deep in the collection of blood, usually in the Douglas pouch or subsplenic space. The outer sump tube may be lined with gauze compresses to provide a first filtration.



K.N. Joshi – K.B. Shrestha / Lumbini Zonal Hospital, Nepal

**Figure 34.8.1**

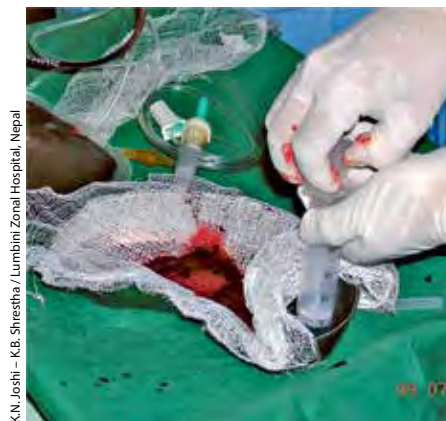The necessary kit for an alternative method of blood filtration and collection.



K.N. Joshi – K.B. Shrestha / Lumbini Zonal Hospital, Nepal

**Figure 34.8.2**

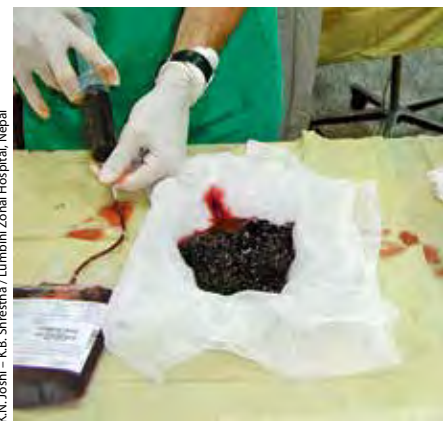Collection of blood using a gallipot.



K.N. Joshi – K.B. Shrestha / Lumbini Zonal Hospital, Nepal

**Figure 34.8.3**

Filtration of blood through layers of gauze compress and its recuperation by means of a large syringe.



K.N. Joshi – K.B. Shrestha / Lumbini Zonal Hospital, Nepal

**Figure 34.8.4**

Filtered blood being packed into ordinary transfusion bags.

For the limbs, the basin or kidney dish is held in such a way as to recuperate as much blood as possible. The blood is then poured through a sterile metal funnel lined with 6 – 8 layers of sterile gauze into a glass bottle.

### 34.5.3 Enteric contamination

These methods of blood recuperation from the abdomen are simple enough when only parenchymatous organs are injured; the amount of bile in shed blood has proven to be of little consequence. The question of the suitability of autotransfusion arises in cases of contamination with enteric contents: gastric juice, chyme or faeces. The gross particulate matter of undigested food and faeces must obviously be removed, but also micro-particulates since it is apparently they that are even more likely to cause complications than the bacterial content. Without a cell-salvage apparatus, this entails careful filtering of the collected blood, twice over, before transferring to the reservoir.

The possibility of infectious complications has given rise to controversy. Experience has shown that autotransfusion of even enteric-contaminated blood is possible and that infection has not been a problem, especially if the patient is covered with wide-spectrum antibiotics. A number of references are to be found in the Selected bibliography.

Nonetheless, and in short, the autotransfusion of enteric-contaminated blood in the absence of cell-salvage technology should be considered an *extreme* technique to be used in *extreme* circumstances. The patient dying on table owing to inadequate blood supplies obviously puts the risk of infection or other complications into another perspective. The transfusion of grossly contaminated but filtered blood in a dying patient *may* be of greater benefit than giving no blood at all. ICRC surgeons have no experience in this domain and recommend great caution.

### 34.5.4 Filters

The simplest method is to use several layers of sterile surgical compresses followed by the in-line 150 – 200 µm filter that is incorporated in a standard blood transfusion set. It has proved to be sufficient in most settings. The use of a special 20 or 40 micron filter has not proved necessary and it probably removes any remaining platelets.

### 34.5.5 Use of anticoagulants

The different manufactured devices that process blood obligatorily use various anticoagulants, which are then removed during the washing process. The need for anticoagulants when using non-processed blood has given rise to controversy. This is largely due to the anecdotal evidence concerning their use, which contrasts considerably with the controlled studies of cell-salvage technology.

It is generally conceded that for blood recuperated from a haemothorax anticoagulation is probably not required, while for shed blood from large vessels anticoagulation is theoretically warranted, although clinically this has not always proved to be the case.

#### ICRC EXPERIENCE

In the case of haemothorax, ICRC surgical teams and others have used CPD-A (citrate phosphate dextrose adenine) either in a standard or half-normal dose, heparin (1,000 to 5,000 IU per bottle), or even no anticoagulant whatsoever. No clinical difference has been observed. The circumstances of autotransfusion when working with limited resources are such that performing a controlled clinical trial would be difficult.

Practical recommendations for those working where resources are scarce should include the following.

- For haemothorax: preferably no anticoagulant, or heparin in a dose of 500 – 1,000 U per unit blood, or half-dose CPD-A.
- For haemoperitoneum: either heparin in a dose of 500 – 1,000 U per unit blood or half-dose CPD-A.

On the purely theoretical grounds that autotransfusion of blood with activated coagulation cascade may lead to DIC, it is probably best to use heparin as the anticoagulant.

## 34.6 Complications and risks

As in all surgical procedures there are possible complications when using autotransfusion. Many are related to the quantity of blood re-infused and are more prevalent with processed blood; they also exist with the transfusion of large quantities of banked blood.

### Febrile reaction

About half the patients undergoing autotransfusion suffer a transient febrile reaction in the first days post-operatively. Apart from the normal reaction seen in trauma patients with absorption of haemolysed blood from their wounds, there may be an activation of the complement system and induction of an inflammatory state. This is self-limiting and, clinically, has proved to be of no consequence.

### Coagulopathy

Theoretically, a combination of consumptive coagulopathy, fibrinolysis, and platelet dysfunction is the greatest danger when resorting to autotransfusion. In addition, the re-infusion of the activated by-products of the coagulation cascade along with micro-particulate matter may trigger the development of disseminated intravascular coagulation, just as with the re-infusion of trophoblastic by-products.

However, as discussed in Chapter 18, there are many factors involved in severely injured patients that may result in coagulopathy: shock, hypothermia and acidosis, multiple transfusions of banked blood, excessive i.v. crystalloids, etc. It is difficult, if not impossible, to determine to what extent any coagulopathy is due to these other factors rather than to the autotransfused blood itself. There is little danger of coagulopathy when three litres or less of unprocessed blood are given.

### Sepsis

War wounds, as is known, are contaminated and dirty and therefore the administration of antibiotics should be routine practice. The wound cannot be sterilized by the surgeon, nor can the blood, but the body has its own defence mechanisms. Studies have shown that processed cell-salvaged blood is not sterile even in the absence of enteric contamination, and yet this has not resulted in an increase in infectious complications. Clinically, infection after autotransfusion of unprocessed blood has not been a problem. However contamination of the *collecting* system from handling must not be forgotten as a possible cause of infection.

### Renal failure

Increased haemolysis liberates large quantities of free haemoglobin with haemoglobinuria. This is especially a risk with the autotransfusion of blood more than six hours old and grossly haemolysed blood. However, there is no proof of clinically relevant complications and the haemoglobinuria usually clears within a few hours.

Blood collected from the abdomen *may* be contaminated with activated pancreatic enzymes in the case of combined injury to the pancreas and intestine or a duodenal wound. Re-infused, such blood causes haemolysis and haemoglobinuria. However, in the rare reported cases, there was only a transient deterioration of renal function.

Patients should, nonetheless, be closely monitored and any sign of a decrease in urine output – in a haemodynamically stabilized patient – should be treated with alkalinization and mannitol and hydration maintained with i.v. crystalloids.

### Pulmonary hypertension and ARDS

Theoretically, the possibility of microemboli of platelet aggregates and particulate debris is greatest with blood recuperated from the abdomen and the limbs. In the latter, fractures may also liberate fat globules. However, microaggregates also exist in banked blood – the older the blood, the more there are – and there is no supporting evidence for the occurrence of fat embolism syndrome from the process of autotransfusion.

### Multiple organ failure

With greater knowledge of the mediators and intermediary products of the inflammatory cascade has come greater awareness of the possible complications that lead to multiple organ failure. These considerations are highly theoretical apart from specific subsets of patients who suffer not only severe trauma but are treated with massive transfusion protocols of blood components and large quantities of i.v. crystalloids. In the setting of the patient suffering massive haemorrhage with little or no blood available for homologous transfusion, autotransfusion has proved to bring far greater benefits than risks of multiple organ failure.

### ICRC EXPERIENCE

There are few occasions more frustrating for a surgeon working with limited resources than to have a patient die on table for lack of blood for transfusion, while the operating linen and floor are drenched in the patient's own blood. Even when some stored blood is available for transfusion, the urgency of massive bleeding is such that autotransfusion may be lifesaving. This has been the experience of ICRC surgeons in Lebanon, the Democratic Republic of the Congo, Liberia, Somalia and elsewhere.





## **Chapter 35**

# **WAR WOUNDS IN PREGNANT WOMEN**

35.	WAR WOUNDS IN PREGNANT WOMEN	
35.1	Introduction	525
35.2	Wound ballistics	525
35.3	Epidemiology and international humanitarian law	525
35.3.1	Women facing war and international humanitarian law	526
35.4	Clinical picture and emergency room care of the mother	527
35.4.1	The differences of pregnancy	527
35.4.2	Airway	527
35.4.3	Breathing	528
35.4.4	Circulation	528
35.4.5	Further examination and investigations	528
35.5	Examination of the foetus	529
35.6	Surgical decision-making	530
35.6.1	Extra-abdominal wounds	530
35.6.2	Abdominal injuries	530
35.6.3	Indications for emergency Caesarean section	530
35.7	Surgery of the abdomen	531
35.7.1	Injury to the uterus itself	531
35.7.2	Injury to other organs	531
35.7.3	Abdominal closure	532
35.7.4	The foetus	532
35.8	Post-operative care	532



## Basic principles

A pregnancy test is mandatory for all female patients of childbearing age.

Resuscitation of the mother comes first: it is better for her – and for the foetus.

The enlarged uterus will raise the diaphragm: take care when inserting a chest drain.

Even minor maternal trauma increases the rate of miscarriage and abruptio placentae.

The surgeon must be ready to perform a Caesarean section, or even an emergency hysterectomy.

### 35.1 Introduction

When presented with a pregnant woman suffering from trauma the attending physician faces two patients: the woman and the foetus. The basic principles of patient management still apply, but the anatomic and physiological changes of pregnancy must be taken into consideration. In addition, foetal monitoring complicates observation of the mother. Resuscitation of the mother takes priority; this is also best for the foetus. Pregnancy, nonetheless, creates particular diagnostic and ethical challenges.

The best resuscitation for the foetus is good resuscitation of the mother.

### 35.2 Wound ballistics

The non-gravid uterus is a very dense muscle enclosing a very thin, even virtual, cavity and reacts to projectile injury as any muscle. Alone amongst the organs of the body, the gravid uterus changes in ballistic character over time; the myometrium becomes thinner and the uterus fills with amniotic fluid and the products of conception. The increased size of the full-term uterus fills the abdominal cavity, thus permitting the full effect of wound channel cavitation to be expressed within the organ.

The fluid-filled uterus can be affected by the same ballistic phenomenon of “boundary effect” as the full stomach or bladder (see Section 3.4.3). A high-kinetic energy projectile that provokes major cavitation can cause uterine rupture, leading to lethal haemorrhage in the mother. Or, it may provoke abruptio placentae resulting in the death of the foetus even if it is not directly injured. A previous Caesarean scar is a particularly weak ballistic point in the uterine wall and more prone to rupture in this case.

On the other hand, the foetus and placenta together constitute a heterogeneous mass of tissues, often sufficient to stop a low-kinetic energy projectile. Depending on the degree of tissue damage, the foetus may survive to term intact.

Little is known of the effects of primary blast on pregnancy apart from the possible occurrence of abruptio placentae.

### 35.3 Epidemiology and international humanitarian law

Although the number of civilian victims of contemporary warfare since World War II has increased, exceedingly little epidemiological information exists on the incidence of the wounding of pregnant women during armed conflict.

While in most traditional societies women continue working in the fields right up to the moment of childbirth, the tendency in general and especially in urbanized societies is to progressively limit women’s mobility as their pregnancy advances, and thus

their exposure to the outside environment, especially a violent one. In some societies, women's access to medical care is limited by cultural constraints and in such settings many women die at home from obstetrical complications. Nonetheless, even in urban civil wars characterized by street fighting and bombing of residential neighbourhoods, the great majority of victims are still men. Those who have practised surgery under such conditions have always marvelled at how few cases of injured pregnant women they have attended to.

Most epidemiological studies stem from industrialized countries during peacetime, but these primarily involve motor vehicle crashes and personal aggression. Thus, most knowledge of maternal and foetal morbidity and mortality is based on blunt trauma, although some series have sufficient numbers of civilian gunshot wounds to make comparisons. One such recent study described 321 pregnant patients, 30 (9%) of whom had suffered penetrating abdominal injury: 22 gunshot wounds, 7 stab wounds, and 1 shotgun injury.<sup>1</sup> The patients with penetrating trauma demonstrated higher maternal mortality (7% vs. 2%, not significant), and significantly higher foetal mortality (73% vs. 10%) and maternal morbidity (66% vs. 10%) when compared to cases of blunt trauma.

Only two modern studies of injury specific to pregnant women during armed conflict are well known. One comes from Lebanon and was limited to fourteen women whose pregnancy was beyond a gestational age of 20 weeks who had suffered non-pelvic abdominal wounds with documented injury to the uterus.<sup>2</sup> Seven patients were injured by rifle bullets and another seven by shell fragments. If the entry wound, whether anterior or posterior, was above the level of the uterine fundus, there was invariably associated visceral injury. An entry wound below the level of the fundus resulted in no other visceral injuries. It was concluded that the gravid uterus acted as a sort of "shield", protecting the maternal vital organs and major blood vessels, at least from low-kinetic energy missiles.

The other study from Israel concerned twelve pregnant women, whatever the anatomic region injured, and suffering wounds from bomb fragments (5 patients), GSW (5), and both fragments and bullets (2).<sup>3</sup> Four of five women with viable foetuses required early Caesarean section (CS) because of obstetric complications. All others continued to term, even those injured in early pregnancy (gestational age of 6 weeks).

In general, fragment wounds have much less of a deleterious effect than gunshot wounds, as is to be expected. GSW confined to the abdomen provoke a foetal perinatal mortality of 40 – 70%, reaching 80% and more if the woman is admitted with haemorrhagic shock. The most common cause of foetal death after any trauma, however, is maternal death.

### 35.3.1 Women facing war and international humanitarian law

Projectile and blast trauma are not the only dangers that women face during armed conflict. In many wars throughout history women have often been the targets and victims of sexual violence; i.e. rape as a method of warfare waged against an entire society. For some combatants, the insemination of women is an "aim" of war. In certain modern conflicts, rape has reached epidemic proportions.

The ICRC and others have studied the implications for international humanitarian law of the particular socio-economic conditions of women, pregnant or not, during armed conflict. These studies include the repercussions on their health in the widest sense of the term.<sup>4 5</sup> Needless to say, sexual violence against women is specifically prohibited by IHL and human rights law.

1 Petrone P, Talving P, Browder T, Teixeira PG, Fisher O, Lozornio A, Chan LS. Abdominal injuries in pregnancy: a 155-month study at two level 1 trauma centers. *Injury* 2011; **42**: 47 – 49.

2 Awwad JT, Azar GB, Seoud MA, Mroueh AM, Karam KS. High-velocity penetrating wounds of the gravid uterus: review of 16 years of civil war. *Obstet Gynecol* 1994; **83**: 259 – 264.

3 Sela HY, Shveiky D, Laufer N, Hersch M, Einav S. Pregnant women injured in terror-related multiple casualty incidents: injuries and outcomes. *J Trauma* 2008; **64**: 727 – 732.

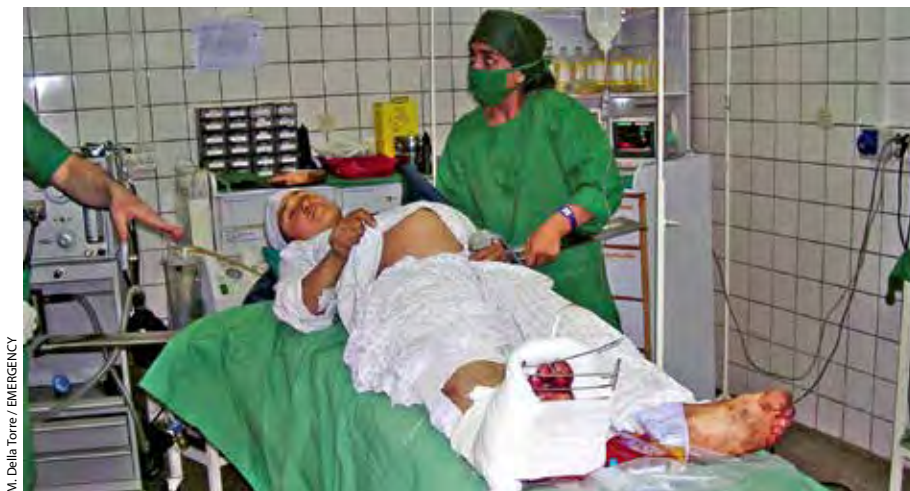4 Lindsey C. *Women Facing War: ICRC Study on the Impact of Armed Conflict on Women*. Geneva: ICRC; 2001.

5 Lindsey-Curtet C, Tercier Holst-Roness F, Anderson L. *Addressing the Needs of Women Affected by Armed Conflict: An ICRC Guidance Document*. Geneva: ICRC; 2004.

## 35.4 Clinical picture and emergency room care of the mother

Every female patient of childbearing age should be considered as possibly pregnant until proven otherwise. It is important to recognize the existence of a pregnancy and its significance for trauma management:

- same priorities for the mother as for all trauma patients according to the ABCDE paradigm;
- differences from other trauma patients, according to the physiologic changes due to pregnancy;
- assessment of the clinical condition of two patients: mother and foetus.



**Figure 35.1**

A pregnant women may suffer any injury. The same priorities apply as for all trauma patients.

### 35.4.1 The differences of pregnancy

Pregnancy produces profound anatomic and physiologic changes; virtually every organ system is affected. The reader should refer to standard textbooks for a full discussion of these changes. Only a short résumé of a few clinically relevant points is given here.

The anatomic changes in pregnancy, apart from the large “*tumour*” present in the peritoneal cavity and the displacement upwards of the intestines and diaphragm, include a greatly increased utero-pelvic blood flow with hypertrophy of the uterine vessels. Muscle guarding and rigidity of the abdominal wall are decreased or even absent in the event of peritoneal irritation.

The gestational age can be deduced from the patient’s history and level of the uterus: a pregnant uterus expands beyond the pelvis by the 12th week of pregnancy.

All women of childbearing age should be asked about their recent menstrual history, and all should undergo a urine pregnancy test. Where there is even the slightest suspicion of pregnancy, an obstetrics colleague or midwife should be consulted.

A distended abdomen may indicate a gravid uterus or intra-abdominal bleeding – or both.

### 35.4.2 Airway

Here, there are relatively few changes with pregnancy, except for an increased risk of regurgitation and aspiration due to the decrease in the tone of the oesophageal sphincter and delayed gastric emptying due to the increased abdominal volume. It has been noted that endotracheal intubation has a much higher failure rate in late pregnancy owing to oedema of the larynx, with a significant risk of regurgitation and inhalation.

### 35.4.3 Breathing

The respiratory rate remains unchanged in pregnancy, but physiological hyperventilation occurs because of an increase in tidal volume of 40%. This results in a slight respiratory alkalosis. In late pregnancy, there is diminished chest amplitude due to the rising of the diaphragm with increased intra-abdominal volume. Clinically, great care must be taken in placing a chest tube. Supplemental oxygen is important to avoid hypoxia, particularly deleterious to the foetus.

Take great care when placing a chest tube in a pregnant patient.

### 35.4.4 Circulation

The patient's circulation probably shows the greatest physiological changes. Up to a gestational age of 34 weeks there is a steady increase in blood volume with more plasma relative to red blood cells, leading to the physiologic anaemia of pregnancy (haematocrit 31 – 35%). Cardiac output is increased by 30% during the first trimester by a slight tachycardia of 10 – 15 beats/minute. This is important in the evaluation of the haemodynamic status of the wounded patient.

Young, healthy pregnant patients may maintain their blood pressure and relatively low pulse rate even with a blood loss of up to 1,500 ml (35% of blood volume) before signs of shock appear. Therefore resuscitation cannot be monitored correctly by the usual parameters. Haemodynamic instability on admission indicates severe trauma. The pregnant trauma victim will require more blood volume replacement than a non-pregnant woman of the same size and weight. Vigorous fluid replacement is warranted even in the absence of signs of shock.

If the patient in the last trimester of pregnancy is lying on a stretcher, spinal board or operating table the gravid uterus can cause compression of the vena cava leading to decreased venous return and resultant hypotension. This can be avoided by keeping her in the left lateral decubitus position or tilted 15° towards the left by a pillow placed below the right flank and the uterus manually displaced to the left.

Antibiotics, anti-tetanus prophylaxis and analgesia that does not induce respiratory depression are administered.

### 35.4.5 Further examination and investigations

The full obstetric history of the patient must be taken.

Increased uterine activity is common following trauma, but can also be a sign of premature labour or abruptio placentae. Its occurrence a few days after the injury may also indicate infection. Any uterine contractions or tenderness, abdominal pain or cramping should be sought.

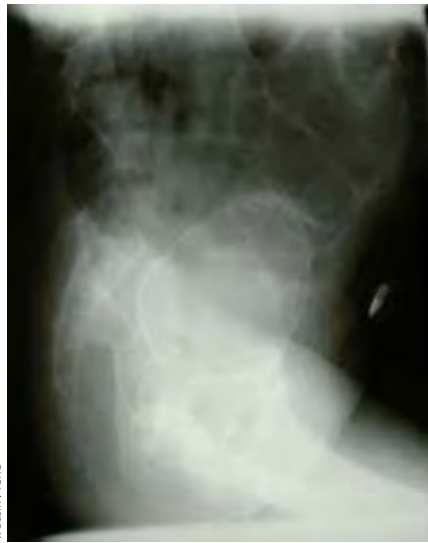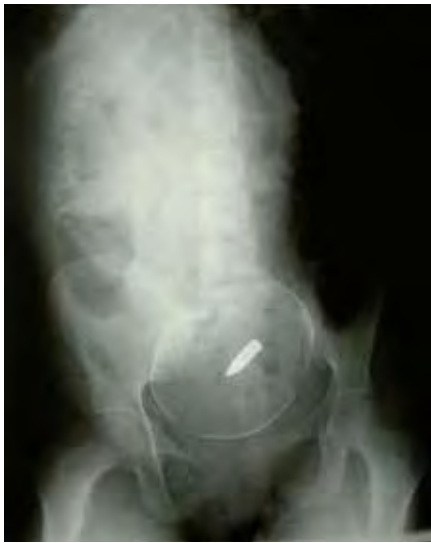Vaginal examination assesses the state of the cervix and the presence of blood or amniotic fluid; combined with abdominal palpation, the foetal presentation is checked. Vaginal bleeding is never normal. Its presence should raise the possibility of premature labour, abruptio placentae, placenta praevia, or uterine rupture, in addition to the trauma. In case of vaginal bleeding or loss of amniotic fluid, a sterile compress or ordinary sanitary pad should be placed extravaginally to absorb the liquid until the underlying condition has been dealt with.

A rectal examination to rule out any rectal injury completes the local examination.

Pregnancy is not a contraindication for radiography.

X-rays should be taken as and when necessary. Ordinary radiographs have a very low dose of radiation and pregnancy is not a contraindication to radiography; the risk of

radiation-induced foetal injury is lower than the benefit gained in management of the mother. Nonetheless, due precautions with a lead shield should be taken. The first trimester foetus is the most sensitive to radiation.



Figures 35.2.1 and 35.2.2

X-rays showing an intra-abdominal but extra-uterine bullet.

A naso-gastric tube and urinary catheter are placed. Routine laboratory examinations are performed.

Also of particular importance is the mother's blood group if she is Rh-negative and the foetus Rh-positive. The problem of iso-immunization is not specific to trauma patients, but trauma may theoretically increase the possibility if the foetus is injured. In this case, the mother should be treated with anti-Rh globulin within 72 hours following the injury, if available.

Remember to check for Rh iso-immunization.

### 35.5 Examination of the foetus

Once life-threatening injuries in the mother have been addressed, the condition of the foetus and maturity of the pregnancy must be properly dealt with. This includes determining the foetus' age and its chances of extra-uterine survival and, therefore, the opportune moment for performing a Caesarean section should it prove necessary.

All patients with a viable foetus should be monitored for six hours after all diagnostic and initial therapeutic procedures have been completed. Sophisticated means exist for foetal monitoring, but these are not always readily available. Again, obstetric consultation is essential.

The foetus is highly susceptible to the effects of maternal hypoxia and hypotension. Loss of the foetus frequently follows prolonged maternal hypotension and/or hypoxia, abruptio placentae, direct injury to the uterus and, obviously, maternal death.

Signs of foetal distress mainly include:

- bradycardia less than 110 beats/min;
- tachycardia greater than 170 beats/min, frequently also observed when the mother has fever;
- loss of beat-to-beat variability;
- late decelerations of the foetal heart rate in response to uterine contractions.

In addition, the projectile may cause direct injury to the foetus, placenta or umbilical cord, possibly causing haemorrhage or, later, infection. Diagnosis is difficult if not impossible in most cases, apart from sepsis and conditions causing foetal death. The mother should be kept under antibiotic cover (ampicillin and metronidazole) as long as necessary, usually about 5 days.

Viability of the foetus is determined to a large extent by the availability of incubators and personnel trained in premature neonatal care. In conditions of limited resources this may be defined as a gestational age of 30 – 32 weeks or even later.

Please note:

If there is no neonatal intensive care unit, it is not reasonable to perform a Caesarean section for foetal distress before a gestational age of 30 – 32 weeks. This is a difficult decision. In a resource-poor setting, most very premature neonates of less than a gestational age of 30 weeks must be considered quite desperate – if the child survives, there will all too often be severe neurological sequelae. It is best for the specific hospital to establish a protocol about gestational week limits as any “useless” Caesarean (defined as a CS without a surviving and relatively healthy child) only burdens the woman with one more big risk: a uterine rupture in the context of limited resources during a future pregnancy. What is more, if the child survives with serious sequelae, it will only create a difficult situation for the family.

## 35.6 Surgical decision-making

Survival of the mother has priority because she may have other dependent children and, of course, the potential for future pregnancies.

Survival of the mother has priority over survival of the foetus.

### 35.6.1 Extra-abdominal wounds

In a pregnant patient these injuries should be managed as for a non-pregnant patient, taking into proper consideration the physiological changes of pregnancy and the adverse effects of shock and hypoxia on the foetus.

### 35.6.2 Abdominal injuries

There are definite indications for surgery in pregnant patients as for others suffering penetrating wounds of the abdomen. Obvious internal haemorrhage or peritoneal irritation and wounds above the level of the uterine fundus call for laparotomy. However, if the entrance wound is below the level of the uterine fundus and there are no clinical signs warranting laparotomy or significant pelvic injury, the patient may be observed and managed non-surgically, especially if the projectile is shown to be intra-uterine by X-ray. An injured uterus can still deliver a viable infant; foetal fractures and other minor wounds can heal *in utero*.

An injured uterus can still deliver a viable infant.

If in addition Caesarean section is not indicated, rest and observant expectancy is the best and simplest method to prolong the pregnancy after trauma or laparotomy, bearing in mind the substantial risks of thrombo-embolism when prolonged bed rest cannot be avoided. Any fever must always be treated with paracetamol because fever can cause uterine contractions and then premature delivery.

### 35.6.3 Indications for emergency Caesarean section

Normal labour often occurs shortly after surgery for other injuries if the patient is at term. While even minor maternal trauma increases the rate of spontaneous abortion and stillbirth, early pregnancy often continues unaltered.

A dead or injured foetus is not an indication for Caesarean section; the foetus will usually abort spontaneously within a few days. If specialized obstetrical care is available, delivery can be hastened by prostaglandins or intra-amniotic saline.

The indications for emergency Caesarean section relate to either the mother or the foetus. To the classical complications of pregnancy requiring immediate CS must be added uterine rupture caused by a projectile. Maternal shock due to haemorrhage, whatever the cause, which is jeopardizing the viability of the foetus may warrant a CS, however it *increases* maternal haemorrhage and cannot be considered a stabilizing measure. In such cases it is aimed only at saving the foetus.

Genuine foetal distress in a viable foetus may also warrant a Caesarean section. The availability of resuscitation resources, for both mother and foetus, is crucial. As mentioned, with limited resources there is no indication for Caesarean section before a gestational age of 30 – 32 weeks.

#### **Perimortem Caesarean section**

A pregnant woman in the throes of death from abdominal or extra-abdominal trauma should be prepared for Caesarean section if the foetus is still viable and close to term. The operation should be performed preferably before death or at least within 5 minutes of death. Exceptionally, short open cardiac massage can be employed if necessary until delivery of the child.

## **35.7 Surgery of the abdomen**

To explore the abdomen the surgeon may retract or pull and push or pack away the uterus without risk to the foetus or placenta. The one manoeuvre to be avoided is the *rotation of the uterus on its axis*, which may compromise its circulation by distorting the uterine vessels and can injure the low uterine segment during the third trimester.

### **35.7.1 Injury to the uterus itself**

Small wounds of the uterus that do not themselves compromise the possibility of subsequent vaginal delivery may be debrided and sutured primarily. As with all hollow organs, inspection for an exit wound is warranted, although in most low-kinetic energy lesions the projectile is retained within the uterus.

Large wounds should be debrided and sutured in layers as with a CS. The extent of the wound, the penetration or not of the amniotic pouch, and the gestational age determine whether later delivery should be vaginal or by Caesarean section. If the foetus is viable and near term, it may be delivered immediately during primary laparotomy.

Very large wounds are the equivalent of a Caesarean section with delivery into the peritoneal cavity, in which case the foetus is almost always dead after a few minutes because of the placental abruption. Whether emergency hysterectomy or uterine repair is performed depends on the degree of damage, as after rupture of the uterus due to obstructed labour.

The uterine arteries and veins are hypertrophied during pregnancy: they are longer, larger, more tortuous, and therefore more prone to injury from a projectile. They may be tied unilaterally without putting the foetus into any particular danger beyond that already present because of the haemorrhage.

### **35.7.2 Injury to other organs**

In most cases, injuries will be to the intestines that have been pushed up into the upper abdomen. Surgical treatment proceeds as usual. Problems may arise with surgical access to injured structures deep in the pelvis. Terminating the pregnancy by Caesarean section, or even in extreme cases emergency hysterectomy, may be necessary to gain adequate exposure, especially if the mother's life is in danger from exsanguinating haemorrhage.

### 35.7.3 Abdominal closure

Closure of the abdomen is standard. There are damage-control situations, however, where packing has been utilized for temporary control of bleeding or where zealous resuscitation has resulted in oedema of the intestines to such an extent that closure is not possible while maintaining an intact pregnancy. Temporary abdominal closure of the skin only may be accomplished without compromising normal labour and vaginal delivery, even if subsequently the patient is not able to perform a Valsalva manoeuvre. Caesarean section is performed if necessary. The incisional hernia is dealt with later as an elective procedure.

### 35.7.4 The foetus

Caesarean section increases blood loss and causes a uterine scar that greatly augments the risk of rupture during a subsequent pregnancy. Thus, vaginal delivery is preferable, even within a few hours of laparotomy and always when the foetus is dead, providing there are no maternal indications for a CS.

As mentioned, injury to the uterus does not prevent vaginal delivery of a healthy infant. For a dead foetus, delivery may await the onset of spontaneous labour or it may be induced. Delay should not be too long in case of uterine and foetal injury in order to avoid infection and disseminated intravascular coagulopathy.

## 35.8 Post-operative care

There is an increased risk of both deep venous thrombosis and pulmonary embolism during pregnancy. Passive or active means of prevention should be instituted in compliance with local practice. The highest risk is during the immediate post-partum period.

The rest of post-operative or post-partum nursing care and physiotherapy are the same as for other abdominal injuries and Caesarean sections.







**Part E**

# **SPINE**

E. SPINE

## Basic principles

Spinal cord injury is a common condition after war wounds to the vertebral column.

A great deal can be done to assure dignified living conditions for the spinal cord injured patient.

The “patient management team” includes the hospital staff, family, friends, social assistants, community members, and the patient.

The consequences of injury to the spinal cord are probably the most disheartening, frustrating and tragic that hospital staff working in resource-poor settings must face. Early death of the patient, often in difficult and “undignified” circumstances, is common. Mid- and long-term treatment is extremely difficult and challenging given the lack of institutional resources. Though often read about and wished for, rehabilitation is a dream that cannot come true.

The management of patients with spinal cord injury (SCI) requires a comprehensive multidisciplinary approach. Physiotherapy, nursing care and psychological support form more than 90% of the treatment. Unfortunately, in many low-income countries trained physiotherapists and psychologists are rare or non-existent. Moreover, nursing staff are all too often scarcely trained in basic patient physiotherapy. It is therefore up to the surgeon, when faced with a lack of adequately trained personnel, to organize the proper protocols for patient management which must be continued at home following discharge.

Next to organic pathologies, depression is the great killer of patients with spinal cord injury. Faced with the frustration of dealing with this pathology, “benign neglect” of the patient was, and still too often is, the road chosen. This attitude must be overcome. It begins immediately on admission and involves the hospital staff, the patient and the patient’s family and friends.

The change in attitude begins with small things: no doctor or nurse should pass by without greeting or addressing a word or two to the patient. Neglect, “overlooking” the patient, only reinforces the perception that he or she is excluded from the rest of the world.

“Never pass by without saying something to the paraplegic.”

M. King<sup>1</sup>

The hospital staff, however, cannot replace the support of family and friends. Consultation and explanation of what is involved is the key. The surgeon, head nurse and physiotherapist must sit down with the family and explain the challenges ahead. A visit to the house before discharge to prepare the environment, and repeat visits after discharge are necessary.

A repetition of a quote from Chapter 26 is in order: rehabilitation is a “creative cooperative effort by the health care team, patient, and family that is aimed at optimizing mental, social, and vocational aptitudes”.<sup>2</sup> Thus, the care of the SCI patient is a true team effort involving the hospital staff, family, friends and the community, especially any social carers who may be present. The quality and sophistication of home care depend on the capacity and dedication of hospital staff to instruct and assist the home care team and the patient, family and friends. Everything must be done to ensure the necessary cooperation of all concerned in order to guarantee a decent and dignified survival for the patient and make certain that a “pessimistic attitude is unwarranted”.

1 King M, ed. *Primary Surgery, Volume Two: Trauma*. Oxford: Oxford University Press; 1987.

2 Erdogan E, Gönül E, Seber N. Craniocerebral gunshot wounds. *Neurosurg Quart* 2002; **12**: 1 – 18.

The patient and family must assume responsibility for the nursing and physiotherapy tasks involved as early as possible in-hospital and continue to do so on a long-term basis. Patient hygiene is a central concern. This includes washing of the body, care of the genitalia and bowel, and clean and dry bedclothes. Maintenance of nutrition, prevention of infectious complications and bedsores and regular exercises should never be forgotten and early mobilization of the patient helps in maintaining morale as well.

**Figure E.1**

Rehabilitation of spinal-injury patients.



D. Constantine / MOTIVATION

“In no previous war, nor in civilian life, has the patient recovering from the immediate effects of a spinal cord injury been considered particularly a problem. In general, it has been taken for granted that he was a hopeless cripple and that, from bladder infection with its sequelae, his life expectancy was brief. Nursing care and narcotics were in most instances the main treatment. The entire attitude has changed in the past few years. We now know that many of these patients can be cleared of infection and live as long as any one else, that bed sores can be closed with good tissue, that locomotion is possible, and that jobs can be found for them. Many minds have been at work once it was recognized that the previous pessimistic attitude was unwarranted.”

R.H. Kennedy<sup>3</sup>

### Home-care team

In some countries, specialized centres for SCI patients exist and even vocational training workshops and micro-credit programmes. Few low-income societies, however, have fully-fledged programmes for training and social reintegration. These then depend on local initiative at district or village level. Hospital staff are usually well-respected in the community and, therefore, have an important role to play in instigating these initiatives, including the organization of a home-care team.

The guidelines to be found as annexes in the DVD accompanying this manual are intended for the home-care team, but may be adapted for distribution to the patient and family in brochure form. The terminology is simplified and aimed at the lay person as well as any health professional – nurse and/or physiotherapist – or social carer. They should obviously be translated into the local language and respect cultural norms.

<sup>3</sup> Kennedy RH. The new viewpoint toward spinal cord injuries. *Ann Surg* 1946; **124**: 1057 – 1062.

A number of major problems will be encountered in the long-term care of the SCI patient and several severe complications must be avoided. Psychological depression, due not only to the loss of self-image and personal independence but also to sexual dysfunction, requires good moral support and proper psychological intervention where available. Such support may also be necessary for family members. They should be informed that a woman suffering from SCI can still carry a normal pregnancy to full term and deliver vaginally. Men can still have sexual activity and father children.

Please note:

Given the difficulty and challenges in the management of patients suffering paraplegia, the care of the tetraplegic patient in low-income countries is an almost impossible task. Thus a realistic approach is to give the patient minimal care, allowing him or her to live as dignified and acceptable a life for as long as possible. Chapter 36 deals primarily with the paraplegic patient – naturally any nursing or physiotherapy measures apply to the tetraplegic as well.





## **Chapter 36**

# **INJURIES OF THE VERTEBRAL COLUMN AND SPINAL CORD**

36.	INJURIES OF THE VERTEBRAL COLUMN AND SPINAL CORD	
36.1	Wound ballistics	543
36.2	Epidemiology	544
36.3	Pathophysiology	545
36.3.1	“Spinal shock”	545
36.3.2	Neurogenic shock: autonomic nervous system dysfunction	546
36.4	Clinical picture and examination	546
36.4.1	Complete examination	548
36.4.2	Prognosis and re-examination	549
36.4.3	Radiographic investigation	549
36.5	Emergency room management	550
36.5.1	Stabilization of the vertebral column	551
36.6	Surgical decision-making	552
36.6.1	Indications for surgery	552
36.6.2	Medical care	553
36.7	Organization of further management	553
36.8	Skin care	554
36.8.1	Change of position	554
36.9	Care of the bladder	555
36.9.1	In-dwelling urinary catheter	555
36.9.2	Intermittent catheterization	556
36.9.3	Spastic or flaccid bladder?	556
36.9.4	Testing bladder tone	556
36.9.5	Medium to long-term bladder management	557
36.9.6	Positioning of a catheter	557
36.10	Nutrition and care of the bowels	558
36.11	Physiotherapy and mobilization	558
36.12	Complications	560
36.12.1	Treatment of established decubitus ulcer	560
36.12.2	Urinary tract infection	561
36.12.3	Autonomic dysreflexia/hyperreflexia	562
	ANNEX 36. A Hospital nursing care	563

## Basic principles

Projectile wounds to the spine are very different from the deceleration injuries of blunt trauma.

Penetrating wounds to the spine usually mean that the patient will be permanently paraplegic or tetraplegic.

The indication for surgery is rare, except for simple wound management. Surgery will seldom improve the condition.

Good nursing care and physiotherapy is more important than surgery.

Patients will need life-long care to avoid bedsores, pneumonia and urinary tract infection.

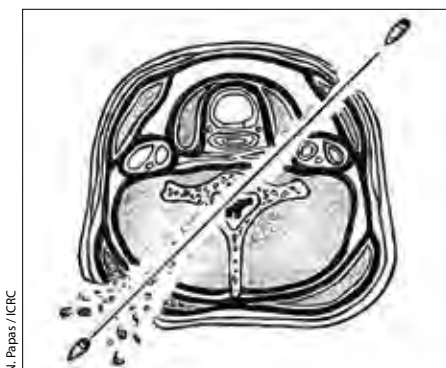
As mentioned several times in both Volumes 1 and 2 of this manual, projectile wounds to the vertebral column and spinal cord in general, and the cervical spine in particular, are very different from the deceleration injuries of blunt trauma, such as motor vehicle crashes and falls. This chapter deals with the surgical management of projectile wounds only.

### 36.1 Wound ballistics

The cervical spine is located deep in the tissues, just about in the centre of the neck, which has a rather small diameter in any direction. Its primary characteristic is its mobility, which allows a reaction to any temporary cavitation effect. The thoracic spine is more superficial and more stable owing to the rigidity of the rib cage. The lumbar spine has little mobility and is located deep within the tissues but, since the spinal cord ends at vertebral level L1 – L2 in the adult, any lower wound is to the nerve roots only. Thus, projectile injuries to the lumbo-sacral vertebrae containing the cauda equina are not usually as severe since the free-lying spinal roots can “flee” away from a projectile.

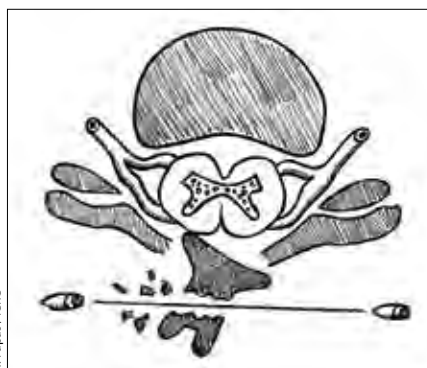The vascularization of the spinal cord is poor, especially in its thoracic part, and very sensitive to direct or nearby ballistic effects.

A missile directly hitting the spinal cord itself, or causing projection of bony fragments from a fractured vertebra into the cord, lacerates the tissues and provokes a definitive and permanent lesion. There is always a clear clinical picture, of tetraplegia or paraplegia depending on the level of the lesion.



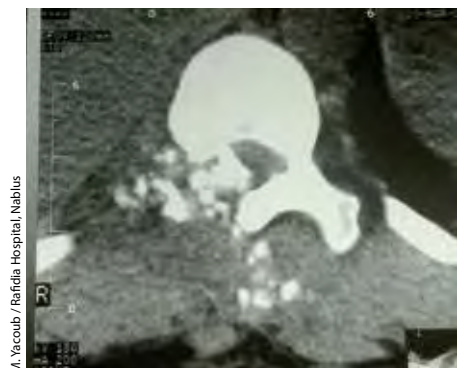**Figure 36.1**

An FMJ bullet has hit the cervical vertebral column. The spinal cord is irredeemably lacerated.



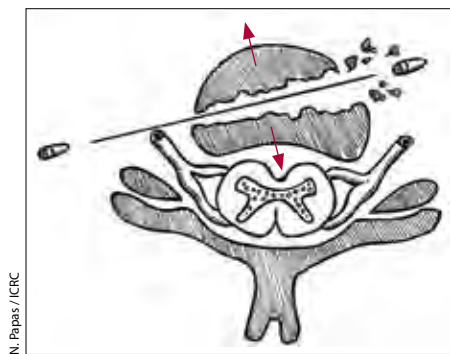
**Figure 36.2.1**

The fractured spinous process impinges on the spinal cord.



**Figure 36.2.2**

CT-scan showing the fractured transverse and spinous processes lacerating the spinal cord.



N. Pepas / CRIC

**Figure 36.3**

The vertebral body is hit and a strong impulse is propagated to the spinal cord.

In addition, spinal cord lesions can be caused by three indirect mechanisms.

1. A projectile hitting a spinous or transverse process or striking the body of a vertebra tangentially is the equivalent of a *blunt blow*. No fragment enters the vertebral canal, which remains intact, but the cord may suffer damage nonetheless from the transfer of kinetic energy in the form of a very short but strong impulse. In these cases the same wound may result in no neurological damage whatsoever, or in a temporary or definitive paralysis. This last may be due to a compromise of the vascular supply. Damage to the cord is more likely in the narrowest part of the spinal canal (around T4).
2. A high-energy stable bullet creates a temporary cavity that produces a pressure wave in proximity to the spinal cord. The occurrence of a phase 2 temporary cavity depends on the length of the bullet's trajectory in the body. The entry must therefore be anterior or lateral and through the chest or abdomen for a cavitation effect to be able to affect the spinal cord. Furthermore, as in other parts of the body, the cavitation effect may produce intimal damage to the vessels with subsequent thrombosis of the segmental spinal arteries.

These two mechanisms were first described under the clinical term of "spinal concussion" ("*commotion médullaire*") during the 1914 – 18 war<sup>1</sup> and today included under the expression "spinal shock". A block occurs in the nervous conduction in the cord with a whole spectrum of intermediary clinical presentations. However, the term concussion to cover all such conditions may well be a misnomer since researchers have noticed contusion of the cord in some cases, while in others there are no gross anatomical changes. Clinically, the result is the same, a neurapraxia. Recovery from paralysis takes place after a few hours or a few weeks.

3. When a landmine detonates under a vehicle, the blast accelerates the chassis upwards delivering an axial load to the spine of a sitting occupant. A burst fracture of lumbar vertebrae, with or without a lesion of the spinal cord, in association with lower-limb fractures can result (see Figure 20.3).

## 36.2 Epidemiology

Reports of war wounds to the vertebral column and spinal cord are relatively rare because most cases are included under injuries to the head and neck, thorax or abdomen. A review of 11 military studies totalling 782 patients with spinal injuries found the cervical spine was the site of injury in 23% of patients, the thoracic in 41%, and the lumbo-sacral in 36%.<sup>2</sup> Fifty percent suffered complete spinal injury.

A few studies rate the incidence of survivable injuries at less than 1% and usually under 0.5. One such study comes from a specialized centre in Croatia that admitted 3,568 injured patients suffering from 5,345 wounds.<sup>3</sup> The anatomic distribution of wounds followed the classic pattern: limbs 69%, head 15%, thorax 11%, abdomen 4%, with the vertebral column as a separate category accounting for only 0.6%. The last figure comprised 32 patients, of whom only 20 (62.5%) had a lesion to the spinal cord resulting in a neurological deficit. However, only seven patients suffered complete paraplegia and one tetraplegia: i.e. 25% of vertebral injuries.

The low incidence is to be expected; the vertebral column is overlaid anteriorly by many vital structures in the neck, thorax and abdomen, which, if injured, cause the victim to succumb in the field. Soldiers suffering vertebro-spinal injuries, like comatose ones, usually have low priority for evacuation owing to the extreme severity of their

1 Claude H, Lhermitte J. Étude clinique et anatomo-pathologique de la commotion médullaire directe par projectiles de guerre. [Clinical and pathological study of direct spinal concussion by projectiles of war.] *Annales de médecine* 1915; **2**: 479 – 506.

2 Klimo P Jr, Ragel BT, Rosner M, Gluf W, McCafferty R. Can surgery improve neurological function in penetrating spinal injury? A review of the military and civilian literature and treatment recommendations for military neurosurgeons. *Neurosurg Focus* 2010 **28** (5): E4. Available at: <http://thejns.org/doi/pdf/10.3171/2010.2.FOCUS1036>.

3 Rukovansjki M. Spinal cord injuries caused by missile weapons in the Croatian war. *J Trauma* 1996; **40** (3 Suppl.): S189 – S192.

condition, the often disastrous prognosis, and the number of personnel required for their correct evacuation and transport. Patients with paraplegia are seen more frequently than those with tetraplegia, as the latter usually die during evacuation.

A number of studies demonstrate that gunshot wounds to the vertebral column are rarely unstable and the few that are show obvious and already established neurological deficits. Wound ballistics research demonstrates that the phenomenon of an *unstable vertebral column without spinal injury*, as may occur with blunt trauma and requiring special precautions while handling the patient, is exceedingly rare with projectile wounds.

### 36.3 Pathophysiology

Lesions to the spinal cord may be anatomic – a laceration or crush which may be complete or incomplete and cause permanent damage; or physiological – a form of concussion neurapraxia, which is temporary. Post-traumatic oedema may affect one or two segments above the site of the lesion; the level “drops” as this oedema resolves. A complete lesion above C5 results in tetraplegia and at C3 there is paralysis of the diaphragm and respiratory muscles and death. Between T1 and C5 there are various degrees of incapacity of the upper limbs. Below T1, the result is paraplegia.

A complete laceration of the spinal cord creates both an upper and lower motor neuron lesion. At the actual segment of injured spinal cord there is a lower motor neuron lesion with destruction of preganglionic autonomic neurons and anterior horn cells resulting in a flaccid paralysis. A complete lesion above vertebral level T12 – L1 (the conus medullaris in most adults) causes an upper-motor neuron paralysis below the level of damage; during the initial period of “spinal shock”, the muscles are flaccid. Later, reflex activity below the lesion recovers and, since the upper motor neuron lesion releases the lower neuron from its inhibitory effect, there is a hyper-reactive response: spastic paralysis. Sensation is lost below the level of the lesion. Clear indications of a complete lesion include retained conus-related reflexes (anal or penile: bulbocavernosus and cremasteric) and a return of the bladder and bowel reflexes *without* any recovery of sensation or motor power.

In the adult, injury at the level of L1 – 2 causes a lesion to the conus medullaris: saddle anaesthesia and loss of the bladder and anal reflexes. Injury below this vertebral level produces a cauda equina syndrome: a lower motor lesion to the nerve roots, with permanent flaccid paralysis and loss of the bladder and anal reflexes.

If the lesion of the spinal cord is incomplete some specific syndrome may be demonstrated, such as Brown-Séquard for example, whereby some sensation or motor function may remain. Some improvement occurs with the passage of time.

Whatever the level of injury, an apparently disproportionate catabolic response follows spinal cord injury. There is rapid muscle wasting, even of those muscles that remain innervated. This, and the various changes in immune and autonomic nervous system response, predispose to pressure ulcers.<sup>4</sup> The protein matrix of bones is also affected with loss of calcium and osteoporosis and a predisposition to urinary calculi.

#### 36.3.1 “Spinal shock”

“Spinal shock” is that period of a few hours to two weeks or more when there is complete absence of any cord function below the level of injury. It ceases when the cord resumes some function. It is a neurological phenomenon and not a “true” shock in the haemodynamic sense and should be distinguished from neurogenic shock, which does affect the circulation.

Spinal shock: a neurological event characterized by areflexia, flaccidity, anaesthesia, and autonomic paralysis below the level of the lesion.

<sup>4</sup> The words pressure or decubitus ulcer and bedsore are used indifferently in this text.

Almost any concussive injury to the spinal cord produces an abrupt cessation of nervous conduction at that level; a form of neurapraxia usually followed by recovery. This is the equivalent of the historical "*commotion médullaire*". Spinal shock is also apparent in complete transection of the cord and masks the nervous deficit. In the early stages, it is clinically impossible to tell the difference between temporary concussive spinal shock and a complete lesion masked by spinal shock. Infection and malnutrition tend to prolong the period of spinal shock.

### 36.3.2 Neurogenic shock: autonomic nervous system dysfunction

A lesion of the cervical cord causes sympathetic denervation (traumatic sympathectomy): sympathetic control of the cardiovascular system is lost while the parasympathetic is maintained. Thus there is an initial haemodynamic neurogenic shock due to the loss of peripheral vasoconstriction leading to pooling of blood in the peripheral veins. The parasympathetic predominance results in bradycardia, rather than the tachycardia of haemorrhagic shock. The patient becomes poikilothermic and hypothermia, as well as hyperthermia, is a real danger. It also produces constipation, hypotonicity of the bladder, a patulous anal sphincter, and priapism.

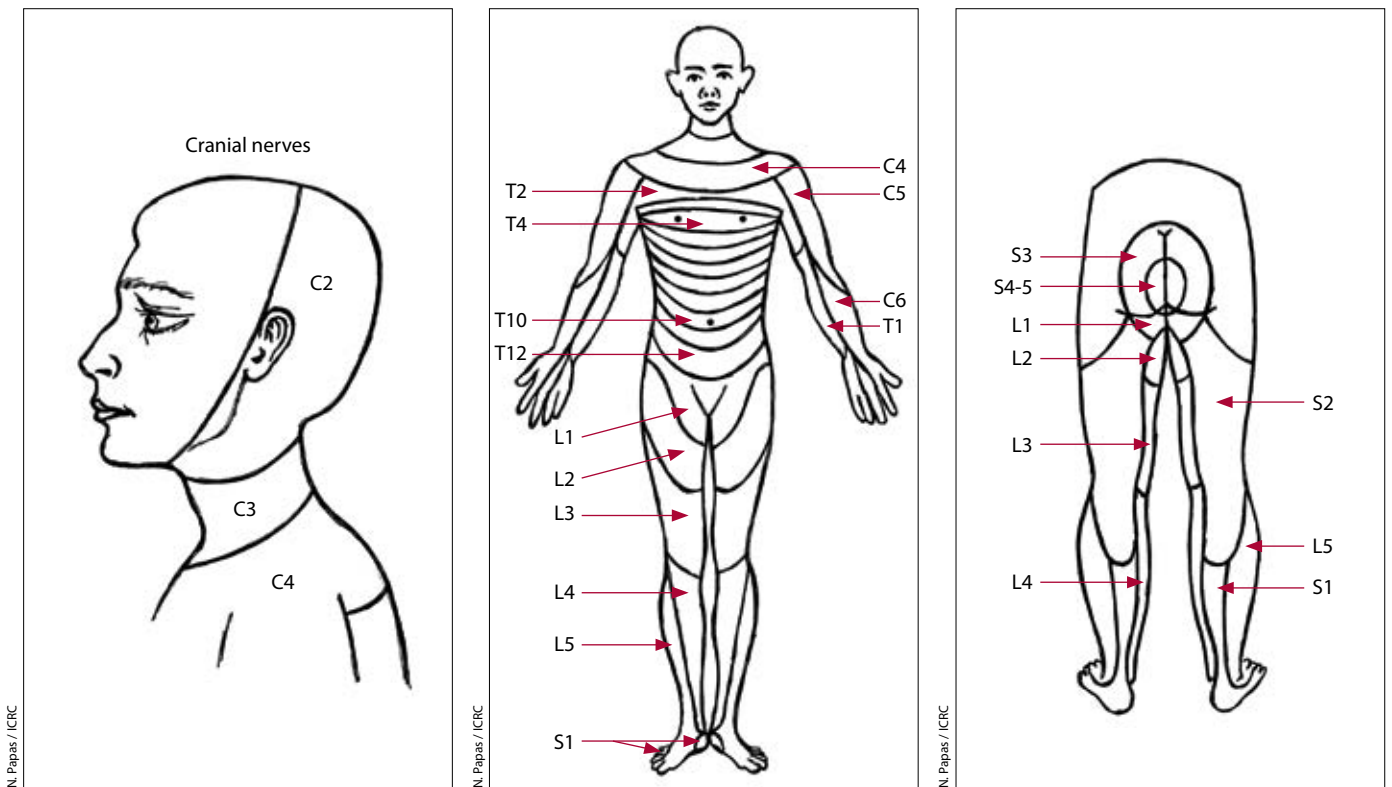
Neurogenic shock: a vascular event compromising the patient's haemodynamic status and presenting with bradycardia, hypotension and hypothermia.

In addition, autonomic cutaneous control is lost (pilo-erection, sweating and vasoconstriction), with the danger of rapid development of bedsores. The patient also suffers from Horner's syndrome owing to the loss of sympathetic innervation of the eye and face. Furthermore, the patient is susceptible to autonomic dysreflexia: a hyper-reflexive state due to an abnormal autonomic nervous system response to irritating stimuli (see Section 36.12.3).

## 36.4 Clinical picture and examination

Myotome spinal level	Muscle activity
C3 – C4	Diaphragm
C5	Elbow flexion
C6	Wrist extension
C7	Elbow extension
C8	Finger flexion (middle finger)
T1	Abduction of fifth finger
T6 – T12	Abdominal muscles
L2	Hip flexion
L3	Knee extension
L4	Ankle dorsiflexion
L5	Dorsiflexion great toe
S1	Ankle plantar flexion
S4 – S5	Voluntary anal sphincter contraction

Table 36.1 Key spinal cord levels.



**Figure 36.4**

Dermatome spinal sensory levels.

Between 50 and 60% of the patients suffering spinal cord injury also have important lesions in other vital organs of the neck, thorax, and/or abdomen. The picture can be complicated, however, by a high spinal injury causing neurogenic shock in addition to haemorrhagic shock. The priorities remain airway, breathing, and circulation.

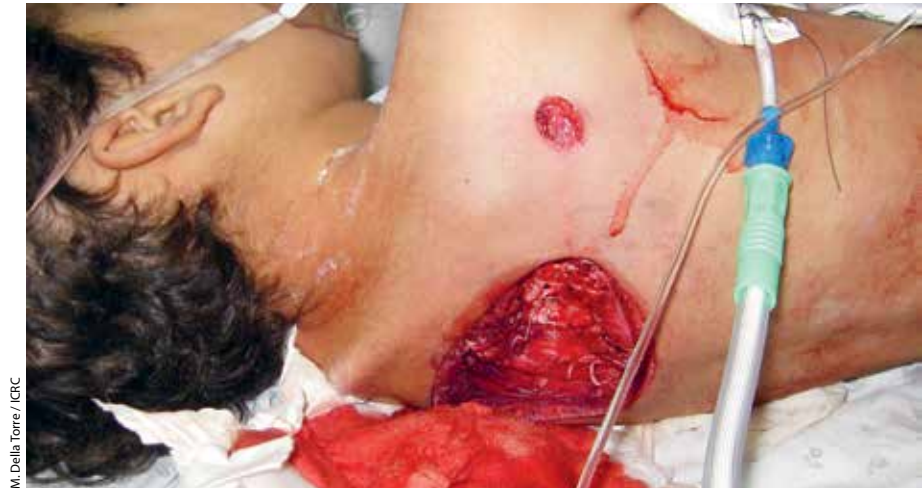“When a fracture occurs in the bones of the neck ... and you want to know whether it will heal or not, then look and if you see both his hands relaxed and numb and dead and he has no power to move or stretch or close them, and when you pinch them or prick them with a needle he does not notice it or feel any pain in them, you may know, as a general rule, that it will not mend, for he is doomed. But if he moves them both and feels in them the pinching and pricking, you may know that the spinal medulla is still intact and that under treatment the patient will recover.”

Abu al-Qasim Khalaf ibn al-Abbas Al-Zahrawi (Albucasis)<sup>5</sup>

5 Abu al-Qasim Khalaf ibn al-Abbas Al-Zahrawi (Albucasis) 936 – 1013 C.E. Arab physician born in al-Andalus and considered one of the greatest of mediaeval surgeons. His treatise, *Kitab al-Tasrif*, was a standard reference in Islamic and European medicine for 500 years. Cited in Goodrich JT. Cervical spine surgery in the ancient and medieval worlds. *Neurosurg Focus* 2007; **23** (1): E7.

Figure 36.5

Some cases are evident.



A brief initial examination allows the surgeon to determine whether the spinal cord has been affected: movement of the legs, reaction to pinching of the skin, etc. While dealing with life-threatening injuries in the thorax or abdomen it is very easy to “overlook” a lesion of the spinal cord. The same may happen with the unconscious patient suffering from spinal injury.

There are four major clinical presentations.

1. Immediate and complete loss of spinal cord function below the lesion and above the conus medullaris.
2. Incomplete but non-progressive neurological deficits.
3. Progressive neurological deficit.
4. Conus medullaris or cauda equina syndromes, with initial neurological signs that vary in severity. It should be noted that injuries to the cauda equina are difficult to differentiate from wounds of the lumbo-sacral plexus.

### 36.4.1 Complete examination

A complete examination includes not only the observation of entry and exit wounds but also a careful palpation of the spinous processes for any swelling and induration, localized pain and tenderness, crepitus, bruising or haematoma over the vertebral column. Induration is easier to feel than deformity of the spine. Bilateral sensory and motor functions and the testing of reflexes must be complete and repeated and noted in the patient’s file.

A thorough neurological examination includes sensory and motor function, reflexes, and cranial nerves in the event of neck injury. Each limb is assessed individually.

Sensation is tested by pin-prick from below upwards; then by light touch and deep pressure. Muscle strength is assessed using the Oxford Scale, a rating system used by physiotherapists and described in Annex 36. B (see DVD). Peripheral (elbow, knee and ankle) and central reflexes (bulbocavernosus, cremasteric and anal) are tested. A rectal examination for sphincter tone and sacral sparing (perianal sensation) is essential.

Partial injury to the cord may result in a mixed picture of sensory and motor loss and pathological reflexes. A standard and universally used classification to describe the grade of incapacity, known as the ASIA scale, is that of the American Spinal Injury Association (see Annex 36.B).



### 36.4.2 Prognosis and re-examination

The outcome of spinal injury is closely related to the initial neurological deficit. Concussion of the cord is temporary. With a complete lesion, often no improvement can be expected. With an incomplete lesion, the end result is unpredictable. There is always a certain degree of spinal shock with conduction block and localized oedema immediately after injury and time should be allowed for this to resolve. Thus, even a complete lesion may clinically “improve” by one or two segments.

It is important to note that, in the early stages, spinal shock following functional neurapraxia or an organic cord lesion, whether complete or incomplete, presents the same clinical picture. Only once the spinal shock begins to recede will the differentiation be possible and a final clinical picture emerge, giving a more accurate idea of any permanent damage.

The exceptions that allow for an early diagnosis of permanent damage are radiological evidence of violation of the vertebral canal and direct observation during wound toilet when the surgeon sees the cord injury. The only question remaining is: how much damage?

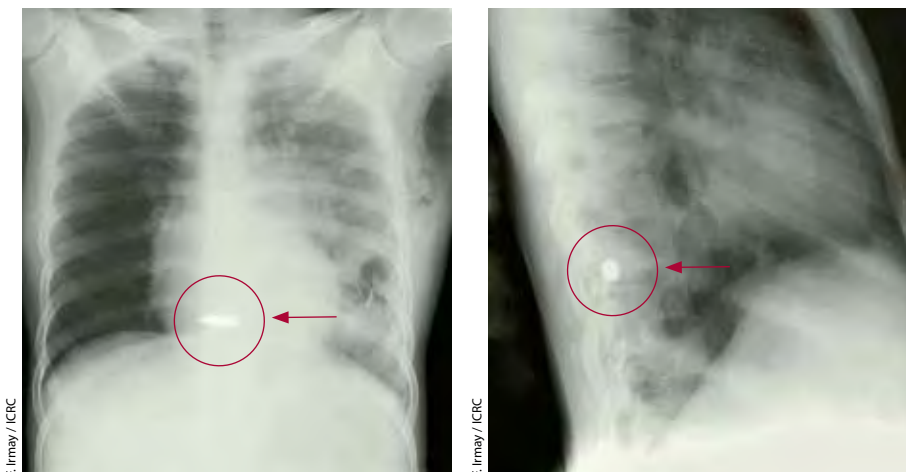
In the early stages, the clinical presentation of spinal shock is the same for both temporary concussion and permanent damage.

The surgeon must not jump to conclusions, therefore, and a complete neurological examination should be repeated several times over a period of 48 – 72 hours before pronouncing a prognosis to patient and family. This is particularly important for patients suffering tetraplegia, whose prognosis is dire. Where resources are limited, an early death is inevitable but the decision to restrict care to the basics must be made in conjunction with the family.

This being said, spinal cord injury is more often a complete lesion when inflicted by a projectile than when caused by blunt trauma. Any laceration of the cord by a bullet or fragment is irrevocable. It should also be noted that a transaxial injury is more likely to be a complete lesion.

### 36.4.3 Radiographic investigation

X-ray investigation shows any bony pathology and any retained projectiles. A standard series of radiographs includes two views of the injured section of the spine. The lateral cervical shot should show the top of vertebral body T1.



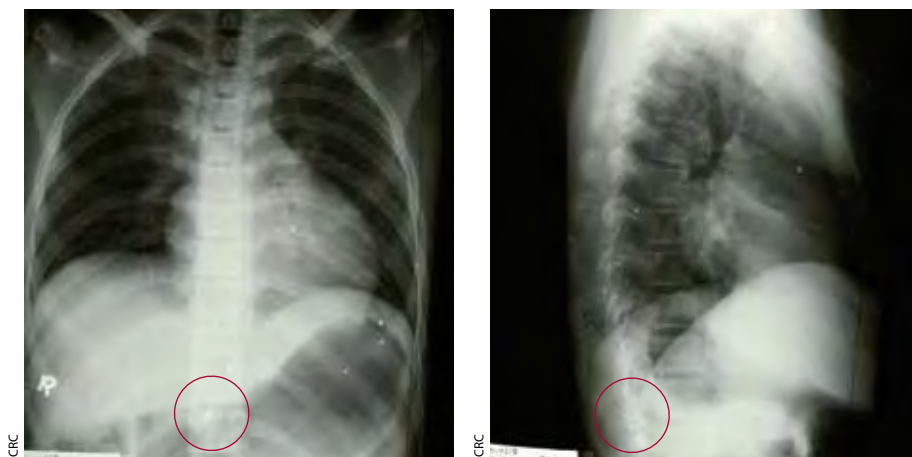
Figures 36.6.1 and 36.6.2

Projectile injury results in definitive but limited spinal cord damage.

It is not only difficult to obtain these views properly, but they can be difficult to interpret. The surgeon must rely on clinical findings primarily; X-rays only help to confirm the diagnosis and define the pathology. Violation of the vertebral canal with impingement on the spinal cord is the key sign.

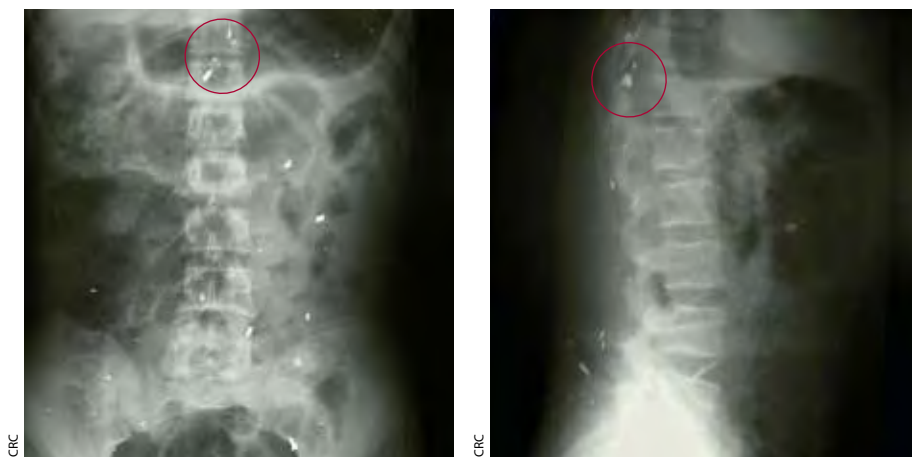
Figures 36.7.1 and 36.7.2

Multiple fragments and a difficult radiological diagnosis. Clinically the patient is paraplegic.



Figures 36.8.1 and 36.8.2

Another difficult radiological diagnosis in a clinically paraplegic patient.



### 36.5 Emergency room management

Paralysed patients are often low on the evacuation priority list and will frequently reach hospital later than the average. They are also low on the hospital priority list during triage of mass casualties. Priority goes to diagnosing any life-threatening injuries implicating the airway, breathing or circulation, which may cause the surgeon to overlook injury to the spinal cord.

**“Do no (further) harm”:** handle the patient carefully. However, with projectile spinal injuries the harm is already done; little can change. The energy of the incident will always be greater than the impact of any handling in the ER.

The damaged vertebral column must be handled with care, but the rigid immobilization used for blunt injury is not necessary for projectile wounds. In wounds of the cervical spine, any compromise of the respiratory muscles calls for an early tracheostomy to decrease the burden of breathing, especially in the absence of mechanical ventilation; a difficult decision if the patient is already tetraplegic.

The circulation may be suffering from a mixture of haemorrhagic and neurogenic shock. The haemorrhage usually predominates and the body's capacity to compensate is seriously compromised. Severe bradycardia and cardiovascular collapse should be treated with atropine. Fluid resuscitation must be closely watched to return blood volume to normal without pushing the patient into pulmonary oedema. A central

venous catheter is most helpful, but not always available. Close monitoring of the urine output, the patient's haemodynamic response, and good clinical judgement are most important in these cases.

Continued hypotension should *not* be attributed to neurogenic shock until all possible sources of bleeding have been excluded. If the diagnosis of neurogenic shock is made and hypotension persists, intravenous noradrenalin (phenylephrine hydrochloride 1%) or titrated dopamine drip should be administered in addition to atropine. The patient is kept in a slight Trendelenburg position.

Continued hypotension should be considered a sign of continuing bleeding until proven otherwise.

Post-injury paralytic ileus calls for the passage of a naso-gastric tube. An in-dwelling urinary catheter should be placed under strict antiseptic precautions. Skin care, to prevent decubitus ulcers, which begin and progress very rapidly, must be commenced in the ER or immediately after emergency surgery. Similarly, measures to prevent deep vein thrombosis should be instituted in those population groups in whom this pathology is a problem.

The use of steroids within the first eight hours of injury is controversial and has not been conclusively proven to improve the neurological outcome. Furthermore there are reports suggesting an increased rate of infection and other complications. They are not used by ICRC surgical teams.

It must be noted that in a mass casualty situation a patient with a spinal cord injury is triaged into Category IV and given supportive treatment only to begin with; and if accompanied by internal haemorrhage or in the case of tetraplegia, even more so.

### 36.5.1 Stabilization of the vertebral column

Projectile wounds rarely cause instability of the vertebral architecture. Nevertheless, while adequate and relevant immobilization procedures should be undertaken when handling the patient, the rigidity of immobilization required after blunt injury, where the possibility of further damage to an incomplete lesion of the cord exists, is not truly relevant or necessary. Especially with cervical injuries, the "over-use" of cervical collars has sometimes been found to mask other injuries and even to be deleterious to the patient because of the risk of impaired breathing (see Selected bibliography of both Volumes 1 and 2).

Adequate care of the vertebral column is called for, but the extensive measures required for blunt injury are not.

Simple measures that are practical and pertinent are called for, nonetheless. Proper handling and moving of the patient require several persons to maintain the neutral position and avoid excessive movement at the fracture site.

The cervical vertebrae are more likely to be unstable than the thoraco-lumbar. If necessary, a simple collar made up of a rolled towel reinforced with a few turns of plaster-of-Paris and overlaid with cotton is quite acceptable and preferable to a rigid collar that can easily cause ulceration if the skin overlying the clavicles is anaesthetized. Skeletal traction using Gardner-Wells tongs or a halo traction device is not called for in tetraplegic patients with a projectile injury.

Most patients who have suffered injury to the vertebral column of the torso should be moved *en bloc* (in one piece) using the log-rolling technique. Foam pillows should be placed under the damaged site. Simple bed rest will result in bony union in 6 – 10 weeks in the rare unstable fracture. For stable injuries, mobilization can begin after two weeks with analgesia; pain is sufficiently reduced after about 6 weeks for the patient to be mobilized without.

## 36.6 Surgical decision-making

Treatment of any life-threatening injuries to the airway, breathing or circulation has priority.

There is much controversy concerning decompressive laminectomy and its indications in the acute phase for the management of penetrating spinal cord injury. Even in specialist centres with well-trained staff the results are contradictory in terms of any improvement of neurological function, even in the case of incomplete spinal lesions. For the general surgeon working with limited resources and with little or no experience of spinal surgery, this pathology calls for conservative treatment: *minimal wound toilet and irrigation of the missile tract*. Emphasis and effort should instead be put on the good organization of nursing care and physiotherapy.

More important than surgery: the organization of nursing care and physiotherapy.

Since the prognosis is so dire in the case of the tetraplegic patient in low-income countries, a realistic approach should probably not involve operative management beyond simple wound toilet to prevent infection for palliative reasons, to allow the patient to live as dignified a life for as long as possible. The rest of this chapter concentrates on the paraplegic patient – naturally any nursing measures apply to the tetraplegic as well.

### 36.6.1 Indications for surgery

Nonetheless, there are several indications for surgery that require less than a full laminectomy, and are within the capacities of the general surgeon.

1. A large wound lying directly over the vertebral column and leaking CSF requires debridement, removal of obvious and accessible missile and bone fragments, irrigation, and closure of the spinal dura, with a fascial graft if necessary. The exposed cord is handled as little as possible. The soft tissues are left open for delayed primary closure.
2. A transperitoneal wound of the spinal cord, especially a projectile passing through the colon, requires debridement of the vertebral column and surrounding muscle, irrigation, and closure of the dura.
3. A persistent CSF fistula should be dissected out and the dura closed in order to avoid ascending infection and meningitis.
4. A foreign body causing infection, usually accompanied by a CSF fistula, should be removed.
5. Injury to the cauda equina is a peripheral nerve lesion, the anatomy is simpler, and relief of pressure from a retained projectile or bone fragment usually improves the neurological outcome.

The sole indication for *urgent laminectomy in capable hands* is progressive neurological deterioration. If the surgeon does feel capable, then an incomplete lesion showing rapid deterioration and clear radiological evidence of spinal cord compression by a foreign body or bone fragment calls for a laminectomy and exploration. Surgery of this sort has its risks and dangers, particularly infectious complications since laminectomy may result in increased CSF leakage. In addition, debridement of bone may result in vertebral instability. It may be more prudent to treat even these injuries conservatively. Much depends on the experience of the surgeon and the quality of post-operative nursing care.

As mentioned, projectile injuries to the vertebral column rarely cause instability of the bony architecture and few patients are candidates for operative stabilization. Conservative measures are more appropriate, especially in the absence of sophisticated equipment for vertebral immobilization.

Much has been made of possible lead poisoning from a retained fragment bathed in CSF. This is not an immediate problem and not an indication for surgery in the acute phase (see Section 14.3).

### 36.6.2 Medical care

Whichever treatment modality is decided, conservative or operative, antibiotics should be administered as per protocol for at least 10 days.<sup>6</sup> This is especially important for patients with abdominal injuries where the projectile has passed through the colon. Vertebral injuries can be quite painful and adequate attention should be paid to analgesia.

## 36.7 Organization of further management

Whether surgery is performed or not, the general management of the spinal cord patient goes through several phases:

- acute stage of spinal shock;
- medium-term hospital care; and
- long-term home care.

The basis for further management is good nursing, physiotherapy, and support of the patient's morale. The quality and sophistication of care to be continued at home upon discharge depend on the availability and dedication of hospital staff and a home-care team, and on the cooperation of the patient, family and friends.

The care of paraplegic patients is "so demanding that ... it is perhaps the ultimate test of the real quality of a hospital, and of the morale and dedication of everyone in it".<sup>7</sup>

The implementation of certain basic measures (prevention of bedsores, bladder care, etc.) must begin immediately on admission during the phase of acute spinal shock. Various adaptations are then implemented in the mid- to longer-term care of the patient depending on the facilities available.

Long-term home care must be planned from the outset. In situations where no specialized centre is available, the patient, family and friends must be shown the measures undertaken in the hospital and be involved in patient care immediately. They must then be provided with sufficient means to continue patient management at home with the assistance of a home-care team to help the patient go through life in the best possible physical and psychological conditions.

A family member or friend should remain with the patient in hospital and be prepared to learn basic nursing and physiotherapy techniques. In many societies, it is quite normal for almost all patients to be so accompanied. For the SCI patient, it is essential.

#### Please note:

The following sections and Annex 36.A deal with the early hospital care of the patient. Annexes 36.B – F included in the DVD attached to Volume 2 of this manual give detailed instructions for the necessary long-term measures based on the experience of ICRC physical rehabilitation home-care teams working in Afghanistan and elsewhere. They are intended as guidelines for medical and non-medical personnel working with limited resources and may be translated into the local language. Annex 36.B is a complete patient assessment checklist that should be filled out on discharge and used during follow-up home visits.

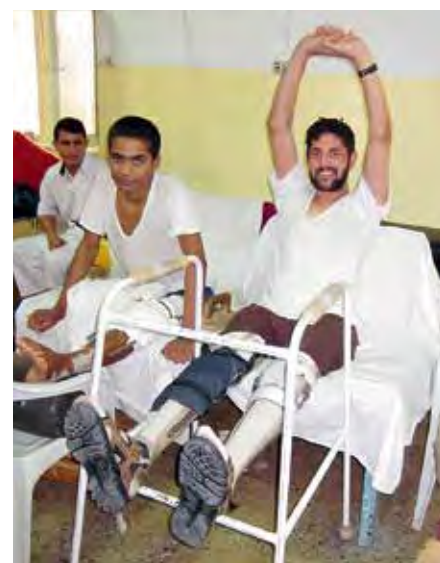

Figure 36.9

Maintaining patient morale is of the utmost importance.

<sup>6</sup> The ICRC protocol calls for penicillin and chloramphenicol in injuries of the central nervous system. For concomitant injuries to the thorax or abdomen, penicillin may be replaced by ampicillin. In addition, abdominal injuries require metronidazole.

<sup>7</sup> King M, ed. *Primary Surgery, Volume Two: Trauma*. Oxford: Oxford University Press; 1987.

## 36.8 Skin care

The most immediate concern in patient care is pressure ischaemia of the skin due to the weight of the body. The anaesthetized skin feels no discomfort and the patient does not move or shift the body to relieve pressure points. The ischaemia develops rapidly into necrosis; the skin breaks down and ulcerates, creating a bedsore.

The prevention of decubitus ulcers begins at admission and entails preparation of a special bed and frequent change of position of the patient. The skin must be kept healthy, clean and dry. In addition, any wound in anaesthetized skin should be bandaged; adhesive tape may be harmful. The preparation of a special SCI bed is described in Annex 36.A.

Care of the skin must begin immediately. The first two weeks after injury are the most critical period and most pressure ulcers begin at this time.

### 36.8.1 Change of position

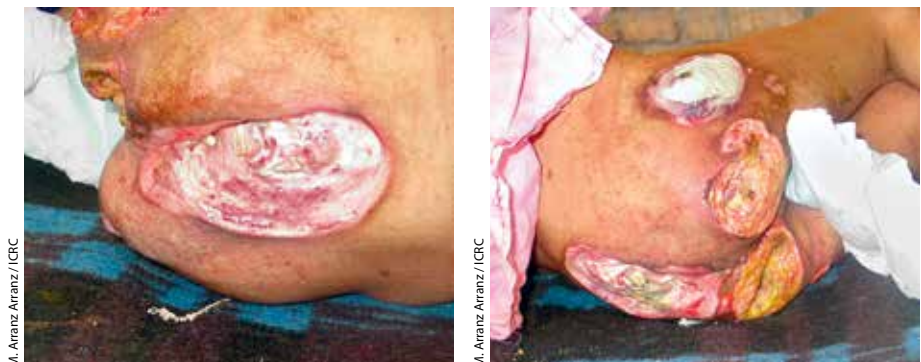The patient's position must be changed *every two hours*. A simple notice to this effect should be placed over the patient's bed, mentioning the new position: front, back, left side, right side. At least two persons are required to change the patient's position properly; with an unstable vertebral column three are necessary. With time, the patient is able to help in this procedure.

Pressure sores can be avoided by vigilant nursing care. The patient must be repositioned every two hours, beginning immediately after admission.

The nursing staff should inspect the pressure areas at each change of position and the surgeon during every ward round. If incipient erythema or blistering starts, the routine for position change must be altered to avoid any pressure whatsoever on the area concerned for several days. The area should be gently massaged to improve local circulation during every change of position. These and further simple nursing measures, organized into a standard protocol, must become a routine that involves the patient and family.

**Figures 36.10.1 and 36.10.2**

Twelve-year old paraplegic patient whose pressure sores were improving upon discharge. She returned to hospital after two weeks owing to lack of family home care.



High-risk parts for pressure sores must be protected. They should not be padded, but rather padding should be placed *around* them through the use of "doughnut dressings" or inflatable tyre tubing of different sizes.

- A soft pillow or piece of foam should be placed between the legs, especially in the lateral position, and under the back.
- The entire body should be washed daily with soap and water and the large muscle masses gently massaged during the bathing. The skin must be thoroughly dried.

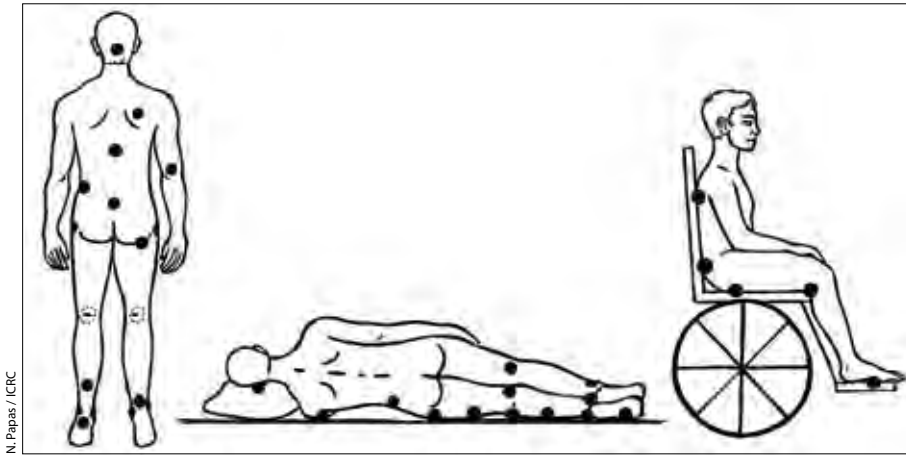
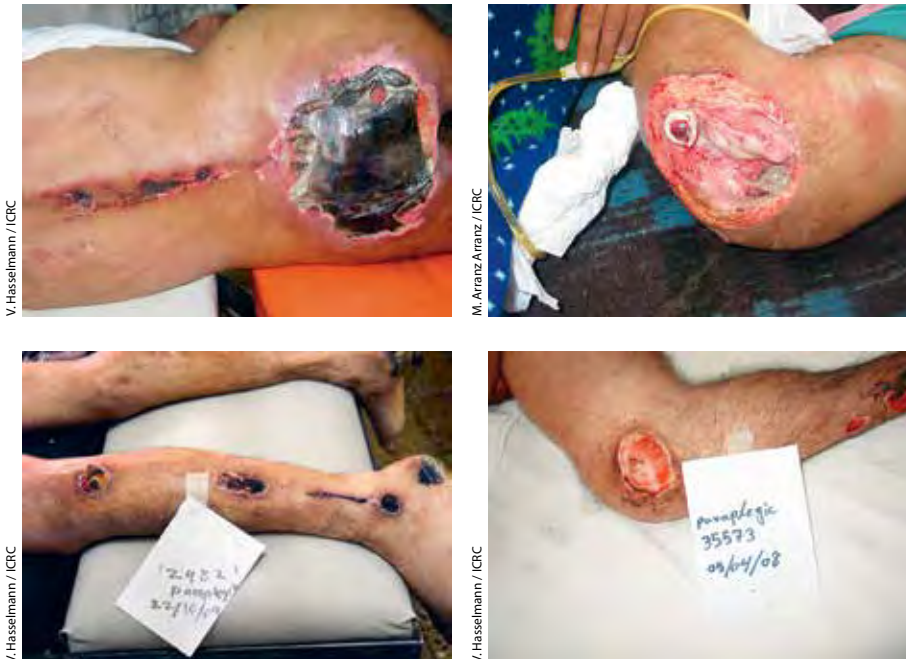

Figure 36.11.1

Areas prone to pressure sores.



Figures 36.11.2 – 36.11.5

Most common areas affected by pressure sores: sacrum and back, trochanter, patella, malleoli and heels.

## 36.9 Care of the bladder

After decubitus ulcers, the greatest problem facing the patient with spinal cord injury is bladder training and the prevention of urinary tract infection: renal failure is a big killer of SCI patients.

Several measures definitely decrease the incidence of infection and deterioration of renal function: fluid input of at least three litres a day; keeping the urine bag below the level of the bladder; and keeping a closed drainage system closed by using a disposable bag and not simply emptying the bag through a valve. The urine should be kept acid when a urinary catheter is in place and this can be achieved using ammonium chloride *per os*. This reduces the chances of UTI and urinary tract stones, whose occurrence is significant in the initial phase of bone demineralization.

Silicone catheters are preferred for all methods, if available.

### 36.9.1 In-dwelling urinary catheter

There are no bladder contractions while the patient is still in a stage of spinal shock. The most common procedure is to employ an in-dwelling urinary catheter during this entire period. The best and least irritant are silicone catheters; if not available then the latex catheter should be changed every 7 days. The catheter is passed using sterile precautions. Secretions at the urethral meatus are gently cleaned with soap and water on a daily basis. Early removal of the catheter is the goal, since its continued presence predisposes to ascending infection.

### 36.9.2 Intermittent catheterization

Alternatively, a better but more labour-intensive approach is to perform regular intermittent catheterization (IC) from the beginning, once resuscitation has ended. The preferred method is sterile intermittent catheterization (SIC) using disposable Nelaton-type catheters. If sufficient quantities are not available, the catheter can be resterilized by boiling before each use, i.e. clean intermittent catheterization (CIC), which has apparently more or less the same complication rate and is better suited to conditions of limited resources.

Intermittent catheterization mimics the natural cycle of bladder filling and emptying. It lessens the incidence of infection but demands a great deal more nursing care and supplies than an in-dwelling catheter.

A catheter is passed every 4 – 6 hours using full sterile technique and the bladder is emptied completely by suprapubic pressure. The catheter is then withdrawn. Later, the catheter is passed every 6 – 8 hours. The amount of urine passed and its nature (clear, cloudy, bloody, bad smell, etc.) should be recorded.

Intermittent catheterization is easier to perform in women owing to the much shorter urethra. ICRC surgical teams consult with their national colleagues for its cultural acceptance.

### 36.9.3 Spastic or flaccid bladder?

Once the spinal shock has worn off, the anatomic level and nature of the neurogenic bladder – spastic or flaccid – determines further patient management. This applies to the medium-term in hospital, as well as to long-term home care. A suitable routine must be instituted and learnt by patient and family for an appropriate length of time in hospital, before patient discharge.

A suprasacral injury results in spontaneous bladder contractions (spastic bladder) and frequently in detrusor-sphincter dyssynergia: failure of sphincter relaxation during detrusor contraction. The patient develops an automatic micturition reflex that comes into play following some sort of stimulus, such as stroking the thigh or penis or suprapubic tapping or pressure.

A lesion of the sacral roots results in a non-contractile flaccid bladder that is compliant and readily fills, even to overflowing. There is no automatic spinal reflex arc, although sometimes a local reflex may develop. The sphincter is not affected to the same extent and there is usually no detrusor-sphincter dyssynergia. Partial lesions complicate these simplistic categories.

### 36.9.4 Testing bladder tone

Three simple tests can be used to establish bladder tone: spastic or flaccid. They do not require any sophisticated apparatus and provide useful information as to the best way to stimulate the bladder to empty.

#### 1. Anal tonus

The external anal sphincter has the same nerve roots (S2 – S4) as the external bladder sphincter. Response to stimulation of the anal sphincter suggests that the bladder sphincter has some function. In a flaccid bladder, there is no sphincter function and the anal and bulbocavernosus reflexes are absent.

#### 2. Ice water test

Introduction of 100 ml of sterile water at 4° C into the bladder with the catheter balloon deflated gives some indication of detrusor muscle function. Expulsion of the catheter by detrusor contraction in response to the cold water indicates a spastic bladder. If the catheter remains inside, the patient has a flaccid bladder.



### 3. Cysto-manometry

This test measures intravesical pressure changes in response to stimuli to determine the most effective way to empty the bladder; for example, suprapubic (Credé manoeuvre) or diaphragmatic pressure (Valsalva manoeuvre). Cysto-manometry is described in Annex 36.A.

### 36.9.5 Medium to long-term bladder management

When the diagnosis of spastic or flaccid bladder has been established, the patient and the family are consulted about the various methods of continuing urine drainage. There is no single “perfect” regime for long-term care and various compromises must be made. Whichever method is most relevant and acceptable to the context of the patient and family depends on their cooperation and understanding of what is required. The agreed method is instituted while the patient is still hospitalized and all concerned are trained in its proper implementation.

#### Flaccid bladder

There are several options.

1. Clean intermittent catheterization, which is the preferred method.
2. Credé or Valsalva manoeuvre in addition to a local micturition reflex, which is however often inadequate to fully empty the bladder.
3. In-dwelling urethral catheter, which is open to infectious complications.
4. Suprapubic catheterization; the most prone to complications.

#### Spastic bladder

In a patient with a spastic bladder some degree of detrusor contractions occurs. They may be spontaneous or provoked by stimulation of the inner thigh or the genitals. The contractions are usually insufficient, however, to fully evacuate the bladder and the patient must perform an added manoeuvre, either Credé or Valsalva. Detrusor-sphincter dyssynergia may require surgical sphincterotomy to remove the resistance to outflow.

There are also several options available.

1. Reflex automatic bladder following some sort of stimulus.
2. In-dwelling urethral catheter.
3. Suprapubic catheter.

Bladder training should be started as soon as possible to maintain bladder capacity and compliance.

Annex 36.A. deals with mid-term hospital bladder care and the different methods of urine evacuation.

Annex 36.C in the DVD attached to Volume 2 of this manual describes the guidelines for long-term bladder care by the patient, family and home-care team.

### 36.9.6 Positioning of a catheter

To help prevent a urethral fistula in men, the penis should be attached to the patient's abdomen by a gauze bandage, thus avoiding internal pressure on the peno-scrotal angle. This is especially important during long-term bladder management. In women, the catheter should be strapped to the thigh so that it lies in a direct line from the bladder outwards.

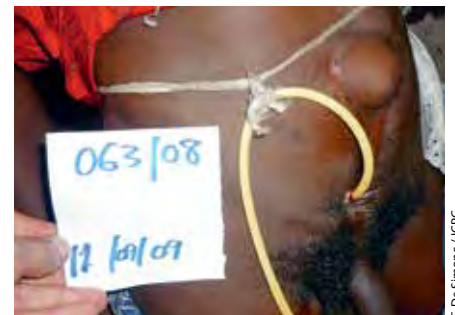
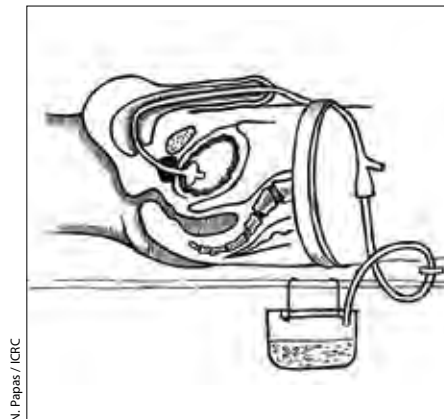
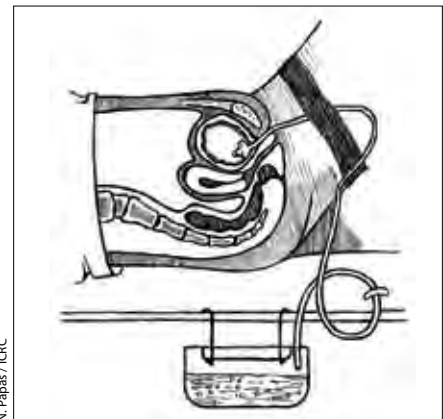
Figure 36.12  
Suprapubic catheter in a male.

F. De Simone / ICRC



**Figure 36.13.1**

Proper positioning of catheter and urine bag and fixation of the penis.



**Figure 36.13.2**

Proper positioning of the urinary catheter in a woman.

### 36.10 Nutrition and care of the bowels

As mentioned, an extreme catabolic state intervenes and the patient loses a disproportionate amount of body mass after spinal injury. Once the patient begins oral feeding, nutrition must be kept up and the patient weighed and the haemoglobin checked regularly. Patient depression is an important instigating and complicating factor that affects the wish to feed oneself adequately, defeating efforts to establish a proper nutritional status.

An H<sub>2</sub>-receptor antagonist and oral anti-acids should be given to prevent stress ulceration and bleeding during the period of spinal shock.

Bowel dysfunction accompanies that of the bladder. The ileus phase may last several days, only sips of fluid are allowed until peristalsis is well established. The patient then proceeds to a fluid, soft, and eventually normal diet. Immobility and insufficient fluids may lead to impaction of hard, dry faeces that may proceed all the way to intestinal obstruction. During the stage of spinal shock, an enema may be required several times a week and possibly manual removal of impacted faeces. A defaecation reflex may then develop.

For the longer term, a high-fluid and adjusted diet with oral stool softeners and bulk-forming agents help attain some regularity. Later, laxatives and glycerine suppositories twice weekly can usually replace enemas. Enemas may still be necessary, however, and along with manual disimpaction and removal of faeces, the technique should be taught to the patient and family.

Annex 36.D in the DVD attached to Volume 2 of this manual gives examples of a proper diet to maintain nutrition and bowel function and describes the long-term home management of bowel care, including colon massage to promote complete emptying.

### 36.11 Physiotherapy and mobilization

Physiotherapy should commence immediately and is an intrinsic part of nursing care. Each change of position of the patient in the acute phase should involve breathing exercises and passive movement of the major joints through the full range of flexion and extension. The objectives are to prevent respiratory complications and flexion contractures. Basic physiotherapy helps prevent atelectasis and hypostatic pneumonia and improves peripheral circulation. It is best not to place pillows under the patient in such a manner as to flex the hips, thus increasing the natural tendency.

Once the SCI patient can sit up in bed, various exercises using a balance beam help strengthen the muscles. Unaffected upper-limb muscles should be “over-developed” by training with weights. This aids in mobilization and respiration; it also prepares the patient for eventual vocational training and rehabilitation.

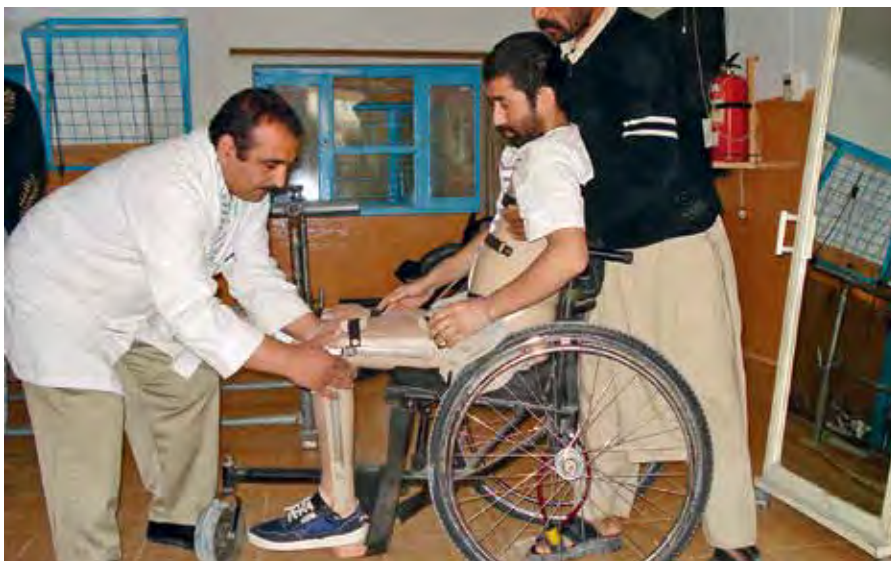

V. Haselmann / ICRC

Figure 36.14

Importance of training: exercising to over-develop the torso and upper limbs is essential.

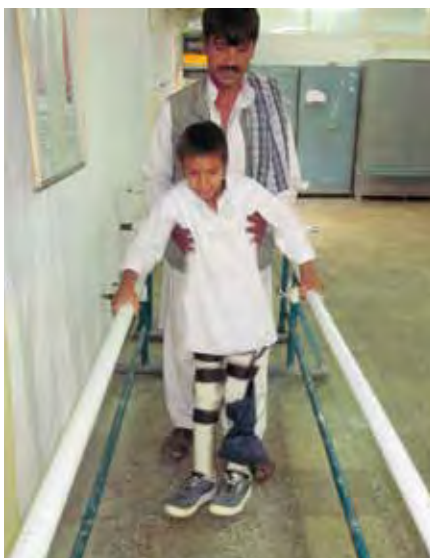Once consolidation of the vertebral fracture and better bladder control have been achieved, the patient may be mobilized to the standing position using posterior plaster-of-Paris splints, followed by gait training with parallel bars, a walking frame, crutches, or simple brace orthoses.



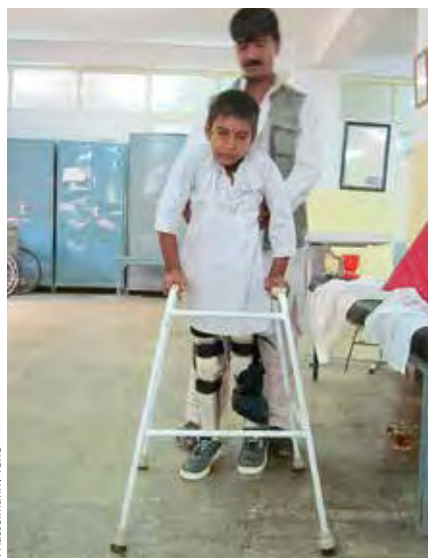ICRC

Figure 36.15

Fitting polypropylene posterior walking splints.



V. Haselmann / ICRC



V. Haselmann / ICRC

Figures 36.16.1 and 36.16.2

Gait training with parallel bars and a walking frame.

Some patients remain confined to a wheelchair. Measures must be implemented here as well to prevent pressure sores. The patient should begin using the wheelchair only one or two hours a day, then gradually increase the time in the chair, and be taught to lift and shift the buttocks every 15 minutes. Foam cushions, or better yet an inflatable inner tube from a tyre, should be placed on the seat. Some sort of urine control (catheter, condom, disposable incontinence or baby pads) is necessary.

Further home physiotherapy and physical rehabilitation is described in Annex 36.F included in the DVD attached to Volume 2 of this manual.

## 36.12 Complications

The SCI patient is prone to multiple complications over time. These include:

- atelectasis and pneumonia;
- decubitus ulcers;
- urinary tract infection and calculi;
- malnourishment and chronic constipation;
- osteoporosis and fractures, and heterotopic ossification: the deposition of bone in joints causing stiffness and fusion;
- autonomic hyperreflexia, which constitutes a medical emergency;
- spasticity of the muscles, often painful;
- deep vein thrombosis where this pathology is common.

Prevention by regular visits of the home-care team and the cooperation of patient and family is best. Even with excellent follow-up complications occur, and the family and team must know when to refer the patient to hospital for further care.

### 36.12.1 Treatment of established decubitus ulcer

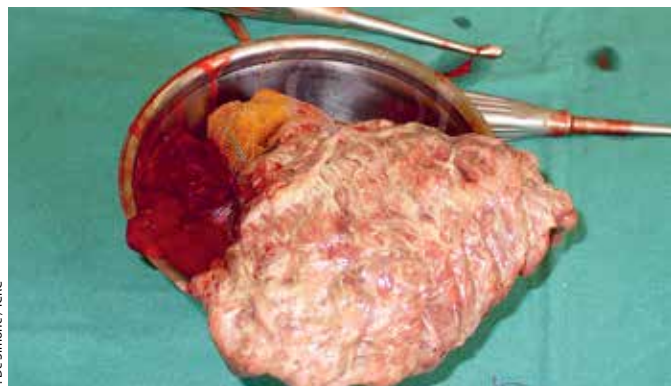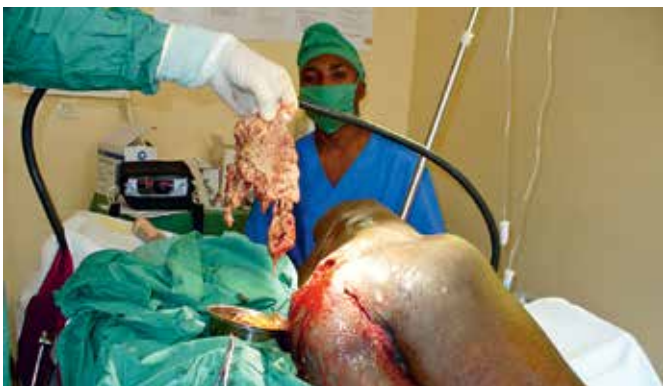An established decubitus ulcer gives off a foul-smelling discharge, with and without necrotic tissue. The discharge seems to be highly irritant to the intact skin surrounding the ulcer.

The treatment of established pressure sores includes:

- avoiding local pressure on the sore;
- adapting the patient's position in bed accordingly;
- no sheepskin contact because of the danger of infection;
- use of a mattress with suitably positioned holes or a "doughnut dressing" or inflatable inner tyre tubing to relieve pressure on the sores;
- care of the ulcer itself.

The patient's morale is essential and a stinking sore does nothing to help.

The surgeon should perform the first wound debridement himself, as necrotic extension in the subcutaneous tissues may underlie intact skin and exploration may be necessary. No anaesthesia is needed and serial debridements are usually required. Subsequently, minor redebridements can be done by a trained nurse.



Figures 36.17.1 and 36.17.2

Debridement of a decubitus ulcer: all necrotic tissue must be removed.

For clean wounds, a daily dressing is sufficient. Infected, deep wounds require regular change of dressings, up to five times a day, during every other change of patient position. The ulcer should first be thoroughly washed with copious amounts of normal saline or potable water.

Many dressings are available to clean the established ulcer and promote healing, either commercial or based on clinical experience in resource-poor settings. ICRC surgical teams and others have used a wide variety of local agents. An inexpensive, universally available and efficient dressing to reduce bacterial growth and foul smell is granulated sugar.<sup>8</sup> Honey and pulped papaya dressings have also been found useful, as has maggot therapy.

Another method is to cut out pieces of foam taken from a mattress in the exact shape of the ulcer, wrap in brown sterilization paper and pass through the autoclave. The sterile foam piece is then placed in the ulcer where it absorbs the irritant discharge so that the ulcer bed no longer bathes in it. The foam dressing is changed several times a day depending on the amount of discharge.

Antibiotics are *not* needed, unless there is spreading or systemic infection. The patient's nutrition must be well maintained and any anaemia treated adequately.

Local surgical treatment of bedsores is the same as for any other wound: excision of non-viable tissue.

#### Further surgery

Large pressure ulcers may require appropriate rotational flaps for closure. No flap should be fashioned before the wound area is clean; this may include removing any necrotic bone. For pressure sores over the ischiatic prominences, typical of the SCI patient spending long hours in the sitting position, a useful tip to prevent recurrence is to surgically flatten the bony prominences.

The atrophy of the gluteal muscles usually provides a large amount of loose skin that can be mobilized as flaps. Superficial defects can be covered by full-thickness cutaneous flaps; deeper areas of defect require musculo-cutaneous flaps to obliterate dead space. It should be emphasized that failure of a musculo-cutaneous flap to close a big ulcer often means that there is no second chance since there is not enough skin remaining. Consequently, strict aseptic procedure and good post-operative care is essential. Split-skin grafts should not be used as they break down with the slightest pressure afterwards.

Musculo-cutaneous flaps are highly effective, but surgical experience and good nursing care are essential for good results.

Management of incipient pressure sores by the home-care team is described in Annex 36.E in the DVD attached to Volume 2 of this manual. It is important that the team diagnose the onset of pressure sores early and refer the patient to hospital in good time.

### 36.12.2 Urinary tract infection

In industrialized societies the causes of mortality in patients with spinal cord injury have begun to mirror those of the general population thanks to a steady improvement in nursing care and physiotherapy. In middle to low-income countries, septicaemia and renal failure remain the main causes of death. Kidney failure usually results from a combination of ascending urinary tract infection (UTI) and pressure atrophy of the kidneys due to increased renal pelvis pressure from urinary reflux. Septicaemia is

<sup>8</sup> Chiwenga S, Dowlen H, Mannion S. Audit of the use of sugar dressings for the control of wound odour at Lilongwe Central Hospital, Malawi. *Trop Doctor* 2009; **39**: 20 – 22.

usually caused by invasive infection from UTI, pressure sores, or hypostatic pneumonia. Consequently, it is important to prevent urinary tract infection and attain some method of long-term bladder regulation. Annex 36.A describes the management of UTI in the SCI patient and the incidence of UTI with respect to the method of bladder training during long-term home management.

### 36.12.3 Autonomic dysreflexia/hyperreflexia

Autonomic dysreflexia is a complication that occurs in patients with spinal cord injury *above T6*; occasionally, patients with injury from T6 to T10 may be susceptible. It is generally brought on by what would have been a noxious stimulus before the injury and is an abnormal autonomic nervous system response.

The irritating stimulus occurs below the level of the spinal cord lesion. A paradoxical disconnection takes place between peripheral and central mechanisms resulting in a loss of the regulation of blood pressure. Patients with cervical or high-thoracic spinal cord injury have an arterial blood pressure that is 15 to 20 mm Hg lower than normal and, therefore, an increase in systolic pressure of greater than 20 – 30 mm Hg is considered a dysreflexic event. The condition may be asymptomatic or result in mild discomfort and headache, or the prolonged bradycardia and severe hypertension may cause retinal haemorrhage, seizures or a cardiovascular accident and death.

Symptoms may include severe throbbing headache, restlessness and seeing spots before the eyes, sweating, pilo-erection (“goose pimples”) and flushing of the skin *above* the level of the spinal cord lesion.

It is important for hospital staff and the patient to be able to recognize autonomic dysreflexia as it can be a life-threatening condition, especially if it occurs at home and takes patient and family by surprise.

A number of conditions can provoke autonomic dysreflexia:

- full or distended bladder, caused by a blocked catheter or insufficient bladder emptying: the commonest cause;
- severe constipation, the second most common cause; but even a digital rectal examination can provoke the reaction in some patients;
- urinary tract infection or bladder stones;
- skin irritation and pressure sores;
- traumatic pain and burns;
- extreme hot and cold temperature;
- tight clothing;
- pregnancy;
- appendicitis.

The patient should be sat up with the head elevated, any clothing loosened and the cause sought out. If a urinary catheter is in place, is it functioning or blocked? If no catheter is present, one should be passed and the bladder emptied slowly. The colon should be palpated for a faecal mass, perhaps calling for manual disimpaction. All gestures should be performed gently since overstimulation may aggravate the condition. Treatment is symptomatic: atropine and anti-hypertensives or nitroglycerine.

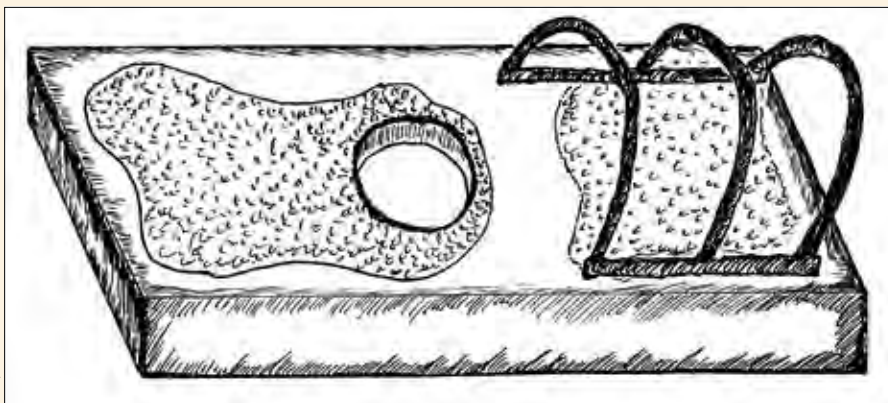
By the time of discharge from hospital the patient should be made fully aware of the signs and symptoms and be able to direct the family to find and remove the cause. The patient and family should be instructed in the difference between autonomic dysreflexia and simple hypertension. Guidelines should be provided in the form of a leaflet to help them make the distinction.

## ANNEX 36. A Hospital nursing care

### 36.A.a Preparation of the bed

Simple measures can be taken to prepare a proper bed in-hospital and, later, at home. An air mattress, such as the kind used at the beach, is best, although seldom available. Otherwise, a door can be placed on a hospital bed and covered with a thick foam mattress protected by some sort of waterproof covering. A sheepskin or pieces of cotton wool can then be placed where the buttocks and heels usually lie when the patient is lying on his back. The mattress should have a 15 – 20 cm deep hole cut into it so that the penis and testicles are free from pressure when the male patient is in the prone position to prevent epididymitis. It also facilitates defecation.

The bottom sheet must be made tight and free of creases. Any wet sheets or clothing must be changed immediately. A protective metal arch, similar to the frame for burn patients, should be constructed over the legs and feet to prevent the weight of bedclothes adding pressure to the skin.

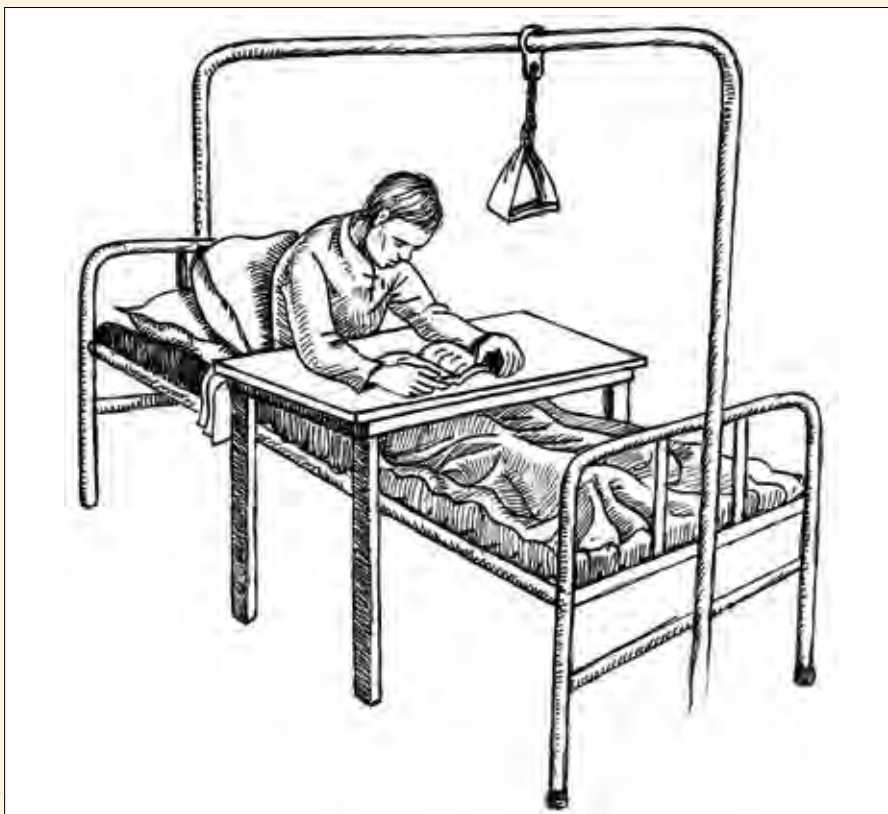

N. Papas / ICRC

**Figure 36.A.1**

Bedding and frame for the prevention of pressure sores.

Once the SCI patient's spine is stable enough to sit up, a special bed with a "Balkan beam" and handle can be constructed from locally available materials. This will allow the patient to change position frequently and independently.



N. Papas / ICRC

**Figure 36.A.2**

Bed organized to make the SCI patient's life as comfortable as possible.

### 36.A.b Testing bladder tone

Two of three simple clinical tests for ascertaining whether an SCI patient has a spastic or flaccid bladder are described in Section 36.9. The mid- to long-term management of the patient depends on this diagnosis.

#### 1. Anal tonus

On PR, a contraction of the anal sphincter indicates some degree of bladder sphincter function and most probably a spastic bladder. In a flaccid bladder, the sphincter is patulous and without function; the anal and bulbocavernosus reflexes are absent.

#### 2. Ice water test

One hundred ml of sterile water at 4° C is introduced into the bladder and the catheter is left with the balloon deflated. In a spastic bladder, the detrusor contracts and expels the catheter; with a flaccid bladder no expulsion takes place.

#### 3. Cysto-manometry

This is a test to measure intravesical pressure changes in response to increased filling of the bladder. The response helps differentiate a spastic from a flaccid bladder and then used to determine the most effective way to empty the bladder; for example, suprapubic (Credé manoeuvre) or diaphragmatic pressure (Valsalva manoeuvre).

**Equipment for cysto-manometry:**

- measuring tape;
- infusion tube 3 m in length;
- sterile water;
- plastic "Y" piece;
- clamp or haemostat;
- urinary balloon catheter.

Figure 36.A.3

Procedure for cysto-manometry:

1. The bladder is slowly filled over 5 minutes with 250 ml of sterile water at 37°C, allowing time for the detrusor muscle to relax.
2. The infusion tube is then clamped.
3. The pressure inside the bladder is read on the measuring tape as centimetres of water and recorded.

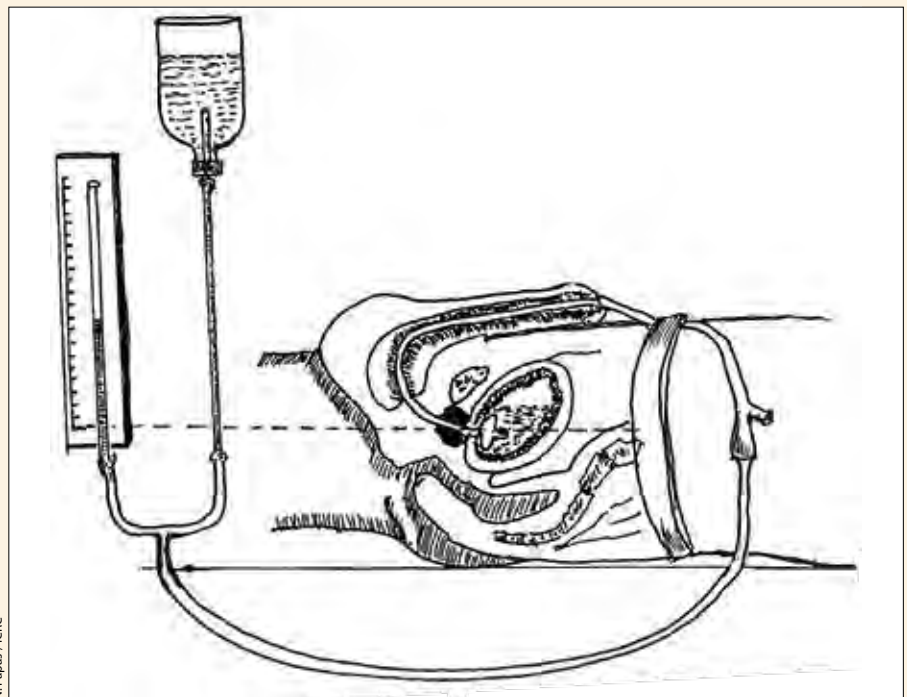
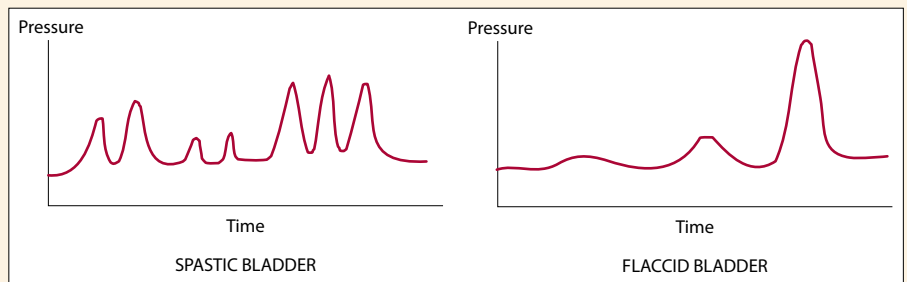


Figure 36.A.4

Examples of recordings for a spastic and a flaccid bladder.





### 36.A.c Medium to long-term bladder management

The procedures differ for a flaccid or spastic bladder and the patient and family must be instructed in the advantages and disadvantages of each so that the most appropriate method is chosen to be continued at home.

**For the flaccid bladder there are several options.**

1. With clean intermittent catheterization a Nelaton-type catheter is passed every 6 – 8 hours and the bladder emptied as much as possible by suprapubic pressure until withdrawal of the catheter.

After use, the catheter is washed with soap and water and the lumen rinsed with force from the water tap or by a syringe. The catheter is then either air-dried and kept in a paper bag or put into a savlon solution (chlorhexidine 1.5% and cetrimide 15%) in a concentration of 1:100 that is changed twice a week.

PVC or latex catheters should be changed every two weeks. Silicone catheters can last for several years, but should be boiled every two weeks. Silicone catheters cost more individually, but the total cost over time is much less and they are preferred, if available.

2. Some patients with a flaccid bladder develop a sufficiently effective local reflex against little or no sphincteric resistance. Micturition usually requires assistance through the use of the Credé (suprapubic pressure) or Valsalva manoeuvre (straining, as with defecation, with the epiglottis closed) in order to increase the intra-abdominal pressure; or a stimulus such as tapping the pubic area or stroking the inside of the thigh. A urinary condom can be used in men for collection of the urine. Such condom devices are not available for women; incontinence pads or baby diapers may be used instead. The patient must be checked regularly by catheterization for any residual urine.
3. In-dwelling urethral and suprapubic catheters result in a high incidence of urinary tract infection, but their use requires the least amount of patient and family cooperation.

Latex Foley catheters should be changed on a weekly basis; silicone Foley catheters can remain for 6 weeks.

**For the spastic bladder several options exist as well.**

1. Reflex automatic bladder following some sort of stimulus. A urinary condom is used in men for collecting the urine. If ready-made urinary condoms are not available, an ordinary condom can be adapted to serve the purpose; for women, incontinence pads or baby diapers may be used.

The patient should be taught suprapubic tapping while in the sitting position as soon as possible.

- The suprapubic area is tapped with the tips of the fingers until urine flows, but not longer than 10 minutes.
- More or less 70 taps, not too strong and not too weak, are usually necessary.
- The tapping is stopped when urine flows.
- When urine flow stops the tapping is recommenced.
- The procedure is repeated until a good amount of urine has been voided, usually 400 – 500 ml, followed by the Credé or Valsalva manoeuvre to fully evacuate the bladder.
- The procedure is followed by catheterization to ascertain the amount of residual urine.
- Bladder voiding by tapping stimulation is repeated every 4 hours.

Catheterization of a reflex bladder after every voiding should continue until residual urine is less than 75 ml.

Bladder training can also be instituted for a spastic bladder but *only* if the patient is taking *anticholinergic drugs*. Otherwise the bladder will react with a permanent contraction resulting in increased intravesical pressure, vesico-ureteric reflux and subsequent damage to the upper urinary tract.

## 2. In-dwelling urethral or suprapubic catheter.

### Reflex micturition and residual urine

If a reflex micturition technique is employed the amount of residual urine should be checked by *home-care team follow-up* every two weeks in both spastic and flaccid bladders. The bladder is emptied by sterile catheterization and the patient drinks 4 glasses of water. The patient then urinates by whatever method is used and a catheter is passed again to measure the residual urine. The amount of residual urine should be less than 75 ml; if greater, the test is repeated in 2 weeks. If the amount of residual urine is consistently more than 75 ml then a different procedure for bladder voiding should be introduced.

With reflex micturition, a urinary condom in men and baby diapers or incontinence pads in women should be employed.

### 36.A.d Urinary tract infection

Several important factors increase the risk of infection and/or overpressure in a neurogenic bladder:

- incomplete emptying of the bladder with residual urine;
- increased intravesical pressure from overfilling of the bladder due to a flaccid detrusor muscle followed by vesico-ureteric reflux of urine;
- increased intravesical pressure due to detrusor-external sphincter dyssynergia, also causing vesico-ureteric backflow; and
- any use of a catheter.

### Signs and symptoms

Repeated urinary tract infection is very common in SCI patients. The classic symptoms of urinary tract infection (UTI), however, are often absent in a neurogenic bladder. Asymptomatic bacteriuria does not require antibiotics, which should only be used in the presence of frank symptoms. It is all too easy to misuse antibiotics in the attempt to prevent infection and thus cause the development of resistant organisms.

The most common symptoms of local urinary tract infection are:<sup>9</sup>

- pyuria: lack of leucocytes in the urine usually excludes UTI;
- lower back pain or suprapubic discomfort (“tense abdomen”);
- urinary incontinence;
- increased spasticity;
- autonomic hyperreflexia;
- lethargy, malaise or sense of uneasiness and nausea, or headache.

Fever is usually absent in localized UTI. Its presence is associated with ascending infection, which may result in pyelonephritis.

The patient is often the first to notice the cloudy urine and increased odour of pyuria.

<sup>9</sup> Adapted from the NIDRR Consensus Statement 1992 (National Institute on Disability and Rehabilitation Research, US Department of Education, Office of Special Education and Rehabilitative Services).

## Treatment

The occurrence of UTI may be treated on an out-patient or in-patient basis, depending on the severity of the infection, the compliance and cooperation of patient and family, and the social context.

In minor infections:

- the urinary catheter is changed and a specimen sent for bacteriological culture and sensitivity if available;
- the quantity of oral fluids is increased to a minimum of 3 – 4 litres per day;
- the pH of the urine is changed by appropriate oral medication (ammonium chloride for alkaline urine, sodium bicarbonate for acidic urine) after a fresh midstream urine analysis.

Antibiotics are added if these measures do not control the UTI or in case of heavy infection. The choice of antibiotic is geography-specific and depends on the availability of culture and sensitivity. It is best to start with a simple regime:

- co-trimoxazole – 2 tabs twice daily for 10 days, or
- nitrofurantoin – once daily 100 mg in the evening for 10 days.

If there is no response, whatever antibiotic gives the best results in the area should be tried; this may include a fluoroquinolone (ciprofloxacin), amoxicillin-clavulanate, or chloramphenicol.

In case of fever and ascending infection, ciprofloxacin tabs (500 mg BID for up to 2 – 3 weeks or 5 days after disappearance of fever) or intravenous ampicillin – gentamycin may be necessary.

Further long-term complications include urinary calculi, hydronephrosis, renal insufficiency and uraemia and, in long-standing cases, squamous metaplasia of the urinary transitional cell epithelium and cancerous transformation.

### 36.A.e Epididymitis

Epididymitis is a common complication resulting mainly from a prolonged ventral position of the male patient and/or delayed removal of the urinary catheter. Prevention is best accomplished by fashioning a mattress so that the penis and testicles are free from pressure when the patient is in the prone position. Treatment follows the same regime as ascending infection.

### 36.A.f Incidence of urinary tract infection

Whatever method of bladder training and passage of urine is used, the great danger to the patient is UTI and pressure atrophy of the kidneys. Much effort has been expended to determine the “safest” methods. One study reviews the incidence of urinary tract infection according to the method of bladder voiding (Table 36.A.1).

Method	Incidence of UTI
In-dwelling catheter	10
Clean intermittent catheterization	1.5
Male condoms	1.3
Suprapubic stimulation in females	1.25
Normal voiding	0.2

Table 36.A.1 Incidence of UTI according to method of bladder voiding: number of UTI episodes per person per year.<sup>10</sup>

<sup>10</sup> Adapted from García Leoni ME, Esclarín De Ruz A. Management of urinary tract infection in patients with spinal cord injuries. *Clin Microbiol Infect* 2003; **9**: 780 – 785.

## ICRC EXPERIENCE

### Patients with spinal cord injury managed by the ICRC in Afghanistan

The ICRC has been active in Afghanistan for over 30 years and one of its most important activities there is physical rehabilitation services for amputees and paraplegics/tetraplegics. More than 5,800 spinal cord injury patients have been recorded by the ICRC, with about 550 new cases per year in recent years. About 1,500 patients are followed regularly by ICRC teams and another 3,500 estimated to be present in off-limit areas and therefore not included in the ICRC home-care programme and only occasionally assisted by the ICRC.

Based on clinical examination, about 70% of patients are trained to empty the bladder with the Credé, Valsalva, or tapping manoeuvres, plus or minus a condom; the remaining 30% have in-dwelling catheters. Approximately 25,000 Foley catheters are required every year for the home-care programme.

For patients with a spastic bladder, the Credé, Valsalva or pubic tapping manoeuvres, plus/minus a condom, are used. Flaccid bladder patients have an in-dwelling catheter. UTI prevention consists of abundant fluid intake, change of catheter every week and follow-up monitoring by the home-care system. For treatment of UTI, home-care teams call upon the Afghan doctor who is part of the team.

### In-dwelling catheterization costs

Latex balloon catheters are the most widely available and used, but, as latex is porous, they cannot be left in place for prolonged periods. The ICRC provides silicone-coated latex catheters, changed on a weekly basis.

Silicone Foley catheters have a smoother surface and are much less irritant to the urethral mucosa; they can stay in place longer, 6 weeks or more. On the negative side, the balloon tends to deflate with time (possible dislocation of the catheter) and to develop a cuff (more difficult removal). Their cost per piece is about five times that of latex catheters but, assuming a catheter exchange every 6 weeks, the cost per year is less than for latex.

### Clean intermittent catheterization costs

The re-utilization of Nelaton-silicone catheters for CIC in selected patients can be very inexpensive and quite affordable in low-income countries. A study of 28 spinal cord injury patients in Thailand analysed the outcome of CIC with reused silicone catheters.<sup>11</sup>

The results appear quite promising for situations where disposable catheters are not affordable and the only alternative is the in-dwelling catheter with its various complications. These patients used the same Nelaton-silicone catheter for an average time of 3 years, range 1 – 7 years. Correct cleaning of the catheter and appropriate catheter passage are important to reduce the risk of UTI.

The difference in cost for re-using the same silicone catheter for a period of two years compared to the cost of disposable catheters over the same period was considerable: US\$ 18 versus US\$ 4,722.

11 Kovindha A, Na Chiang Mai W, Madersbacher H. Reused silicone catheter for clean intermittent catheterization (CIC): is it safe for spinal cord-injured (SCI) men? *Spinal Cord* 2004; **42**: 638 – 642.





**Part F**

**HOSPITAL  
MANAGEMENT  
AND PATIENT CARE**

F.	HOSPITAL MANAGEMENT AND PATIENT CARE	
F.1	Hospital management	573
F.2	Post-operative care	574
F.3	Critical care in low-income countries	578
F.4	Improvisation	580
F.5	Final remarks	582
ANNEX F. 1	Ballistics	583
ANNEX F. 2	Red Cross Wound Score and classification system	586
ANNEX F. 3	ICRC antibiotic protocol	588



## Basic principles

Managing a hospital is always a challenge – even more so where resources are limited.

The responsibilities of the surgeon go far beyond the operating theatre.

Post-operative patient care is teamwork .

Care for the critically ill does not require sophisticated technology.

Improvisation is an art to be cultivated.

This Part discusses the importance of good hospital management and post-operative patient care and the responsibility of the surgeon for providing that care. It is based on clinical practice in ICRC hospitals. It also includes annexes on topics that have been dealt with repeatedly in this manual: a summary of wound ballistics; the Red Cross Wound Score; and the ICRC antibiotic protocol.

## F.1 Hospital management

In many resource-poor settings the surgeon is often also the director of the local hospital. Although not optimal, all too frequently this cannot be avoided. Section 6.2.4 explains briefly the major elements in the functioning of a hospital and Annex 6.A is a checklist for the initial assessment of a surgical hospital treating war wounded patients.

“Perhaps the most important ‘support service’ ... for the hospital as a whole, is a functioning administrative structure with systems for good governance, quality improvement, financial management, resource management, general and biomedical technology maintenance, consistent staff education, and information technology.”

E.D. Riviello et al.<sup>1</sup>

A great deal of ICRC support to hospitals in countries wracked by armed conflict goes towards maintaining hospital infrastructure and improving the functioning of the administration. Many practical details are to be found in the ICRC book *Hospitals for War-Wounded: A Practical Guide for Setting Up and Running a Surgical Hospital in an Area of Armed Conflict*.<sup>2</sup>

Following upon its field experience, the ICRC has developed an organigram for the running of a hospital working with limited resources in a situation of armed conflict. A team comprising a hospital project manager (director), the head nurse (matron), the hospital administrator and the senior surgeon covers the main aspects of a functioning surgical hospital. This team works in a collegial fashion with as little vertical hierarchy as possible.

The project manager is in charge of the general coordination of hospital services and contacts with outside authorities; in ICRC practice, most project managers are former head nurses. The head nurse is responsible for overall patient management, nursing, and the paraclinical departments. The administrator deals with the finances and budget, human resources management, infrastructure and medical equipment maintenance, pharmacy, warehousing and supplies, and auxiliary services (kitchen, laundry, tailor workshop). The senior surgeon is the chief medical officer and is responsible for clinical care and making certain that team surgeons follow ICRC treatment protocols. The priorities for hospital management remain in the hands of clinicians.

1 Riviello ED, Letchford S, Achieng L, Newton MW. Critical care in resource-poor settings: lessons learned and future directions. *Crit Care Med* 2011; **39**: 860 – 867.

2 Hayward-Karlsson J, Jeffery S, Kerr A, Schmidt H. Geneva: ICRC; 1998.

Every hospital in the world, no matter how well run, has bottlenecks in its systems for the circulation of patients and distribution of supplies. The cleaning staff, porters and maintenance personnel usually understand the “bowels” of the hospital best, but their knowledge is frequently underestimated or entirely overlooked. Another lesson drawn from ICRC field experience is that a good hospital management team knows how to exploit this knowledge to overcome shortcomings and blockages.

## F.2 Post-operative care

Surgery is a multidisciplinary task and post-operative care is teamwork. Nursing, physiotherapy, radiology and laboratory work, not to mention patient nutrition and hygiene, all contribute towards determining the outcome of patient treatment. The comatose or spinal trauma patient and the amputee best exemplify the absolute necessity of this teamwork.

In many countries with limited resources the level of education of doctors far exceeds that of nurses, as does their social status and prestige. Indeed, in some societies nursing work is looked down upon, especially for women. Regardless of local beliefs, the surgeon is best placed to appreciate the importance of good post-operative nursing care. The level of sophistication of any surgery undertaken is more a function of the standard of nursing care than of the surgeon’s competency and expertise.

In some hospitals where there is a crying shortage of nursing staff the surgeon must assume a major role in patient post-operative care. If necessary, the surgeon must make the patient get up and walk with his assistance and simultaneously train the hospital staff by demonstration. Unquestionably, the surgeon’s knowledge of anatomy, physiology and pathology carries the added responsibility of sharing some of that knowledge with the nursing staff and participating in the on-the-job training of newly-recruited nurses.

**Figure F.1**

An accompanying family member assists in basic patient care: a common occurrence in many societies.



In many societies it is customary for a family member to accompany a patient during hospitalization and to participate in the essential daily tasks of patient care. Their responsibilities often include emptying the bedpan, patient hygiene, cooking for the patient, and psychological support. However, the proper execution of these tasks demands that there be at least some nursing supervision.

### Post-operative rounds

The surgeon must understand that the treatment of the patient does not end at the door of the operating theatre. The post-operative round is as much an inherent part of surgical practice as the pre-operative examination and the work in the OT. Rounds should be undertaken with the anaesthetist, ward nurses *and* the physiotherapist. Checking the dressings, tubing and drains and their connections, and the stability of fracture fixation are not tasks for nurses alone.

Post-operative rounds should involve a systematic review of the patient's condition, and a complete re-examination of the patient and re-evaluation of all diagnostic investigations. Detected lesions should be re-assessed and the possibility of missed injuries entertained. Missed injuries are commonly related to increased trauma severity; involvement of multiple systems; excessive workload; and transfer and/or referral of the patient. The delay in diagnosis often leads to re-operation.

Further treatment should be discussed with the nursing staff. Antibiotics and other medications should be ordered according to standard protocols. Should these be changed for a specific patient, the change must be explained and justified.

Written notes for other medications, dressings, feeding, physiotherapy and the management of drains must be clear and concise. The condition of the patient and status of the wounds should be briefly but clearly written at every ward round.

### Case studies and staff continuing education

It is very helpful that the surgical team meet to discuss the care of specific patients, preferably on a regular basis. Such sessions can be educational for everybody involved and help establish hospital treatment protocols; they frequently have a significant impact on the outcome of patient management. As mentioned, the surgeon's extra knowledge of anatomy, physiology and pathology carries an added responsibility of providing instruction for others. Most surgeons are not trained in pedagogical methods, however, and the "art" of teaching must be cultivated in the same way as the "art" of surgery is.

### Hygiene

Patient hygiene is mentioned several times in this manual. The ICRC practice, apart from a general showering of all patients on admission, is to scrub the affected limb or torso with copious amounts of soap and water and a brush under anaesthesia and just prior to operation, with the obvious exception of patients suffering from immediate life-threatening injuries. This scrubbing may have to be repeated at DPC.

Patient hygiene includes post-operative body cleanliness and a family member is often involved in patient bathing. Care for fluid and solid excrements are of particular concern in spinal trauma patients and, along with oral hygiene, in the comatose patient.

General hospital cleanliness, often a challenge in settings with limited resources, assists in maintaining patient hygiene and comfort and preventing nosocomial and cross infections.

### Nutrition protocols<sup>3</sup>

Malnutrition in low-income countries is widespread and is exacerbated by situations of armed conflict. Malnourished patients and those who lose weight post-operatively show poor healing of wounds and intestinal anastomoses and greater susceptibility to infection. ICRC supported hospitals have a routine policy that on admission all patients are given iron and vitamin supplements, in addition to an antihelminthic where necessary. Families are often involved in patient feeding and proper supervision of foods provided by them and their preparation is the rule.

Most surgical patients, however, easily withstand a short period of starvation and few need nutritional support. Patient requirements in protein and energy vary according to the underlying condition.

Conditions that require a greater need for nutritional support comprise:

- severe trauma;
- severe sepsis;
- fasting more than 7 days post surgery, especially in the comatose patient;
- post-operative weight loss greater than 15%;
- serum albumin level < 30 g/l.

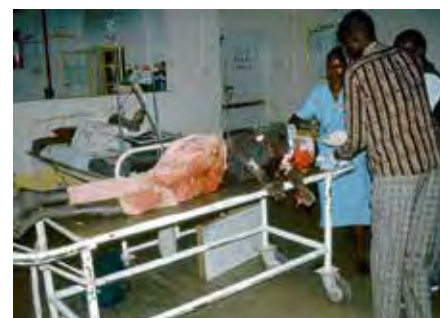

Figure F.2

Battlefield dirt requires scrubbing.

D. Cooke / ICRC

<sup>3</sup> This section is derived from the report of the Second ICRC Master Surgeons Workshop held in Geneva, December 2010.

Specific injuries that require extra nutritional support include:

- severe burns;
- upper gastro-intestinal injuries;
- pancreatic injury;
- high-output bowel fistula;
- chronically discharging sinus or chronic wound;
- severe maxillo-facial injuries;
- tracheostomy that makes swallowing difficult.

Nutrition can be provided enterally or parenterally: the important point is the indications for each method. Discussion of parenteral feeding or feeding ostomies should be part of a hospital "nutrition protocol".

Enteral nutrition should always be used if the gastro-intestinal tract is functioning. It should be begun as soon as possible.

- *Per os*: including encouragement of the patient to take food.
- Standard naso-gastric tube: good for short-term use only.
- Fine-bore double-lumen naso-enteric tube reaching the duodenum-jejunum (Levin tube) with small external diameter (9 CH) and preferably made of silicone: also good for short-term use only.
- Feeding gastrostomy: a Foley catheter is preferable.
- Feeding jejunostomy: a Foley catheter is preferable.

The administration of non-oral enteral feeding can be implemented by gravity or by a volumetric pump. Feeds are started with 25 ml/h as soon as possible and provided in a cyclical fashion: 16 hours feeding with 8 hours rest period. Commercial products are available which provide all essential nutrients. Annex 15.A: *Nutrition in major burns: calculating nutritional requirements* offers a simple protocol for preparing tube-feeding with locally available products.

*Complications* exist with these techniques but most can be dealt with by simple means:

- warm feeding solution;
- metoclopramide, to decrease nausea and increase peristalsis and absorption;
- acid suppression;
- imodium and dilution of the feeding solution for diarrhoea;
- awareness of the possibility of constipation in the immobile patient;
- attention to the fact that fine feeding tubes may be blocked by crushed tablets;
- patients propped up 30° or more while feeding and kept up for 30 minutes afterwards to prevent aspiration.

Peripheral parenteral nutrition can be provided through a peripheral venous line if the patient needs nutritional support for just a few days. A commercially available three-bag system creates the fewest logistic problems, but availability and cost may make this inappropriate.

Total parenteral nutrition through a central venous line is usually reserved for patients with a severe pathology, but requires intense monitoring and has a high rate of complications. It is not suitable in an ICRC or resource-poor setting.

### **Deep vein thrombosis**

Deep vein thrombosis (DVT) and pulmonary embolism (PE) are almost unheard of in ICRC practice of surgery for the war-wounded. They are a rare occurrence in rural societies where people maintain a traditional diet rich in natural fibres and a physically active life-style and do not present other risk factors typical of urban industrialized societies.

Studies concerning the incidence and risk factors for deep vein thrombosis and pulmonary embolism have focused on industrialized societies. There have however been several studies on patients with spinal cord injury (who are particularly at risk of developing DVT and PE) undertaken in Southeast Asian countries that bear out the diet-linked difference compared to Western industrialized societies (see Selected bibliography).

The ICRC procedure is to ask national colleagues about the extent of the problem and what is commonly used in the country.

- Is DVT a known problem in the main local government hospitals?
- Are there studies on the local population?
- Do Ministry of Health guidelines exist?
- Do local colleagues routinely prescribe prophylaxis for DVT?

Should prophylaxis be contemplated, non-pharmacological methods are given priority: good pain management allowing for early patient mobilization, physiotherapy and leg exercises.

### Physiotherapy

In low-income and some medium-income countries, physiotherapists are far less numerous than nursing staff, if at all present. Furthermore, doctors and nursing staff are often poorly trained in basic patient physiotherapy. Skilled staff who understand the importance of good analgesia and getting the patient out of bed, breathing deeply and coughing, are essential. This is as much the responsibility of the surgeon as that of the nurse or physiotherapist, if not more so, and the surgeon must help to define and organize the physiotherapy protocols for patient management.

Many patients certainly prefer to stay inactive after major operations and, in some societies, the patient mistakenly “expects” to remain perfectly still in bed. Ambulation, as early as possible, has been for a long time the most crucial component of post-operative care. In ICRC hospitals, all patients begin physiotherapy the first day after initial wound debridement as a routine.

“Bed rest is a fatal disease.”

Dr John M. Howard<sup>4</sup>

In ICRC hospitals, the physiotherapist participates in the team performing the daily rounds of patients and in decision-making. This is especially the case for certain pathologies and methods of treatment:

- control of skeletal traction in the “traction ward”, usually run by physiotherapists;
- POP casts;
- post-operative care of an amputation stump prior to the fitting of a prosthesis;
- care of the spinal cord injury patient.

In a hospital without physiotherapists, the surgeon should take the time to give the necessary explanations and instruct the nursing staff in the “mechanics” of traction, casts, etc.

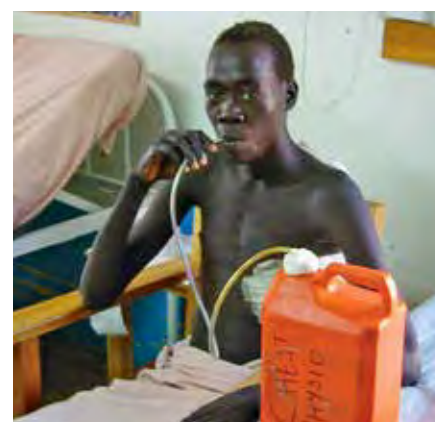

Figure F.3

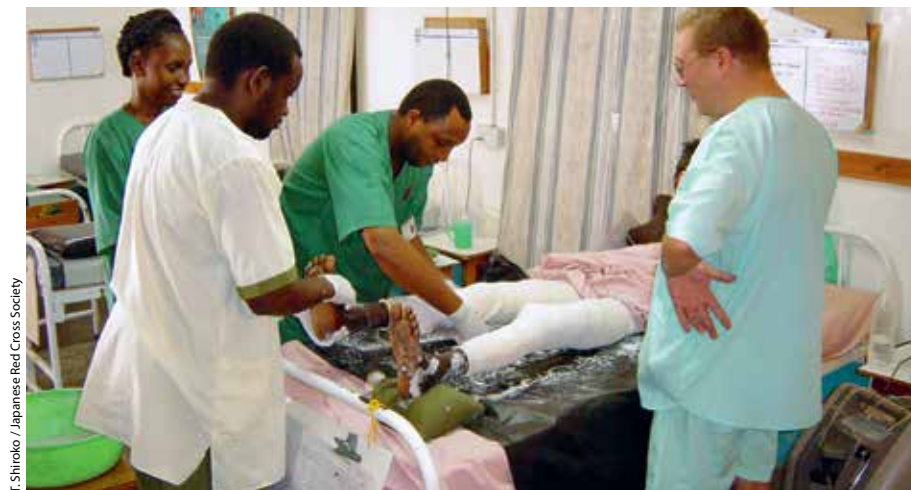Simple but effective chest physiotherapy.

T. Shiroko / Japanese Red Cross Society

<sup>4</sup> Personal communication to Dr Assad Taha, Associate Professor at the American University of Beirut Medical Center and consultant to the ICRC. Dr John M. Howard (1919 – 2011) served in a Mobile Army Surgical Hospital (MASH) during the War in Korea and directed the Army’s Surgical Research Team, which developed vascular repair of arterial injuries instead of ligation. He went on to chair the departments of surgery at Emory University College of Medicine and the University of Toledo Medical Center.

Figure F.4

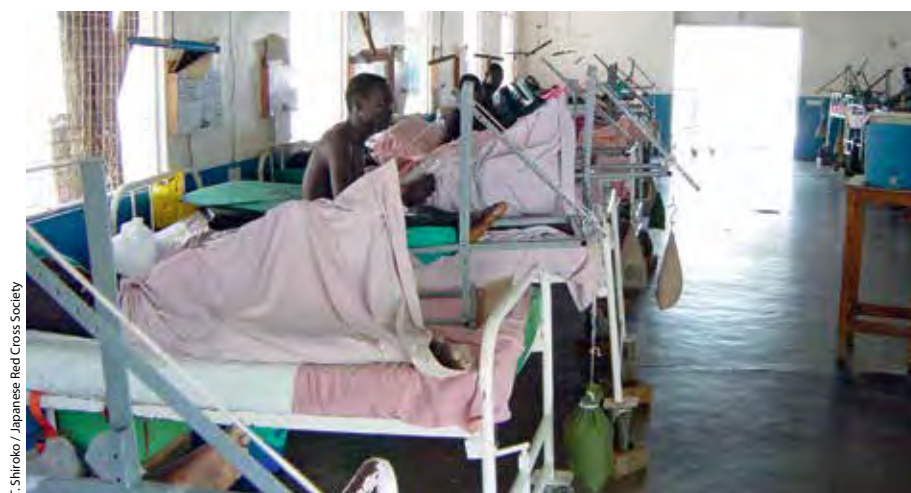ICRC physiotherapists applying a POP cast.



T. Shiroko / Japanese Red Cross Society

Figure F.5

Traction ward in the ICRC Lokichokio Hospital in northern Kenya, under the primary supervision of physiotherapists.



T. Shiroko / Japanese Red Cross Society

### Discharge

The hospital should have a clear and simple discharge card. In the rural areas of low-income countries, patients often return home to places where there are no doctors. The card should give clear and simply written information on what has been done and what to do in case of commonly occurring problems. It should also include instructions on how to contact the hospital and whom to contact if any complication develops.

## F.3 Critical care in low-income countries

“All hospitals have critically ill patients.”

D.A.K. Watters et al.<sup>5</sup>

The absence of a sophisticated intensive care unit equipped with mechanical ventilation, advanced high-level patient monitors and resuscitation equipment does not prevent organizing the care of critically ill patients in a specially designated part of the hospital. Good critical care through intensive nursing can do much to help the patient with an open brain injury, a laparotomy, a haemothorax requiring chest tube drainage, tetanus or eclampsia.

### Organization of an intensive therapy ward

An intensive therapy ward requires a chosen space to concentrate available equipment and nursing staff. The patient to nurse ratio – usually 20 or 30:1 or more in the general wards in settings of limited resources – should be much lower. A 4:1 ratio is the standard in ICRC hospitals.

<sup>5</sup> Watters DAK, Wilson IH, Leaver RJ, Bagshawe A. *Care of the Critically Ill Patient in the Tropics and Subtropics*. 2nd ed. Oxford: Macmillan; 2004.



T. Shiroko / Japanese Red Cross Society

**Figure F.6**  
General male ward in Lokichokio Hospital.



F. Hebert / ICRC

**Figure F.7**  
Intensive nursing ward in Lokichokio Hospital.

Equipment should include at a minimum a suction device, pulse oxymeter, oxygen supply of some sort and humidifier system, as well as the standard stethoscope and sphygmomanometer. Usually lacking in resource-poor settings are mechanical ventilation, a cardiac monitor, an infusion pump, the capacity for inotropic support, dialysis, and central venous lines. These all need trained biomedical technicians for maintenance and repair and specialized preparation and guidance of the nursing staff.

Laboratory analyses that are commonly available include basic blood analysis, biochemistry and serology. Serum electrolytes are a definite plus, but analysis of arterial blood gases is almost universally absent.

“Patients do not deteriorate suddenly. We just suddenly notice.”

J.-L. Vincent<sup>6</sup>

Nursing staff should be qualified to carry out frequent monitoring of patients and trained in recognizing the deterioration of a patient’s status and responding to acute conditions with appropriate initial resuscitative interventions. Training of nursing staff to accomplish these goals should be an essential task for the surgeon, anaesthetist or anaesthesia nurse, and other fully-trained doctors in the hospital.

The key to intensive critical care: well-trained and motivated nursing staff.

### Admission criteria

The criteria for admission to an intensive therapy unit should apply the same logic as that of triage of mass casualties “to avoid futile efforts [and] to identify potential survivors”.<sup>7</sup> There is a great deal of difference between an acute pathology in an otherwise relatively healthy individual – particularly the case with the victims of trauma – and an acute exacerbation of multiple chronic pathologies. Such conditions or treatments include:

- unconscious patients;
- tracheostomy;
- chest tube;
- laparotomy;
- enteral feeding using a naso-gastric, gastric, or jejunal tube;
- tetanus;
- eclampsia;

<sup>6</sup> Professor Jean-Louis Vincent, Intensive Care Service, Erasmus University Hospital, Brussels, Belgium.

<sup>7</sup> Towey RM, Ojara S. Practice of intensive care in rural Africa: an assessment of data from Northern Uganda. *African Health Sciences* 2008; **8**: 61 – 64.

- venomous snake bite;
- or quite simply a patient requiring intravenous fluids and antibiotics and frequent monitoring in the opinion of the treating physician.

#### Assisted ventilation

The absolute number of patients actually requiring assisted ventilation is rather small. Manually “bagging” a specific patient, and for how long, depends on hospital staffing. Volunteers can be engaged and trained, according to the circumstances.

Although mechanical ventilation is not an absolute necessity for the treatment of many acutely ill patients, if one is to be used it should consist of an appropriate technology. Annex 1.A defines the ICRC criteria for introducing a new technology. The best ventilator in resource-poor circumstances is driven by an oxygen concentrator and not by pressurized oxygen, although this still requires a constant supply of electrical current.

However, it should be kept in mind that the use of a mechanical ventilator in critical care means a systemic change in the functioning of the hospital. Taking a patient off the ventilator after 24 or 48 hours to provide care for another more critically ill patient is not easy to do or to explain to the family and creates a possible security risk in conditions of armed conflict.

## F.4 Improvisation

This manual often speaks of the need to improvise certain pieces of equipment or clinical protocols. Doctors and nurses who have worked in resource poor areas of the world have regularly published articles describing their inventions. A short summary of some of the most useful in conditions of extreme destitution might include the following.

- Recycling used surgical gloves: wash with a hypochlorite solution, rinse, dry, powder and pass through the autoclave.
- Cotton thread or fishing-tackle for sutures.
- Atraumatic needles: cotton thread or fishing tackle is threaded through a thin hypodermic needle, which is then crimped to keep the suture material in place and the plastic end of the needle broken off (Figure 32.26).
- Heimlich valve using the cut finger from a surgical glove (Figure 8.3).
- Any sterile tube as a chest drain: Foley catheter, naso-gastric tube, i.v. giving set. (Figure 31.12.2)
- Chest drainage bottles made from small jerry cans or plastic water bottles, and fixing the tubing with tape to prevent the end rising above the level of normal saline (Figure 31.12.2). Sterile urine bags can also be used.
- Bent spoon or fork used as a laryngoscope and the supraglottic space lit by a torch.
- Urinary catheter: naso-gastric tube or a tracheal suction catheter and fixed with tape.
- Naso-gastric suction apparatus.
- Penrose drain: cut fingers from a sterile surgical glove.
- Esmarch elastic bandage can be used as a tourniquet where the pneumatic tourniquet is not available and can be made using bicycle inner tubes. The same inner tubes can be used for various physiotherapy exercises.
- Sterile vaseline gauze for burn dressings can be made locally at very low cost: a roll of cotton gauze cut in pieces of the desired sizes and covered with vaseline jelly, which are then autoclaved.
- Treated tap water for wound irrigation.



M. Balaban / ICRC

Figure F.8

Recycled surgical gloves on a drying rack.



- Sugar and honey for dressing wounds.
- Maggot therapy where this is acceptable to the patients.
- Sterilized mosquito netting for hernia repair, including incisional hernias.
- Rectal use of vaginal metronidazole suppositories or non-coated tablets where intravenous supplies are lacking.
- Cardboard box as a patient warmer to prevent hypothermia.

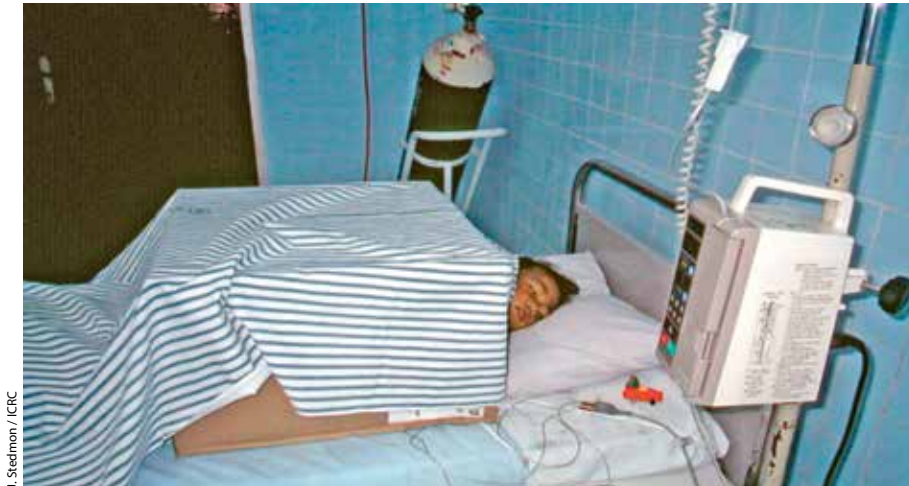

Figure F.9

Using a cardboard box to maintain patient temperature for prevention and treatment of hypothermia.

- Modified “pizza-cutter” for meshing split skin grafts.
- Rectal tap water fluid therapy. All adult patients having had abdominal surgery are given 500 ml of tap water *per rectum* every 6 hours until capable of taking oral fluids. Sodium chloride (15 gm) and potassium chloride (5 gm) can be added to each 5 litre batch. An intravenous infusion is maintained as well for the first 12 hours post-operatively.
- Production of i.v. fluids (normal saline, dextrose 5% in water, Ringer’s lactate) by distillation of water, recyclable glass jars, and autoclaving as done in many isolated missionary hospitals.



Figure F.10

Meshing a split-skin graft with a “pizza-cutter” whose edge has been serrated.



Figures F.11.1 and F.11.2

Distilling device, recyclable glass bottles and autoclave for the local production of i.v. fluids.

The running of a hospital when resources are scarce is a challenging task. Equipment is limited, medicines and consumables in short supply, trained staff lacking, and support from a far distant ministry often inadequate. Poverty, bureaucratic obstacles, disorganization due to the prevailing violence, and corruption all too often complicate the work of health professionals. Even with adequate support, the management of war-wounded is frequently an overwhelming additional burden on the daily work of a public hospital. It is common under these circumstances for the surgeon to assume responsibility for tasks for which he is not always trained or prepared.

Improvisation is an art to be cultivated.

## F.5 Final remarks

It is not unusual when working in conditions of limited resources for the surgeon to sleep by the patient's bedside if that is what is necessary.

The surgeon must assume entire responsibility for the patient for the entire duration of hospitalization and, in many cases, even after discharge. It is not enough for the good surgeon to develop the "cognitive dissonance" which allows him or her to go from a death bed to the operating table to patient rounds. It is not enough to master the technical skills of dissection and repair. There is also the art of humane medical practice. If this is true of surgical work in a resource-rich environment, then it is even more essential in a resource-poor one.

In many countries around the world the surgeon remains a much respected member of the community. The patient's right to consultation and discussion, so much a matter of concern in developed countries, is almost inexistent and patient management rather resembles surgical practice in the industrialized countries of the West of a generation or two ago. Thus the responsibility of the surgeon is even greater to "do no harm" and treat the patient with due respect, empathy and humanity.

"I made an amputee laugh today. My day is a success!"

ICRC surgeon

## ANNEX F. 1 Ballistics

A detailed description of wound ballistics is to be found in Chapter 3 of Volume 1. This Annex gives a brief summary of some important points.

Many factors are involved in determining the extent of injury due to projectiles. Ultimately, the most important ones are the effective transfer of kinetic energy to the tissues and the reaction of the specific tissue concerned. Projectiles cause tissue trauma by crush and laceration and by the effects of temporary cavitation: shearing forces leading to stretch.

Some tissues are severely affected by cavitation (parenchymatous and fluid-filled organs) and others not (lungs), depending on the density and elasticity of the specific tissue. Whether clinically significant cavitation occurs depends on the type of projectile – fragment or bullet– and on the length of the projectile trajectory in the body. In the case of bullets it also depends on whether it is a full metal jacket (FMJ) or semi-jacketed (SJ) one, and on whether the bullet is stable or has been destabilized by ricochet. The point of any cavitation along the trajectory is highly significant.

Five different projectile profiles can be described as shown by shooting various projectiles into blocks of glycerine soap in a ballistics laboratory.

### F.1.a Stable high-energy FMJ military rifle bullet travelling at more than 600 m/sec

The wound channel of the AK-47 bullet is used as an example. The bullet first follows a straight line creating the phase 1 straight narrow channel. It then tumbles and causes the creation of the phase 2 temporary cavity whose diameter can be 25 times that of the bullet. The bullet then carries on more or less in a straight line producing the phase 3 narrow channel.



Figure F.1.1

Profile of an AK-47 bullet in soap: stable bullet with high-kinetic energy.

For all three phases to be apparent in the body, the length of the bullet's trajectory must be long enough. Otherwise, an exit wound occurs at an earlier stage and the characteristics of this wound – large or small – correspond to that particular phase of the profile. Different bullets create different profiles with specific distances for the onset of phase 2 cavitation.

### F.1.b Stable low-energy FMJ handgun bullet

With the bullet from a handgun no tumbling of the bullet occurs and it follows a simple straightforward path. An FMJ rifle bullet hitting the body at less than 600 m/sec tends to create the same sort of profile as a handgun bullet.




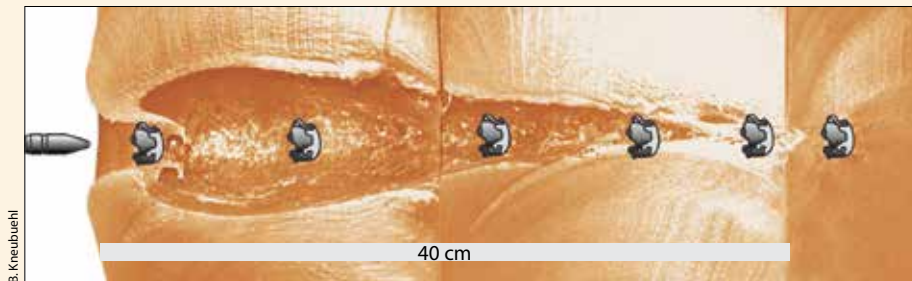
Figure F.1.2

Profile of a low-kinetic energy stable FMJ bullet in soap.

**F.1.c High-energy SJ hunting rifle bullet travelling at more than 600 m/sec**

The bullet deforms – mushrooms – immediately on impact with the body causing an abrupt reduction in velocity and great transfer of kinetic energy, which results in an immediate and large temporary cavity with much tissue damage. These bullets are colloquially known as “dum-dum” bullets and their use in combat is prohibited by international treaties.


**Figure F.1.3**  
Profile of a deforming SJ rifle bullet in soap.



**F.1.d Deforming low-energy SJ handgun bullet**

The same mushrooming of the bullet occurs, thus presenting a large cross section to the tissues, but the width of the temporary cavitation is proportionally smaller.


**Figure F.1.4**  
Profile of a deforming handgun bullet in soap.



**F.1.e Fragments**

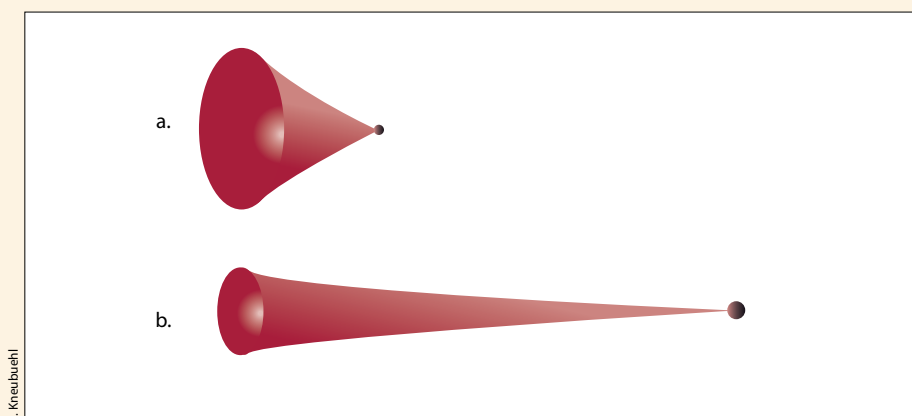
In the case of a fragment – a non-aerodynamic projectile – the major transfer of kinetic energy always occurs at the entry point. This creates a profile that resembles a “cone”. The entry is always larger than the diameter of the fragment and always larger than any exit.

**Figure F.1.5**  
Shooting profile of a fragment in soap.



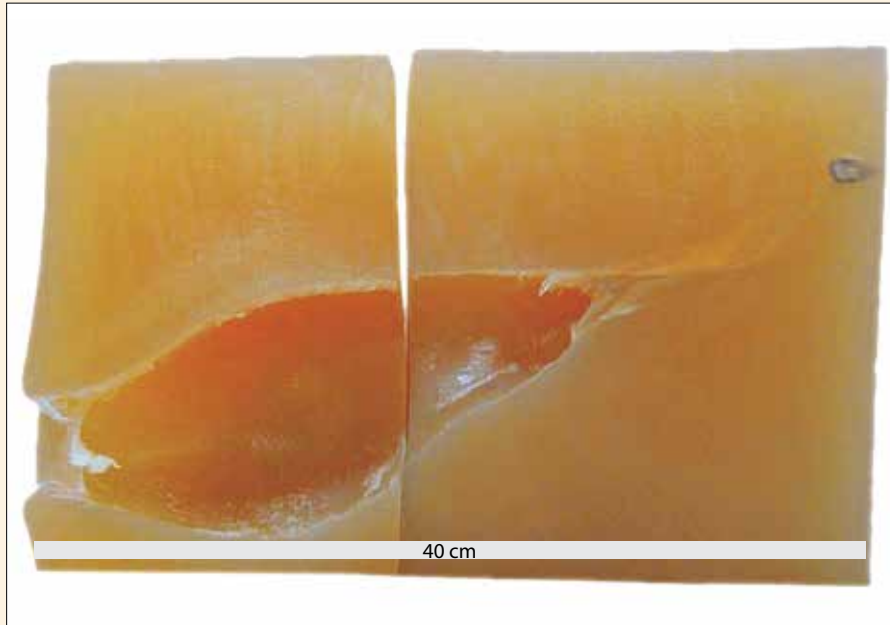
**Figure F.1.6**  
Two fragments with the same kinetic energy – note the difference in energy deposition along the track, demonstrated by the difference in the cavities:

- a. lightweight and fast fragment;
- b. heavy and slow fragment.



### F.1.f Ricochet bullets

A ricochet bullet striking some object that destabilizes it before it hits the target creates a profile that resembles that of an SJ bullet or even a fragment, giving off a large part of its kinetic energy soon after impact. The existence of ricochet wounds has often caused combatants to accuse the adversary of using "illegal dum-dum" bullets.



B. Kneubuehl

**Figure F.1.7**

FMJ rifle bullet after ricochet effect in soap. The large impact angle after ricochet destabilizes the bullet, which tumbles easily and early in the shooting channel. Note that the cavitation occurs almost immediately on impact, similar to an SJ bullet.

## ANNEX F. 2 Red Cross Wound Score and classification system

Chapter 4 in Volume 1 gives a full description of the Red Cross Wound Score and Classification System.

The RCWS pertains only to penetrating wounds caused by projectiles. It is an attempt to correlate in a simple manner the effective transfer of kinetic energy as described by wound ballistics to the lesions that the surgeon actually sees. It is based on the features of the wound itself, and not on the weaponry or the presumed velocity or kinetic energy of the missile.

The severity of projectile wounds depends on the degree of tissue damage and the structure(s) that may have been injured: thus the clinical significance of a wound depends on its size and site. Six parameters are used to describe the wound, resulting in a grading system and defining the type of injured tissues.

E	Entry wound in centimetres	
X	Exit wound in centimetres (x = 0 if no exit wound)	
C	Cavity	Can the cavity of the wound take two fingers before surgical excision? C 0 = no C 1 = yes
F	Fracture	Are any bones fractured? F 0 = No fracture F 1 = Simple fracture, hole or insignificant comminution F 2 = Clinically significant comminution
V	Vital structure	Is there penetration of the dura, pleura, peritoneum? Or injury to major peripheral vessels? V 0 = no vital structure injured V N = (neurological) penetration of the dura of the brain or spinal cord V T = (thorax or trachea) penetration of the pleura or of the larynx/trachea in the neck V A = (abdomen) penetration of the peritoneum V H = (haemorrhage) injury to a major peripheral blood vessel down to brachial or popliteal arteries, or carotid artery in the neck
M	Metallic body	Are bullets or fragments visible on X-ray? M 0 = no M 1 = yes, one metallic body M 2 = yes, multiple metallic bodies

Table F.2.1 Parameters of the Wound Score.

### F.2.a Wound Grade according to amount of tissue damage

#### Grade 1

E + X is less than 10 cm with Scores C 0 and F 0 or F 1.

(Low energy transfer)

#### Grade 2

E + X is less than 10 cm with Scores C 1 or F 2.

(High energy transfer)

#### Grade 3

E + X is 10 cm or more, invariably with Scores C 1 or F 2.

(Massive energy transfer)

These increasing Grades of severity represent the outcome of a simple clinical assessment that corresponds to the effective transfer of kinetic energy of projectiles to body tissues. Plainly put, large wounds are more serious and require greater resources for their management, and this is particularly true of wounds to the limbs.

### F.2.b Typing wounds according to the injured tissues

#### Type ST

Soft-tissue wounds: F 0 and V 0.

#### Type F

Wounds with fractures: F 1 or F 2, and V 0.

#### Type V

Vital wounds putting the patient's life at risk: V = N, T, A or H and F 0.

#### Type VF

Wounds with fractures and involving vital structures putting life or limb at risk: F 1 or F 2 and V = N, T, A or H.

### F.2.c Wound classification

Combining Grades and Types gives rise to a classification system divided into 12 categories.

	Grade 1	Grade 2	Grade 3
Type ST	1 ST Small, simple wound	2 ST Medium soft-tissue wound	3 ST Large soft-tissue wound
Type F	1 F Simple fracture	2 F Important fracture	3 F Massive comminution threatening limb
Type V	1 V Small wound threatening life	2 V Medium wound threatening life	3 V Large wound threatening life
Type VF	1 VF Small wound threatening limb and/or life	2 VF Important wound threatening life and/or limb	3 VF Large wound threatening life and/or limb

Table F.2.2 Grade and tissue Type categories.

## ANNEX F. 3 ICRC antibiotic protocol

Injury	Antibiotic	Remarks
Minor soft-tissue wounds, uncomplicated Grade 1	Penicillin-V tablets 500 mg QID for five days	Anti-tetanus measures for all weapon - injured patients
Compound fractures Traumatic amputations Major soft-tissue wounds (Grades 2 and 3)	Penicillin-G 5 MIU i.v. QID for 48 hours Follow with penicillin-V tablets 500 mg QID until DPC	Continue penicillin-V for five days if closure is performed with a split skin graft If re-debridement is performed instead of DPC: stop antibiotic unless there are signs of systemic infection or active local inflammation – in latter case, add metronidazole 500 mg i.v. TID and gentamycin 80 mg i.v. TID
Compound fractures or major soft-tissue wounds with delay of more than 72 hours Anti-personnel landmine injuries to limbs whatever the delay	Penicillin-G 5 MIU i.v. QID and metronidazole 500 mg i.v. TID for 48 hours Follow with penicillin-V tablets 500 mg QID and metronidazole tablets 500 mg TID until DPC	Continue for 5 days
Haemothorax	Ampicillin 1 gm i.v. QID for 48 hours, followed by amoxicillin tablets 500 mg QID	Continue i.v. or orally according to patient's condition for a total of 10 days
Penetrating cranio-cerebral wounds	Penicillin-G 5 MIU i.v. QID and chloramphenicol 1 gm i.v. TID for at least 72 hours	Continue i.v. or orally according to patient's condition for total of 10 days Local instillation of antibiotic eye-drops
Brain abscess	Same regime as for penetrating cranio-cerebral wounds plus metronidazole 500 mg i.v. TID	
Penetrating eye injuries	Penicillin-G 5 MIU i.v. QID and chloramphenicol 1 gm i.v. TID for 48 hours	
Maxillo-facial wounds	Ampicillin 1 gm i.v. QID and metronidazole 500 mg i.v. TID for 48 hours	Continue i.v. or orally according to patient's condition for total of 5 days
Abdominal wounds: 1. solid organs only: liver, spleen, kidney; or isolated bladder injury 2. stomach, small intestines 3. colon, rectum, anus	Penicillin-G 5 MIU i.v. QID  Ampicillin 1 gm i.v. QID and metronidazole 500 mg i.v. TID  Ampicillin 1 gm i.v. QID and metronidazole 500 mg i.v. TID and gentamycin 80 mg i.v. TID	Continue for 5 days

MIU: million international units.

QID: *quater in die* (4 x day).

TID: *ter in die* (3 x day).

Please note:

This protocol was revised by the Second ICRC Master Surgeons Workshop held in Geneva, December 2010.







## ACRONYMS

ABI	Ankle-brachial index
AIS	Abbreviated injury scale
APM	Anti-personnel mine
ARDS	Acute respiratory distress syndrome
ASIA	American Spinal Injury Association
ATM	Anti-tank mine
A-V	Arterio-venous
BID	<i>Bis in die</i> ; twice a day
BLI	Blast lung injury
CH or F	Charrière or French gauge system used in sizing catheters (1 CH = 0.333 mm)
CIC	Clean intermittent catheterization
CNS	Central nervous system
CPD-A	Citrate phosphate dextrose adenine
CS	Caeserean section
CSF	Cerebrospinal fluid
CT scan	Computed tomography scan
CVP	Central venous pressure
DIC	Disseminated intravascular coagulation
DIME	Dense inert metal explosive
DOA	Dead on arrival
DPC	Delayed primary closure
2, 3-DPG	2, 3-diphosphoglycerate
DPL	Diagnostic peritoneal lavage
DVT	Deep vein thrombosis
eFAST	Extended focused assessment sonography in trauma
EMG	Electromyography

ENT	Ear-nose-throat
ER	Emergency room
ERT	Emergency room thoracotomy
ERW	Explosive remnants of war
F or CH	French or Charrière gauge system used in sizing catheters (1 F = 0.333 mm)
FAST	Focused assessment sonography in trauma
FMJ	Full metal jacket
GCS	Glasgow Coma Scale
GOS	Glasgow Outcome Scale
GSW	Gunshot wound
IC	Intermittent catheterization
ICP	Intracranial pressure
ICU	Intensive care unit
IED	Improvised explosive device
IOFB	Intra-ocular foreign body
ISS	Injury Severity Score
IVC	Inferior vena cava
IVP	Intravenous pyelogram
MESS	Mangled Extremity Severity Score
MMF	Maxillo-mandibular fixation
NPO	<i>Nil per os</i> ; nothing by mouth, keep fasting
OPSI	Overwhelming post-splenectomy infection
ORL	Otorhinolaryngology
OT	Operating theatre
PATI	Penetrating Abdominal Trauma Index
PE	Pulmonary embolism
POP	Plaster-of-Paris
PR	<i>Per rectum</i>
PT	Prothrombin time
PTB	Patella-tendon-bearing
PTSD	Post-traumatic stress disorder
PTT	Partial thromboplastin time
QID	<i>Quater in die</i> ; four times a day
RBC	Red blood cell
RPG	Rocket-propelled grenade
RTD	Returned to duty
SCI	Spinal cord injury (injured)
SCM	Sternocleidomastoid
SIC	Sterile intermittent catheterization

SJ	Semi-jacketed
SMA	Superior mesenteric artery
SMV	Superior mesenteric vein
TID	<i>Ter in die</i> ; three times a day
TUU	Transverse uretero-ureterostomy
UGT	Urogenital tract
UNC	Uretero-neocystostomy
UTI	Urinary tract infection
UU	Uretero-ureterostomy
UXO	Unexploded ordnance
VAC	Vacuum assisted wound closure
Ø	Diameter



## SELECTED BIBLIOGRAPHY

Many references in Volume 1 have served in the writing of this Volume; they are not referred to here unless mentioned as a source in a table. For the sake of brevity references cited in footnotes in the main text are not repeated in this Bibliography.

### Additional general references

Bashir MO, Abu-Zidan FM, Lennquist S. Will the damage-control concept influence the principles for setting priorities for severely traumatized patients in disaster situations? *Int J Disaster Med* 2003; **1**: 97 – 102.

Hollifield M. Taking measure of war trauma. *Lancet* 2005; **365 (9467)**: 1283 – 1284.

Ivatury RR, Cayten CG, eds. *The Textbook of Penetrating Trauma*. Media, PA: Williams & Wilkins; 1996.

Mahoney PF, Ryan JM, Brooks AJ, Schwab CW eds. *Ballistic Trauma: A Practical Guide, 2nd ed.* London: Springer-Verlag; 2005.

Mattox KL, Moore EE, Feliciano DV eds. *Trauma, 7th ed.* New York: McGraw Hill; 2012.

Meier D. Opportunities and improvisations: a pediatric surgeon's suggestions for successful short-term surgical volunteer work in resource-poor areas. *World J Surg* 2010; **34**: 941 – 946.

Mohta M, Sethi AK, Tyagi A, Mohta A. Psychological care in trauma patients. *Injury* 2003; **34**: 17 – 25.

Parker PJ. Damage control surgery and casualty evacuation: techniques for surgeons, lessons for military medical planners. *J R Army Med Corps* 2006; **152**: 202 – 211.

Velmahos GC, Degiannis E, Doll D Eds. *Penetrating Trauma: A Practical Guide on Operative Technique and Peri-Operative Management*. Springer-Verlag, Berlin Heidelberg, 2012.

### Part A

#### Introduction

Baskin TW, Holcomb JB. Bombs, mines, blast, fragmentation, and thermobaric mechanisms of injury. In: Mahoney PF, Ryan JM, Brooks AJ, Schwab CW eds. *Ballistic Trauma: A Practical Guide, 2nd ed.* London: Springer-Verlag; 2005: 45 – 66.

Champion HR, Holcomb JB, Young LA. Injuries from explosions: physics, biophysics, pathology, and required research focus. *J Trauma* 2009; **66**: 1468 – 1477.

Cullis IG. Blast waves and how they interact with structures. *J R Army Med Corps* 2001; **147**: 16 – 26.

Morrison JJ, Mahoney PF, Hodgetts T. Shaped charges and explosively formed penetrators: background for clinicians. *J R Army Med Corps* 2007; **153**: 184 – 187.

Ramasamy A, Harrisson SE, Clasper JC, Stewart MPM. Injuries from roadside improvised explosive devices. *J Trauma* 2008; **65**: 910 – 914.

## Chapter 19

### General references

Almogly G, Mintz Y, Zamir G, Bdolah-Abram T, Elazary R, Dotan L, Faruga M, Rivkind AI. Suicide bombing attacks: can external signs predict internal injuries. *Ann Surg* 2006; **243**: 541 – 546.

Arnold JL, Halperin P, Tsai MC, Smithline H. Mass casualty terrorist bombings: a comparison of outcomes by bombing type. *Ann Emerg Med* 2004; **43**: 263 – 273.

DePalma RG, Burris DG, Champion HR, Hodgson MJ. Review Article: Blast Injuries. *N Engl J Med* 2005; **352**: 1335 – 1342.

Horrocks CL. Blast injuries: biophysics, pathophysiology and management principles. *J R Army Med Corps* 2001; **147**: 28 – 40.

Kosashvili Y, Loebenberg MI, Lin G, Peleg K, Zvi F, Kluger Y, Blumenfeld A. Medical consequences of suicide bombing mass casualty incidents: the impact of explosion setting on injury patterns. *Injury* 2009; **40**: 698 – 702.

Plurad DS. Blast injury. *Mil Med* 2011; **176**: 276 – 282.

Propper BW, Rasmussen TE, Davidson SB, Vandenberg SL, Clouse WD, Burkhardt GE, Gifford SM, Johannigman JA. Surgical response to multiple casualty incidents following single explosive events. *Ann Surg* 2009; **250**: 311 – 315.

Ramasamy A, Hill AM, Clasper JC. Improvised explosive devices: pathophysiology, injury profiles and current medical management. *J R Army Med Corps* 2009; **155**: 265 – 272.

Ritenour AE, Baskin TW. Primary blast injury: update on diagnosis and treatment. *Crit Care Med* 2008; **36 (Suppl.)**: S311 – S317.

Ritenour AE, Blackbourne LH, Kelly JF, McLaughlin DF, Pearse LA, Holcomb JB, Wade CE. Incidence of primary blast injury in US military overseas contingency operations: a retrospective study. *Ann Surg* 2010; **251**: 1140 – 1144.

Wolf SJ, Bebarta VS, Bonnett CJ, Pons PT, Cantrill SV. Seminar: blast injuries. *Lancet* 2009; **374**: 405 – 415.

### Epidemiology

Aylwin C, König TC, Brennan RW, Shirley PJ, Davies G, Walsh MS, Brohi K. Reduction in critical mortality in urban mass casualty incidents: analysis of triage, surge, and resource use after the London bombings on July 7, 2005. *Lancet* 2006; **368**: 2219 – 2225.

Brismar B, Bergenwald L. The terrorist bomb explosion in Bologna, Italy, 1980: an analysis of the effects and injuries sustained. *J Trauma* 1982; **22**: 216 – 220.

Frykberg ER, Tepas JJ, Alexander RH. The 1983 Beirut airport terrorist bombing: injury patterns and implications for disaster management. *Am Surg* 1989; **55**: 134 – 141.

Katz E, Ofek B, Adler J, Abramowitz HB, Krausz MM. Primary blast injury after a bomb explosion in a civilian bus. *Ann Surg* 1989; **209**: 484 – 488.

Langworthy MJ, Sabra J, Gould M. Terrorism and blast phenomena: lessons learned from the attack on the USS Cole (DDG67). *Clin Orthop Rel Res* 2004; **422**: 82 – 87.

Mallonee S, Shariat S, Stennies G, et al: Physical injuries and fatalities resulting from the Oklahoma City bombing. *JAMA* 1996; **276**: 382 – 387.

Rignault DP, Deligny MC. The 1986 terrorist bombing experience in Paris. *Ann Surg* 1989; **209**: 368 – 373.



Teague DC. Mass casualties in the Oklahoma City bombing. *Clin Orthop Relat Res* 2004; **422**: 77 – 81.

Thompson D, Brown S, Mallonee S, Sunshine D. Fatal and non-fatal injuries among U.S. Air Force personnel resulting from the terrorist bombing of the Khobar Towers. *J Trauma* 2004; **57**: 208 – 215.

Torkki M, Koljonen V, Sillanpää K, Tukiainen E, Pyörälä S, Kemppainen E, Kalske J, Arajärvi E, Keränen U, Hirvensalo E. Triage in a bomb disaster with 166 casualties. *Eur J Trauma* 2006; **32**: 374 – 380.

Turégano-Fuentes F, Caba-Doussoux P, Jover-Navalón JM, Martín-Pérez E, Fernández-Luengas D, Díez-Valladares L, Pérez-Díaz D, Yuste-García P, Guadalajara Labajo H, Ríos-Blanco R, Hernando-Trancho F, García-Moreno Nisa F, Sanz-Sánchez M, García-Fuentes C, Martínez-Virto A, León-Baltasar JL, Vasquez-Estévez J. Injury patterns from major urban terrorist bombings in trains: the Madrid experience. *World J Surg* 2008; **32**: 1168 – 1175.

### Ear

Cave KM, Cornish EM, Chandler DW. Blast injury of the ear: clinical update from the Global War on Terror. *Mil Med* 2007; **172**: 726 – 730.

Chandler D. Blast-related ear injury in current U.S. military operations. *ASHA Lead* 2006; **11**: 8 – 9, 29.

Garth RJN. Blast injury of the ear: an overview and guide to management. *Injury* 1995; **26**: 363 – 366.

Leibovici D, Gofrit ON, Shapira SC. Eardrum perforation in explosion survivors: is it a marker of pulmonary blast injury? *Ann Emerg Med* 1999; **34**: 168 – 172.

Peters P. Primary blast injury: an intact tympanic membrane does not indicate the lack of a pulmonary blast injury. *Mil Med* 2011; **176**: 110 – 114.

### Cardiovascular and pulmonary barotrauma

Abu-Zidan FM, Aman S. Underwater explosion lung injury. *J Trauma* 2001; **50**: 169.

Avidan V, Hersch M, Armon Y, Spira R, Aharoni D, Reissman P, Schecter WP. Blast lung injury: clinical manifestations, treatment, and outcome. *Am J Surg* 2005; **190**: 945 – 950.

Bala M, Shussman N, Rivkind AI, Izhar U, Almog G. The pattern of thoracic trauma after suicide terrorist bombing attacks. *J Trauma* 2010; **69**: 1022 – 1029.

Chavco M, Prusaczyk WK, McCarron RM. Lung injury and recovery after exposure to blast overpressure. *J Trauma* 2006; **61**: 933 – 942.

Cohn SM, DuBose JJ. Pulmonary contusion: an update on recent advances in clinical management. *World J Surg* 2010; **34**: 1959 – 1970.

Mackenzie IMJ, Tunnicliffe B. Blast injuries to the lung: epidemiology and management. *Phil Trans R Soc B* 2011; **366**: 295 – 299. [doi: 10.1098/rstb.2010.0252]

Smith JE. The epidemiology of blast lung injury during recent military conflicts a retrospective database review of cases presenting to deployed military hospitals, 2003-2009. *Phil Trans R Soc B* 2011; **366**: 291 – 294. [doi: 10.1098/rstb.2010.0251]

### Neurotrauma

Armonda RA, Bell RS, Vo AH, Ling G, DeGraba TJ, Crandall B, Ecklund J, Cambell WW. Wartime traumatic cerebral vasospasm: recent review of combat casualties. *Neurosurg* 2006; **59**: 1215 – 1225.

Bhattacharjee Y. Shell shock revisited: solving the puzzle of blast trauma. *Science* 2008; **319**: 406 – 408.

Desmoulin GT, Dionne J-P. Blast-induced neurotrauma: surrogate use, loading mechanisms, and cellular responses. *J Trauma* 2009; **67**: 1113 – 1122.

Hicks RR, Fertig SJ, Desrocher RE, Koroshetz WJ, Pancrazio JJ. Neurological effects of blast injury. *J Trauma* 2010; **68**: 1257 – 1263.

Ling G, Bandak F, Armonda R, Grant G, Ecklund J. Explosive blast neurotrauma. *J Neurotrauma* 2009; **26**: 815 – 825.

Ling GSF, Ecklund JM. Traumatic brain injury in modern war. *Curr Opin Anesthesiol* 2011; **24**: 124 – 130.

MacDonal CL, Johnson AM, Cooper D, Nelson EC, Werner NJ, Shimony JS, Snyder AZ, Raichle ME, Witherow JR, Fang R, Flaherty SF, Brody DL. Detection of blast-related traumatic brain injury in U.S. military personnel. *N Engl J Med* 2011; **364**: 2091 – 2100.

Mora AG, Ritenour AE, Wade CE, Holcomb JB, Blackburne LH, Gaylord KM. Posttraumatic stress disorder in combat casualties with burns sustaining primary blast and concussive injuries. *J Trauma* 2009; **66 (Suppl.)**: S178 – S185.

Ropper A. Editorial: Brain injuries from blasts. *N Engl J Med* 2011; **364**: 2156 – 2157.

Rosenfeld JV, Ford NL. Bomb blast, mild traumatic brain injury and psychiatric morbidity: a review. *Injury* 2010; **41**: 437 – 443.

Sams R, LaBrie W, Norris J, Schauer J, Frantz E. IED blast postconcussive syncope and autonomic dysregulation. *Mil Med* 2012; **177**: 48 – 51.

#### Gastro-intestinal tract

Cripps NPJ, Cooper GJ. Risk of late perforation in intestinal contusions caused by explosive blast. *Br J Surg* 1997; **84**: 1298 – 1303.

Huller T, Bazini Y. Blast injuries of the chest and abdomen. *Arch Surg* 1970; **100**: 24 – 30.

Owers C, Morgan JL, Garner JP. Abdominal trauma in primary blast injury. *Br J Surg* 2011; **98**: 168 – 179.

Paran H, Neufeld D, Schwartz I, Kidron D, Susmallian S, Mayo A, Dayan K, Vider I, Sivak G, Freund U. Perforation of the terminal ileum induced by blast injury: delayed diagnosis or delayed perforation. *J Trauma* 1996; **40**: 472 – 475.

Wani I, Parray FQ, Sheikh T, Wani RA, Amin A, Gul I, Nazir M. Spectrum of abdominal organ injury in a primary blast type. *World J Emerg Surg* 2009; **4**: 46. Available at: <http://www.wjes.org/content/4/1/46>. [doi:10.1186/1749-7922-4-46]

#### Extremities

Covey DC, Lurate RB, Hatton CT. Field hospital treatment of blast wounds of the musculoskeletal system during the Yugoslav civil war. *J Orthop Trauma* 2000; **14**: 278 – 286.

Hull JB, Bowyer GW, Cooper GJ, Crane J. Pattern of injury in those dying from traumatic amputation caused by bomb blast. *Br J Surg* 1994; **81**: 1132 – 1135.

Ramasamy A, Hill AM, Masouros S, Gibb I, Bull AMJ, Clasper JC. Blast-related fracture patterns: a forensic biomechanical approach. *J R Soc Interface* 2011; **8**: 689 – 698. [doi:10.1098/rsif.2010.0476]

#### Biological foreign bodies

Centers for Disease Control and Prevention. *Recommendations for Postexposure Interventions to Prevent Infection with Hepatitis B Virus, Hepatitis C Virus, or Human Immunodeficiency Virus, and Tetanus in Persons Wounded During Bombings and Other Mass-Casualty Events – United States, 2008*. MMWR 2008; **57 (No. RR – 6)**: 1 – 19. Available at: <http://www.cdc.gov/mmwr/pdf/rr/rr5706.pdf>.

Eshkol Z, Katz K. Injuries from biologic material of suicide bombers. *Injury* 2005; **36**: 271 – 274.

Expert Group Convened by the Health Protection Agency (UK) 8 July 2005. *Risk Assessment. Post exposure prophylaxis against hepatitis B for bomb victims and immediate care providers. Consideration of other blood borne viruses (hepatitis C and HIV)*.

Available at: <http://www.hpa.org.uk/Topics/EmergencyResponse/ExplosionsAndFires/HealthEffectsOfExplosions/PostExposureProphylaxisAgainstBloodBorneViruses>.

### Tungsten toxicity

Jonas W, van der Voet GB, Todorov TI, Centeno JA, Ives J, Mullick FG. Metals and health: a clinical toxicological perspective on tungsten and review of the literature. *Mil Med* 2007; **172**: 1002 – 1005.

Machado BI, Murr LE, Suro RM, Gaytan SM, Ramirez DA, Garza KM, Schuster BE. Characterization and cytotoxic assessment of ballistic aerosol particulates for tungsten alloy penetrators into steel target plates. *Int J Environ Res Public Health* 2010; **7**: 3313 – 3331.

## Chapter 20

Jacobs LGH. The landmine foot: its description and management. *Injury* 1991; **22**: 463 – 466.

Ragel BT, Allred CD, Brevard S, Davis RT, Frank EH. Fractures of the thoracolumbar spine sustained by soldiers in vehicles attacked by improvised explosive devices. *Spine* 2009; **34**: 2400 – 2405.

Ramasamy A, Hill AM, Hepper AE, Bull AMJ, Clasper JC. Blast mines: physics, injury mechanisms and vehicle protection. *J R Army Med Corps* 2009; **155**: 258 – 264.

Ramasamy A, Masouros SD, Newell N, Hill AM, Proud WG, Brown KA, Bull AMJ, Clasper JC. In-vehicle extremity injuries from improvised explosive devices: current and future foci. *Phil Trans R Soc B* 2011; **366**: 160 – 170. [doi: 10.1098/rstb.2010.0219]

## Chapter 21

### General references

Anderson K, Goose SD, Stover E, Schurtman M, Askin S. *Landmines: A Deadly Legacy*. New York, NY: Human Rights Watch and Physicians for Human Rights; 1993.

Chaloner EJ, Mannion SJ. Antipersonnel mines: the global epidemic. *Ann R Coll Surg Engl* 1996; **78**: 1 – 4.

Coupland RM. *Assistance for Victims of Anti-personnel Mines: Needs, Constraints and Strategies*. Geneva: ICRC; 1997.

Giannou C, Romer C. *Victim Assistance: a public health response for landmine victims*. Geneva: ICRC / WHO; 2000.

Giannou C. Antipersonnel landmines: facts, fictions, and priorities. *BMJ* 1997; **315**: 1453 – 1454.

Giannou C, Geiger HJ. The Medical Lessons of Landmine Injuries. In: Cahill KM ed. *Clearing the Fields: Solutions to the Global Land Mines Crisis*. New York, NY: Basic Books and Council of Foreign Relations; 1994: 138 – 147.

World Health Organization: *Guidance for Surveillance of Injuries due to Landmines and Unexploded Ordnance*. Geneva: WHO; 2000.

### Epidemiology and socio-economic repercussions

Andersson N, Palha da Sousa C, Paredes S. Social cost of land mines in four countries: Afghanistan, Bosnia, Cambodia, and Mozambique. *BMJ* 1995; **311**: 718 – 721.

Ascherio A, Biellik R, Epstein A, Snetro G, Gloyd S, Ayotte B, Epstein PR. Deaths and injuries caused by land mines in Mozambique. *Lancet* 1995; **346**: 721 – 724.

Bilukha OO, Brennan M, Woodruff B. Death and injury from landmines and unexploded ordnance in Afghanistan. *JAMA* 2003; **290**: 650 – 653.

Bilukha OO, Tsitsaev Z, Ibragimov R, Anderson M, Brennan M, Murtazaeva E. Epidemiology of injuries and deaths from landmines and unexploded ordnance in Chechnya, 1994 through 2005. *JAMA* 2006; **296**: 516 – 518.

Bilukha OO, Brennan M, Anderson M. The lasting legacy of war: epidemiology of injuries from landmines and unexploded ordnance in Afghanistan, 2002–2006. *Prehosp Disast Med* 2008; **23**: 493 – 499.

Hanevik K, Kvåle G. Landmine injuries in Eritrea. *BMJ* 2000; **321**: 1189.

Jahunlu HR, Husum H, Wisborg T. Mortality in land-mine accidents in Iran. *Prehosp Disast Med* 2002; **17**: 107 – 109.

Kakar F, Bassani F, Romer CJ, Gunn SWA. The consequences of land mines on public health. *Prehosp Disast Med* 1996; **11**: 13 – 21.

Kinra S, Black ME. Landmine related injuries in children of Bosnia and Herzegovina 1991–2000: comparison with adults. *J Epidemiol Community Health* 2003; **57**: 264 – 265.

Meade P, Mirocha J. Civilian landmine injuries in Sri Lanka. *J Trauma* 2000; **48**: 735 – 739.

Papadakis SA, Babourda EC, Mitsitskas TC, Markakidis S, Bachtis C, Koukouvis D, Tentes AA. Anti-personnel landmine injuries during peace: experience in a european country. *Prehosp Disast Med* 2006; **21**: 237 – 240.

Stover E, Keller AS, Cobey J, Sopheap S. The medical and social consequences of land mines in Cambodia. *JAMA* 1994; **272**: 331 – 336.

Woodmansey I, Maresca L. *The Silent Menace: Landmines in Bosnia and Herzegovina*. Geneva: ICRC and UNHCR; 1997.

#### Clinical studies

Adams DB, Schwab CW. Twenty-one-year experience with land mine injuries. *J Trauma* 1988; **28 (Suppl. 1)**: S159 – S162.

Arnson Y, Bar-Dayyan Y. Reducing landmine mortality rates in Iran using public medical education and rural rescue teams. What can be learned from landmine casualties, and how can the situation be improved? *Prehosp Disast Med* 2009; **24**: 130 – 132.

Coupland RM. Amputation for antipersonnel mine injuries of the leg: preservation of the tibial stump using a medial gastrocnemius myoplasty. *Ann R Coll Surg Engl* 1989; **71**: 405 – 408.

Coupland RM. Transfusion for war wounded: letter. *Br J Anaes* 1993; **71**: 172.

De Wind CM. Antipersonnel mine injuries in Somaliland: the pattern of injury. *Trop Doct* 1995; **25 (Suppl. 1)**: S52 – S53.

Eshaya-Chauvin B, Coupland R. M Transfusion for war wounded patients: the experience of the International Committee of the Red Cross. *Br J Anaes* 1992; **68**: 221 – 223.

Fasol R, Irvine S, Zilla P. Vascular injuries caused by anti-personnel mines. *J Cardiovasc Surg (Torino)* 1989; **30**: 467 – 472.

Grau LW, Jorgensen WA, Love RR. Guerrilla warfare and land mine casualties remain inseparable. *U.S. Army Medical Dept Journal* 1998; **October-December**. Available at: <http://fmso.leavenworth.army.mil/documents/guerwf.htm>.

Hayda R, Harris RM, Bass CD. Blast injury research: modelling injury effects of landmines, bullets, and bombs. *Clin Orthop Relat Res* 2004; **422**: 97 – 108.

Husum H, Gilbert M, Wisborg T, Heng YV, Murad M. Land mine injuries: a study of 708 victims in north Iraq and Cambodia. *Mil Med* 2003; **168**: 934 – 939.

Khan MT, Husain FN, Ahmed A. Hindfoot injuries due to landmine blast accidents. *Injury* 2002; **33**: 167 – 171.

Korver AJH. Amputees in a hospital of the International Committee of the Red Cross. *Injury* 1993; **24**: 607 – 609.

Korver AJH. Injuries of the lower limb caused by antipersonnel mines; experience of the International Committee of the Red Cross. *Injury* 1996; **27**: 477 – 479.

Morris D, Sugrue W, McKenzie E. At War: on the border of Afghanistan with the International Committee of the Red Cross. *NZ Med J* 1985; **98**: 750 – 752.

Muller A, Sherman R, Weiss J, Addison R, Carr D, Harden RN. Neurophysiology of pain from landmine injury. *Pain Med* 2006; **7 (Suppl.)**: S204 – S208.

Strada G: The horror of land mines. *Sci Am* 1996; **May**: 40 – 46.

Wiffen P, Maynadier J, Dubois M, Thurel C, deSmet J, Harden RN. Diagnostic and treatment issues in postamputation pain after landmine injury. *Pain Med* 2006; **7 (Suppl. 2)**: S209 – S212.

### Essential websites

E-mine: The electronic Mine Information Network (United Nations)

<http://www.mineaction.org>

Geneva International Center for Humanitarian Demining

<http://www.gichd.org>

International Campaign to Ban Landmines / Landmine Monitor

<http://www.icbl.org> / <http://www.lm.icbl.org>

International Committee of the Red Cross

<http://www.icrc.org/eng/mines>

## Part B

### Introduction

#### General references

Brown KV, Murray CK, Clasper JC. Infectious complications of combat-related mangled extremity injuries in the British military. *J Trauma* 2010; **69 (Suppl.)**: S109 – S115.

Clasper JC, Brown KV, Hill P. Limb complications following pre-hospital tourniquet use. *J R Army Med Corps* 2009; **155**: 200 – 202.

Coupland RM. Hand grenade injuries among civilians. *JAMA* 1993; **270**: 624 – 626.

Coupland RM. *War Wounds of Limbs: Surgical Management*. Oxford: Butterworth-Heinemann; 1993.

Covey DC. Blast and fragment injuries of the musculoskeletal system. *J Bone Joint Surg Am* 2002; **84**: 1221 – 1234.

Dougherty AL, Mohrle CR, Galarneau MR, Woodruff SI, Dye JL, Quinn KH. Battlefield extremity injuries in Operation Iraqi Freedom. *Injury* 2009; **40**: 772 – 777.

Eardley WGP, Brown KV, Bonner TJ, Green AD, Clasper JC. Infection in conflict wounded. *Phil Trans R Soc B* 2011; **366**: 204 – 218. [doi: 10.1098/rstb.2010.0225]

Fackler ML. Wound ballistics and soft-tissue wound treatment. *Tech Orthop* 1995; **10**: 163 – 170.

Guthrie HC, Clasper JC, Kay AR, Parker PJ, on behalf of the Limb Trauma and Wounds Working Groups, ADMST. Initial extremity war wound debridement: a multidisciplinary consensus. *J R Army Med Corps* 2011; **157**: 170 – 175.

Hill PF, Edwards DP, Bowyer GW. Small fragment wounds: biophysics, pathophysiology and principles of management. *J R Army Med Corps* 2001; **147**: 41 – 51.

Jackson DS. Soldiers injured during the Falklands campaign 1982: sepsis in soft tissue limb wounds. *J R Army Med Corps* 2007; **153 (Suppl.)**: S55 – S56.

Klenerman L. *The Tourniquet Manual – Principles and Practice*. London: Springer-Verlag Ltd; 2003.

Lerner A, Soudry M, eds. *Armed Conflict Injuries to the Extremities: A Treatment Manual*. Berlin; Springer-Verlag; 2011.

Mabry RL, Holcomb JB, Baker AM, Cloonan CC, Uhorchak JM, Perkins DE, Canfield AJ, Hagmann JH. United States Army Rangers in Somalia: an analysis of combat casualties on an urban battlefield. *J Trauma* 2000; **49**: 515 – 529.

Madenwald MB, Fisher RC. Experiences with war wounds in Afghanistan and Mozambique. *Tech Orthop* 1995; **10**: 231 – 237.

Murray CK, Wilkins K, Molter NC, Yun HC, Dubick MA, Spott MA, Jenkins D, Eastridge B, Holcomb JB, Blackburne LH, Hospenthal DR. Infections in combat casualties during Operations Iraqi and Enduring Freedom. *J Trauma* 2009; **66 (Suppl.)**: S138 – S144.

Shen-Gunther J, Ellison R, Kuhens C, Roach CJ, Jarrard S. Operation Enduring Freedom: trends in combat casualty care by forward surgical teams deployed to Afghanistan. *Mil Med* 2011; **176**: 67 – 78.

### Limb salvage

Akula M, Gella S, Shaw CJ, McShane P, Mohsen AM. A meta-analysis of amputation versus limb salvage in mangled lower limb injuries – the patient perspective. *Injury* 2011; **42**: 1194 – 1197.

Brown KV, Ramasamy A, McLeod J, Stapley S, Clasper JC. Predicting the need for early amputation in ballistic mangled extremity injuries. *J Trauma* 2009; **66 (Suppl.)**: S93 – S98.

Brown KV, Henman P, Stapley S, Clasper JC. Limb salvage of severely injured extremities after military wounds. *J R Army Med Corps* 2011; **157 (Suppl. 3)**: S315 – S323.

Doucet JJ, Galarneau MR, Potenza BM, Bansal V, Lee JG, Schwartz AK, Dougherty AL, Dye J, Hollingsworth-Fridlund P, Fortlage D, Coimbra R. Combat versus civilian open tibia fractures: the effect of blast mechanism on limb salvage. *J Trauma* 2011; **70**: 1241 – 1247.

Langworthy MJ, Smith JM, Gould M. Treatment of the mangled lower extremity after a terrorist blast injury. *Clin Orthop* 2004; **422**: 88 – 96.

Rajasekaran S. Ganga Hospital open injury severity score: a score to prognosticate limb salvage and outcome measures in type IIIb open tibial fractures. *Indian J Orthop* 2005; **39**: 4 – 13. Available at: <http://www.ijonline.com/text.asp?2005/39/1/4/36888>.

Rush RM Jr, Kjorstad R, Starnes BW, Arrington E, Devine JD, Andersen CA. Application of the Mangled Extremity Score in a combat setting. *Mil Med* 2007; **172**: 777 – 781.

### Damage-control orthopaedics

Andersen RC, Ursua VA, Valosen JM, Shawen SB, Davila JN, Baechler MF, Keeling JJ. Damage control orthopaedics: an in-theatre perspective. *J Surg Orthop Adv* 2010; **19**: 13 – 17.

### Wound irrigation and dressings

Anglen JO, Gainor BJ, Simpson WA, Christensen G. The use of detergent irrigation for musculoskeletal wounds. *Int Orthop* 2003; **27**: 40 – 46.

Anglen JO. Comparison of soap and antibiotic solutions for irrigation of lower limb fracture wounds: prospective, randomized study. *J Bone Joint Surg Am* 2005; **87**: 1415 – 1422.

Brown PW. Simplified wound lavage. *Tech Orthop* 1995; **10**: 154.

Chirife J, Scarmato G, Herszage L. Scientific basis for the use of granulated sugar in the treatment of infected wounds. *Lancet* 1982; **319 (8271)**: 560 – 561.

Cooper RA, Molan PC, Harding KG. Antibacterial activity of honey against strains of *Staphylococcus aureus* from infected wounds. *J R Soc Med* 1999; **92**: 283 – 285.

Cyr SJ, Hensley D, Benedetti GE. Treatment of field water with sodium hypochlorite for surgical irrigation. *J Trauma* 2004; **57**: 231 – 235.

FLOW Investigators. Fluid Lavage of Open Wounds (FLOW): a multicenter, blinded, factorial pilot trial comparing alternative irrigating solutions and pressures in patients with open fractures. *J Trauma* 2011; **71**: 596 – 606.

Lee DS; Sinno S, Khachemoune A. Honey and wound healing: an overview. *Am J Clin Dermatol* 2011; **12**: 181 – 190.

Mphande ANG, Killowe C, Phalira S, Wynn Jones H, Harrison WJ. Effects of honey and sugar dressings on wound healing. *J Wound Care* 2007; **16**: 317 – 319.

Nagoba B, Wadher B, Kulkarni P, Kolhe S. Acetic acid treatment of pseudomonal wound infections. *Eur J Gen Med* 2008; **5**: 104 – 106.

Salati SA, Rather A. Management of pseudomonal wound infection. *Internet J Surg* 2009; 20(1). Available at: [http://www.ispub.com/journal/the\\_internet\\_journal\\_of\\_surgery/volume\\_20\\_number\\_1\\_article/management-of-pseudomonal-wound-infection.html](http://www.ispub.com/journal/the_internet_journal_of_surgery/volume_20_number_1_article/management-of-pseudomonal-wound-infection.html).

Seal DV, Middleton K. Healing of cavity wounds with sugar. *Lancet* 1991; **338 (8766)**: 571 – 572.

Song JJ, Salcido R. Use of honey in wound care: an update. *Adv Skin Wound Care* 2011; **24**: 40 – 44.

### Topical negative pressure and vacuum dressing

Andreassen GS, Madsen JE. A simple and cheap method for vacuum-assisted wound closure. *Acta Orthop* 2006; **77**: 820 – 824.

Bui TD, Huerta S, Gordon IL. Negative pressure wound therapy with off-the-shelf components. *Am J Surg* 2006; **192**: 235 – 237.

Fagerdahl A-M, Boström L, Ulfvarson J, Ottosson C. Risk factors for unsuccessful treatment and complications with negative pressure wound therapy. *Wounds* 2012; **24**: 168 – 177.

Fries CA, Jeffery SLA, Kay AR. Topical negative pressure and military wounds – a review of the evidence. *Injury* 2011; **42**: 436 – 440.

Leininger BE, Rasmussen TE, Smith DL, Jenkins DH, Coppola C. Experience with wound VAC and delayed primary closure of contaminated soft tissue injuries in Iraq. *J Trauma* 2006; **61**: 1207 – 1211.

Rispoli DM, Horne BR, Kryzak TJ, Richardson MW. Description of a technique for vacuum-assisted deep drains in the management of cavitary defects and deep infections in devastating military and civilian trauma. *J Trauma* 2010; **68**: 1247 – 1252.

Runkel N, Krug E, Berg L, Lee C, Hudson D, Birke-Sorensen H, Depoorter M, Dunn R, Jeffery S, Duteille F, Bruhin A, Caravaggi C, Chariker M, Dowsett C, Ferreira F, Francos Martinez JM, Grudzien G, Ichioka S, Ingemansson R, Malmsjo M, Rome P, Vig S, Martin R, Smith J. (International Expert Panel on Negative Pressure Wound Therapy [NPWT-EP]). Evidence-based recommendations for the use of Negative Pressure Wound Therapy in traumatic wounds and reconstructive surgery: steps towards an international consensus. *Injury* 2011; **42 (Suppl.)**: S1 – S12.

### Crush injury

Bartels SA, VanRooyen MJ. Medical complications associated with earthquakes. *Lancet* 2012; **379**: 748 – 757.

Bowley DMG, Buchan C, Khulu L; Boffard KD. Acute renal failure after punishment beatings. *J R Soc Med* 2002; **95**: 300 – 301.

Hiss J, Kahana T, Kugel C. Beaten to death: why do they die? *J Trauma* 1996; **40**: 27 – 30.

Knottenbelt JD. Traumatic rhabdomyolysis from severe beating – experience of volume diuresis in 200 patients. *J Trauma* 1994; **37**: 214 – 219.

Malik GH, Reshi AR, Najar MS. Further observations on acute renal failure following physical torture. *Nephrol Dial Transplant* 1995; **10**: 198 – 202.

Reis ND, Michaelson M. Crush injury to the lower limbs. *J Bone Joint Surg Am* 1986; **68**: 414 – 418.

Smith WA, Hardcastle TC. A crushing experience: The spectrum and outcome of soft tissue injury and myonephropathic syndrome at an urban South African university hospital. *African J Emerg Med* 2011; **1**: 17 – 24.

Vanholder R, Sever MS, Ereke E, Lameire N. Rhabdomyolysis. *J Am Soc Nephrol* 2000; **11**: 1553 – 1561.

#### **Compartment syndrome and fasciotomy**

Chiverton N, Redden JF. A new technique for delayed primary closure of fasciotomy wounds. *Injury* 2000; **31**: 21 – 24.

Clasper JC, Standley D, Heppell S, Jeffrey S, Parker PJ. Limb compartment syndrome and fasciotomy. *J R Army Med Corps* 2009; **155**: 298 – 301.

Harrah J, Gates R, Carl J, Harrah JD. A simpler, less expensive technique for delayed primary closure of fasciotomies. *Am J Surg* 2000; **180**: 55 – 57.

Mbubaegbu CE, Stallard MC. A method of fasciotomy wound closure. *Injury* 1996; **27**: 613 – 615.

Middleton S, Clasper J. Compartment syndrome of the foot – implications for military surgeons. *J R Army Med Corps* 2010; **156**: 241 – 244.

Ojike NI, Roberts CS, Giannoudis PV. Compartment syndrome of the thigh: a systemic review. *Injury* 2010; **41**: 133 – 136.

Ritenour AE, Dorlac WC, Fang R, Woods T, Jenkins DH, Flaherty SF, Wade CE, Holcomb JB. Complications after fasciotomy revision and delayed compartment release in combat patients. *J Trauma* 2008; **64 (Suppl.)**: S153 – S162.

## **Chapter 22**

### **General references**

Brown PW. War wounds and the orthopaedic surgeon. *Tech Orthop* 1995; **10**: 301 – 305.

Coupland RN, Howell PR. An experience of war surgery and wounds presenting after 3 days on the border of Afghanistan. *Injury* 1988; **19**: 259 – 262.

Murphy RA, Ronat J-B, Fakhri RM, Herard P, Blackwell N, Abgrall S, Anderson DJ. Multi-drug resistant chronic osteomyelitis complicating war injury in Iraqi civilians. *J Trauma* 2011; **71**: 252 – 254.

Orr HW. The treatment of infected wounds without sutures, drainage tubes or antiseptic dressings. *J Bone Joint Surg Am* 1928; **10**: 605 – 611.

Richardson J, Hill AM, Johnston CJC, McGregor A, Norrish AR, Eastwood D, Lavy CBD. Fracture healing in HIV-positive populations. *J Bone Joint Surg Br* 2008; **90**: 988 – 994.

Rosell PAE, Clasper JC. Ballistic fractures – the limited value of existing classifications. *Injury* 2005; **36**: 369 – 372.

Rotman MB, Hoffer MM. Gunshot wounds: the lessons learned from recent wars / Sri Lanka experience. *Tech Orthop* 1995; **10**: 238 – 244.

Shanewise RP. Treatment of gunshot wounds in Ethiopia 1986 – 92. *Tech Orthop* 1995; **10**: 222 – 224.

Sundin JA. War surgery in Kigali, Rwanda: the role of the International Committee of the Red Cross. *Tech Orthop* 1995; **10**: 250 – 258.

Trueta J. *Treatment of War Wounds and Fractures with Special Reference to the Closed Method as Used in the War in Spain*. New York: Paul B. Hoeber Inc.; 1940. London: Hamish Hamilton Medical Books; 1942/39.

Uhorchak JM, Arciero RA. Recent wounds of war: lessons learned and relearned. *Tech Orthop* 1995; **10**: 176 – 188.



**Ballistics**

Clasper JC, Hill PF, Watkins PE. Contamination of ballistic fractures: an in vitro model. *Injury* 2002; **33**: 157 – 160.

Dougherty PJ, Sherman D, Dau N, Bir C. Ballistic fractures: indirect fracture to bone. *J Trauma* 2011; **71**: 1381 – 1384.

**Plaster-of-Paris**

Anderson LD, Hutchins WC, Wright PE, Disney JM. Fractures of the tibia and fibula treated by casts and transfixing pins. *Clin Orthop Relat Res* 1974; **105**: 179 – 191.

Brown PW. The early weight-bearing treatment of tibial shaft fractures. *Clin Orthop Relat Res* 1974; **105**: 167 – 178.

Dehne E; Metz CW; Deffer PA, Hall RM. Nonoperative treatment of the fractured tibia by immediate weight bearing. *J Trauma* 1961; **1**: 514 – 535.

Dehne E. Ambulatory treatment of the fractured tibia. *Clin Orthop Relat Res* 1974; **105**: 192 – 201.

Sarmiento A. A functional below-the-knee brace for tibial fractures: a report on its use in one hundred and thirty-five cases. *J Bone Joint Surg Am* 1970; **52**: 295 – 311. Reprinted in *J Bone Joint Surg Am* 2007; **89 (Suppl. 2, Part 2)**: 157 – 169.

Sarmiento A, Kinman PB, Galvin EG, Schmitt RH, Phillips JG. Functional bracing of fractures of the shaft of the humerus. *J Bone Joint Surg Am* 1977; **59**: 596 – 601.

**Traction**

Althausen PL, Hak DJ. Lower extremity traction pins: indications, technique, and complications. *Am J Orthop* 2002; **31**: 43 – 47.

Boyd MC, Mountain AJC, Clasper JC. Improvised skeletal traction in the management of ballistic femoral fractures. *J R Army Med Corps* 2009; **155**: 194 – 196.

Clasper JC, Rowley DI. Outcome, following significant delays in initial surgery, of ballistic femoral fractures managed without internal or external fixation. *J Bone Joint Surg Br* 2009; **91**: 97 – 101.

Rungee JL. Skeletal traction in the military field hospital. *Tech Orthop* 1995; **10**: 189 – 194.

**External fixation**

Camuso MR. Far-forward fracture stabilization: external fixation versus splinting. *J Am Acad Orthop Surg* 2006; **14 (Suppl.)**: S118 – S123.

Clasper JC, Phillips SL. Early failure of external fixation in the management of war injuries. *J R Army Med Corps* 2005; **151**: 81 – 86.

Coupland RM. War wounds of bones and external fixation. *Injury* 1994; **25**: 211 – 217.

Dubravko H, Žarko R, Tomislav T, Dragutin K, Vjenceslav N. External fixation in war trauma management of the extremities – experience from the war in Croatia. *J Trauma* 1994; **37**: 831 – 834.

Khan OH, Shaw DL. Over-the-counter pin site care: a novel approach. *Injury* 2009; **40**: 459 – 460.

Labeau F, Pasuch M, Toussaint P, Van Erps S. External fixation in war traumatology: report from the Rwandese War (October 1, 1990 to August 1, 1993). *J Trauma* 1996; **40 (Suppl.)**: S223 – S227.

McHenry T, Simmons S, Alitz C, Holcomb J. Forward surgical stabilization of penetrating lower extremity fractures: circular casting versus external fixation. *Mil Med* 2001; **166**: 791 – 795.

Possley DR, Burns TC, Stinner DJ, Murray CK, Wenke JC, Hsu JR, the Skeletal Trauma Research Consortium. Temporary external fixation is safe in a combat environment. *J Trauma* 2010; **69 (Suppl.)**: S135 – S139.

Rautio J, Paavolainen P. Delayed treatment of complicated fractures in war wounded. *Injury* 1987; **18**: 238 – 240.

Rowley DI. The management of war wounds involving bone. *J Bone Joint Surg Br* 1996; **78**: 706 – 709.

#### Internal fixation

Beech Z, Parker P. Internal fixation on deployment: never, ever, clever? *J R Army Med Corps* 2012. **158**: 4 – 5.

Bušić Ž, Lovrc Z, Amc E, Bušić V, Lovrc L, Markovc I. War injuries of the extremities: twelve-year follow-up data. *Mil Med* 2006; **171**: 55 – 57.

Clasper JC, Stapley SA, Bowley DMG, Kenward CE, Taylor V, Watkins PE. Spread of infection, in an animal model, after intramedullary nailing of an infected external fixator pin track. *J Orthop Res* 2001; **19**: 155 – 159.

Dougherty PJ, Silverton C, Yeni Y, Tashman S, Weir R. Conversion from temporary external fixation to definitive fixation: shaft fractures. *J Am Acad Orthop Surg* 2006; **14 (Suppl.)**: S124 – S127.

Furlong R, Clark MP. Missile wounds involving bone. *Br J Surg* 1948; **War Supplement No. II**: 291 – 310.

Hill PF, Clasper JC, Parker SJ, Watkins PE. Early intramedullary nailing in an animal model of a heavily contaminated fracture of the tibia. *J Orthop Res* 2002; **20**: 648 – 653.

Keeney JA, Ingari JV, Mentzer KD, Powell ET IV. Closed intramedullary nailing of femoral shaft fractures in an echelon III facility. *Mil Med* 2009; **174**: 124 – 128.

Rich NM, Metz CW, Hutton JE, Baugh JH, Hughes CW. Internal versus external fixation of fractures with concomitant vascular injuries in Vietnam. *J Trauma* 1971; **11**: 463 – 473.

#### Hands and feet

Bluman EM, Ficke JR, Covey DC. War wounds of the foot and ankle: causes, characteristics, and initial management. *Foot Ankle Clin* 2010; **15**: 1 – 21.

Brown PW. War wounds of the hand revisited. *J Hand Surg Am* 1995; **20 (Part 2)**: S61 – S67.

Burkhalter WE. Care of war injuries of the hand and upper extremity. Report of the War Injury Committee. *J Hand Surg Am* 1983; **8**: 810 – 813.

Nikolić D, Jovanović Z, Vulović R, Mladenović M. Primary surgical treatment of war injuries of the foot. *Injury* 2000; **31**: 193 – 197.

#### Bone reconstruction

Coupland RM. A management algorithm for chronically exposed war wounds of bone. *Injury* 1990; **21**: 101 – 103.

Goulet JA, Senunas LE, DeSilva GL, Freenfield M-L VH. Autogenous iliac crest bone graft. complications and functional assessment. *Clin Orthop Relat Res* 1997; **339**: 76–81.

Panagiotis M. Classification of non-union. *Injury* 2005; **36 (Suppl. 4)**: S30 – S37.

Sen MK, Miclau T. Autologous iliac crest bone graft: should it still be the gold standard for treating nonunions? *Injury* 2007; **38 (Suppl. 1)**: S75 – S80.

## Chapter 23

Amputation Surgery Education Center. *General Principles of Amputation Surgery*. Available at <http://www.ampsurg.org/html/fundopen.html>.

Coupland MR. Amputation for antipersonnel mine injuries of the leg-preservation of the tibial stump using a medial gastrocnemius myoplasty. *Ann R Coll Surg Engl* 1989; **17**: 405.

Doucet JJ, Galarneau MR, Potenza BM, Bansal V, Lee JG, Schwartz AK, Dougherty AL, Dye J, Hollingsworth-Fridlund P, Fortlage D, Coimbra R. Combat versus civilian open

tibia fractures: the effect of blast mechanism on limb salvage. *J Trauma* 2011; **70**: 1241 – 1247.

Irmay F, Merzouga B, Vettorel D. The Krukenberg procedure: a surgical option for the treatment of double hand amputees in Sierra Leone. *Lancet* 2000; **356**: 1072 – 1075.

Knowlton LM, Gosney JE Jr, Chackungal S, Altschuler E, Black L, Burkle FM Jr, Casey K, Crandell D, Demey D, Di Giacomo L, Dohlman L, Goldstein J, Gosselin R, Ikeda K, Le Roy A, Linden A, Mullaly CM, Nickerson J, O'Connell C, Redmond AD, Richards A, Rufsvold R, Santos ALR, Skelton T, McQueen K. Consensus statements regarding the multidisciplinary care of limb amputation patients in disasters or humanitarian emergencies: report of the 2011 Humanitarian Action Summit Surgical Working Group on Amputations Following Disasters or Conflict. *Prehosp Disast Med* 2011; **26**: 438 – 448. [doi:10.1017/S1049023X12000076]

Rush RM Jr, Kjorstad R, Starnes BW, Arrington E, Devine JD, Andersen CA. Application of the Mangled Extremity Severity Score in a combat setting. *Mil Med* 2007; **172**: 777 – 781.

Simmons JD, Schmiegl RE, Porter JM, D'Souza SE, Duchesne JC, Mitchell ME. Brachial artery injuries in a rural catchment trauma center: are the upper and lower extremity the same? *J Trauma* 2008; **65**: 327 – 330.

Simper LB. Below knee amputation in war surgery: a review of 111 amputations with delayed primary closure. *J Trauma* 1993; **34**: 96 – 98.

Smith DG, Michael JW, Bowker JH. *Atlas of Amputations and Limb Deficiencies*. Rosemont, IL: American Academy of Orthopaedic Surgeons; 2004.

Stansbury LG, Lalliss SJ, Branstetter JG, Bagg MR, Holcomb JB. Amputations in U.S. military personnel in the current conflicts in Afghanistan and Iraq. *J Orthop Trauma* 2008; **22**: 43 – 46.

Stinner DJ, Burns TC, Kirk KL, Scoville CR, Ficke JR, Hsu JR, Late Amputation Study Team (LAST). Prevalence of late amputations during the current conflicts in Afghanistan and Iraq. *Mil Med* 2010; **175**: 1027 – 1029.

Tintle SM, Keeling JJ, Shawen SB, Forsberg JA, Potter BK. Traumatic and trauma-related amputations. Part I: General principles and lower-extremity amputations. *J Bone Joint Surg Am* 2010; **92**: 2852 – 2868.

## Chapter 24

Amato JJ, Rich NM, Billy LJ, Gruber RP, Lawson NS. High-velocity arterial injury: a study of the mechanism of injury. *J Trauma* 1971; **11**: 412 – 416.

Brown KV, Ramasamy A, Tai N, McLeod J, Midwinter M, Clasper JC. Complications of extremity vascular injuries in conflict. *J Trauma* 2009; **66 (Suppl.)**: S145 – S149.

Dajani OM, Haddad FF, Hajj HA, Sfeir RE, Khoury GS. Injury to the femoral vessels – the Lebanese War experience. *Eur J Vasc Surg* 1988; **2**: 293 – 296.

Dar AM, Ahanger AG, Wani RA, Bhat MA, Lone GN, Shah SH. Popliteal artery injuries: the Kashmir experience. *J Trauma* 2003; **55**: 362 – 365.

de Silva WDD, Ubayasiri RA, Weerasinghe CW, Wijeyaratne SM. Challenges in the management of extremity vascular injuries: a wartime experience from a tertiary centre in Sri Lanka. *World J Emerg Surg* 2011; **6**: 24. Available at: <http://www.wjes.org/content/6/1/24>.

Dragas M, Davidovic L, Kostic D, Markovic M, Pejic S, Ille T, Ilic N, Koncar I. Upper extremity arterial injuries: factors influencing treatment outcome. *Injury* 2009; **40**: 815 – 819.

Fowler J, MacIntyre N, Rehman S, Gaughan JP, Leslie S. The importance of surgical sequence in the treatment of lower extremity injuries with concomitant vascular injury: a meta-analysis. *Injury* 2009; **40**: 72 – 76.

- Hafez HM, Woolgar J, Robbs JV. Lower extremity arterial injury: results of 550 cases and review of risk factors associated with limb loss. *J Vasc Surg* 2001; **33**: 1212 – 1219.
- Hughes CW. Arterial repair during the Korean War. *Ann Surg* 1958; **147**: 555 – 561.
- Leppäniemi AK, Rich NM. Treatment of vascular injuries in war wounds of the extremities. *Tech Orthop* 1995; **10**: 265 – 271.
- Levin PM, Rich NM, Hutton JE Jr. Collateral circulation in arterial injuries. *Arch Surg* 1971; **102**: 392 – 399.
- Lovrić Z, Wertheimer B, Candrić K, Kuvezdić H, Lovrić I, Medarić D, Janosi K. War injuries of major extremity vessels. *J Trauma* 1994; **36**: 248 – 251.
- Miller KR, Bennis MV, Sciarretta JD, Harbrecht BG, Ross CB, Franklin GA, Smith JW. The evolving management of venous bullet emboli: a case series and literature review. *Injury* 2011; **42**: 441 – 446.
- Nanobashvili J, Kopadze T, Tvaladze M, Buachidze T, Nazvlshvili G. War injuries of major extremity arteries. *World J Surg* 2003; **27**: 134 – 139.
- Peck MA, Clouse WD, Cox MW, Bowser AN, Eliason JL, Jenkins DH, Smith DL, Rasmussen TE. The complete management of extremity vascular injury in a local population: a wartime report from the 332nd Expeditionary Medical Group/Air Force Theater Hospital, Balad Air Base, Iraq. *J Vasc Surg* 2007; **45**: 1197 – 1205.
- Quan RW, Gillespie DL, Stuart RP, Chang AS, Whittaker DR, Fox CJ. The effect of vein repair on the risk of venous thromboembolic events : a review of more than 100 traumatic military venous injuries. *J Vasc Surg* 2008; **47**: 571 – 577.
- Rich NM, Baugh JH, Hughes CW. Acute arterial injuries in Vietnam: 1,000 cases. *J Trauma* 1970; **10**: 359 – 369.
- Rich NM, Collins GJ Jr, Andersen CA, McDonald PT, Kozloff L, Ricotta JJ. Missile emboli. *J Trauma* 1978; **18**: 236 – 239.
- Rich NM, Leppäniemi A. Vascular trauma: a 40-year experience with extremity vascular emphasis. *Scand J Surg* 2002; **91**: 109 – 126.
- Roostar L. Treatment plan used for vascular injuries in the Afghanistan war. *Cardiovasc Surg* 1995; **1**: 42 – 45.
- Roostar L. *Gunshot Vascular Injuries*. Tartu, Estonia: OÜ Tartumaa; 1999.
- Schramek A, Hashmonai M. Vascular injuries in the extremities in battle casualties. *Br J Surg* 1977; **64**: 644 – 648.
- Shackford SR, Rich NM. Peripheral Vascular Injury. In: Mattox KL, Feliciano DV, Moore EE, eds. *Trauma, 4th ed*. New York: McGraw Hill; 2000: 1011 – 1044.
- Stannard A, Brown K, Benson C, Clasper J, Midwinter M, Tai NR. Outcome after vascular trauma in a deployed military trauma system. *Br J Surg* 2011; **98**: 228 – 234.
- Starnes BW, Beekley AC, Sebesta JA, Andersen CA, Rush RM Jr. Extremity vascular injuries on the battlefield: tips for surgeons deploying to war. *J Trauma* 2006; **60**: 432 – 442.
- Yılmaz AT, Arslan M, Demirkiliç U, Özal E, Kuralay E, Tatar H, Öztürk ÖY. Missed arterial injuries in military patients. *Am J Surg* 1997; **173**: 110 – 114.

#### Temporary vascular shunt

- Borut J, Acosta JA, Tadlock M, Dye JL, Galarneau M, Elshire D. The use of temporary vascular shunts in military extremity wounds: a preliminary outcome analysis with 2-year follow-up. *J Trauma* 2010; **69**: 174 – 178.
- Chambers LW, Green DJ, Sample K, Gillingham BL, Rhee P, Brown C, Narine N, Uecker JM, Bohman JR. Tactical surgical intervention with temporary shunting of peripheral vascular trauma sustained during Operation Iraqi Freedom: one unit's experience. *J Trauma* 2006; **61**: 824 – 830.

Ding W, Wu X, Li J. Temporary intravascular shunts used as a damage control surgery adjunct in complex vascular injury: collective review. *Injury* 2008; **39**: 970 – 977.

Gifford SM, Aidinian G, Clouse WD, Fox CJ, Porras CA, Jones WT, Zarzabal L-A, Michalek JE, Propper BW, Burkhardt GE, Rasmussen TE. Effect of temporary shunting on extremity vascular injury: an outcome analysis from the Global War on Terror vascular injury initiative. *J Vasc Surg* 2009; **50**: 549 – 556.

Granchi T, Schmittling Z, Vasquez J Jr, Schreiber M, Wall M. Prolonged use of intraluminal arterial shunts without systemic anticoagulation. *Am J Surg* 2000; **180**: 493 – 497.

Rasmussen TE, Clouse WD, Jenkins DH, Peck MA, Eliason JL, Smith DL. The use of temporary vascular shunts as a damage control adjunct in the management of wartime vascular injury. *J Trauma* 2006; **61**: 8 – 15.

Taller J, Kamdar JP, Green JA, Morgan RA, Blankenship CL, Dabrowski P, Sharpe RP. Temporary vascular shunts as initial treatment of proximal extremity vascular injuries during combat operations: the new standard of care at Echelon II facilities? *J Trauma* 2008; **65**: 595 – 603.

## Chapter 25

Friedman AH. An eclectic review of the history of peripheral nerve surgery. *Neurosurgery* 2009; **65 (Suppl. 4)**: A3 – A8.

Gousheh J. The treatment of war injuries of the brachial plexus. *J Hand Surg Amer* 1995; **20 (Suppl.)**: S68 – S76.

Hamdan TA. Missed injuries in casualties from the Iraqi-Iranian war: a study of 35 cases. *Injury* 1987; **18**: 15 – 17.

Jebara VA, Sadde B. Causalgia: A war time experience – report of twenty treated cases. *J Trauma* 1987; **27**: 519 – 524.

Roganovic Z, Mandic-Gajic G. Pain syndromes after missile-caused peripheral nerve lesions: Part 1 – Clinical Characteristics. *Neurosurgery* 2006; **59**: 1226 – 1237.

Roganovic Z, Mandic-Gajic G. Pain syndromes after missile-caused peripheral nerve lesions: Part 2 – Treatment. *Neurosurgery* 2006; **59**: 1238 – 1251.

Samardzic MM, Rasulic LG, Grujicic DM. Gunshot injuries to the brachial plexus. *J Trauma* 1997; **43**: 645 – 649.

Stanec S, Tonković I, Stanec Z, Tonković D, Džepina I. Treatment of upper limb nerve war injuries associated with vascular trauma. *Injury* 1997; **28**: 463 – 468.

Vrebalov-Cindro V, Reic P, Ognjenovic M, Jankovic S, Andelinovic S, Karelovic D, Kapural L, Rakic M, Primorac D. Peripheral nerve war injuries. *Mil Med* 1999; **164**: 351 – 352.

## Part C

### Introduction

Breeze J, Gibbons AJ, Shieff C, Banfield G, Bryant DG, Midwinter MJ. Combat-related craniofacial and cervical injuries: a 5-year review from the British military. *J Trauma* 2011; **71**: 108 – 113.

Petersen K, Hayes DK, Blice JP, Hale RG. Prevention and management of infections associated with combat-related head and neck injuries. *J Trauma* 2008; **64 (Suppl.)**: S265 – S276.

## Chapter 26

### Working with limited resources

Coupland RM, Pesonen PE. Craniocerebral war wounds: non-specialist management. *Injury* 1992; **23**: 21 – 24.

Coutts A. Chewing gum for extradural haemorrhage. *BMJ* 1998; **317**: 1687.

Dumurgier C, Teisserenc J-Y, Jancovici R. Note sur les plaies crânio-cérébrales par projectiles de guerre au cours du conflit tchadien. [Note on cranio-cerebral wounds due to projectiles during the conflict in Chad.] *Bordeaux Médical* 1983; **16**: 841 – 844.

Newcombe R, Merry G. The management of acute neurotrauma in rural and remote locations: a set of guidelines for the care of head and spinal injuries. *J Clin Neurosci* 1996; **6**: 85 – 93.

Rosenfeld JV, Watters DAK. *Neurosurgery in the Tropics: A Practical Approach to Common Problems*. London: MacMillan; 2001.

Schechter WP, Peper E, Tuatoo V. Can general surgery improve the outcome of the head-injury victim in rural America? A review of the experience in American Samoa. *Arch Surg*. 1985; **120**: 1163 – 1166.

Simpson DA, Heyworth JS, McLean AJ, Gilligan JE, North JB. Extradural haemorrhage: strategies for management in remote places. *Injury* 1988; **19**: 307 – 312.

Treacy PJ, Reilly P, Brophy B. Emergency neurosurgery by general surgeons at a remote major hospital. *ANZ J Surg* 2005; **75**: 852 – 857.

### General references

Aarabi B. Surgical outcome in 435 patients who sustained missile head wounds during the Iran-Iraq war. *Neurosurgery* 1990; **27**: 692 – 695.

Abdul-Wahid T. Analysis of 500 penetrating high velocity missile wounds of the brain. *Médecine Militaire* 1985; **4**: 85 – 88.

Ameen AA. The management of acute craniocerebral injuries caused by missiles: analysis of 110 consecutive penetrating wounds of the brain from Basrah. *Injury* 1984; **16**: 88 – 90.

Amirjamshidi A, Abbassioun K, Rahmat H. Minimal debridement or simple wound closure. *Surg Neurol* 2003; **60**: 105 – 111.

Bell RS, Vo AH, Neal CJ, Tigno J, Roberts R, Mossop C, Dunne JR, Armonda RA. Military traumatic brain and spinal column injury: a 5-year study of the impact blast and other military grade weaponry on the central nervous system. *J Trauma* 2009; **66 (Suppl.)**: S104 – S111.

Brain Trauma Foundation, American Association of Neurological Surgeons, Congress of Neurological Surgeons, Joint Section on Neurotrauma and Critical Care. Guidelines for the management of severe traumatic brain injury 3rd ed. *J Neurotrauma* 2007; **24 (Suppl.)**: S1 – S106.

Brandvold B, Levi L, Feinsod M, George ED. Penetrating craniocerebral injuries in the Israeli involvement in the Lebanese conflict, 1982 – 1985: analysis of a less aggressive approach. *J Neurosurg* 1990; **72**: 15 – 21.

Carey ME, Sarna GS, Farrell JB, Happel LT. Experimental missile wounds to the brain. *J Neurosurg* 1989; **71**: 754 – 764.

Carey ME. The treatment of wartime brain wounds: traditional versus minimal debridement. *Surg Neurol* 2003; **60**: 112 – 119.

Chaudhuri K, Malham GM, Rosenfeld JV. Survival of trauma patients with coma and bilateral fixed dilated pupils. *Injury* 2009; **40**: 28 – 32.

Copley IB. Cranial tangential gunshot wounds. *Br J Neurosurg* 1991; **5**: 43 – 53.

Dodge PR, Meierowsky AM. Tangential wounds of the scalp and skull. *J Neurosurg* 1952; **9**: 472 – 483.

DuBose JJ, Barmparas G, Inaba K, Stein DM, Scalea T, Cancio LC, Cole J, Eastridge B, Blackbourne L. Isolated severe traumatic brain injuries during combat operations:

demographics, mortality outcomes, and lessons to be learned from contrasts to civilian counterparts. *J Trauma* 2011; **70**: 11 – 18.

Galarneau MR, Woodruff SI, Dye JL, Mohrle CR, Wade AL. Traumatic brain injury during Operation Iraqi Freedom: findings from the United States Navy–Marine Corps Combat Trauma Registry. *J Neurosurg* 2008; **108**: 950 – 957.

Haddad FS. Nature and management of penetrating head injuries during the civil war in Lebanon. *Can J Surg* 1978; **21**: 233 – 240.

Haddad FS. Penetrating missile head injuries: personal experiences during the Lebanese conflict. *Neurosurg Quart* 2002; **12**: 299 – 306.

Hanieh A. Brain injury from a spent bullet descending vertically. Report of five cases. *J Neurosurg* 1971; **34**: 222 – 224.

Knuth T, Letarte PB, Ling G, Moores LE, Rhee P, Tauber D, Trask A. *Guidelines for Field Management of Combat-Related Head Trauma*. New York, NY: Brain Trauma Foundation; 2005.

Liebenberg WA, Demetriades AK, Hankins M, Hardwidge C, Hartzenberg BH. Penetrating civilian craniocerebral gunshot wounds: a protocol of delayed surgery. *Neurosurg* 2005; **57**: 293 – 299.

Marcikic M, Melada A, Kovacevic R. Management of war penetrating craniocerebral injuries during the war in Croatia. *Injury* 1998; **29**: 613 – 618.

Rosenfeld JV. Gunshot injury to the head and spine. *J Clin Neurosci* 2002; **9**: 9 – 16.

Rosenfeld JV. Damage control neurosurgery. *Injury* 2004; **35**: 655 – 660.

Taha JM, Saba MI, Brown JA. Missile injuries to the brain treated by simple wound closure: results of a protocol during the Lebanese conflict. *Neurosurgery* 1991; **29**: 380 – 383.

### Infection

Aarabi B. Causes of infections in penetrating head wounds in the Iran – Iraq war. *Neurosurgery* 1989; **25**: 923 – 926.

Aarabi B, Taghipour M, Alibai E, Kamgarpour A. Central nervous system infections after military missile head wounds. *Neurosurgery* 1998; **42**: 500 – 509.

Gönül E, Baysefer A, Kahraman S, Çiklatekerlioğlu Ö, Gezen F, Yayla O, Seber N. Causes of infections and management results in penetrating craniocerebral injuries. *Neurosurg Rev* 1997; **20**: 177 – 181.

Splavski B, Šišljagić V, Perić LJ, Vranković Dj, Ebling Z. Intracranial infection as a common complication following war missile skull base injury. *Injury* 2000; **31**: 233 – 237.

Taha JM, Haddad FS, Brown JA. Intracranial infection after missile injuries to the brain: report of 30 cases from the Lebanese conflict. *Neurosurgery* 1991; **29**: 864 – 868.

Wortmann GW, Valadka AB, Moores LE. Prevention and management of infections associated with combat-related central nervous system injuries. *J Trauma* 2008; **64 (Suppl.)**: S252 – S256.

### CSF fistulas

Management of cerebrospinal fluid leaks. Guidelines. *J Trauma* 2001; **51 (Suppl.)**: S29 – S33.

Meirowsky AM, Caveness WF, Dillon JD, Rish BL, Mohr JP, Kistler JP, Weiss GH. Cerebrospinal fluid fistulas complicating missile wounds of the brain. *J Neurosurg* 1981; **54**: 44 – 48.

### Epilepsy

Aarabi B, Taghipour M, Gahdar AH, Farokhi M, Mobley L. Prognostic factors in the occurrence of posttraumatic epilepsy after penetrating head injury suffered during military service. *Neurosurg Focus* 2000; **8 (1)**: 1 – 6. Available at: <http://thejns.org/doi/pdf/10.3171/foc.2000.8.1.155>.

Eftekhari B, Sahraian MA, Nouralishahi B, Khaji A, Vahabi Z, Ghodsi M, Araghizadeh H, Soroush MR, Karbalaie Esmaili S, Masoumi M. Prognostic factors in the persistence of posttraumatic epilepsy after penetrating head injuries sustained in war. *J Neurosurg* 2009; **110**: 319 – 326.

Salazar AM, Jabbari B, Vance SC, Grafman J, Amin D, Dillon JD. Epilepsy after penetrating head injury. I. Clinical correlates: a report of the Vietnam Head Injury Study. *Neurology* 1985; **35**: 1406 – 1414.

## Chapter 27

Adeyemo WL, Iwegbu IO, Bello SA, Okoturo E, Olaitan AA, Ladeinde AL, Ogunlewe MO, Adepoju AA, Taiwo OA. Management of mandibular fractures in a developing country: a review of 314 cases from two urban centers in Nigeria. *World J Surg* 2008; **32**: 2631 – 2635.

Akhlaghi F, Aframian-Farnad F. Management of maxillofacial injuries in the Iran-Iraq war. *J Oral Maxillofac Surg* 1997; **55**: 927 – 930.

Breeze J, Monaghan AM, Williams MD, Clark RNW, Gibbons AJ. Five months of surgery in the Multinational Field Hospital in Afghanistan with an emphasis on oral and maxillofacial injuries. *J R Army Med Corps* 2010; **156**: 125 – 128.

Demetriades D, Chahwan S, Gomez H, Falabella A, Velmahos G, Yamashita D. Initial evaluation and management of gunshot wounds to the face. *J Trauma* 1998; **45**: 39 – 41.

Gibbons AJ, Patton DW. Ballistic injuries of the face and mouth in war and civil conflict. *Dent Update* 2003; **30**: 272 – 278.

Gibbons AJ, Mackenzie N. Lessons learned in oral and maxillofacial surgery from British military deployments in Afghanistan. *J R Army Med Corps* 2010; **156**: 110 – 113.

Ivanovic A, Nebosja J, Vukelic-Markovic S. Frontoethmoidal fractures as a result of war injuries. *J Trauma* 1996; **40 (Suppl.)**: S177 – S179.

Mabry RL, Edens JW, Pearse L, Kelly JF, Harke H. Fatal airway injuries during Operation Enduring Freedom and Operation Iraqi Freedom. *Prehosp Emerg Care* 2010; **14**: 272 – 277.

Motamedi MH. Primary treatment of penetrating injuries to the face. *J Oral Maxillofac Surg* 2007; **65**: 1215 – 1218.

Petersen K, Hayes DK, Blice JP, Hale RG. Prevention and management of infections associated with combat-related head and neck injuries. *J Trauma* 2008; **64 (Suppl.)**: S265 – S276.

Powers DB. Distribution of civilian and military maxillofacial surgical procedures performed in an air force theatre hospital: implications for training and readiness. *J R Army Med Corps* 2010; **156**: 117 – 121.

Puzović D, Konstantinović VS, Dimitrijević M. Evaluation of maxillofacial weapon injuries: 15-year experience in Belgrade. *J Craniofac Surg* 2004; **15**: 543 – 546.

Reed BE, Hale RG. Training Australian military health care personnel in the primary care of maxillofacial wounds from improvised explosive devices. *J R Army Med Corps* 2010; **156**: 117 – 121.

Rezende-Neto J, Marques AC, Guedes LJ, Teixeira LC. Damage control principles applied to penetrating neck and mandibular injury. *J Trauma* 2008; **64**: 1142 – 1143.

Rustemeyer J, Kranz V, Bremerich A. Injuries in combat from 1982-2005 with particular reference to those to the head and neck: a review. *Br J Oral Maxillofac Surg* 2007; **45**: 556 – 560.

Shelton DW. Management of maxillofacial injuries in the Iran-Iraq war. Discussion. *J Oral Maxillofac Surg* 1997; **55**: 930 – 931.

Shuker ST, Satta R. Craniomaxillofacial falling bullet injuries and management. *J Oral Maxillofac Surg* 2010; **68**: 1593 – 1601.



Shuker ST. Maxillofacial air-containing cavities, blast implosion injuries, and management. *J Oral Maxillofac Surg* 2010; **68**: 93 – 100.

Sollmann W-P, Seifert V, Haubitz B, Dietz H. Combined orbito-frontal injuries. *Neurosurg Rev* 1989; **12**: 115 – 121.

Ueek BA. Penetrating injuries to the face: delayed versus primary treatment – considerations for delayed treatment. *J Oral Maxillofac Surg* 2007; **65**: 1209 – 1214.

Zaytoun GM, Shikhani AH, Salman SD. Head and neck war injuries: 10-year experience at the American University of Beirut Medical Center. *Laryngoscope* 1986; **96**: 899 – 903.

## Chapter 28

Garth RJN. Blast injury of the ear: an overview and guide to management. *Injury* 1995; **26**: 363 – 366.

Kluger Y, Peleg K, Daniel-Aharonson L, Mayo A, Israeli Trauma Group. The special injury pattern in terrorist bombings. *J Am Coll Surg* 2004; **199**: 875 – 879.

Okpala N. Management of blast ear injuries in mass casualty environments. *Mil Med* 2011; **176**: 1306 – 1310.

Ritenour AE, Wickley A, Ritenour JS, Kriete BR, Blackburne LH, Holcomb JB, Wade CE. Tympanic membrane perforation and hearing loss from blast overpressure in Operation Enduring Freedom and Operation Iraqi Freedom wounded. *J Trauma* 2008; **64 (Suppl.)**: S174 – S178.

## Chapter 29

Albert DM, Diaz-Rohena R. A historical review of sympathetic ophthalmia and its epidemiology. *Surv Ophthalmol* 1989; **34**: 1 – 14.

Ansell MJ, Breeze J, McAlister VC, Williams MD. Management of devastating ocular trauma – experience of maxillofacial surgeons deployed to a forward field hospital. *J R Army Med Corps* 2010; **156**: 106 – 109.

Ben Simon GJ, Moisseiev J, Rosen N, Alhalel A. Gunshot wound to the eye and orbit: a descriptive case series and literature review. *J Trauma* 2011; **71**: 771 – 778.

Biehl J, Biehl JW, Valdez J, et al. Penetrating eye injury in war. *Mil Med* 1999; **164**: 780 – 784.

Blanch RJ, Scott RAH. Military ocular injury: presentation, assessment and management. *J R Army Med Corps* 2009; **155**: 279 – 284.

Cho RI, Bakken HE, Reynolds ME, Schlifka BA, Powers DB. Concomitant cranial and ocular combat injuries during Operation Iraqi Freedom. *J Trauma* 2009; **67**: 516 – 520.

Gönül E, Erdoğan E, Taşar M, Yetişer S, Akay KM, Düz B, Bedük B, Timurkaynak E. Penetrating orbitocranial gunshot injuries. *Surg Neurol* 2005; **63**: 24 – 31.

Heinemann MH, Coleman DJ. Chapter 38: Eye. In: Ivatury RR, Cayten CG, eds. *The Textbook of Penetrating Trauma*. Media, PA: Williams & Wilkins; 1996: 471 – 477.

Janković S, Buca A, Busić Z, Zuljan I, Primorac D. Orbitocranial war injuries: report of 14 cases. *Mil Med* 1998; **163**: 490 – 493.

Mader TH, Carroll RD, Slade CS, George RK, Ritchey JP, Neville SP. Ocular war injuries of the Iraqi insurgency January – September 2004. *Ophthalmology* 2006; **113**: 97 – 104.

Mines M, Thach A, Mallonee S, Hildebrand L, Shariat S. Ocular injuries sustained by survivors of the Oklahoma City bombing. *Ophthalmology* 2000; **107**: 837 – 843.

Perry M, Dancey A, Mireskandari K, Oakley P, Davies S, Cameron M. Emergency care in facial trauma – a maxillofacial and ophthalmic perspective. *Injury* 2005; **36**: 875 – 896.

Scott RAH. Eyes. In: Brooks AJ, Clasper J, Midwinter MJ, Hodgetts TJ, Mahoney PF, eds. *Ryan's Ballistic Trauma*. London: Springer-Verlag; 2011.

Shuker ST. Management of transcranial orbital penetrating shrapnel/bullet war injuries. *J Maxillofac Surg* 2008; **66**: 1927 – 1931.

Thach AB, Johnson AJ, Carroll RB, Huchun A, Ainbinder DJ, Stutzman RD, Blaydon SM, DeMartelaere SL, Mader TH, Slade CS, George RK, Ritchey JP, Barnes SD, Fannin LA. Severe eye injuries in the war in Iraq, 2003 – 2005. *Ophthalmology* 2008; **115**: 377 – 382.

du Toit N, Motala MI, Richards J, Murray ADN, Maitra S. The risk of sympathetic ophthalmia following evisceration for penetrating globe injuries at Groote Schuur Hospital. *Br J Ophthalmol* 2008; **92**: 61 – 63.

## Chapter 30

Asensio JA, Chahwan S, Forno W, et al. Penetrating oesophageal injuries: multicenter study of the American Association for the Surgery of Trauma. *J Trauma* 2001; **50**: 289 – 296.

Breeze J, Gibbons AJ, Shieff C, Banfield G, Bryant DG, Midwinter MJ. Combat-related craniofacial and cervical injuries: a 5-year review from the British military. *J Trauma* 2011; **71**: 108 – 113.

Breeze J, Allanson-Bailey LS, Hunt NC, Delaney RS, Hepper AE, Clasper J. Mortality and morbidity from combat neck injury. *J Trauma* 2012; **72**: 969 – 974.

Bonanno FG. Techniques for emergency tracheostomy. *Injury* 2008; **39**: 375 – 378.

Borgstrom D, Weigelt JA. Chapter 39 Neck: Aerodigestive Tract. In: Ivatury RR, Cayten CG, eds. *The Textbook of Penetrating Trauma*. Media, PA: Williams & Wilkins; 1996: 479 – 487.

Demetriades D, Velmahos GG, Asensio JA. Cervical pharyngoesophageal and laryngotracheal injuries. *World J Surg* 2001; **25**: 1044 – 1048.

Gilyoma JM, Balumuka DD, Chalya PL. Ten-year experiences with tracheostomy at a university teaching hospital in northwestern Tanzania: A retrospective review of 214 cases. *World J Emerg Surg* 2011; **6**: 38. Available at: <http://www.wjes.org/content/6/1/38>.

Golueke P, Sclafani S, Phillips T, Goldstein A, Scalea T, Duncan A. Vertebral artery injury – diagnosis and management. *J Trauma* 1987; **27**: 856 – 864.

Hirshberg A, Wall MJ, Johnston RH Jr, Burch JM, Mattox KL. Transcervical gunshot injuries. *Am J Surg* 1994; **167**: 309 – 312.

Jacobson LE, Gomez GA. Chapter 22 Neck. In: Ivatury RR, Cayten CG, eds. *The Textbook of Penetrating Trauma*. Media, PA: Williams & Wilkins; 1996: 258 – 271.

Ledgerwood AM, Mullins RJ, Lucas CE. Primary repair vs ligation for carotid artery injuries. *Arch Surg* 1980; **115**: 488 – 493.

Ledgerwood AM, Lucas CE. Chapter 40 Neck: Vessels. In: Ivatury RR, Cayten CG, eds. *The Textbook of Penetrating Trauma*. Media, PA: Williams & Wilkins; 1996: 488 – 497.

Moeng S, Boffard K. Penetrating neck injuries. *Scand J Surg* 2002; **91**: 34 – 40.

Mwipatayi BP, Jeffery P, Beningfield SJ, Motale P, Tunnicliffe J, Navsaria PH. Management of extra-cranial vertebral artery injuries. *Eur J Vasc Endovasc Surg* 2004; **27**: 157 – 162.

Ordog GJ. Penetrating neck trauma. *J Trauma* 1987; **27**: 543 – 554.

Richardson R, Obeid FN, Richardson JD, Hoyt DB, Wisner DH, Gomez GA, Johansen K, McSwain NE Jr, Weigelt JA, Blaisdell FW. Neurologic consequences of cerebrovascular injury. *J Trauma* 1992; **32**: 755 – 758.

Sheely CH II, Mattox KL, Beall AC, DeBakey ME. Penetrating wounds of the cervical oesophagus. *Am J Surg* 1975; **130**: 707 – 711.

du Toit DF, van Schalkwyk GD, Wade SA, Warren BL. Neurologic outcome after penetrating extracranial arterial trauma. *J Vasc Surg* 2003; **38**: 257 – 262.

Walsh MS. The management of penetrating injuries of the anterior triangle of the neck. *Injury* 1994; **25**: 393 – 395.

## Part D

### Introduction

Barker P. Penetrating wounds of the torso. *J R Army Med Corps* 2001; **147**: 62 – 72.

Conger NG, Landrum ML, Jenkins DH, Martin RR, Dunne JR, Hirsch EF. Prevention and management of infections associated with combat-related thoracic and abdominal cavity injuries. *J Trauma* 2008; **64 (Suppl.)**: S257 – S264.

Degiannis E, Benn C-A, Leandros E, Goosen J, Boffard K, Saadia R. Transmediastinal gunshot injuries. *Surgery* 2000; **128**: 54 – 58.

Renz BM, Cava RA, Feliciano DV, Rozycki GS. Transmediastinal gunshot wounds: a prospective study. *J Trauma* 2000; **48**: 416 – 422.

## Chapter 31

### General references

Bastos R, Baisden CE, Harker L, Calhoun JH. Penetrating thoracic trauma. *Semin Thorac Cardiovasc Surg* 2008; **20**: 19 – 25.

Biočina B, Sutlić Ž, Husedžinović I, Rudež I, Ugljen R, Letica D, Slobodnjak Z, Karadža J, Brida V, Vladović-Relja T, Jelić I. Penetrating cardiothoracic war wounds. *Eur J Cardiothorac Surg* 1997; **11**: 399 – 405.

Demetriades D, Velmahos GC. Penetrating injuries of the chest: indications for operation. *Scand J Surg* 2002; **91**: 41 – 45.

Duhamel P, Bonnet PM, Pons F, Jourdan P, Jancovici R. Traumatismes balistiques du thorax. Agents vulnérants et balistique lésionnelle. [Thoracic ballistic trauma. Wounding agents and wound ballistics.] *Annales de chirurgie plastique esthétique* 2003; **48**: 128 – 134.

Ferguson DG, Stevenson HM. A review of 158 gunshot wounds to the chest. *Br J Surg* 1978; **65**: 845 – 847.

Gibbons JRP. Treatment of missile injuries of the chest: Belfast experience. *Eur J Cardiothorac Surg* 1989; **3**: 297 – 299.

Grover FL. Editorial: Treatment of thoracic battle injuries versus civilian injuries. *Ann Thorac Surg* 1985; **40**: 207 – 208.

Kjaergaard J. Les blessés de guerre de l'hôpital de campagne du CICR à Beyrouth en 1976 [War wounded in the ICRC field hospital in Beirut 1976]. *Schweiz Z Milit Med* 1978; **55**: 1 – 23.

Levinsky L, Vidne B, Nudelman I, Salomon J, Kissin L, Levy MJ. Thoracic injuries in the Yom Kippur War: experience in a base hospital. *Isr J Med Sci* 1975; **11**: 275 – 280.

Mattox KL, Allen MK. Penetrating wounds of the thorax. *Injury* 1986; **17**: 313 – 317.

McNamara JJ, Messersmith JK, Dunn RA, Molot MD, Stremple JF. Thoracic injuries in combat casualties in Vietnam. *Ann Thorac Surg* 1970; **10**: 389 – 399.

Propper BW, Gifford SM, Calhoun JH, McNeil JD. Wartime thoracic injury: perspectives in modern warfare. *Ann Thorac Surg* 2010; **89**: 1032 – 1036.

Roostar L. *Gunshot Chest Injuries*. Tartu, Estonia: Tartu University Press; 1996.

Rosenblatt M, Lemer J, Best LA, Peleg H. Thoracic wounds in Israeli battle casualties during the 1982 evacuation of wounded from Lebanon. *J Trauma* 1985; **25**: 350 – 354.

Zakharia AT. Thoracic battle injuries in the Lebanon War: review of the early operative approach in 1,992 patients. *Ann Thorac Surg* 1985; **40**: 209 – 213.

Zakharia AT. Cardiovascular and thoracic battle injuries in the Lebanon War. Analysis of 3,000 personal cases. *J Thorac Cardiovasc Surg* 1985; **89**: 723 – 733.

#### Chest tube drainage

Aylwin CJ, Brohi K, Davies GD, Walsh MS. Pre-hospital and in-hospital thoracostomy: indications and complications. *Ann R Coll Surg Engl* 2008; **90**: 54 – 57.

Fitzgerald M, Mackenzie CF, Marasco S, Hoyle R, Kossmann T. Pleural decompression and drainage during trauma reception and resuscitation. *Injury* 2008; **39**: 9 – 20.

Griffiths JR, Roberts N. Do junior doctors know where to insert chest drains safely? *Postgrad Med J* 2005; **81**: 456 – 458.

Mattox KL, Allen MK. Symposium Paper: Systematic approach to pneumothorax, haemothorax, pneumomediastinum and subcutaneous emphysema. *Injury* 1986; **17**: 309 – 312.

Mitchell R, Freeman L. Intercostal catheter placement in trauma: a case series and review of common pitfalls. *Injury* 2010; **41 (Suppl. 1)**: S56 – S57.

#### Thoracotomy

MacFarlane C. Emergency thoracotomy and the military surgeon. *ANZ J Surg* 2004; **74**: 280 – 284.

Mattox KL, Pickard LR, Allen MK. Emergency thoracotomy for injury. *Injury* 1986; **17**: 327 – 331.

Moore EE, Knudson MM, Burlew CC, Inaba K, Dicker RA, Biffi WL, Malhotra AK, Schreiber MA, Browder TD, Coimbra R, Gonzalez EA, Meredith JW, Livingston DH, Kaups KL, and the WTA Study Group. Defining the limits of resuscitative emergency department thoracotomy: a contemporary Western Trauma Association perspective. *J Trauma* 2011; **70**: 334 – 339.

Phelan HA, Patterson SG, Hassan MO, Gonzalez RP, Rodning CB. Thoracic damage-control operation: principles, techniques, and definitive repair. *J Am Coll Surg* 2006; **203**: 933 – 941.

Rotondo MF, Bard MR. Damage control surgery for thoracic injuries. *Injury* 2004; **35**: 649 – 654.

#### Tension pneumothorax

Britten S, Palmer SH, Snow TM. Needle thoracocentesis in tension pneumothorax: insufficient cannula length and potential failure. *Injury* 1996; **27**: 321 – 322.

Inaba K, Branco BC, Eckstein M, Shatz DV, Martin MJ, Green DJ, Noguchi TT, Demetriades D. Optimal positioning for emergent needle thoracostomy: a cadaver-based study. *J Trauma* 2011; **71**: 1099 – 1103.

Leigh-Smith S, Davies G. Indications for thoracic needle decompression. *J Trauma* 2007; **63**: 1403 – 1404.

Maxwell WB. The hanging drop to locate the pleural space: a safer method for decompression of suspected pneumothorax? *J Trauma* 2010; **69**: 970 – 971.

McPherson JJ, Feigin DS, Bellamy RF. Prevalence of tension pneumothorax in fatally wounded combat casualties. *J Trauma* 2006; **60**: 573 – 578.

Zengerink I, Brink PR, Laupland KB, Raber EL, Zygun D, Kortbeek JB. Needle thoracostomy in the treatment of a tension pneumothorax in trauma patients: what size needle? *J Trauma* 2008; **64**: 111 – 114.

#### Lung

Bastos R, Calhoun JH, Baisden CE. Flail chest and pulmonary contusion. *Semin Thorac Cardiovasc Surg* 2008; **20**: 39 – 45.

Bongard FS, Lewis FR. Crystalloid resuscitation of patients with pulmonary contusion. *Am J Surg* 1984; **148**: 145 – 149.

Johnson SB. Tracheobronchial injury. *Semin Thorac Cardiovasc Surg* 2008; **20**: 52 – 57.

Tang BMP, Craig JC, Eslick GD, Seppelt I, McLean AS. Use of corticosteroids in acute lung injury and acute respiratory distress syndrome: a systematic review and meta-analysis. *Crit Care Med* 2009; **37**: 1594 – 1603.

Wall MJ Jr, Hirshberg A, Mattox KL. Pulmonary tractotomy with selective vascular ligation for penetrating injuries to the lung. *Am J Surg* 1994; **168**: 665 – 669.

### Oesophagus

Ilic N, Petricevic A, Mimica Z, Tanfara S, Frleta Ilic N. War injuries to the thoracic esophagus. *Eur J Cardiothorac Surg* 1998; **14**: 572 – 574.

Popovsky J. Perforations of the esophagus from gunshot wounds. *J Trauma* 1984; **24**: 337 – 339.

Wu JT, Mattox KL, Wall MJ Jr. Esophageal perforations: new perspectives and treatment paradigms. *J Trauma* 2007; **63**: 1173 – 1184.

### Empyema

Carrillo EH, Barkoe DJ, Sanchez R, Lee SK, Rosenthal A, Pepe A, Nardiello D. Open thoracic window: a useful alternative for retained infected pleural collections in critically ill trauma patients. *Am Surg* 2009; **75**: 152 – 156.

Eren S, Esme H, Sehitogullari A, Durkan A. The risk factors and management of posttraumatic empyema in trauma patients. *Injury* 2008; **39**: 44 – 49.

## Chapter 32

### General references

Adesanya AA, da Rocha-Afodu JT, Ekanem EE, Afolabi IR. Factors affecting mortality and morbidity in patients with abdominal gunshot wounds. *Injury* 2000; **31**: 397 – 404.

Bamberger PK. The adoption of laparotomy for the treatment of penetrating abdominal wounds in war. *Mil Med* 1996; **161**: 189 – 196.

Becker VV Jr, Brien WW, Patzakis M, Wilkins J. Gunshot injuries to the hip and abdomen: the association of joint and intra-abdominal visceral injuries. *J Trauma* 1990; **30**: 1324 – 1329.

Borhan MS, Al-Najafi HH. *Analysis of Abdominal Missile Injuries: Prospective Study in Mosul*. Fellowship thesis; presented at ICRC War Surgery Seminar, Suleymanieh, Iraq, 2008.

Cutting PA, Agha R. Surgery in a Palestinian refugee camp. *Injury* 1992; **23**: 405 – 409.

Dent RI, Jena GP. Missile injuries of the abdomen in Zimbabwe-Rhodesia. *Br J Surg* 1980; **67**: 305 – 310.

Dudley HAF, Knight RJ, McNeur JC, Rosengarten DS. Civilian battle casualties in South Vietnam. *Br J Surg* 1968; **55**: 332 – 340.

Dumurgier C, Weissbrod R, Durette D, Jancovici R, Suc L, Mechineau Y. Plaies de l'abdomen par projectiles de guerre: expérience du détachement médical de Kousseri-Riggil – 15.07.80 au 15.12.80. [Abdominal wounds by the projectiles of war: experience of the medical detachment in Kousseri-Riggil – 15.07.80 to 15.12.80.] *Médecine et Hygiène* 1982; **40**: 2984 – 2992.

Fasol R, Zilla P, Irvine S, von Oppell U. Thoraco-abdominal injuries in combat casualties on the Cambodian border. *Thorac Cardiovasc Surg* 1988; **36**: 33 – 36.

Fekadu T. *Abdominal War Wounds: Challenges to Field Surgeons. Inside Eritrea's War for Independence*. Asmara, Eritrea: Hdri Publishers; 2006.

Gorgulu S, Gencosmanoglu R, Akaoglu C. Penetrating abdominal gunshot wounds caused by high-velocity missiles: a review of 51 military injuries managed at a level-3 trauma center. *Internat Surg* 2008; **93**: 331 – 338.

Hardaway RM III. Viet Nam wound analysis. *J Trauma* 1978; **18**: 635 – 643.

- Kandil A. Gunshot wounds of the abdomen. *Palestinian Med J* 2005. Ministry of Health Information Centre, Department of Electronic Publication. Available at: <http://www.moh.gov.ps/pmj/GUNSHOT.htm>.
- Kleinman Y, Rosin R. The Yom Kippur war experience: a survey of the management of 151-abdominal combat casualties at the Refidim evacuation hospital. *Inter Rev Army Navy Air Force* 1979; **52**: 623 – 649.
- Leppäniemi AK. Abdominal war wounds—experiences from Red Cross field hospitals. *World J Surg* 2005; **29 (Suppl.)**: S67 – S71.
- Morris DS, Sugrue WJ. Abdominal injuries in the war wounded of Afghanistan: a report from the International Committee of the Red Cross Hospital in Kabul. *Br J Surg* 1991; **78**: 1301 – 1304.
- Nassoura Z, Hajj H, Dajani O, Jabbour N, Ismail M, Tarazi T, Khoury G, Najjar F. Trauma management in a war zone: the Lebanese War experience. *J Trauma* 1991; **31**: 1596 – 1599.
- Peitzman AB, Richardson JD. Surgical treatment of injuries to the solid abdominal organs: a 50-year perspective from the *Journal of Trauma*. *J Trauma* 2010; **69**: 1011 – 1021.
- Pfeffermann R, Rozin RR, Durst AL, Marin G. Modern war surgery: operations in an evacuation hospital during the October 1973 Arab – Israeli war. *J Trauma* 1976; **16**: 694 – 703.
- Rozin RR, Kleinman Y. Surgical priorities of abdominal wounded in a combat situation. *J Trauma* 1987; **27**: 656 – 660.
- Saghafinia M, Nafissi N, Motamedi MRK, Motamedi MHK, Hashemzade M, Hayati Z, Panahi F. Assessment and outcome of 496 penetrating gastrointestinal warfare injuries. *J R Army Med Corps* 2010; **156**: 25 – 27.
- Šikić N, Korać Ž, Krajačić I, Žunić J. War abdominal trauma: usefulness of penetrating abdominal trauma index, injury severity score, and number of injured abdominal organs as predictive factors. *Mil Med* 2001; **166**: 226 – 230.
- Versier G, Le Marec C, Rouffi J. Quatre ans de chirurgie de guerre au GMC de Sarajevo (juillet 1992 à août 1996). [Four years of war surgery at the French surgical facility in Sarajevo – July 1992 – August 1996.] *Médecine et armées* 1998; **26**: 213 – 218.
- Ballistics**
- Ben-Menachem Y. Intra-abdominal injuries in nonpenetrating gunshot wounds of the abdominal wall: two unusual cases. *J Trauma* 1979; **19**: 207 – 210.
- Edwards J, Gaspard DJ. Visceral injury due to extraperitoneal gunshot wounds. *Arch Surg* 1974; **108**: 865 – 866.
- Georgi BA, Massad M, Obeid M. Ballistic trauma to the abdomen: shell fragments versus bullets. *J Trauma* 1991; **31**: 711 – 715.
- Kennedy FR, Fleming AW, Sterling Scott R. Splenic injury from gunshot wounds to the chest without diaphragmatic or peritoneal violation: case reports. *J Trauma* 1991; **31**: 1561 – 1562.
- Paran H, Neufeld D, Shwartz I, Kidron D, Susmallian S, Mayo A, Dayan K, Vider I, Sivak G, Freund U. Perforation of the terminal ileum induced by blast injury: delayed diagnosis or delayed perforation? *J Trauma* 1996; **40**: 472 – 475.
- Sasaki LS, Mittal UK. Small bowel laceration from a penetrating extraperitoneal gunshot wound: a case report. *J Trauma* 1995; **39**: 602 – 604.
- Sharma OP, Oswanski MF, White PW. Injuries to the colon from blast effect of penetrating extra-peritoneal thoraco-abdominal trauma. *Injury* 2004; **35**: 320 – 324.
- Tien HC, van der Hurk TWG, Dunlop MP, Kropelin B, Nahouraii R, Battad AB, van Egmond T. Small bowel injury from a tangential gunshot wound without peritoneal penetration: a case report. *J Trauma* 2007; **62**: 762 – 764.

Velitchkov NG, Losanoff JE, Kjossev et al. Delayed small bowel injury as a result of penetrating extraperitoneal high-velocity ballistic trauma to the abdomen. *J Trauma* 2000; **48**: 169 – 170.

Wani I, Parray FQ, Sheikh T, Wani RA, Amin A, Gul I, Nazir M. Spectrum of abdominal organ injury in a primary blast type. *World J Emerg Surg* 2009; **4**: 46. [doi:10.1186/1749-7922-4-46]

#### Diagnosis, operative or selective non-operative management

Beekley AC, Blackburn LH, Sebesta JA, McMullin N, Mullenix PS, Holcomb JB, Members of 31st Combat Support Hospital Research Group. Selective nonoperative management of penetrating torso injury from combat fragmentation wounds. *J Trauma* 2008; **64** (Suppl.): S108 – S117.

Como JJ, Bokhari F, Chiu WC, Duane TM, Holevar MR, Tandoh MA, Ivatury RR, Scalea TM. Practice management guidelines for selective nonoperative management of penetrating abdominal trauma. *J Trauma* 2010; **68**: 721 – 733.

Demetriades D, Rabinowitz B, Sofianos C, Charalambides D, Melissas J, Hatjitheofilou C, Da Silva J. The management of penetrating injuries of the back: a prospective study of 230 patients. *Ann Surg* 1988; **207**: 72 – 74.

Demetriades D, Velmahos G, Cornwell E III, Berne TV, Cober S, Bhasin PS, Belzberg H, Asensio J. Selective nonoperative management of gunshot wounds of the anterior abdomen. *Arch Surg* 1997; **132**: 178 – 183.

DiGiacomo JC, Schwab CW, Rotondo MF, Angood PA, McGonigal MD, Kauder DR, Phillips GR III. Gluteal gunshot wounds: who warrants exploration? *J Trauma* 1994; **37**: 622 – 628.

Duncan AO, Phillips TF, Scalea TM, Maltz SB, Atweh NA, Scalafani SJA. Management of transpelvic gunshot wounds. *J Trauma* 1989; **29**: 1335 – 1340.

Inaba K, Barmparas G, Foster A, Talving P, David J-S, Green D, Plurad D, Demetriades D. Selective nonoperative management of torso gunshot wounds: when is it safe to discharge? *J Trauma* 2010; **68**: 1301 – 1304.

Nance ML, Nance FC. It is time we told the emperor about his clothes. *J Trauma* 1996; **40**: 185 – 186.

Renz BM, Feliciano DV. Unnecessary laparotomies for trauma: a prospective study of morbidity. *J Trauma* 1995; **38**: 350 – 356.

Ross SE, Dragon GM, O'Malley KF, Rehm CG. Morbidity of negative coeliotomy in trauma. *Injury* 1995; **26**: 393 – 394.

Rozycki GS, Root HD. The diagnosis of intraabdominal visceral injury. *J Trauma* 2010; **68**: 1019 – 1023.

Velmahos GC, Demetriades D, Cornwell EE III, Asensio J, Belzberg H, Berne TV. Gunshot wounds to the buttocks: predicting the need for operation. *Dis Colon Rectum* 1997; **40**: 307 – 311.

Velmahos GC, Demetriades D, Cornwell EE III. Transpelvic gunshot wounds: routine laparotomy or selective management? *World J Surg* 1998; **22**: 1034 – 1038.

Velmahos GC, Demetriades D, Toutouzas KG, Sarkisyan G, Chan LS, Ishak R, Alo K, Vassiliu P, Murray JA, Salim A, Asensio J, Belzberg H, Katkhouda N, Berne TV. Selective nonoperative management in 1,856 patients with abdominal gunshot wounds: should routine laparotomy still be the standard of care? *Ann Surg* 2001; **234**: 395 – 403.

Weigelt JA, Kingman RG. Complications of negative laparotomy for trauma. *Am J Surg* 1988; **156**: 544 – 547.

**Damage-control laparotomy (further references)**

Ball CG, Wyrzykowski AD, Nicholas JM, Rozycki GS, Feliciano DV. A decade's experience with balloon catheter tamponade for the emergency control of hemorrhage. *J Trauma* 2011; **70**: 330 – 333.

Duchesne JC, Kimonis K, Marr AB, Rennie KV, Wahl G, Wells JE, Islam TM, Meade P, Stuke L, Barbeau JM, Hunt JP, Baker CC, McSwain NE Jr. Damage control resuscitation in combination with damage control laparotomy: a survival advantage. *J Trauma* 2010; **69**: 46 – 52.

Feliciano DV, Mattox KL, Burch JM, Bitondo CG, Jordan GL Jr. Packing for control of hepatic hemorrhage. *J Trauma* 1986; **26**: 738 – 743.

Parr MJA, Alabdi T. Damage control surgery and intensive care. *Injury* 2004; **35**: 713 – 722.

Sambasivan CN, Underwood SJ, Cho SD, Kiraly LN, Hamilton GJ, Kofoed JT, Flaherty SF, Dorlac WC, Schreiber MA. Comparison of abdominal damage control surgery in combat versus civilian trauma. *J Trauma* 2010; **69 (Suppl.)**: S168 – S174.

Sugrue M, D'Amours SK, Joshipura M. Damage control surgery and the abdomen. *Injury* 2004; **35**: 642 – 648.

**Abdominal compartment syndrome and the open abdomen**

An G, West MA. Abdominal compartment syndrome: a concise clinical review. *Crit Care Med* 2008; **36**: 1304 – 1310.

Basu A. A low-cost technique for measuring the intraabdominal pressure in non-industrialised countries. *Ann R Coll Surg Engl* 2007; **89**: 434 – 435.

Burlew CC, Moore EE, Cuschieri J, Jurkovich GJ, Codner P, Crowell K, Nirula R, Haan J, Rowell SE, Kato CM, MacNew H, Ochsner MG, Harrison PB, Fusco C, Savaia A, Kaups KL, and the WTA Study Group. Sew it up! A Western Trauma Association multi-institutional study of enteric injury management in the postinjury open abdomen. *J Trauma* 2011; **70**: 273 – 277.

Cheatham ML, Malbrain ML, Kirkpatrick A, Sugrue M, Parr M, De Waele J, Balogh Z, Leppäniemi A, Olvera C, Ivatury R, D'Amours S, Wendon J, Hillman K, Wilmer A. Results from the International Conference of Experts on Intra-abdominal Hypertension and Abdominal Compartment Syndrome. II. Recommendations. *Intensive Care Med* 2007; **33**: 951 – 962.

Collee GG, Lomax DM, Ferguson C, Hanson GC. Bedside measurement of intra-abdominal pressure (IAP) via an indwelling naso-gastric tube: clinical validation of the technique. *Intensive Care Med* 1993; **19**: 478 – 480.

Diaz JJ Jr, Dutton WD, Ott MM, Cullinane DC, Alouidor R, Armen SB, Bilaniuk JW, Collier BR, Gunter OL, Jawa R, Jerome R, Kerwin AJ, Kirby JP, Lambert AL, Riordan WP, Wohltmann CD. Eastern Association for the Surgery of Trauma: a review of the management of the open abdomen: Part 2 "management of the open abdomen". *J Trauma* 2011; **71**: 502 – 512.

Kopelman T, Harris C, Miller R, Arrillaga A. Abdominal compartment syndrome in patients with isolated extraperitoneal injuries. *J Trauma* 2000; **49**: 744 – 749.

Malbrain ML. Different techniques to measure intra-abdominal pressure (IAP): time for a critical reappraisal. *Intensive Care Med* 2004; **30**: 357 – 371.

Malbrain ML, Cheatham ML, Kirkpatrick A, Sugrue M, Parr M, De Waele J, Balogh Z, Leppäniemi A, Olvera C, Ivatury R, D'Amours S, Wendon J, Hillman K, Johansson K, Kolkman K, Wilmer A. Results from the International Conference of Experts on Intra-abdominal Hypertension and Abdominal Compartment Syndrome. I. Definitions. *Intensive Care Med* 2006; **32**: 1722 – 1732.

Vargo D, Richardson JD, Campbell A, Chang M, Fabian T, Franz M, Kaplan M, Moore F, Reed RL, Scott B, Silverman R. (Open Abdomen Advisory Panel) Management of the



open abdomen: from initial operation to definitive closure. *Am Surg* 2009; **75 (Suppl.)**: S1 – S22.

Vertrees A, Greer L, Pickett C, Nelson J, Wakefield M, Stojadinovic A, Shriver C. Modern management of complex open abdominal wounds of war: a 5-year experience. *J Am Coll Surg* 2008; **207**: 801 – 809.

World Society on the Abdominal Compartment Syndrome. [Dedicated professional web site: <http://wsacs.org>.]

### Great vessels

Asensio JA, Soto SN, Forno W, Roldán G, Petrone P, Gambaro E, Salim A, Rowe V, Demetriades D. Abdominal vascular injuries: the trauma surgeon challenges. *Surg Today* 2001; **31**: 949 – 957.

Asensio JA, Petrone P, Garcia-Nuñez L, Healy M, Martin M, Kuncir E. Superior mesenteric venous injuries: to ligate or to repair remains the question. *J Trauma* 2007; **62**: 668 – 675.

Chapellier X, Sockeel P, Baranger B. Management of penetrating abdominal vessel injuries. *J Visc Surg* 2010; **147**: e1 – e12. [doi:10.1016/j.jviscsurg.2010.06.003]

Mattox KL, McCollum WB, Beall AC Jr, Jordan GL Jr, DeBakey ME. Management of penetrating injuries of the suprarenal aorta. *J Trauma* 1975; **15**: 808 – 815.

Reilly PM, Rotondo MF, Carpenter JP, Sherr SA, Schwab CW. Temporary vascular continuity during damage control: intraluminal shunting for proximal superior mesenteric artery injury. *J Trauma* 1995; **39**: 757 – 760.

Richards AJ Jr, Lamis PA Jr, Rogers JT Jr, Bradham GB. Laceration of abdominal aorta and study of intact abdominal wall as tamponade: report of survival and literature review. *Ann Surg* 1966; **164**: 321 – 324.

### Liver

Demetriades D. Balloon tamponade for bleeding control in penetrating liver injuries. *J Trauma* 1998; **44**: 538 – 539.

Feliciano DV, Mattox KL, Burch JM, Bitondo CG, Jordan GL Jr. Packing for control of hepatic hemorrhage. *J Trauma* 1986; **26**: 738 – 743.

Ivatury RR, Nallathambi M, Gunduz Y, Constable R, Rohman M, Stahl WM. Liver packing for uncontrolled hemorrhage: a reappraisal. *J Trauma* 1986; **26**: 744 – 751.

Discussion of the previous two papers: *J Trauma* 1986; **26**: 751 – 753.

Marr JDF, Krige JEJ, Terblanche J. Analysis of 153 gunshot wounds of the liver. *Br J Surg* 2000; **87**: 1030 – 1034.

Morrison JJ, Bramley KE, Rizzo AG. Liver trauma – operative management. *J R Army Med Corps* 2011; **157**: 136 – 144.

Ozdogan M, Ozdogan H. Balloon tamponade with Sengstaken-Blakemore tube for penetrating liver injury: case report. *J Trauma* 2006; **60**: 1122 – 1123.

Stone HH, Lamb JM. Use of pedicled omentum as an autogenous pack for control of hemorrhage in major injuries of the liver. *Surg Gynecol Obstet* 1975; **141**: 92 – 94.

### Extrahepatic biliary tract

Bade PG, Thomson SR, Hirshberg A, Robbs JV. Surgical options in traumatic injury to the extrahepatic biliary tract. *Br J Surg* 1989; **76**: 256 – 258.

Feliciano DV, Bitondo CG, Burch JM, Mattox KL, Beall AC Jr, Jordan GL Jr. Management of traumatic injury to the extrahepatic biliary ducts. *Am J Surg* 1985; **150**: 705 – 709.

Posner MC, Moore EE. Extrahepatic biliary tract injury: operative management plan. *J Trauma* 1985; **25**: 833 – 837.

Sheldon GF, Lim RC, Yee ES, Petersen SR. Management of injuries to the porta hepatis. *Ann Surg* 1985; **202**: 539 – 545.

**Spleen**

Di Sabatino A, Carsetti R, Corazza GR. Post-splenectomy and hyposplenic states. *Lancet* 2011; **378**: 86 – 97.

Pisters PWT, Pachter HL. Autologous splenic transplantation for splenic trauma. *Ann Surg* 1994; **219**: 225 – 235.

**Pancreas and duodenum**

Boffard KD, Brooks AJ. Pancreatic trauma – injuries to the pancreas and pancreatic duct. *Eur J Surg* 2000; **166**: 4 – 12.

Degiannis E, Levy RD, Potokar T, Lennox H, Rowse A, Saddia R. Distal pancreatectomy for gunshot injuries of the distal pancreas. *Br J Surg* 1995; **82**: 1240 – 1242.

Degiannis E, Levy RD, Velmahos GC, Potokar T, Florizoone MGC, Saadia R. Gunshot injuries of the head of the pancreas: conservative approach. *World J Surg* 1996; **20**: 68 – 71.

Degiannis E, Boffard K. Duodenal injuries. *Br J Surg* 2000; **87**: 1473 – 1479.

Degiannis E, Glapa M, Loukogeorgakis SP, Smith MD. Management of pancreatic trauma. *Injury* 2008; **39**, 21 – 29.

Feliciano DV, Martin TD, Cruse PA, Graham JM, Burch JM, Mattox KL, Bitondo CG, Jordan GL Jr. Management of combined pancreatoduodenal injuries. *Ann Surg* 1987; **205**: 673 – 680.

Jansen M, Du Toit DF, Warren BL. Duodenal injuries: surgical management adapted to circumstances. *Injury* 2002; **33**: 611 – 615.

Khan MA, Cameron I. The management of pancreatic trauma. *J R Army Med Corps* 2010; **156**: 221 – 227.

Lopez PP, Benjamin R, Cockburn M, Amortegui JD, Schulman CI, Soffer D, Blackbourne LH, Habib F, Jerokhimov I, Trankel S, Cohn SM. Recent trends in the management of combined pancreatoduodenal injuries. *Am Surg* 2005; **71**: 847 – 852.

Velmahos GC, Constantinou C, Kasotakis G. Safety of repair for severe duodenal injuries. *World J Surg* 2008; **32**: 7 – 12.

**Stomach and small bowel**

Guarino J, Hassett JM Jr, Luchette FA. Small bowel injuries: mechanisms, patterns, and outcome. *J Trauma* 1995; **39**: 1076 – 1080.

Olofsson P, Abu-Zidan FM, Wang J, Nagelkerke N, Lennquist S, Wikstrom T. The effects of early rapid control of multiple bowel perforations after high-energy trauma to the abdomen: implications for damage control surgery. *J Trauma* 2006; **61**: 185 – 191.

**Colon and rectum**

Angelici AM, Montesano G, Nasti AG, Palumbo P, Vietri F. Treatment of gunshot wounds to the colon: experience in a rural hospital during the civil war in Somalia. *Ann Ital Chir* 2004; **75**: 461 – 464.

Armstrong RG, Schmitt HJ Jr, Patterson LT. Combat wounds of the extraperitoneal rectum. *Surg* 1973; **74**: 570 – 583.

Crass RA, Salbi F, Trunkey DD. Colostomy closure after colon injury: a low-morbidity procedure. *J Trauma* 1987; **27**: 1237 – 1239.

Demetriades D, Murray JA, Chan L, Ordoñez C, Bowley D, Nagy KK, Cornwell EE III, Velmahos GC, Muñoz N, Hatzitheofilou C, Schwab CW, Rodriguez A, Cornejo C, Davis KA, Namias N, Wisner DH, Ivatury RR, Moore EE, Acosta JA, Maull KI, Thomason MH, Spain DA. Penetrating colon injuries requiring resection: diversion or primary anastomosis? An AAST prospective multicenter study. *J Trauma* 2001; **50**: 765 – 775.

Dumurgier C. Place de la colectomie avec rétablissement immédiat de la continuité, en chirurgie de guerre: à propos de 66 plaies coliques. [The place of colectomy with immediate establishment of continuity during war surgery: concerning 66 wounds of the colon.] *Lyon Chirurgical* 1982; **78**: 348 – 352.

Dykes SL. *Ostomies & Stomal Therapy*. American Society of Colon and Rectal Surgeons. Available at: [www.fascrs.org/physicians/education/core\\_subjects/2010](http://www.fascrs.org/physicians/education/core_subjects/2010).

Edwards DP, Brown D, Watkins PE. Should colon-penetrating small missiles be removed? An experimental study of retrocolic wound tracks. *J Investig Surg* 1999; **12**: 25 – 29.

Govender M, Madiba TE. Current management of large bowel injuries and factors influencing outcome. *Injury* 2010; **41**: 58 – 63.

Hudolin T, Hudolin I. The role of primary repair for colonic injuries in wartime. *Br J Surg* 2005; **92**: 643 – 647.

Moreels R, Pont M, Ean S, Vitharit M, Vuthy C, Roy S, Boelaert M. Wartime colon injuries: primary repair or colostomy? *J R Soc Med* 1994; **87**: 265 – 267.

Nelson R, Singer M. *Primary repair for penetrating colon injuries (Cochrane Database of Systematic Reviews 2009)*. Available at: <http://www.cochrane.org>.

Nwafo DC. Selective primary suture of the battle-injured colon: an experience of the Nigerian civil war. *Br J Surg* 1980; **67**: 195 – 197.

Poret HA III, Fabian TC, Croce MA, Bynoe RP, Kudsk KA. Analysis of septic morbidity following gunshot wounds to the colon: the missile is an adjuvant for abscess. *J Trauma* 1991; **31**: 1088 – 1091.

Schnüriger B, Inaba K, Wu T, Eberle BM, Belzberg H, Demetriades D. Crystalloids after primary colon resection and anastomosis at initial trauma laparotomy: excessive volumes are associated with anastomotic leakage. *J Trauma* 2011; **70**: 603 – 610.

Stankovic N, Petrovic, M, Drinkovic N, Bjelovic M, Jevtic M, Mirkovic D. Colon and rectal war injuries. *J Trauma* 1996; **40 (Suppl.)**: S183 – S188.

Steele SR. *Colon & Rectal Trauma*. American Society of Colon and Rectal Surgeons. Available at: [www.fascrs.org/physicians/education/core\\_subjects/2008](http://www.fascrs.org/physicians/education/core_subjects/2008).

Steele SR, Maykel JA, Johnson EK. Traumatic injury of the colon and rectum: the evidence versus dogma. *Dis Colon Rectum* 2011; **54**: 1184 – 1201.

Strada G, Raad L, Belloni G, Setti Carraro P. Large bowel perforations in war surgery: one-stage treatment in a field hospital. *Int J Colorect Dis* 1993; **8**: 213 – 216.

Urvic M. Colorectal war injuries. *Mil Med* 2000; **165**: 186 – 188.

Vertrees A, Wakefield M, Pickett C, Greer L, Wilson A, Gillern S, Nelson J, Aydelotte J, Stojadinovic A, Shriver C. Outcomes of primary repair and primary anastomosis in war-related colon injuries. *J Trauma* 2009; **66**: 1286 – 1293.

Webster C, Mercer S, Schrage J, Carrell TWG, Bowley D. Indirect colonic injury after military wounding: a case series. *J Trauma* 2011; **71**: 1475 – 1477.

Welling DR, Hutton JE, Minken SL, Place RJ, Burriss DG. Diversion defended – military colon trauma. *J Trauma* 2008; **64**: 1119 – 1122.

### Pelvis

Adams SA. Pelvic ring injuries in the military environment. *J R Army Med Corps* 2009; **155**: 293 – 296.

Arthurs Z, Kjorstad R, Mullenix P, Rush RM Jr, Sebesta J, Beekley A. The use of damage-control principles for penetrating pelvic battlefield trauma. *Am J Surg* 2006; **191**: 604 – 609.

Ball CG, Hameed M, Navsaria P, Edu S, Kirkpatrick AW, Nicol AJ. Successful damage control of complex vascular and urological gunshot injuries. *Can J Surg* 2006; **49**: 437 – 438.

Ball CG, Feliciano DV. Damage control techniques for common and external iliac artery injuries: have temporary intravascular shunts replaced the need for ligation? *J Trauma* 2010; **68**: 1117 – 1120.

- Cothren CC, Osborn PM, Moore EE, Morgan SJ, Johnson JL, Smith WR. Preperitoneal pelvic packing for hemodynamically unstable pelvic fractures: a paradigm shift. *J Trauma* 2007; **62**: 834 – 842.
- Gonzalez RP, Holevar MR, Falimirski ME, Merlotti GJ. A method for management of extraperitoneal pelvic bleeding secondary to penetrating trauma. *J Trauma* 1997; **43**: 338 – 341.
- Haan J, Rodriguez A, Chiu W, Boswell S, Scott J, Scalea T. Operative management and outcome of iliac vessel injury: a ten-year experience. *Am Surg* 2003; **69**: 581 – 586.
- Lesperance K, Martin MJ, Beekley AC, Steele SR. The significance of penetrating gluteal injuries: an analysis of the Operation Iraqi Freedom experience. *J Surg Educ* 2008; **65**: 61 – 66. [doi:10.1016/j.jsurg.2007.08.004]
- Losanoff JE, Richman BW, Jones JW. Letter to the Editor and authors' reply: Remzi et al. Muscle tamponade to control presacral venous bleeding. *Dis Colon Rectum* 2003; **46**: 688 – 689.
- Lunevicius R, Schulte K-M. Analytical review of 664 cases of penetrating buttock trauma. *World J Emerg Surg* 2011; **6**: 33. Available at: <http://www.wjes.org/content/6/1/33>.
- McCourtney JS, Hussain N, Mackenzie I. Balloon tamponade for control of massive presacral haemorrhage. *Br J Surg* 1996; **83**: 222.
- Morrison JJ, Mountain AJC, Galbraith KA, Clasper JC. Penetrating pelvic battlefield trauma: internal use of chitosan-based haemostatic dressings. *Injury* 2010; **41**: 239 – 241.
- Nunn T, Cosker TDA, Bose D, Pallister I. Immediate application of improvised pelvic binder as first step in extended resuscitation from life-threatening hypovolaemic shock in conscious patients with unstable pelvic injuries. *Injury* 2007; **38**: 125 – 128.
- Pohlemann T, Gänsslen A, Bosch U, Tscherner H. The technique of packing for control of hemorrhage in complex pelvic fractures. *Tech Orthop*. 1995; **9**: 267 – 270.
- Remzi FH, Oncel M, Fazio VW. Muscle tamponade to control presacral venous bleeding: report of two cases. *Dis Colon Rectum* 2002; **45**: 1109 – 1111.
- Simpson T, Krieg JC, Heuer F, Bottlang M. Stabilization of pelvic ring disruptions with a circumferential sheet. *J Trauma* 2002; **52**: 158 – 161.
- Tötterman A, Madsen JE, Skaga NO, Røise O. Extraperitoneal pelvic packing: a salvage procedure to control massive traumatic pelvic hemorrhage. *J Trauma* 2007; **62**: 843 – 852.
- Xu J, Lin J, Hangzhou C. Control of presacral hemorrhage with electrocautery through a muscle fragment pressed on the bleeding vein. *J Am Coll Surg* 1994; **179**: 351 – 352.
- Post-operative care and complications**
- Hamp T, Fridrich P, Mauritz W, Hamid L, Pelinka LE. Cholecystitis after trauma. *J Trauma* 2009; **66**: 400 – 406.
- Lindberg EF, Grinnan GLB, Smith L. Acalculous cholecystitis in Viet Nam casualties. *Ann Surg* 1970; **171**: 152 – 157.
- Nastro P, Knowles CH, McGrath A, Heyman B, Porrett TRC, Lunniss PJ. Complications of intestinal stomas. *Br J Surg* 2010; **97**: 1885 – 1889.
- Schein M. To drain or not to drain? The role of drainage in the contaminated and infected abdomen: an international and personal perspective. *World J Surg* 2008; **32**: 312 – 321.
- Schmitt HJ Jr, Patterson LT, Armstrong RJ. Reoperative surgery of abdominal war wounds: *Ann Surg* 1967; **165**: 173 – 185.

## Chapter 33

### General references

Abu-Zidan FM, Al-Tawheed A, Ali YM. Urologic injuries in the Gulf War. *Int Urol Nephrol* 1999; **31**: 577 – 583.

Archbold JAA, Barros D'Sa AAB, Morrison E. Genito-urinary tract injuries of civil hostilities. *Br J Surg* 1981; **68**: 625 – 631.

Busch FM, Chenault OW Jr, Zinner NR, Clarke BG. Urological aspects of Vietnam war injuries. *J Urol* 1967; **97**: 763 – 765.

Hudak SJ, Morey AF, Rozanski TA, Fox CW Jr. Battlefield urogenital injuries: changing patterns during the past century. *Urol* 2005; **65**: 1041 – 1046.

Hudak SJ, Hakim S. Operative management of wartime genitourinary injuries at Balad Air Force Theater Hospital, 2005 to 2008. *J Urol* 2009; **182**: 180 – 183.

Hudolin T, Hudolin I. Surgical management of urogenital injuries at a war hospital in Bosnia-Herzegovina, 1992 to 1995. *J Urol* 2003; **169**: 1357 – 1359.

Mareković Z, Derezić D, Krhen I, Kastelan Z. Urogenital war injuries. *Mil Med* 1997; **162**: 346 – 348.

Ochsner TJ, Busch FM, Clarke BG. Urogenital wounds in Vietnam. *J Urol* 1969; **101**: 224 – 225.

Salvatierra O Jr, Rigdon WO, Norris DM, Brady TW. Vietnam experience with 252 urological war injuries. *J Urol* 1969; **101**: 615 – 620.

Thompson IM, Flaherty SF, Morey AF. Battlefield urologic injuries: the Gulf War experience. *J Am Coll Surg* 1998; **187**: 139 – 141.

Tucak A, Lukačević T, Kuveždić H, Petek Ž, Novak R. Urogenital wounds during the war in Croatia in 1991/1992. *J Urol* 1995; **153**: 121 – 122.

Velmahos GC, Degiannis E. The management of urinary tract injuries after gunshot wounds of the anterior and posterior abdomen. *Injury* 1997; **28**: 535 – 538.

Vuckovic I, Tucak A, Gotovac J, Karlovic B, Matos I, Grdovic K, Zelic M. Croatian experience in the treatment of 629 urogenital war injuries. *J Trauma* 1995; **39**: 733 – 736.

### Kidney

Karademir K, Gunhan M, Can C. Effects of blast injury on kidneys in abdominal gunshot wounds. *Urology* 2006; **68**: 1160 – 1163.

Kuveždić H, Tucak A, Grahovac B. War injuries of the kidney. *Injury* 1996; **27**: 557 – 559.

Master VA, McAninch JW. Operative management of renal injuries: parenchymal and vascular. *Urol Clin North Am* 2006; **33**: 21 – 31, v – vi.

Santucci RA, Wessells H, Bartsch G, Descotes J, Heyns CF, McAninch JW, Nash P, Schmidlin F. Consensus on genitourinary trauma. Evaluation and management of renal injuries: consensus statement of the renal trauma subcommittee. *BJU Int* 2004; **93**: 937 – 954. [doi:10.1111/j.1464-410X.2004.04820.x]

Selikowitz SM. Penetrating high-velocity genitourinary injuries. Part I. Statistics, mechanisms, and renal wounds. *Urology* 1977; **9**: 371 – 376.

Serkin FB, Soderdahl DW, Hernandez J, Patterson M, Blackbourne L, Wade CE. Combat urologic trauma in US military overseas contingency operations. *J Trauma* 2010; **69 (Suppl.)**: S175 – S178.

Voelzke BB, McAninch JW. The current management of renal injuries. *Am Surg* 2008; **74**: 667 – 678.

Voelzke BB, McAninch JW. Renal gunshot wounds: clinical management and outcome. *J Trauma* 2009; **66**: 593 – 601.

**Ureter**

Abid AF, Hashem HL. Ureteral injuries from gunshots and shells of explosive devices. *Urol Ann* 2010; **2**: 17 – 20. [doi: 10.4103/0974-7796.62920]

Al-Ali M, Haddad LF. The late treatment of 63 overlooked or complicated ureteral missile injuries: the promise of nephrostomy and role of autotransplantation. *J Urol* 1996; **156**: 1918 – 1921.

Azimuddin K, Milanese D, Ivatury R, Porter J, Ehrenpreis M, Allman DB. Penetrating ureteric injuries. *Injury* 1998; **29**: 363 – 367.

Brandes S, Coburn M, Armenaksa N, McAninch J. Consensus on genitourinary trauma. Diagnosis and management of ureteric injury: an evidence-based analysis. *BJU Int* 2004; **94**: 277 – 289. [doi:10.1111/j.1464-410X.2004.04978.x]

Cass AS. Ureteral contusion with gunshot wounds. *J Trauma* 1984; **24**: 59 – 60.

Cetti NE. Delayed urinary fistula from high velocity missile injury to the ureter. *Ann R Coll Surg Engl* 1983; **65**: 286 – 288.

Fievet JP, Dumurgier C, Jaud V, Courbon X, Cazenave JC, Barnaud P. Les plaies urétérales de guerre: à propos de trois observations africaines. [Ureteric war wounds: concerning three cases in Africa.] *Médecine tropicale* 1987; **47**: 375 – 379.

Rohner TJ Jr. Delayed ureteral fistula from high velocity missiles: report of 3 cases. *J Urol* 1971; **105**: 63 – 64.

Selikowitz SM. Penetrating high-velocity genitourinary injuries. Part II. Ureteral, lower tract, and genital wounds. *Urology* 1977; **9**: 493 – 499.

Stutzman R E. Ballistics and management of ureteral injuries from high velocity missiles. *J Urol* 1977; **118**: 947 – 949.

**Urinary bladder**

Gomez RG, Ceballos L, Coburn M, Corriere JN Jr, Dixon CM, Lobels B, McAninch J. Consensus on genitourinary trauma. Consensus statement on bladder injuries. *BJU Int* 2004; **94**: 27 – 32. [doi:10.1111/j.1464-410X.2004.04896.x]

Petros FG, Santucci RA, Al-Saigh NK. The incidence, management, and outcome of penetrating bladder injuries in civilians resultant from armed conflict in Baghdad 2005 – 2006. *Adv Urol* 2009. [doi: 10.1155/2009/275634]

**Genitalia and urethra**

Brandes SB, Buckman RF, Chelsky MJ, Hanno PM. External genitalia gunshot wounds: a ten-year experience with fifty-six cases. *J Trauma* 1995; **39**: 266 – 272.

Chapple C, Barbagli G, Jordan G, Mundy AR, Rodrigues-Netto N, Pansadoros V, McAninch JW. Consensus on genitourinary trauma. Consensus statement on urethral trauma. *BJU Int* 2004; **93**: 1195 – 1202. [doi:10.1111/j.1464-410X.2004.04805.x]

Cline KJ, Mata JA, Venable DD, Eastham JA. Penetrating trauma to the male external genitalia. *J Trauma* 1998; **44**: 492 – 494.

Goldman HB, Idom CB Jr, Dmochowski RR. Traumatic injuries of the female external genitalia and their association with urological injuries. *J Urol* 1998; **159**: 956 – 959.

Kunkle DA, Lebed BD, Mydlo JH, Pontari MA. Evaluation and management of gunshot wounds of the penis: 20-year experience at an urban trauma center. *J Trauma* 2008; **64**: 1038 – 1042.

Lukačević T, Tucak A, Kuveždić H. Les blessures de guerre des organes génitaux externes. [War injuries of the external genital organs.] *Progrès en Urologie* 1997; **7**: 259 – 261.

Phonsombat S, Master VA, McAninch JW. Penetrating external genital trauma: a 30-year single institution experience. *J Urol* 2008; **180**: 192 – 196.

## Chapter 34

Ahmed AM, Sabrye MH, Baldan M. Autotransfusion in penetrating chest war trauma with haemothorax: the Keysaney Hospital experience. *East Cent Afr J Surg* 2003; **8**: 51 – 54.

Baldan M, Giannou C, Rizzardi G, Irmay F, Sasin V. Autotransfusion from haemothorax after penetrating chest trauma: a simple life-saving procedure. *Trop Doct* 2006; **36**: 21 – 22.

Barriot P, Riou B, Viars P. Prehospital autotransfusion in life-threatening hemothorax. *Chest* 1998; **93**: 522 – 526.

Brown CVR, Foulkrod KH, Sadler HT, Richards EK, Biggan DP, Czysz C, Manuel T. Autologous blood transfusion during emergency trauma operations. *Arch Surg* 2010; **145**: 690 – 694.

Buffat JJ, Bonsignour JP, Brinquin L, Diraison Y, Huard F, Pavie G. Autotransfusion après récupération de sang dans les situations d'exception. [Autotransfusion after blood recuperation in exceptional situations.] *Ann Fr Anesth Réanim* 1989; **8**: 234 – 240.

Bulger EM, Maier RV. Autologous blood transfusion in trauma. *Trauma* 2001; **3**: 1 – 7. [doi:10.1177/146040860100300101]

Glover JL, Broadie TA. Intraoperative autotransfusion. *World J Surg* 1987; **11**: 60 – 64.

Jevtic M, Petrovic M, Ignjatovic D, Ilijevski N, Misovic S, Kronja G, Stankovic N. Treatment of wounded in the combat zone. *J Trauma* 1996; **40 (Suppl.)**: S173 – S176.

Koopman-van Gemert AWMM. Autotransfusion: therapeutic principles, efficacy and risks. In: Kochhar PK ed. *Blood Transfusion in Clinical Practice*. Rijeka, Croatia: InTech Open Publishing; 2012: 205 – 222. Available at: <http://www.intechopen.com/books/blood-transfusion-in-clinical-practice/autotransfusion-therapeutic-principles-efficacy-and-risks>. [doi: 10.5772/35754]

Lenz G, Stehle R. Anaesthesia under field conditions. A review of 945 cases. *Acta Anaesthesiol Scand* 1984; **28**: 351 – 356.

Marquis M-C, Gyger D. Autotransfusions peropératoires en zone rurales africaines: une solution d'urgence. [Intra-operative autotransfusion in rural Africa: an emergency solution.] *Labor und Medizin / Laboratoire et Médecine* 1998; **25**: 284 – 285.

Mattox KL, Walker LE, Beall AC, Jordan GL Jr. Blood availability for the trauma patient – autotransfusion. *J Trauma* 1975; **15**: 663 – 668.

Parker-Williams EJ. Autologous blood transfusion. *Postgrad Doct Afr* 1989; **11**: 52 – 55.

Rubens FD, Mujoomdar A, Tien HC. Cell salvage in trauma. *International Trauma Care ITACCS* 2008; **18**: 35 – 41.

Rumisek JD. Autotransfusion of shed blood: an untapped battlefield resource. *Mil Med* 1982; **147**: 193 – 196.

Symbas PN. Extraoperative autotransfusion from haemothorax. *Surgery* 1978; **84**: 722 – 727.

Vélez-Rojas H. La autotransfusión en Medellín: diez años de experiencia. [Autotransfusion in Medellín: ten years' experience.] *Revista Colombiana de Cirugía* 2000; **15**: 22 – 27.

### Enteric contamination

Bowley DM, Barker P, Boffard KD. Intraoperative blood salvage in penetrating abdominal trauma: a randomised, controlled trial. *World J Surg* 2006; **30**: 1074 – 1080.

Due TL, Johnson JM, Wood M, Hale HW Jr. Intraoperative autotransfusion in the management of massive hemorrhage. *Am J Surg* 1975; **130**: 652 – 658.

Glover JL, Smith R, Yaw PB, Radigan LR, Bendick P, Plawecki R. Autotransfusion of blood contaminated by intestinal contents. *J Am Coll Emerg Phys (Ann Emerg Med)* 1978; **7**: 142 – 144.

Gurin NN, Vovk VI, Novitskiĭ LV. Blood reinfusion in penetrating gunshot wounds of the abdomen. *Voenno-Meditsinskii Zhurnal* 1992; **6**: 10 – 12. [In Russian; English abstract.]

Ozmen V, McSwain NR Jr, Nichols RL, Smith J, Flint LM. Autotransfusion of potentially culture-positive blood (CPB) in abdominal trauma: preliminary data from a prospective study. *J Trauma* 1992; **32**: 36 – 39.

Smith RN, Yaw PB, Glover JL. Autotransfusion of contaminated intraperitoneal blood: an experimental study. *J Trauma* 1978; **18**: 341 – 344.

Thomas MJG. Infected and malignant fields are an absolute contraindication to intraoperative cell salvage: fact or fiction? *Transfus Med* 1999; **9**: 269 – 278.

Timberlake GA, McSwain NE. Autotransfusion of blood contaminated by enteric contents: a potentially life-saving measure in the massively hemorrhaging patient? *J Trauma* 1988; **28**: 855 – 857.

## Chapter 35

Aboutanos SZ, Aboutanos MB, Malhotra AK, Duane TM, Ivatury RR. Management of a pregnant patient with an open abdomen. *J Trauma* 2005; **59**: 1052 – 1056.

Barraco RD, Chiu WC, Clancy TV, Como JJ, Ebert JB, Hess LW, Hoff WS, Holevar MR, Quirk JG, Simon BJ, Weiss PM. Practice management guidelines for the diagnosis and management of injury in the pregnant patient: the EAST Practice Management Guidelines Work Group. *J Trauma* 2010; **69**: 211 – 214.

Buchsbaum HJ. Diagnosis and management of abdominal gunshot wounds during pregnancy. *J Trauma* 1975; **15**: 425 – 430.

Grabo DJ, Schwab CW. Trauma in Pregnant Women. In: Peitzman AB, Schwab CW, Yealy DM, Rhodes M, Fabian TC, eds. *The Trauma Manual: Trauma and Acute Care Surgery 4th ed*. Philadelphia PA: Lippincott Williams & Wilkins; 2012: 228 – 233.

Iliya FA, Hajj SN, Buchsbaum HJ. Gunshot wounds of the pregnant uterus: report of two cases. *J Trauma* 1980; **20**: 90 – 92.

Mattox KL, Goetzl L. Trauma in pregnancy. *Crit Care Med* 2005; **33 (Suppl. 10)**: S385 – S389.

McNabney WK, Smith EI. Penetrating wounds of the gravid uterus. *J Trauma* 1972; **12**: 1024 – 1028.

Petrone P, Asensio JA. Trauma in pregnancy: assessment and treatment. *Scand J Surg* 2006; **95**: 4 – 10.

Pierson R, Mihalovits H, Thomas L, Beatty RI. Penetrating abdominal wounds in pregnancy. *Ann Emerg Med* 1986; **15**: 1232–1234.

Wilson F, Swartz DP. Gunshot and war projectile wounds of the gravid uterus: case report and review of the literature. *J Natl Med Assoc* 1972; **64**: 8 – 13.

### International humanitarian law

Customary International Humanitarian Law. Chapter 39, Rule 134. *Women: The specific protection, health and assistance needs of women affected by armed conflict must be respected*. Available at: <http://www.icrc.org/customary-ihl/eng/docs/v1>.

Durham H. Women, armed conflict and international law. *International Review of the Red Cross*; 2002; **84 (847)**: 655 – 660. [doi: S1560775500090416]

Gardam JG. Femmes, droits de l'homme et droit international humanitaire. [Women, human rights and international humanitarian law.] *International Review of the Red Cross* 1998; **80 (831)**: 449 – 462. [doi: S0035336100056008]

*Gender Perspectives on International Humanitarian Law: Report on the International expert meeting*. Stockholm, 4 – 5 October 2007. Co-hosted by the Swedish Ministry for Foreign Affairs, the Swedish Defence College, the Folke Bernadotte Academy and the Asia Pacific Centre for Military Law. Stockholm: Sweden Ministry for Foreign Affairs; 2008.



Krill F. La protection de la femme en droit international humanitaire. [The protection of women in International Humanitarian Law] *International Review of the Red Cross* 1985; **67 (756)**: 343 – 370. [doi: S0035336100086123]

Lindsey C. *Women Facing War: ICRC Study on the Impact of Armed Conflict on Women*. Geneva: ICRC; 2001.

Lindsey-Curtet C. Afghanistan: An ICRC perspective on bringing assistance and protection to women during the Taliban regime. *International Review of the Red Cross* 2002; **87 (847)**: 643 – 654. [doi: S1560775500090404]

Lindsey-Curtet C, Tercier Holst-Roness F, Anderson L. *Addressing the Needs of Women Affected by Armed Conflict: An ICRC Guidance Document*. Geneva: ICRC; 2004.

Mazurana D. *Women in Armed Opposition Groups in Africa and the Promotion of International Humanitarian Law and Human Rights: Report of a Workshop, Addis Ababa, 23 – 26 November, 2005*. Geneva: Geneva Call and Program for the Study of International Organizations; 2006.

de Preux J. Texte de Synthèse III: Protection spéciale des femmes et des enfants. [Special protection of women and children.] *International Review of the Red Cross* 1985; **67 (755)**: 297 – 307. [doi: S0035336100171424]

Rahim T. An identity of strength: personal thoughts on women in Afghanistan. *International Review of the Red Cross* 2002; **84 (847)**: 627 – 641. [doi: S1560775500090398]

## Part E

### Chapter 36

Aarabi B, Alibaii E, Taghipur M, Kamgarpur A. Comparative study of functional recovery for surgically explored and conservatively managed spinal cord missile injuries. *Neurosurgery* 1996; **39**: 1133 – 1140.

Alaca R, Yilmaz B, Goktepe AS, Yazicioglu K, Gunduz S. Military gunshot wound-induced spinal cord injuries. *Mil Med* 2002; **167**: 926 – 928.

Buxton N. The military medical management of missile injury to the spine: a review of the literature and proposal of guidelines. *J R Army Med Corps* 2001; **147**: 168 – 172.

Comstock S, Pannell D, Talbot M, Compton L, Withers N, Tien HC. Spinal injuries after improvised explosive device incidents: implications for Tactical Combat Casualty Care. *J Trauma* 2011; **71 (Suppl.)**: S413 – S417.

Covey DC, Lurate RB, Hatton CT. Field hospital treatment of blast wounds of the musculoskeletal system during the Yugoslav civil war. *J Orthop Trauma* 2000; **14**: 278 – 286.

Duz B, Cansever T, Secer HI, Kahraman S, Daneyemez MK, Gonul E: Evaluation of spinal missile injuries with respect to bullet trajectory, surgical indications and timing of surgical intervention: a new guideline. *Spine* 2008; **33**: E746 – E753.

Goonewardene SS, Mangati KS, Sargeant ID, Porter K, Greaves I. Tetraplegia following spinal cord contusion from indirect gunshot injury effects. *J R Army Med Corps* 2007; **153**: 52 – 53.

Hammoud MA, Haddad FS, Moufarrij NA. Spinal cord missile injuries during the Lebanese civil war. *Surg Neurol* 1995; **43**: 432 – 442.

Harbrecht BG, Djurasovic M. Thoracolumbar spine trauma: diagnostic and therapeutic considerations for the general surgeon. *Am Surg* 2009; **75**: 191 – 196.

Jourdan P, Breteau JP, Volff P. Lésions de la moelle par projectile a trajet extra-rachidien. Approche historique, expérimentale et thérapeutique. [Spinal cord injuries caused by extraspinal gunshot. A historical, experimental and therapeutic approach]. *Neuro-Chirurgie* 1994; **40**: 183 – 195.

Kihtir T, Ivatury RR, Simon R, Stahl WM. Management of transperitoneal gunshot wounds of the spine. *J Trauma* 1991; **31**:1579 – 1583.

Klimo P Jr, Ragel BT, Rosner M, Gluf W, McCafferty R. Can surgery improve neurological function in penetrating spinal injury? A review of the military and civilian literature and treatment recommendations for military neurosurgeons. *Neurosurg Focus* 2010 **28 (5)**: E4. Available at: <http://thejns.org/doi/pdf/10.3171/2010.2.FOCUS1036>.

Kossmann T, Trease L, Freedman I, Malham G. Damage control surgery for spine trauma. *Injury* 2004; **35**: 661 – 670.

Mirovsky Y, Shalmon E, Blankstein A, Halperin N. Complete paraplegia following gunshot injury without direct trauma to the cord. *Spine* 2005; **30**: 2436 – 2438.

Newcombe R, Merry G. The management of acute neurotrauma in rural and remote locations: a set of guidelines for the care of head and spinal injuries. *J Clin Neurosci* 1996; **6**: 85 – 93.

Ohry A, Rozin R. Acute spinal cord injuries in the Lebanon war, 1982. *Isr J Med Sci* 1984; **20**: 345 – 349.

Splavski B, Vranković D, Šarić G, Blagus G, Muršić B, Rukovanjski M. Early management of war missile spine and spinal cord injuries: experience with 21 cases. *Injury* 1996; **27**: 699 – 702.

Waters RL, Adkins RH. The effects of removal of bullet fragments retained in the spinal canal. A collaborative study by the National Spinal Cord Injury Model Systems. *Spine* 1991; **16**: 934 – 939.

#### **Spinal immobilization (additional references)**

Cornwell EE, Chang DC, Bonar JP, Campbell KA, Phillips J, Lipsett P, Scalea T, Bass R. Thoracolumbar immobilization for trauma patients with torso gunshot wounds: Is it necessary? *Arch Surg* 2001; **136**: 324 – 327.

Haut ER, Kalish BT, Efron DT, Haider AH, Stevens KA, Kieninger AN, Cornwell EE, Chang DC. Spine immobilization in penetrating trauma: more harm than good? *J Trauma* 2010; **68**: 115 – 121.

Inaba K, Barmparas G, Ibrahim D, Branco BC, Gruen P, Reddy S, Talving P, Demetriades D. Clinical examination is highly sensitive for detecting clinically significant spinal injuries after gunshot wounds. *J Trauma* 2011; **71**: 523 – 527.

Kupcha PC, An HS, Cotler JM. Gunshot wounds to the cervical spine. *Spine* 1990; **15**: 1058 – 1063.

Lanoix R, Gupta R, Leak L, Pierre J. C-spine injury associated with gunshot wounds to the head: retrospective study and literature review. *J Trauma* 2000; **49**: 860 – 863.

Lustenberger T, Talving P, Lam L, Kobayashi L, Inaba K, Plurad D, Branco BC, Demetriades D. Unstable cervical spine fracture after penetrating neck injury: a rare entity in an analysis of 1,069 patients. *J Trauma* 2011; **70**: 870 – 872.

Splavski B, Vranković D, Blagus G, Muršić B, Iveković V. Spinal stability after war missile injuries of the spine. *J Trauma* 1996; **41**: 850 – 853.

Stuke LE, Pons PT, Guy JS, Chapleau WP, Butler FK, McSwain NE. Prehospital spine immobilization for penetrating trauma – review and recommendations from the Prehospital Trauma Life Support Executive Committee. *J Trauma* 2011; **71**: 763 – 770.

Vanderlan WB, Tew BE, McSwain NE Jr. Increased risk of death with cervical spine immobilization in penetrating cervical trauma. *Injury* 2009; **40**: 880 – 883.

#### **Management of spinal cord patients**

American Spinal Injury Association. Dedicated website; for learning materials see: <http://www.asia-spinalinjury.org/elearning/elearning.php>.

Burgdörfer H, Heidler H, Madersbacher H, Kutzenberger J, Palmtag H, Pannek J, Sauerwein D, Stöhrer M. *Manual Neuro-Urology and Spinal Cord Lesion. Guidelines for*

*Urological Care of Spinal Cord Injury Patients 4th edition*. Cologne: German Working Party on Urological Rehabilitation of Spinal Cord Injury Patients; 2007.

Consortium for Spinal Cord Medicine. *Bladder Management for Adults with Spinal Cord Injury: A Clinical Practical Guideline for Health-Care Providers*. Washington, DC: Paralyzed Veterans of America; 2006. Available at: <http://www.pva.org>.

icord International Collaboration On Repair Discoveries. University of British Columbia and Vancouver Coastal Health Research Institute. Available at: <http://icord.org>. [A general web site on the care of patients with spinal cord injuries.]

Kirshblum SC, Burns SP, Biering-Sorensen F, Donovan W, Graves DE, Jha A, Johansen M, Jones L, Krassioukov A, Mulcahey MJ, Schmidt-Read M, Waring W. International Standards Committee of ASIA. International Standards for Neurological Classifications of Spinal Cord Injury. Revised 2011. *J Spinal Cord Med* 2011; **34**: 535 – 546. [doi 10.1179/204577211X13207446293695]

NIDRR National Institute on Disability and Rehabilitation Research Consensus Statement. The prevention and management of urinary tract infections among people with spinal cord injuries. *J Amer Parapleg Soc* 1992; **15**: 194 – 204.

Parikh RP, Franzen M, Pope C, Gould L. Autonomic dysreflexia: be aware and be prepared. *Wounds* 2012; **24**: 160 – 167.

Vaidyanathan S, Soni B, Oo T, Hughes P, Singh G, Pulya K. Autonomic dysreflexia in a tetraplegic patient due to blocked urethral catheter: Spinal cord injury patients with lesions above T-6 require prompt treatment of obstructed urinary catheter to prevent life-threatening complications of autonomic dysreflexia. *Internat J Emerg Med* 2012; **5**: 6. Available at: <http://www.intjem.com/content/5/1/6>.

## Part F

Adler D, Mgalula K, Price D, Taylor O. Introduction of a portable ultrasound unit into the health services of the Lugufu refugee camp, Kigoma District, Tanzania. *Int J Emerg Med* 2008; **1**: 261 – 266. [doi 10.1007/s12245-008-0074-7]

American Thoracic Society. Fair allocation of intensive care unit resources. *Am J Respir Crit Care Med* 1997; **156**: 1282 – 1301.

Dünser MW, Baelani I, Ganbold L. A review and analysis of intensive care medicine in the least developed countries. *Crit Care Med* 2006; **34**: 1234 – 1242.

Eyssallenne AP. How far do you go? Intensive care in a resource-poor setting. *N Engl J Med* 2012; **367**: 8 – 9.

Gatrad AR, Gatrad S, Gatrad A. Equipment donation to developing countries. *Anaesthesia* 2007; **62 (Suppl. 1)**: 90 – 95.

Jarvis DA, Brock-Utne JG. Use of an oxygen concentrator linked to a draw-over vaporizer (anesthesia delivery system for underdeveloped nations). *Anesth Analg* 1991; **72**: 805 – 810.

McCormick BA, Eltringham RJ. Anaesthesia equipment for resource-poor environments. *Anaesthesia* 2007; **62 (Suppl.)**: 54 – 60.

Okafor UV. Challenges in critical care services in Sub-Saharan Africa: perspectives from Nigeria. *Indian J Crit Care Med* 2009; **13**: 25 – 27. [doi: 10.4103/0972-5229.53112]

Rathore MFA, Hanif S, New PW, Butt AW, Aasi MH, Khan SU. The prevalence of deep vein thrombosis in a cohort of patients with spinal cord injury following the Pakistan earthquake of October 2005. *Spinal Cord* 2008; **46**: 523 – 526.

Saraf SK, Rana RJ, Sharma OP. Venous thromboembolism in acute spinal cord injury patients. *Indian J Orthop* 2007; **41**: 194 – 197.

Sippel S, Muruganandan K, Levine A, Shah S. Review article: Use of ultrasound in the developing world. *Int J Emerg Med* 2011; **4**: 72. Available at: <http://www.intjem.com/content/4/1/72>.

Towey RM, Ojara S. Intensive care in the developing world. *Anaesthesia* 2007; **62 (Suppl.)**: 32 – 37.

Wilson RM, Michel P, Olsen S, Gibberd RW, Vincent C, El-Assady R, Rasslan O, Qsous S, Macharia WM, Sahel A, Whittaker S, Abdo-Ali M, Letaief M, Ahmed NA, Abdellatif A, Larizgoitia I, for the WHO Patient Safety EMRO/AFRO Working group. Patient safety in developing countries: retrospective estimation of scale and nature of harm to patients in hospital. *BMJ* 2012; **344**: e832. [doi: 10.1136/bmj.e832]

World Health Organization. *Guidelines for Health Care Equipment Donations*. Geneva: WHO; 2000. Available at: [http://www.who.int/hac/techguidance/pht/1\\_equipment%20donationbuletin82WHO.pdf](http://www.who.int/hac/techguidance/pht/1_equipment%20donationbuletin82WHO.pdf).



**MISSION**

The International Committee of the Red Cross (ICRC) is an impartial, neutral and independent organization whose exclusively humanitarian mission is to protect the lives and dignity of victims of armed conflict and other situations of violence and to provide them with assistance. The ICRC also endeavours to prevent suffering by promoting and strengthening humanitarian law and universal humanitarian principles. Established in 1863, the ICRC is at the origin of the Geneva Conventions and the International Red Cross and Red Crescent Movement. It directs and coordinates the international activities conducted by the Movement in armed conflicts and other situations of violence.





ICRC

ISBN 978-2-940396-25-2



9 782940 396252 >